

THE ROLE OF PARASITIC INFECTIONS IN THE DEVELOPMENT OF RESPIRATORY DISEASES IN SWINE

Ivan PAVLOVIĆ¹, Jovan BOJKOVSKI², Nemanja ZDRAVKOVIĆ¹, Oliver RADANOVIĆ¹,
Ivan DOBROSAVLJEVIĆ³, Slavonka STOKIĆ-NIKOLIĆ³, Ljiljana SPALEVIĆ¹,
Srđan JOVČEVSKI⁴, Stefan JOVČEVSKI⁴

e-mail: dripavlovic58@gmail.com

Abstract

Metastrongylidosis is a parasitosis caused by several species of nematodes of the genus *Metastrongylus*. The development of parasites goes through transitional hosts - earthworms. Infection occurs when pigs eat infected worms so infections are most commonly found in organic production and extensive breeding. The pathological effect of parasites begins with their larvae migratory movement from the lung capillaries to the lung tissue, during migration through the lung tissue, during the stay and activity of adults in the bronchi and aspiration of parasite eggs into bronchioles and alveoli. This is followed by the toxic effect of metabolic products of the parasite, which after resorption in the blood can lead to general intoxication. The predilection place of parasites is the posterior parts of the diaphragmatic lobe - margo acutus and margo obtusus. Affected animals show signs of dyspnoea and frequent vesicular respiration. In addition to the direct pathological action of metastrongylide, they transmit several diseases of pigs of bacterial and viral etiology. Two species of these parasites, *Metastrongylus elongatus* and *Metastrongylus pudendotectus*, have been identified in Serbia. The prevalence of both species varies from region to region. In the north of Serbia (Vojvodina), the presence of *M. pudendotectus* dominates, while in central and southern Serbia, *M. elongatus* is much more common. In Serbia, in individual (semi-extensive and extensive) housing, infections are found in 34-52% of animals and in 1-3% of swine in farms.

Key words: *Metastrongylus spp.*, swine, respiratory diseases

INTRODUCTION

With increasing demand for products resulting from organic farming and corresponding better animal welfare closer to natural behaviour, animals are increasingly kept outdoors grow possibility to have direct contact with numerous intermediate hosts of parasites and other diseases (Loskot V.I., *et al.* 1988; Pavlović I., *et al.* 2013,2017; Adedokun O.A., *et al.* 2001; Carstensen L.,*et al.*2002).

The dominant species of parasites in this breeding are biohelminths and lungworms are one of the most common. (Dunn D.R., *et al.*1955; Kruse G.O.W., Ferguson D.L., 1980; Pavlović I.,*et al.* 2012). *Metastrongylus* sp. infection is reported all around the world in wild boars and pigs (Barutzki D.,Richter R.,1980; Alcaide M.,*et al.*2005; García-González A.M.,*et al.*2013; Nagy *et al.*,2013; Spieler N.,Schnyde M.,2021).

¹ Scientific Veterinary Institute of Serbia, Belgrade, Serbia

² Faculty of Veterinary Medicine, Belgrade, Serbia

³ Veterinary Institute Požarevac, Požarevac, Serbia

⁴ Veterinary Clinic " I N O - V E T " Kumanovo, North Macedonia

In Serbia, research on the *Metastrongylus* species in domestic and wild swine has been done periodically (Pavlović I.,*et al.* 1995, 1997, 2005b, 2011).

SYSTEMATICS AND DISTRIBUTION OF METASTRONGYLUS

All *Metastrongylus* are in the class Nematoda, subclass Myosyringata, order Strongylata, suborder Metastrongyloidea, family Metastrongyloidea, subfamily Metastrongylinae and genus *Metastrongylus*. A total of 6 species have been identified in this genus: *Metastrongylus apri* (syn. *M. elongatus*), *Metastrongylus asymmetricus*, *Metastrongylus confusus*, *Metastrongylus madagascariensis*, *Metastrongylus pudendotectus* and *Metastrongylus salmi* (Gasso, D., *et al.* 2014),

The geographical distribution of individual species varies so that *M.apri* and *M.pudentotectus* have the widest distribution. *M.confusus* is found in Europe including Poland and *M.salmi* has been found in South America, Europe and Africa (Khrustalev A.V., 1981; Drozd J., Zalewska-Schonthaler N.,1987; Singh B.B., *et al.* 1989). The last two species, *M.tschiauricus* and *M.madagascariensis* have been described only in feral pigs, the first species in the Netherlands and Georgia and the second found only in Madagascar. Most of these species persist in feral pigs so that cross-infections occur in environments where extensive housing (packing) is present (Corwin R.M., Stewart T.B., 1992).

Two species of *M.elongatus* and *M.pudendotectus* have been established in Serbia. The prevalence of both species varies from region to region. The presence of *M.pudendotectus* dominates in Vojvodina, while *M.elongatus* is much more common in central and southern Serbia. (Pavlović I., *et al.* 1997,2005b).

BIOLOGY AND MORPHOLOGY OF METASTRONGYLUS

The genus *Metastrongylus* is characterized by a thin long whitish body, the oral cavity is small and the oral opening is surrounded by two small three-lobed lips. The copolar bursa is relatively small with well-developed lateral lobes while the dorsal lobe is small (Soulsby E.J.L., 1977). At the time of laying, the eggs are embryonated and wrapped in a thin membrane that swells during their passage through the respiratory and digestive organs of pigs, so that we find eggs with a thick membrane in the feces.

EPIZOOTIOLOGY

Metastrongylus belongs to biohelminths whose causative agents use transient hosts for their development and maintenance of the biological cycle, in this case numerous types of lumbricids (earthworms). Eggs are very resistant in the external environment and can remain vital in a humid environment for up to 2 years. Depending on the external conditions, larvae are released from the eggs, which can survive in the external environment for up to three months but are not infectious to the true host (Dun D.R., *et al.*, 1955; Kruse G.O.W., 1978; Vanparijs O., Thienpont D.,1982; Humbert J.F., Drouet J.,1990).

The larvae become infected only when they are eaten by earthworms - a transitional host. Depending on the geographical environment, numerous representatives of lumbricids persist as intermediate hosts. In environment condition in Serbia the dominant species of earthworms are *Eisenia foetida*, *E.rosea*, *E.veneta*, *Dandreobena rubida*, *D. octaedra*, *D.subrubicunda*, *Allopbophora caliginosa*, *A.jassyensis*, *A.longa*, *Octolasion complanatum*, *O.lacteum*, *O.rebeli*, *Lubricus terrestris* and *L.rubbelus* (Tričković D.,1978; Pavlović I., *et al.*2005a).

In worms, the larvae are localized in the walls of the blood vessels of the esophagus and foregut. Here they hatch twice and develop into an infectious form in 10-25 days (Kruse G.O.W., 1978; Humbert J.F.,1992). After maturation, the larvae migrate into the blood vessels of the worms and remain infectious in them for up to 7 years. The

larvae never leave the worms spontaneously (Ueno H., *et al.* 1960; Kruse G.O.W., 1978). Only in the case of earthworm damage (cutting during tillage, etc.) do they come out of the earthworm and from there reach the surface layers of the earth, where they can live up to 2 weeks, depending on the humidity.

ROUTES AND MODE OF INFECTION

Infection of pigs occurs orally. From the digestive tract, the larvae reach the mesenteric lymph nodes where they hatch. From there, they reach the bloodstream and lungs via the lymphatic system through the right heart. In the bronchi and bronchioles, the larvae grow and after 24 days reach the adult stage. The transparent period lasts 24-37 days (Dunn D.R., *et al.* 1955; Dunn D.R.,1957)

Young pigs aged 2-8 weeks are the most susceptible to infection. Maximum production of parasite eggs in the period of 5-9 weeks after infection. In the following period, the number of parasites decreases, but one number remains especially in the distal parts of the lungs (Kvachadze G.A.,1975).

PATHOGENESIS AND PATHOLOGICAL FINDING

The pathological effect of parasites begins with their larvae migratory movement from pulmonary capillaries to lung tissue, during migration through lung tissue, during stay and activity of adults in bronchi and aspiration of parasite eggs into bronchioles and alveoli (Dunn D.R., *et al.* 1955; Drozd J., Zalewska-Schonhaler N.,1987). This is followed by the toxic effect of metabolic products of the parasite, which after resorption in the blood can lead to general intoxication.

The degree and intensity of pathological changes in the lungs directly depends on the intensity of the infection. In mild infections, the predilection site is the posterior parts of the diaphragmatic lobe - margo acutus and margo obtusus (Nakauchi K., *et al.* 1991, Ivetić V., *et al.*2000, Šabec D.,2002). Other parts of the lungs are also affected by severe infections (Marruchella G., *et al.*2012). Bronchiolitis, bronchitis, diffuse pneumonia, alveolar emphysema and connective tissue proliferation and cellular infiltration are observed (Ivetić V., *et al.*2000).

Some groups of lobules or groups of lobules are voluminous, grayish-white, and rustling (lobular emphysema) can be heard at the cross-section, and the changes are wedge-shaped, based on a bronchus

filled with parasites (Yoshihara S., *et al.* 1990; Šabec D., 2002).

In bronchioles and bronchi, parasites are found in various developmental stages, either free in mucous exudate or surrounded by cellular infiltrate (Ivetić V., *et al.* 2003) (figure 1).

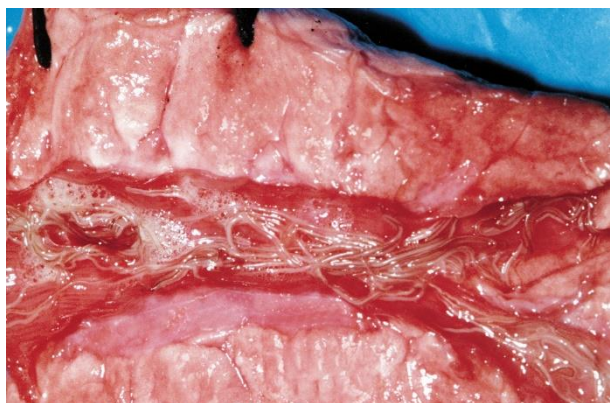


Figure 1. adult *Metastrongylus sp.* in bronchi

In the pulmonary parenchyma, especially in the caudal part of the diaphragmatic lobe, gray nodules of 0.6-2 mm in size are found subpleurally, in which a central yellow or yellow-green field surrounded by a dark zone of connective tissue is observed (Nakauchi K., *et al.* 1991). This zone is composed of larvae of parasites, cellular infiltration of macrophages, eosinophils, lymphocytes and giant cells (Sasaki O., Katsuno M., 1983; Ivetić V., *et al.* 2003) (figure 2).

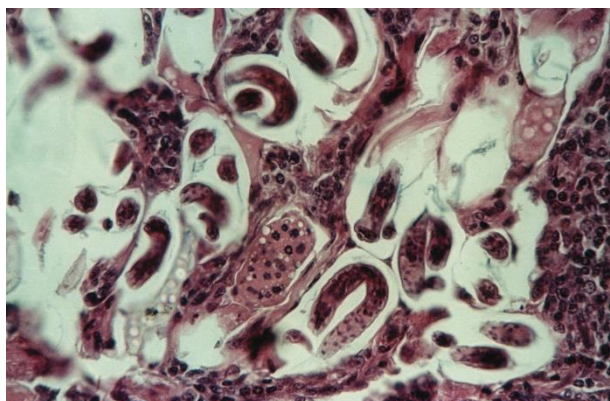


Figure 2. larvae of *Metastrongylus sp.* in the pulmonary parenchyma

CLINICAL SIGNS

The clinical signs of disease depends on the degree of infection. In mild infections, they are

weakly expressed - a weak cough is most often present. In severe infections, the symptoms appear as early as the second week after the infection, and are most pronounced 4-6 weeks when the disease progresses to a chronic stage. Diseased animals show signs of dyspnoea and frequent vesicular respiration (Pavlović I., *et al.* 1997).

At the beginning, there is a weak and later a hoarse cough, which is in the form of an attack when the animals have stress (running, etc.). The mucous membranes are pale, appetite is reduced and eosinophilia is present in the blood. Body temperature is elevated only when secondary infections are present (Pavlović I., *et al.* 1997). Metastrongylides are biological and mechanical vectors of many bacterial and viral infections in pigs. Influenza viruses and classical swine fever, which infiltrate the embryos of metastrongylide egg embryos and then persist in larvae in transient hosts and finally infect pigs that eat earthworms with larvae are certainly the most significant (Shope R.E., 1941, 1958, Pavlović I., *et al.* 2005b, 2012). Pasteurellosis is also transmitted through metastrongylide and several other types of bacteria.

Thanks to that, the clinical picture of metastrongylid is additionally burdened with secondary infections that can be drastic and cause mass deaths of pigs (Corwin R.M., Stewart T.B., 1992; Pavlović I., *et al.* 2005).

DIAGNOSTIC METHODS

Similar to other types of endoparasites, metastrongylides eliminate eggs in the environment through feces or sputum. In the feces of diseased animals, they are isolated by standard coprological methods (sedimentation, flotation), where the morphometric differences between individual species in this genus are very small, so it is most often mentioned in the finding as *Metastrongylus spp.* (similar to other strongylides) (Euzebý, 1981).

An autopsy report provides accurate information on the type of metastrongylide present. The morphometric differences are very clear so there are no problems related to the determination of the causative agent. Epizootiological data on the types of lumbricids and the finding of metastrongylide larvae in them is also an important diagnostic data that allows us to determine potential sites of infection.

THERAPY AND PROPHYLAXIS

In the control of metastrongylides, there is a large selection of preparations that are applied by food or injection. Neither has an effect on migratory larvae nor is it an ovcid. Metastrongylidosis is a

disease of pigs kept on pastures, in yards and in general on the outlets extensively or semi-extensively, although it will also occur in farm-kept animals in conditions when they are kept on the outlet. In the free keeping of pigs, the most important but also the least feasible preventive measure is the separate keeping of different age categories of animals. It is desirable to avoid contaminated pastures, and considering the length of life of earthworms (they live 2-7 years), it is also difficult to do, as well as avoiding mixing wild and domestic pigs, which is even more difficult when packing. Preventive deworming proved to be the most effective – autumn, which is done 3-4 weeks after withdrawal from pastures, and spring before expulsion to pasture. All animals must be treated (Pavlović I., *et al.* 2005).

ACKNOWLEDGMENTS

This study was supported by the Ministry of Education, Science and Technological Development, Republic of Serbia (Contract for research funding No. 451-03-68/2020-14/200030)

REFERENCES

- Adedokun O.A., Adejinmi J.O., Ukoikpoko G.B., 2001** - Effect of husbandry system on the incidence of lungworm (*Metastrongylus* spp) in pigs in Ibadan, Nigeria. Tropical Veterinary, 19, 175–177.
- Alcaide M., Frontera E., Rodríguez M.J., Sáez I.E., Domínguez-Alpízar J.L., Reina D., Navarrete I. 2005** - Parasitosis pulmonares del cerdo ibérico Situación actual de la metastrongilosis en España. Mundo Ganadero, 176, 40–44
- Barutzki D., Richter R., 1990** - Investigations on the endoparasitic infection on wild boars of open area. Zeitschrift für Jagdwissenschaft, 36, 244-251
- Corwin R.M., Stewart T.B., 1992** - Internal parasites. In: A.D.Leman. (eds) Disease of Swine. Wolf Publishing, London, 718-734
- Carstensen L., Vaarst M., Roepstorff A., 2002** - Helminth infections in Danish organic swine herds. Veterinary Parasitology, 106,253–264.
- Drozd J., Zalewska-Schonthaler N., 1987** - *Metastrongylus confusus*, a lungworm of wild boars, new for Poland. Wiadomosci parazytologiczne, 33, 217-218
- Dunn D.R., Gentiles M.A., White E.G., 1955** - Studies on the pig lungworm (*Metastrongylus* spp.) Observations on natural infection in the pig in Great Britain. British Veterinary Journal, 111, 271-275.
- Dunn D.R., 1957** - Studies on the pig lungworm (*Metastrongylus* spp.) II Experimental infection of pigs with *M.apri*. British Veterinary Journal, 112, 327-331.
- Euzeby J., 1981** - Diagnostic experimental des helminthoses animales. EITSV, Paris.
- Gassó D., Rossi L., Mentaberre G., Casas E., Velarde R., Nosal P., Serrano E., Segales J., Fernandez- Llarío P., Felíu C., 2014** - An identification key for the five most common species of *Metastrongylus*. Parasitology Research, 113,3495–3500.
- García-González Á.M., Pérez-Martín J.E., Gamito-Santos J.A., 2013** - Epidemiologic study of lung parasites (*Metastrongylus* spp.) in wild boar (*Sus scrofa*) in southwestern Spain. Journal of Wildlife Disease 49,157– 162.
- Ivetić V., Žutić M., Valter D., Pavlović I., Savić B., 2000** - Atlas patomorfoloških promena bolesti svinja /Atlas of pathological changes at swine disease/. Naučni institut za veterinarstvo Srbije, Beograd.
- Humbert J.F., 1992** - Etude histo-pathologique de la relation hôte-parasite: le modèle lombric, sanglier-metastrongyles. Revue scientifique et technique. 11,1063–1070
- Humbert J.F., Drouet J., 1990** - Enquête épidémiologique sur la métastrongylose du sanglier (*Sus scrofa*) en France. Gibier Faune Sauvage, 7, 67–84
- Khrustalev A.V., 1981** - Species composition of the genus *Metastrongylus* a lung parasite of pigs and wild boars in the USSR. Parazitologiya (St Petersburg), 15,420–423.
- Kruse G.O.W., 1978** - Studies of the life cycle stages of the porcine lungworm *Metastrongylus apri* Gmelin 1790 (Nematode:Metastrongylidae). Proceeding of Nebraska Academy of Science, 88, 15.
- Kruse G.O.W., Ferguson D.L., 1980** - Continued studies of the porcine lungworm *Metastrongylus apri* (Ebel,1777) Vostokov 1905 (Metastrongylidae Nematoda). Veterinary Medicine Review, 2, 113-130
- Kvachadze G.A., 1975** - Age variations in *Metastrongylus* infection in pigs in the Georgia SSR. Gruzinskogo Zootehničeskie Veterinary Ucheno Issledovaniya 39, 320-322
- Loskot V.I., Voronov A.N., Semenov L.D., 1988** - Parasitoses of pigs in breeding herds and fattening houses. Sbornik Nauchnykh Trudov Leningradski Veterinarny Institut, 94, 45-48
- Marruchella G., Paoletti B., Speranza R., Di Guardo G., 2012** - Fatal bronchopneumonia in a *Metastrongylus elongatus* and Porcine circovirus type 2 co-infected pig. Research in Veterinary Science, 93,310–312.
- Nagy G., Varga G., Csivincsik A., Sugar L. 2013** - Occurrence of *Metastrongylus asymmetricus* (Noda, 1973) in Hungary. Magyar Allatorvosok Lapja, 135,308–312.
- Nakauchi K., Nakajima H., Okabe M., Nakajima M., 1991** - Parasitological and pathological findings in marginal emphysema of pig lungs. Journal of Japan Veterinary Medicine Association, 44, 248-251.
- Pavlović I., Lončarević A., Ivetić V., Kulišić Z., Markić Z., Tosevski J., 1995** - Sort and distribution of parasitary infestation in swine farms breeding. Macedonian Veterinary Review, 24 (1-2), 69-72
- Pavlović I., Kulišić Z., Mišić Z., 2005a** - Lumbricidae – prelazni domaćini metastrongilida svinja. Veterinarski glasnik, 59 (5-6), 521-527.
- Pavlović I., Hudina V., Pupavac S., Stevanović Đ., Kulišić Z., Stevanović S., 2005b** - Metastrongilidoza svinja. Zbornik naučnih radova Instituta PKB Agroekonomik, 2005, 11 (3-4), 133-141.
- Pavlović I., Ivetić V., Savić B., Žutić M., Radanović O., 2009** - Aktuelne parazitske bolesti u svinjarskoj proizvodnji. Zbornik radova Sedmi simpozijum Zdravstvena zaštita, selekcija i reprodukcija svinja, Srebrno Jezero, 53-56.

- Pavlović I., Savić B., Rogožarski D., Hadžić I., Bojkovski J., Ivetić V., Radanović O., Žutić M., Kulišić Z., 2011** - *Parazitska fauna svinja u ekstenzivnom držanju*. Zbornik radova Deveti simpozijumi zdravstvena zaštita, selekcija i reprodukcija svinja sa međunarodnim učešćem Srebrno jezero, 56-61.
- Pavlović I., Savić B., Rogožarski D., Bojkovski J., Ivetić V., Martinov R., 2012** - *Uticaj parazita u nastanku respiratornih oboljenja svinja - predlog rešenja*. Zbornik radova desetog simpozijuma zdravstvena zaštita, selekcija i reprodukcija svinja sa međunarodnim učešćem (načini rešavanja respiratornih problema tovljenika), Srebrno jezero, 30-33.
- Pavlović I., Savić B., Rogožarski D., Bojkovski J., Ivetić V., Radnović O., Žutić M., Stokić-Nikolić S., Jezdimirović N., Cvetojević Đ., 2013** - *Parasites fauna of swine in organic breeding*. Contemporary Agriculture, 62, 1-2, 118-126.
- Pavlović I., Rogožarski D., Savić B., Kureljušić B., Dobrosavljević I., Stokić-Nikolić S., Bojkovski J., Jovčevski Sr., Jovčevski S., Radanović O., 2017** - *Helmitoze svinja u slobodnom držanju*. Zbornik radova 15 simpozijuma Zdravstvena zaštita, selekcija, i reprodukcija svinja sa međunarodnim učešćem, Srebrno jezero, 63-68.
- Sasaki O., Katsuno M., 1983** - *Leukocyte chemotactic factors in soiluble extracts of Metastrongylus apri at different stage*. Journal of Japany Veterinary Medicine Association, 45, 807-809.
- Singh B.B., Kazadi L., Welu M., Muhigirwa S.S., 1989** - *An epidemiological survey of swine metastrongylosis and its impact on the growth of piglets in the Kivu region (Zaire)*. Revue de Médecine Vétérinaire, 140, 611-615.
- Serra Freire N.M., Siqueira L.F.G., Consorte L.B.S., 1982** - *Incidence of species of Metastrongylus (Nematoda: Protostrongylidae) in swine from the State of parana, Brazil*. Arquivos da Universidade Federal Rural do Rio de Janeiro, 5, 111-114.
- Shope R.E., 1941** - *The swine lungworm as a reservoir and intermediate host for swine influenza virus : II. The transmission of swine influenza virus by the swine lungworm*. Journal of Experimental Medicine, 74(1), 49-68.
- Shope R.E., 1958** - *The swine lungworm as a reservoir and intermediate host for hog cholera virus. II. Attempts to demonstrate the presence of hog cholera virus in lungworms derived from swine with cholera*. Journal of Experimental Medicine, 108(1), 159-69.
- Spieler N., Schnyder M., 2021** - *Lungworms (Metastrongylus spp.) and intestinal parasitic stages of two separated Swiss wild boar populations north and south of the Alps: Similar parasite spectrum with regional idiosyncrasies*. International Journal for Parasitology: Parasites and Wildlife, 14, 202–210.
- Soulsby E.J.L., 1977** - *Helminths, Arthropods and Protozoa of Domesticated Animals*. Baillier Tindall and Cassell ed. London.
- Šabec D., 2002** - *Barvani atlas o bolesti prašičev / A color atlas of swine diseases*, Littera picta doo, Ljubljana.
- Tričković D., 1978** - *Prilog poznavanju metastrongiloze u svinja na terenu opštine Knjaževac*. specijalistički rad, Fakultet veterinarske medicine u Beogradu,
- Ueno H., Lee B.D., Watanabe S., Fujita J., 1960** - *Spontaneous liberation of infective larvae from the earthworm Eisenia foetida infected Metastrongylus apri*, National Institute of Animal Health, 6, 89.
- Vanparijs O., Thienpont D., 1982** - *The earthworm Eisenia foetida as intermediate host for artificial infection of pigs with Metastrongylus apri and treatment with flubendazole*. Parasitology, 84, R-45.
- Yoshihara S., Nakagawa M., Suda H., Taira N., 1990** - *White spots on the liver in pigs experimentally infected with Metastrongylus apri*, Japanes Journal of Parasitology, 39, 365-368.