

University of Texas Rio Grande Valley

ScholarWorks @ UTRGV

School of Medicine Publications and
Presentations

School of Medicine

11-2022

Rituximab for steroid-resistant organising pneumonia in a woman with rheumatoid arthritis

Christine E. Loftis

Emilia C. Dulgheru

Adolfo Kaplan

Follow this and additional works at: https://scholarworks.utrgv.edu/som_pub



Part of the [Medicine and Health Sciences Commons](#)



OPEN ACCESS

Rituximab for steroid-resistant organising pneumonia in a woman with rheumatoid arthritis

Christine Elizabeth Loftis ,¹ Emilia Dulgheru,² Adolfo Kaplan³

¹Internal Medicine, The University of Texas Rio Grande Valley School of Medicine, Edinburg, Texas, USA

²Rheumatology Institute at Doctors Hospital at Renaissance, Edinburg, Texas, USA

³Pulmonary and Sleep Center of the Valley, McAllen, Texas, USA

Correspondence to

Dr Christine Elizabeth Loftis; Christine.Loftis01@utrgv.edu

Accepted 14 October 2022

SUMMARY

Organising pneumonia (OP) is a form of interstitial pneumonia characterised by inflammation and scarring leading to obstruction within the small airways and alveoli. Practice guidelines recommend treatment of moderate to severe OP with glucocorticoids; however, there have been cases of steroid-resistant OP successfully treated with rituximab. We describe a case of a woman in her 20s with rheumatoid arthritis who presented with pleuritic chest pain, haemoptysis and dyspnoea on exertion and was diagnosed with OP after multiple radiographic images and biopsies. The patient failed numerous treatment regimens, including corticosteroids, antibiotics and mycophenolate, but was successfully treated with rituximab. This case highlights the importance of identifying new therapeutic agents that will minimise the use of glucocorticoids in the treatment of OP.

BACKGROUND

Organising pneumonia (OP) is a form of interstitial pneumonia characterised by inflammation and scarring that leads to obstruction within the small airways and alveoli.¹ OP usually affects individuals in the fifth or sixth decade of life and typically manifests as acute symptoms of non-productive cough, dyspnoea, fever, malaise and weight loss that generally persists for weeks to months.² The underlying cause of the condition is unknown however it is thought to be a consequence of epithelial injury to alveoli leading to protein leakage, fibroblast recruitment and subsequent fibrin formation within the lumen of alveoli.³⁻⁵ Since there have been few randomised controlled trials, treatment is based on practice guidelines. Current practice guidelines recommend no treatment for mild cases of OP and recommend glucocorticoids for moderate to severe cases of OP.⁶⁻⁹ In patients with steroid-resistant disease, cytotoxic agents such as cyclophosphamide along with macrolides are recommended, however, there have been reported cases of steroid-resistant OP successfully treated with rituximab.⁴ Here, we illustrate a case of OP in a woman in her 20s presenting as haemoptysis and multiple lung nodules on imaging that was successfully treated with rituximab after minimal improvement with combination of glucocorticoids and antibiotics.

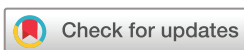CASE PRESENTATION

A young woman in her 20s with a history of juvenile idiopathic arthritis (JIA) diagnosed at 14 presented to the rheumatology clinic with haemoptysis that progressively worsened over a 1-week

period. The patient's diagnosis of JIA was made at 14 when she presented with polyarticular joint pain primarily affecting her right shoulder, right elbow, right knee, bilateral wrists and bilateral hands. The patient initially believed that the arthritis was due to overuse injuries because she was very active in soccer; however, when she began to develop synovitis and joint swelling, the patient was referred to a rheumatologist. The patient's laboratory workup revealed a negative rheumatoid factor and antinuclear antibodies with high titre positive anti-cyclic citrullinated peptide antibody >250 units/mL (reference range less than 20 units/mL). She was initially treated with methotrexate 20 mg subcutaneously weekly and etanercept 50 mg subcutaneously once weekly. The patient's symptoms drastically improved on this regimen; however, the patient missed her follow-up appointments and had intermittent care up until the current visit. On her current presentation, she endorsed pleuritic chest pain and mild dyspnoea on exertion that had been present since onset of haemoptysis. In the past, the patient was diagnosed with pulmonary nodules in bilateral lung fields which spontaneously resolved dating back 3 years prior to current presentation. Her vital signs showed a temperature of 37.3°C, a blood pressure 138/88 mmHg, a pulse oximetry saturation of 98% on room air and a respiratory rate of 18 breaths per minute. Her physical examination was notable for rhonchus breath sounds to bilateral lower lung fields, synovial thickening of metacarpophalangeal joint two and three of the left hand, and tenderness to proximal interphalangeal joints three and four bilaterally.

INVESTIGATIONS

The patient's laboratory findings are shown in table 1. Given the patient's symptoms, she had a chest X-ray performed which showed left perihilar opacities (figure 1), which warranted further investigation with a CT chest. CT of the chest revealed multiple bilateral basal lung nodules measuring up to 4.0 cm and a 1.2 cm consolidation noted at the lingula with few areas of ground glass opacities (figure 2). The patient had a transthoracic biopsy performed which revealed granulomatous inflammation with caseous necrosis with silver and mucin stains negative for fungi or acid-fast bacilli. Furthermore, immunoperoxidase staining for tuberculosis was negative. At that time, the patient was diagnosed with a granulomatous infection despite being unable to identify any specific organisms however when patient had repeat imaging performed 2 months later, the nodules had resolved (figure 3). In between visits, the patient had only been treated with



© BMJ Publishing Group Limited 2022. Re-use permitted under CC BY-NC. No commercial re-use. See rights and permissions. Published by BMJ.

To cite: Loftis CE, Dulgheru E, Kaplan A. *BMJ Case Rep* 2022;**15**:e249912. doi:10.1136/bcr-2022-249912

Table 1 Laboratory findings

Parameter	Finding	Reference range
WCC	12.5x10 ⁹ /L	<10.9 103 cells/ μ L
Haemoglobin	89 g/L	108–147 g/L
Platelet	613 x10 ⁹ /L	30–999 103 cells/ μ L
Creatinine	45.75 μ mol/L	<91.5 μ mol/L
Sedimentation rate	87 mm/hour	0–32 mm/hour
C reactive protein	12.4 mg/L	<10.0 mg/L
Antinuclear antibody	1:320	<1:80
C-ANCA	<1:20	<1:20
P-ANCA	1:2560	<1:20
Anti-myeloperoxidase antibody	<9.0 IU/mL	0–9 IU/mL
Anti-proteinase-3 antibody	<3.5 IU/mL	0–3.5 IU/mL
Rheumatoid factor	3 UI/dL	<20 UI/dL
Anti-citrullinated protein antibody	>250 units	<20

WCC, white cell count.

methotrexate 20mg orally weekly for baseline rheumatoid arthritis. Over the following few months her symptoms recurred with new pulmonary nodules on imaging (figure 4). During these episodes, the patient had a bronchoscopy with bronchoalveolar lavage which revealed negative cultures. She was treated with prednisone 40mg with decreasing doses over weeks, which did improve the symptoms briefly however the symptoms of haemoptysis and pleuritic chest pain began to recur more frequently and persist despite treatment. Ultimately, the patient underwent an open lung biopsy with results of pathology revealing very focal OP in which polypoid plugs of organising fibroblasts and myofibroblasts are situated within the lumens of distal airspaces. These findings were accompanied by a variably conspicuous chronic interstitial pneumonia in which alveolar septae and peri-bronchial interstitium are expanded by an infiltrate of predominantly mononuclear cells including lymphocytes and plasma cells. The foci of subpleural interstitial pneumonia are associated with foamy alveolar macrophages. There was no evidence of necrotising granulomatous inflammation identified (figures 5–7).

DIFFERENTIAL DIAGNOSIS

The patient presented with haemoptysis, pleuritic chest pain and radiographic imaging that revealed lung masses in the background of a diagnosis of rheumatoid arthritis. Given her symptoms, the list of differentials is vast, with the highest suspicion being for malignancy, infection, vasculitis, rheumatoid arthritis-associated interstitial lung disease (RA-ILD), rheumatoid nodules and OP. Our initial biopsy revealed no evidence of fungal or mycobacterial infection which ruled out infection as the cause of her symptoms. Similarly, there was no evidence of malignant cells on bronchoalveolar lavage or biopsy and given

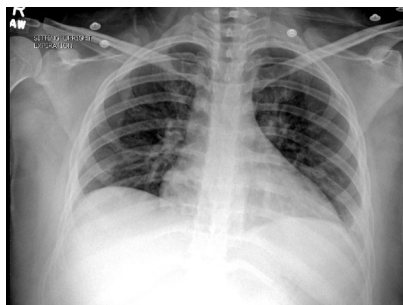


Figure 1 Chest X-Ray showing left perihilar opacities.

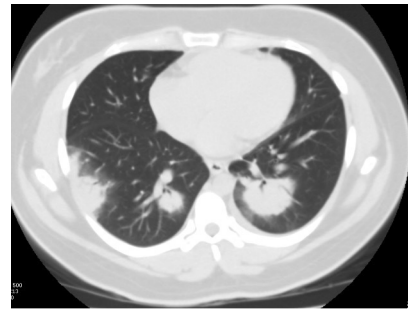


Figure 2 CT chest without contrast demonstrating multiple bilateral lung nodules measuring up to 4.0 cm and a 1.2 cm consolidation noted at the lingula with a few areas of ground glass opacities.

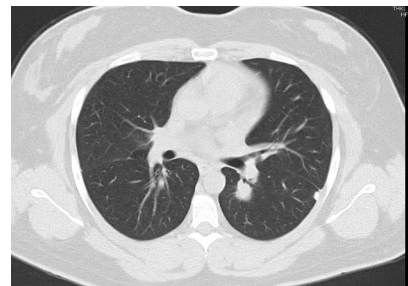


Figure 3 CT chest without contrast with improvement of bilateral basal lung nodules however persistent lingula consolidation.

the spontaneous resolution of the masses, malignancy was ruled out. The diagnosis of vasculitis was entertained especially given the high titre P-ANCA 1:2560, however, myeloperoxidase and proteinase-3 were negative, and the patient never presented with constitutional symptoms. The presence of P-ANCA, regardless of the titre, without the appropriate clinical context and MPO antibody positivity is non-specific and can be seen in other rheumatological and non-rheumatological conditions. The most common histopathological subtype of RA-ILD is usual interstitial pneumonia (UIP).¹⁰ The risk factors for RA-ILD include male gender, older age, cigarette smoking and more severe and active RA.¹¹ The typical findings on high-resolution CT include subpleural, bibasilar reticular opacities associated with honeycomb changes and traction bronchiectasis. The histopathology will show areas of normal lung alternating with interstitial inflammation, fibroblast foci, and honeycomb changes.¹² Our patient did not meet any of the abovementioned risk factors except for more severe RA and did not have characteristic imaging or histopathologic findings to meet criteria for the diagnosis of UIP.

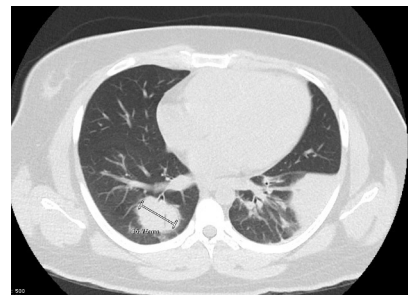


Figure 4 CT chest without contrast with multiple basilar nodules with the largest measuring 6.3 cm, worse than previous CT chest.

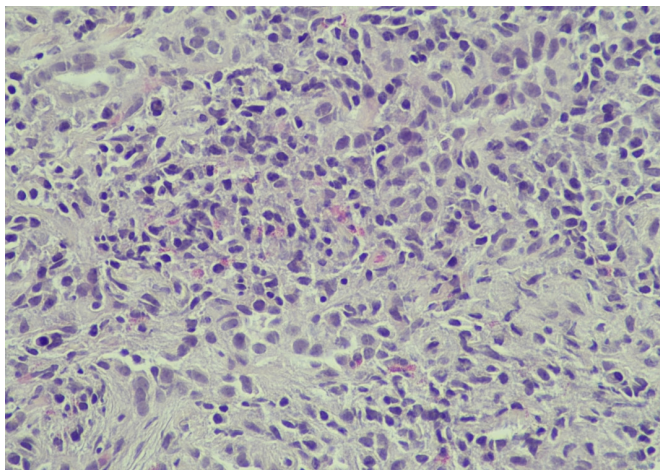


Figure 5 H&E biopsy pleura demonstrating foamy alveolar macrophages within the subpleural interstitium.

Lastly, rheumatoid lung nodules are specific to the diagnosis of RA and are typically asymptomatic. These nodules can be single or multiple and are typically located in subpleural areas or interlobular septa and can range from millimetres to several centimetres in size.^{13 14} These nodules can cavitate and rupture, resulting in infection, haemoptysis and effusions. The histopathology of these nodules demonstrates central necrosis, palisading epithelioid cell, mononuclear cell infiltrate and vasculitis.^{15 16} Although this was one of the differentials in our patient, histopathology did not correlate with the expected findings. Based on the biopsy results, the recurrent and spontaneous nature of the pulmonary nodules, and the patient's history of rheumatoid arthritis, a diagnosis of OP was made.

TREATMENT

Given the diagnosis of OP, the patient was started on a course of prednisone 60 mg daily with a decreasing taper dose over the subsequent weeks along with clarithromycin 250 mg two times per day for several months. During this time, mycophenolate 2.0 g daily was added to the corticosteroids, however, the patient could not have the dose decreased below prednisone 20 mg daily

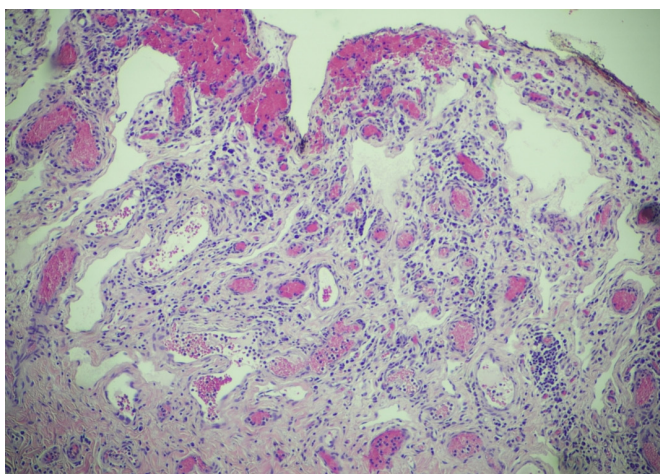


Figure 6 A ×10 H&E wedge biopsy left lower lung demonstrating polypoid plugs of organising fibroblasts and myofibroblasts situated within the lumens of distal airspace with associated lymphocytes and plasma cells within alveolar septae and peribronchial interstitium.

without recurrence of haemoptysis and pleuritic chest pain. Due to being on a prolonged course of prednisone, she began to have glucocorticoid toxicity including a 20 lb weight gain, non-alcoholic fatty liver disease and secondary diabetes mellitus. At that point in time, due to her persistent symptoms, failure of treatment with steroids and anecdotal cases in the literature, the patient was started on rituximab 1000 mg for two doses, followed by an additional dose 6 months later as per rheumatoid arthritis protocol.⁴

OUTCOME AND FOLLOW-UP

The patient has been in remission for 8 months without any new episodes of haemoptysis, chest pain or radiologic findings on imaging (figure 8). She is no longer taking steroids or immunosuppressive agents.

DISCUSSION

In this discussion, we will focus on the current practice guidelines and diagnostic criteria of OP, highlight cases of OP treated with rituximab from the literature, and explain our rationale for deviating from standard of therapy.

OP is a diagnosis of exclusion and should be suspected given the appropriate clinical context and characteristic symptoms. Diagnostic imaging such as CT, chest X-ray and lung biopsy with histopathological findings of intra-alveolar buds of granulation tissue, consisting of intermixed myofibroblasts and connective tissue with or without

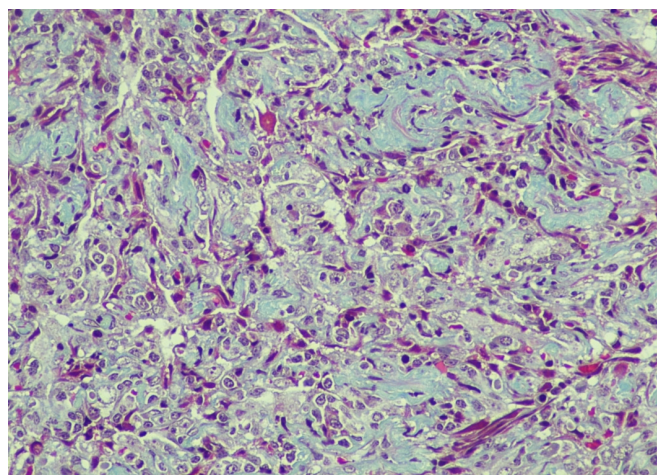


Figure 7 A ×40 H&E wedge biopsy left lower lung demonstrating polypoid plugs of organising fibroblasts and myofibroblasts situated within the lumens of distal airspace with associated lymphocytes and plasma cells within alveolar septae and peribronchial interstitium.

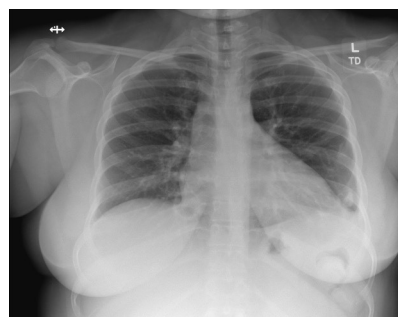


Figure 8 CXR with improvement of perihilar opacities, no new or worsening infiltrates noted.

bronchial intraluminal polyps help confirm the diagnosis.^{3 4 17} The current practice guidelines base treatment on the severity of the presentation. Patients with mild symptoms and minimal radiographic changes are likely to have resolution of symptoms without pharmacological intervention, however, if symptoms worsen at any point throughout the clinical course, treatment should be initiated.⁹ Patients with mild to moderate disease can be treated with clarithromycin as per case reports, however, macrolide therapy has been shown to be less effective than glucocorticoid therapy based on long-term retrospective studies.^{6–9} For patients with worsening and severe symptoms, glucocorticoid therapy is standard of care. The initial dose is typically 0.75–1.0 mg/kg per day per ideal body weight as per British Thoracic Society guidelines.¹² The initial dose should be continued for 1–2 months and if the symptoms remain stable or improve, a steroids should be decreased over the next 4–6 weeks and the discontinuation of steroids should be achieved by 6 months. Unfortunately, relapses are common in OP and many patients will fail to respond to corticosteroid therapy. In these cases, there are no specific guidelines on the correct approach to treatment. Anecdotal evidence suggests the use of cyclophosphamide or cyclosporine in the treatment of OP when steroid resistant occurs however there have been cases of successful treatment with rituximab.^{4 18 19}

In reviewing the literature, we identified one article that discussed the successful treatment of OP with Rituximab. Shitenberg *et al* reported four patients with biopsy proven OP who were successfully treated with Rituximab. The patients that he identified were Caucasian, between 54 and 82 years of age, and did not report underlying connective tissue disease. Each of his patients had been on high dose corticosteroids without resolution of symptoms. With the addition of rituximab at 375 mg/BSA, one of the patients reached complete remission without the addition of any other cytotoxic or corticosteroid therapy. The remaining three patients had to continue steroid treatment to remain in remission however the steroids were maintained at much lower doses.⁴

The clinical presentation of our patient was atypical as she had haemoptysis along with chest pain as her initial symptomology. The literature reports that haemoptysis is an exceedingly rare presentation of OP and typical age of onset is between the fifth and sixth decade of life.^{12 20 21} Our patient presumably had radiographic findings in late adolescence before her 20s, however, she did not have a formal diagnosis until years later following multiple imaging studies and biopsies. The heterogeneity of OP highlights the importance of a very thorough clinical and diagnostic investigation to confirm the diagnosis. Our patient was treated with a combination of antibiotics and glucocorticoids for several months without complete resolution of symptoms. On the contrary, her symptoms began to recur more frequently and were more persistent. Despite the utilisation of steroid sparing agents such as mycophenolate, we were unable to decrease her prednisone below 20 mg daily and as a result, she developed significant side effects from steroid use. Previously, she failed multiple treatment regimens for rheumatoid arthritis including methotrexate and etanercept; thus, we did not feel that her condition would significantly improve on these agents despite literature suggesting appropriate clinical response to these agents in OP secondary to rheumatoid arthritis.²² Throughout her clinical course, her rheumatoid arthritis was intermittently flaring, and we wanted to use an agent that would target both diseases. Our suspicion was that if we controlled her underlying connective tissue disease, we could alleviate the symptoms of OP. Despite the scarcity of cases in the literature regarding treatment of OP with rituximab, we felt that our patient would benefit from this therapeutic avenue. As predicted, the patient was successfully treated with rituximab. Of note, it is essential to mention that there have been reported cases of rituximab-induced OP.^{23 24} The exact mechanism is not well established; however, risk

Patient's perspective

As a mother, I was initially reluctant to have invasive diagnostic testing or start aggressive treatment. After some time, my condition began to interfere with my activities of daily living which prompted me to agree to further testing and treatment. After successfully being treated, I am considering a career in medicine.

Learning points

- ▶ Pulmonary nodules in the setting of rheumatoid arthritis give rise to a vast differential diagnosis.
- ▶ P-ANCA, in the absence of myeloperoxidase antibodies, is non-specific for vasculitis.
- ▶ Although commonly seen in the fifth and sixth decade of life, organising pneumonia (OP) can be seen in younger patients with an underlying connective tissue disease.
- ▶ Patients with glucocorticoid-resistant OP can be successfully treated with rituximab in the appropriate clinical setting.

factors include recurrent exposure to rituximab and concurrent rituximab and granulocyte colony-stimulating factor.²⁵ We believe this case highlights the importance of further studies on the role of CD-20 inhibition in the treatment of OP.

Acknowledgements We wish to extend a special thanks to Trina Sciuotto and Andrew Salinas for their helpful suggestions.

Contributors CEL, ED and AK were all involved in the patient's care. ED was responsible for the case presentation write up and AK was responsible for reviewing the images. CEL was in charge of literature review and discussion. All three physicians worked on the teaching points, background and summary. The final manuscript was reviewed by all physicians and final draft was approved by all.

Funding The authors have not declared a specific grant for this research from any funding agency in the public, commercial or not-for-profit sectors.

Competing interests None declared.

Patient consent for publication Consent obtained directly from patient(s).

Provenance and peer review Not commissioned; externally peer reviewed.

Open access This is an open access article distributed in accordance with the Creative Commons Attribution Non Commercial (CC BY-NC 4.0) license, which permits others to distribute, remix, adapt, build upon this work non-commercially, and license their derivative works on different terms, provided the original work is properly cited and the use is non-commercial. See: <http://creativecommons.org/licenses/by-nc/4.0/>.

Case reports provide a valuable learning resource for the scientific community and can indicate areas of interest for future research. They should not be used in isolation to guide treatment choices or public health policy.

ORCID iD

Christine Elizabeth Loftis <http://orcid.org/0000-0001-6597-7996>

REFERENCES

- 1 Myers JL, Katzenstein AL. Ultrastructural evidence of alveolar epithelial injury in idiopathic bronchiolitis obliterans-organizing pneumonia. *Am J Pathol* 1988;132:102–9.
- 2 King TE. Organizing pneumonia. In: Schwarz MI, King TE, eds. *Interstitial lung disease*. 5. Shelton, CT: People's Medical Publishing House, 2011: 5. 981.
- 3 Cordier J-F. Cryptogenic organizing pneumonia. *Clin Chest Med* 2004;25:727–38.

- 4 Shitenberg D, Fruchter O, Fridel L, *et al.* Successful rituximab therapy in steroid-resistant, cryptogenic organizing pneumonia: a case series. *Respiration* 2015;90:155–9.
- 5 Raghu G, Meyer KC. Cryptogenic organising pneumonia: current understanding of an enigmatic lung disease. *Eur Respir Rev* 2021;30:210094.
- 6 Radzikowska E, Wiatr E, Langfort R, *et al.* Cryptogenic organizing pneumonia—results of treatment with clarithromycin versus corticosteroids—observational study. *PLoS One* 2017;12:e0184739.
- 7 Radzikowska E, Wiatr E, Gawryluk D, *et al.* Organizujące się zapalenie płuc—leczenie klarytromycyna [Organizing pneumonia—clarithromycin treatment]. *Pneumonol Alergol Pol* 2008;76:334–9.
- 8 Vaz AP, Morais A, Melo N. Azitromicina como terapêutica adjuvante na pneumonia organizativa criptogénica [Azithromycin as an adjuvant therapy in cryptogenic organizing pneumonia]. *Rev Port Pneumol* 2011;17:186–9.
- 9 Ichikawa Y, Ninomiya H, Katsuki M, *et al.* Low-dose/long-term erythromycin for treatment of bronchiolitis obliterans organizing pneumonia (BOOP). *Kurume Med J* 1993;40:65–7.
- 10 Kelly CA, Saravanan V, Nisar M, *et al.* Rheumatoid arthritis-related interstitial lung disease: associations, prognostic factors and physiological and radiological characteristics—a large multicentre UK study. *Rheumatology* 2014;53:1676–82.
- 11 Tanaka N, Kim JS, Newell JD, *et al.* Rheumatoid arthritis-related lung diseases: CT findings. *Radiology* 2004;232:81–91.
- 12 Bradley B, Branley HM, Egan JJ, *et al.* Interstitial lung disease guideline: the British thoracic society in collaboration with the thoracic society of Australia and New Zealand and the Irish thoracic society. *Thorax* 2008;63 Suppl 5:v1-58.
- 13 Lee H-K, Kim DS, Yoo B, *et al.* Histopathologic pattern and clinical features of rheumatoid arthritis-associated interstitial lung disease. *Chest* 2005;127:2019–27.
- 14 Rabeyrin M, Thivolet F, Ferretti GR, *et al.* Usual interstitial pneumonia end-stage features from explants with radiologic and pathological correlations. *Ann Diagn Pathol* 2015;19:269–76.
- 15 Gupta P, Ponzio F, Kramer EL. Fluorodeoxyglucose (FDG) uptake in pulmonary rheumatoid nodules. *Clin Rheumatol* 2005;24:402–5.
- 16 Yousem SA, Colby TV, Carrington CB. Lung biopsy in rheumatoid arthritis. *Am Rev Respir Dis* 1985;131:770–7.
- 17 King TE Jr. Cryptogenic organizing pneumonia; 2014 [Accessed 16 July 2015].
- 18 Purcell IF, Bourke SJ, Marshall SM. Cyclophosphamide in severe steroid-resistant bronchiolitis obliterans organizing pneumonia. *Respir Med* 1997;91:175–7.
- 19 Lee J, Cha SI, Park TI, *et al.* Adjunctive effects of cyclosporine and macrolide in rapidly progressive cryptogenic organizing pneumonia with no prompt response to steroid. *Intern Med* 2011;50:475–9.
- 20 Mroz BJ, Sexauer WP, Meade A, *et al.* Hemoptysis as the presenting symptom in bronchiolitis obliterans organizing pneumonia. *Chest* 1997;111:1775–8.
- 21 Shen L, Liu J, Huang L, *et al.* Cryptogenic organizing pneumonia presenting as a solitary mass: clinical, imaging, and pathologic features. *Med Sci Monit* 2019;25:466–74.
- 22 Mori S, Koga Y, Sugimoto M. Organizing pneumonia in rheumatoid arthritis patients: a case-based review. *Clin Med Insights Circ Respir Pulm Med* 2015;9:CCRPM.S23327.
- 23 Maeng CH, Chin SO, Yang BH, *et al.* A case of organizing pneumonia associated with rituximab. *Cancer Res Treat* 2007;39:88–91.
- 24 Biehn SE, Kirk D, Rivera MP, *et al.* Bronchiolitis obliterans with organizing pneumonia after rituximab therapy for non-hodgkin's lymphoma. *Hematol Oncol* 2006;24:234–7.
- 25 Macartney C, Burke E, Elborn S, *et al.* Bronchiolitis obliterans organizing pneumonia in a patient with non-Hodgkin's lymphoma following R-CHOP and PEGylated filgrastim. *Leuk Lymphoma* 2005;46:1523–6.

Copyright 2022 BMJ Publishing Group. All rights reserved. For permission to reuse any of this content visit <https://www.bmj.com/company/products-services/rights-and-licensing/permissions/>
BMJ Case Report Fellows may re-use this article for personal use and teaching without any further permission.

Become a Fellow of BMJ Case Reports today and you can:

- ▶ Submit as many cases as you like
- ▶ Enjoy fast sympathetic peer review and rapid publication of accepted articles
- ▶ Access all the published articles
- ▶ Re-use any of the published material for personal use and teaching without further permission

Customer Service

If you have any further queries about your subscription, please contact our customer services team on +44 (0) 207111 1105 or via email at support@bmj.com.

Visit casereports.bmj.com for more articles like this and to become a Fellow