

Management challenges of disorders of sex development- Case Series

Authors: B. Tuyishimire^{1,2}; H. Irere^{1,2}; F. Rutagarama²; A. Ndatinya²; O.R. Karangwa²; A. Gasana²; C. Nsanabaganwa¹; L. Mutesa^{1,*}

Affiliations: ¹Center for Human Genetics, College of Medicine and Health Sciences, University of Rwanda; Kigali, Rwanda; ²Rwanda Military Hospital, Kigali, Rwanda

ABSTRACT

INTRODUCTION: Disorders of sex development (DSDs) are genetic abnormalities characterized by discordance between phenotypic, gonadal, and genetic sex. They are grouped into two categories based on karyotype: 46, XX DSD and 46, XY DSD.

CASES: We reviewed two patients referred to the Rwanda Military Hospital genetic unit. The first patient was a 3-year-old toddler who was referred for confusing sex organs. Physical examination showed ambiguous genital organs with hypospadias and micropenis. Pelvic examination showed a swelling solid mass that leading to a suspicion of ovary or undescended testes or combined ovary and testes (ovotestes). The second patient was a 17 years old teenager who presented with primary amenorrhea and lack of female secondary sexual characteristics at her age. The karyotype test was performed to investigate the genotypic sex of the patients and results revealed the karyotype formula of 46, XX/XY indicating the presence of two cell lines in the patient for the toddler and 46XYinv9 (p11q13) indicating the mismatch between the genotype and phenotype of the patients for the teenager.

CONCLUSION: Patients were diagnosed with Disorder of Sex Development with 46, XX/XY and 46, XY genotypes respectively. A multidisciplinary team of a geneticist, urologist, endocrinologist and a psychologist reviewed the patient for the effective management.

Keywords: Disorders of sex development, Genotype, Phenotype, Karyotype, Chromosome, Hypospadias, Chimerism

INTRODUCTION

Disorders of Sex Development (DSD) are defined as a condition in which chromosomal sex is inconsistent with phenotypic sex, or in which the phenotype is not classifiable as either male or female. Mutations in genes present in X and Y chromosomes can cause abnormalities of testis

determination leading to DSD [1]. Those Disorders are a group of rare conditions that usually present with atypical genitalia in the newborns or as delayed puberty in an adolescents [2]. DSDs have been classified into:

The first class: 46 XY DSD due to gonadal dysgenesis and consists of a variety of clinical conditions in which the fetal gonad development is abnormal

***Corresponding author:** Leon Mutesa, MD, PhD, Center for Human Genetics, College of Medicine and Health Sciences, The University of Rwanda; Kigali, Rwanda, Email: lmutesa@gmail.com; **Potential Conflicts of Interest (CoI):** All authors: no potential conflicts of interest disclosed; **Funding:** All authors: no funding was disclosed; **Academic Integrity.** All authors confirm that they have made substantial academic contributions to this manuscript as defined by the ICMJE; **Ethics of human subject participation:** The study was approved by the local Institutional Review Board. Informed consent was sought and gained where applicable; **Originality:** All authors: this manuscript is original has not been published elsewhere; **Review:** This manuscript was peer-reviewed by three reviewers in a double-blind review process;

Received: 02nd August 2022; **Initial decision given:** 25th September 2022; **Revised manuscript received:** 29th September 2022; **Accepted:** 29th September 2022.

Copyright: © The Author(s). This is an Open Access article distributed under the terms of the Creative Commons Attribution License (CC BY-NC-ND) ([click here](https://creativecommons.org/licenses/by-nc-nd/4.0/)) which permits unrestricted use, distribution, and reproduction in any medium, provided the original work is properly cited. **Publisher:** Rwanda Biomedical Centre (RBC)/Rwanda Health Communication Center, P. O. Box 4586, Kigali. ISSN: 2079-097X (print); 2410-8626 (online)

Citation for this article: B. Tuyishimire; C. Nsanabaganwa; L. Mutesa. Management challenges of disorders of sex development- Case Series. Rwanda Medical Journal, Vol. 79, no. 3, pp. 9-13, 2022. <https://dx.doi.org/10.4314/rmj.v79i3.9>

and can be further classified in complete and partial forms. The complete form is characterized by female external and internal genitalia, lack of secondary sexual characteristics, normal or tall stature and the presence of bilateral dysgenetic gonads. The partial form of this syndrome is characterized by impaired testicular development that results in patients with ambiguous external genitalia with or without Mullerian structure [3].

The second class: Congenital Adrenal Hyperplasia (CAH), which is a 46XX disorder of sex development in which phenotypically male individuals present 46XX genotype [4]. It is a family of autosomal recessive disorders characterized by the inability of the body to synthesize cortisol, and in most of cases, the inability to synthesize the salt-retaining hormone called aldosterone. The most common form of congenital adrenal hyperplasia is caused by inadequate quantity of the adrenal enzyme 21-hydroxylase (21-OH) and is identified by assessing the level of 17-alpha hydroxyprogesterone (17-OHP) in blood. CAH is in most of the cases the cause of ambiguous genitalia in females, and can cause acute life-threatening adrenal crisis in both males and females in the neonatal period [5].

In few cases DSD is caused by two distinct cell lines genetically present in an organism arising from two or more zygotes. This condition is recognized as a chimera. In humans, true chimeras always result a wide range of degrees of cell duality in different body tissue and it is suspected clinical in patients with disorders of sex development with ambiguous genitalia. it may also be suspected in cases of abnormal karyotypes as well as abnormalities in blood typing results [6].

In humans, when it affects sex chromosomes it is called sex chromosome-discordant 46, XX/46, XY chimeras. The phenotypic spectrum of 46, XX/46, XY chimeric patients is variable ranging from normal male or female genitalia to different degrees of ambiguous genitalia [7]. The sex chromosome-discordant chimeras 46,XX/46,XY is a rare condition found in humans with mostly with a phenotypically normal appearance, and sometimes ambiguous genital organs. This lack of phenotypic changes and the rarity of chimeras make it difficult to identify its exact incidence [8].

Patient 1

A 3 year old patient was referred to genetics

unit of the Rwanda military Hospital with chief complaint of confusing genital organs. Physical examination showed ambiguous genital organs with hypospadias and micropenis, with pelvic solid mass leading to the suspicion of ovary or undescended testes or combined ovary and testes (ovotestes).

The Karyotyping test showed the co-existence of both 46XX/XY cell lines in the same cell (Figure 1).



Figure 1: Karyotype of the patient showing the co-existence of both 46XX/XY cell lines in the same cell

Endocrinology investigations showed normal estradiol and follicle stimulating hormones and decreased levels of luteinizing and testosterone hormones (Table 1).

Based on the results from karyotype examinations and the phenotypic sex appearances, the patient was diagnosed with a DSD with Dispermic chimerism

The patient was referred to endocrinologist and urologist. Due to ambiguous genital organs, the parents of the patient decided to raise him as male since genital organs were more dominant. Urologist did hypospadias repair with the purpose of restoring functional genital anatomy, minimizing future urological complications related to abnormal genito-urinary anatomy, such as urinary

Table 1: Results of endocrinology investigations

HORMONE (Unit)	NORMAL RANGE	QUANTITY FOR PATIENT
ESTRADIOL (pg/ml)	[7.63-42.6]	33.24
FSH (mIU/ml)	[0.11-198]	0.445
19117 LH (mIU/ml)	[0.27-198]	0.100
TESTOSTERONE (ng/ml)	[3.92-7.28]	0.025

LH: Luteinizing hormone; FSH: Follicle stimulating hormone

tract infections, and urinary incontinence. The patient was scheduled to be reviewed once every year to evaluate the progress and effectiveness of the treatment.

Patient 2

A 17-year-old female patient came to the Rwanda Military Hospital complaining of the lack of menses at her age. Physical examinations showed that the patient had no female secondary sexual characteristics. She had no breast and nipple enlargements, had little pubic hair, no widening of hips and lower waist, and her elbows weren't hyperextended. The patient had also heavier skull and bone structure, broadening of shoulders and chest. Genital examination showed that the patient has female external genital organs with labia minora and inner tips of the vulva that not did not grow more prominent and did not change in colour (Figure 2).

Results from karyotype examinations showed that a patient had male karyotype (46XY) while echography showed that the patient has neither uterus nor undescended testicles (Figure 3).

Basing on the phenotype and genotype, the patient was diagnosed with Complete Androgen Insensitivity Syndrome with Pericentric Inversion of Chromosome 9 (inv[9][p11q13])

We did genetic counselling to provide information related to genotypic sex of the patient. Counselling also aimed at managing emotional distress of the patients and their caretakers as well as to give the information regarding available treatment. After genetic counselling, the patient was referred to endocrinologist for stimulating female sex hormones with respect to the phenotypic sex appearance to help develop female secondary sexual characteristics. The patient is reviewed once in a year for evaluation of the hormonal treatment prescribed.

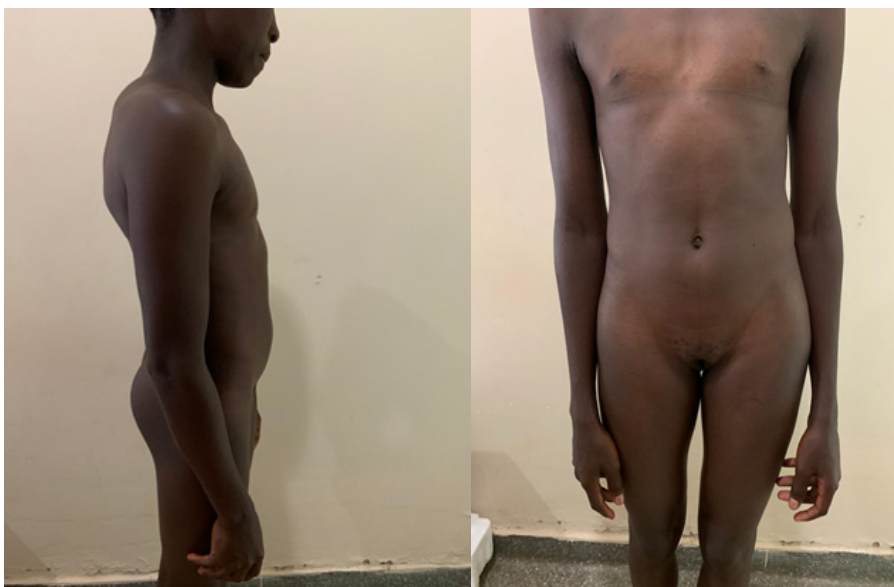

Figure 2: Male physical characteristics of the patient despite having female external genitalia

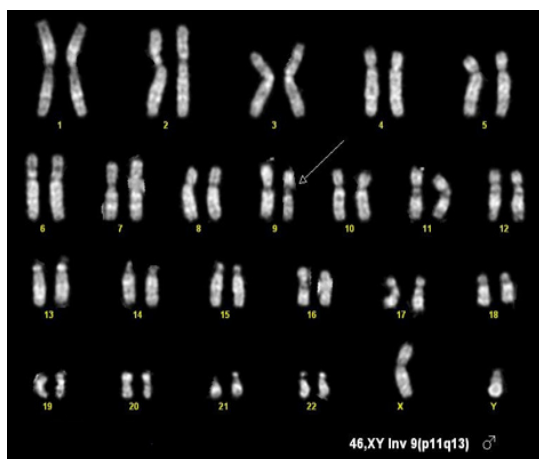


Figure 3: The karyotype formula of 46XYInv9 (p11q13)

Case management challenges

Gender development as somatic sex, gender identity, and gender role typically develop in accordance with each other. A newborn does not immediately have self-awareness of his or her sex and gender because such self-awareness evolves gradually during infancy, childhood and adolescence period. In the absence of harmony between aspects of sex and gender, few will reflect on their gender identity or gender role. As found in counseling sessions with the second patient, psychological and behavioral problems may rise in patients with DSD as the effect of facing sexual ambiguity, reproductive problems and self-placement in the society. This loss of identity leads to shame and social isolation or self-stigmatization and anxiety. We found that having a child with DSD is the source of family conflicts and misunderstandings among parents. Such conflicts lead to the delay in seeking help due to resignation of responsibilities for some parents. Caregivers of children with 46, XY and DSD, are at increased risk for elevated stress, anxiety and depression and child-focused stigma. All those psychosocial issues become challenges for healthcare providers since they lead to delay in consultation and diagnosis.

DISCUSSION

Different researchers have found that DSDs encompass heterogeneous group of congenital conditions associated with atypical development of internal and external genitalia generally attributed

to deviations from the typical progression of sex development [9,10]. Different studies have highlighted different features in the group of DSDs that are similar to the ones found in our patients, such as sex ambiguity and micropenis with varying degrees of gonadal dysgenesis [10].

DSDs present a mismatch between the genotype and phenotype of the individual. For instance, for Androgen insensitivity syndrome (AIS), individuals with 46, XY karyotype show female genital organs. This is further classified as complete form with female external genitalia and appearance, a partial form with a wide range of male features, and a mild form with only minor undervirilisation [11].

However, though the second patient was diagnosed with Androgen insensitivity Syndrome, her chromosomal formula shows additional abnormality of 46XYInv9 (p11q13). This inversion on chromosome 9, itself is the chromosomal abnormality which is not associated with abnormal phenotypes, but associated with subfertility and several miscarriages.

Interestingly, unlike most of the studies of 46 XX and 46 XY disorders of sex, the first patient was diagnosed with 46 XX/46XY named as dispermic chimeras. This is the sex chromosome-discordant condition infrequently found in humans and in most of the cases individuals with this condition are phenotypically normal [12]. However, in some cases, it leads to true hermaphroditism [13] as well as ambiguous genitalia as it was in our case [14].

The management of DSDs is done through surgical interventions with the purpose of the gender and biological sex assignment especially in the cases of ambiguous genitalia [15]. Different types of those surgical interventions have been highlighted by different researchers, including Clitoroplasty which is a cosmetic procedure designed to reduce the size of the clitoris whilst keeping male sex appearance. The other intervention is feminizing genital surgery, which encompasses clitoroplasty, and vaginoplasty as well as labioplasty. This procedure is mostly recommended in girls with CAH [16]. The procedure that was used for our patient is hypospadias repair, which is one of the more common operations in paediatric urology centers [17].

CONCLUSION

Different health professionals together reviewed the patient for better management of the two

patients diagnosed with different types of DSDs. While parents of the patients showed symptoms of depression and anxiety, counselling which aimed at providing adequate information of the disease including its pathophysiology and available management options and risks of recurrence for the future births proven to be helpful. It also helps burst myths and misconceptions, leading to improved patients' quality of life and successful management.

REFERENCES

- [1] S. Jahan, M. Abul Hasanat, F. Alam, M. Fariduddin, and T. Tofail, "Leydig Cell Hypoplasia: a Unique Paradox in the Diagnosis of 46,Xy Disorders of Sex Development," *AACE Clin. Case Reports*, vol. 6, no. 3, pp. e117–e122, 2020, doi: 10.4158/accr-2019-0152.
- [2] R. Röhle et al., "Participation of adults with disorders/differences of sex development (DSD) in the clinical study dsd-LIFE: Design, methodology, recruitment, data quality and study population," *BMC Endocr. Disord.*, vol. 17, no. 1, pp. 1–26, 2017, doi: 10.1186/s12902-017-0198-y.
- [3] S. Domenice et al., "Wide spectrum of NR5A1-related phenotypes in 46,XY and 46,XX individuals," *Birth Defects Res. Part C- Embryo Today Rev.*, vol. 108, no. 4, pp. 309–320, 2016, doi: 10.1002/bdrc.21145.
- [4] M. Terribile et al., "46,XX testicular disorder of sex development (DSD): A case report and systematic review," *Med.*, vol. 55, no. 7, pp. 1–13, 2019, doi: 10.3390/medicina55070371.
- [5] Y. Ganie, C. Aldous, Y. Balakrishna, and R. Wiersma, "Disorders of sex development in children in KwaZulu-Natal Durban South Africa : 20-year experience in a tertiary centre," vol. 30, no. 1, pp. 11–18, 2017, doi: 10.1515/jpem-2016-0152.
- [6] N. L. Draper, C. Conley, C. Smith, and K. Benson, "Dispermic chimerism identified during HLA typing for stem cell transplantation," *Transfusion*, vol. 48, no. 7, pp. 1398–1402, 2008, doi: 10.1111/j.1537-2995.2008.01711.x.
- [7] V. Malan et al., "Prenatal diagnosis and normal outcome of a 46,XX/46,XY chimera: A Case Report," *Hum. Reprod.*, vol. 22, no. 4, pp. 1037–1041, 2007, doi: 10.1093/humrep/del480.
- [8] E. J. Choi et al., "Clinical and Genetic Analysis of an Infertile Male with 46,XX/46,XY Chimerism," *Andrologia*, vol. 51, no. 3, pp. 1–9, 2019, doi: 10.1111/and.13215.
- [9] S. F. Witchel, "Congenital Adrenal Hyperplasia," *J. Pediatr. Adolesc. Gynecol.*, 2017, doi: 10.1016/j.jpag.2017.04.001.
- [10] P. Acién and M. Acién, *Disorders of sex development: Classification, review, and impact on fertility*, vol. 9, no. 11. 2020.
- [11] I. A. Hughes, J. D. Davies, T. I. Bunch, V. Pasterski, K. Mastroyannopoulou, and J. Macdougall, "Androgen insensitivity syndrome," *Lancet*, vol. 380, no. 9851, pp. 1419–1428, 2012, doi: 10.1016/S0140-6736(12)60071-3.
- [12] E. Schoenle et al., "46,XX/46,XY chimerism in a phenotypically normal man," *Hum. Genet.*, vol. 64, no. 1, pp. 86–89, 1983, doi: 10.1007/BF00289485.
- [13] M. S. Verp et al., "Chimerism as the etiology of a 46,XX/46,XY fertile true hermaphrodite," *Fertil. Steril.*, vol. 57, no. 2, pp. 346–349, 1992, doi: 10.1016/S0015-0282(16)54843-2.
- [14] R. Kawamura et al., "A case of a parthenogenetic 46,XX/46,XY chimera presenting ambiguous genitalia," *J. Hum. Genet.*, vol. 65, no. 8, pp. 705–709, 2020, doi: 10.1038/s10038-020-0748-4.
- [15] J. S. Barthold, "Disorders of sex differentiation: A pediatric urologist's perspective of new terminology and recommendations," *J. Urol.*, vol. 185, no. 2, pp. 393–400, 2011, doi: 10.1016/j.juro.2010.09.083.
- [16] S. Creighton, S. D. Chernausek, R. Romao, P. Ransley, and J. P. Salle, "Timing and nature of reconstructive surgery for disorders of sex development - Introduction," *J. Pediatr. Urol.*, vol. 8, no. 6, pp. 602–610, 2012, doi: 10.1016/j.jpuro.2012.10.001.
- [17] C. R. J. Woodhouse, "Hypospadias Surgery: an Illustrated Guide," *Eur. J. Plast. Surg.*, vol. 27, no. 4, 2004, doi: 10.1007/s00238-004-0627-9.