

Original Research Article

Diagnostic value of multi-slice spiral computed tomography after adiponectin treatment of tracheal malignancies

Jian Liu¹, Degui Zu², Ying Yang¹, Maosong Deng¹, Gang Deng¹, Xin Chang¹, Xiaoming Yin^{1*}

¹Department of Radiology, ²Department of Interventional, Emergency General Hospital, Beijing, China

*For correspondence: **Email:** yinxianchenlun9@126.com; **Tel:** +86-13611007150

Sent for review: 9 April 2022

Revised accepted: 24 September 2022

Abstract

Purpose: To determine the diagnostic value of multi-slice spiral computed tomography (CT) after adiponectin treatment of tracheal malignancies.

Methods: Sixty patients with tracheal malignancies admitted to Emergency General Hospital from February 2017 to February 2021 were assigned to the study group. After physical examination, 60 healthy subjects in the same period served as the control group. All patients were treated with adiponectin. The control group was subjected to serum tumor marker testing before and after treatment, while the study group received multi-slice spiral CT before and after adiponectin treatment.

Results: The 60 patients enrolled in the study group comprised 30 cases of squamous carcinoma, 22 cases of adenocarcinoma, and 8 cases of mucosa-associated lymphoma. Multi-slice spiral CT before treatment showed that 35 patients with tracheal malignant tumors had expansive lumen hyperplasia, while 25 patients with bulging tumors had saddle-like hyperplasia with irregular surfaces, uneven margins, and mean thickness of 5.96 ± 0.65 mm in the tracheal and bronchial walls adjacent to the luminal nodule. After treatment, the thickness of the tracheal and bronchial walls adjacent to the luminal nodule decreased to a mean value of 4.65 ± 0.48 mm. Prior to treatment, the mean enhancement value of contrast-enhanced CT was 18.98 ± 1.23 Hu, and mean tumor diameter was 3.68 ± 0.23 cm. However, after treatment, the mean enhancement value increased to 25.98 ± 1.44 Hu, while mean tumor diameter decreased to 2.54 ± 0.20 cm in the study group.

Conclusion: Multi-slice spiral CT has promising diagnostic value for patients with tracheal malignancies after adiponectin treatment. Therefore, it can potentially be used in the diagnosis of patients with tracheal malignancies.

Keywords: Multi-slice spiral CT, Adiponectin, Tracheal malignancy, Computed tomography (CT)

This is an Open Access article that uses a funding model which does not charge readers or their institutions for access and distributed under the terms of the Creative Commons Attribution License (<http://creativecommons.org/licenses/by/4.0>) and the Budapest Open Access Initiative (<http://www.budapestopenaccessinitiative.org/read>), which permit unrestricted use, distribution, and reproduction in any medium, provided the original work is properly credited.

Tropical Journal of Pharmaceutical Research is indexed by Science Citation Index (SciSearch), Scopus, Web of Science, Chemical Abstracts, Embase, Index Copernicus, EBSCO, African Index Medicus, JournalSeek, Journal Citation Reports/Science Edition, Directory of Open Access Journals (DOAJ), African Journal Online, Bioline International, Open-J-Gate and Pharmacy Abstracts

INTRODUCTION

Tracheal malignant tumors develop at the junction of the cartilaginous ring and the

membrane. The early stage of the disease presents symptoms such as irritating cough, shortness of breath, and dyspnea. At the advanced stage, the tumor cells usually

metastasize to the lung tissue and directly invade the esophagus and larynx, resulting in severe risk of death if treatment is delayed [1]. Currently, surgery is the preferred modality for the treatment of tracheal malignancies. Moreover, partial radiotherapy and chemotherapy are given to patients with unresectable advanced tumors or incompletely resected tumors, based on pathological types [2,3]. However, these patients usually exhibit poor tolerance and impaired immune function. Therefore, research has resulted in the additional provision of adiponectin therapy to patients [4]. This is aimed at enhancing the survival time of cytotoxic T cells, regulating the immunity of the patients, and exerting anti-tumor effects. Given that the survival of patients with tracheal malignancies is affected by various factors such as tumor stage, therapeutic drugs, and treatment modalities, close monitoring of the conditions of the patients after systemic treatment is still indispensable. At present, imaging examinations are mostly performed for disease monitoring in clinical practice [5].

Multi-slice spiral CT is a tumor diagnostic modality with wide applications. Its ability to acquire multi-slice images enables the physician to observe the patient's tracheal morphology from multiple perspectives such as the deformation, wall thickening, and luminal manifestations of the diseased segment of the trachea [6-8]. Based on review of extant literature, multi-slice spiral CT is used mainly for diagnosis of the early stage of tracheal malignancies. However, no studies have been carried out to investigate its diagnostic value for tracheal malignancies after adiponectin treatment.

Therefore, the present study was aimed at evaluating the clinical benefits associated with the application of multi-slice spiral CT after adiponectin treatment.

METHODS

Study design

This research was designed as a retrospective study, and carried out at Emergency General Hospital from February 2017 to February 2021. The aim was to investigate the clinical diagnostic value of multi-slice spiral CT after adiponectin treatment of tracheal malignancies. The study was set up at a double-blind level, with neither the study subjects nor the investigator being aware of the trial groupings. Moreover, the study designer was responsible for the arrangement and control of the entire trial.

Recruitment of study subjects

The data of patients with tracheal malignancies who were admitted to Emergency General Hospital from February 2017 to February 2021 were retrospectively analyzed.

Inclusion criteria

Patients who satisfied the following criteria were included in the study: (1) patients who were diagnosed with tracheal malignancy *via* pathological examination [9]; (2) patients who were treated in Emergency General Hospital only, without death, intermediate transfer, or discontinuation of treatment; (3) those with complete clinical data; (4) patients with expected survival period of more than 3 months, and (5) those who were diagnosed with tracheal malignancies for the first time.

Exclusion criteria

Patients in the following categories were excluded: (1) those who were unable to communicate due to impairment of hearing, language impairment, unconsciousness, or mental illness; (2) patients who withdrew from treatment, died, changed their treatment plan, or were lost to follow-up; (3) those with incomplete clinical data, and (4) patients with other serious organic diseases such as malignant tumors and abnormal liver and kidney functions.

A total of 60 patients with tracheal malignancies were included in this study, and designated the study group, while 60 healthy individuals were selected and designated the control group during the same period. On the day of admission, the socio-demographic and clinical presentation data of the patients were collected by the study team.

All patients received multi-slice spiral CT and tests for serum tumor markers. The multi-slice spiral CT was repeated in the test group of patients after adiponectin treatment so as to determine its diagnostic value.

Ethical considerations

The study complied with the principles of Declaration of Helsinki [10]. It was approved by the review board of the ethical review committee of Emergency General Hospital (approval no. 201700230).

After recruitment, the patients were informed of the purpose, significance, content, and confidentiality of the study, and each patient voluntarily signed an informed consent form.

Withdrawal criteria

The case record forms of patients who had the following conditions, and were adjudged by the research group to be unsuitable for continuing their participation in the study, were retained, but data analysis was not performed: (1) patients who had serious adverse events; (2) those whose conditions deteriorated during the study; (3) patients who had some serious co-morbidities or complications, and (4) those who were unwilling to continue the clinical trial during the study, and so requested to withdraw from the trial.

Treatments

All patients were treated with adiponectin. The test group received multi-slice spiral CT examinations before and after treatment. The tube voltage of the multi-slice spiral CT scanner (Philips, State Food and Drug Administration No. 3303600, 2008) was set at 120 kV, with tube current of 100 mA, pitch of 1.15, and scan slice thickness and interval slice thickness of 6 mm. The scanning was performed from the patient's thoracic inlet to the suprarenal pole, including the bilateral adrenal glands, using the end-inspiratory hold method.

The contrast agent for the enhancement scan was iohexol (Zhejiang Haichang Pharmaceutical Co. Ltd, State Pharmacopoeia H20093053) given at a dose of 100 mL. Intravenous injection of contrast agent was done in the forearm of the patient using a high-pressure syringe at a flow rate of 3 mL/s, with a 10-s delay.

The reconstruction was performed using Volume Wizard workstation with a slice thickness and reconstruction interval of 1 mm, while multi-planar reconstruction images were obtained with the multi-planar reconstruction (MPR) technique. The standard plane of the trachea was the coronal and sagittal plane through the central long axis of the trachea. After reconstruction, three experienced radiologists performed image analysis to determine the size of the tumor in the patient's tracheal lumen, the smoothness of the tumor margin, and the growth pattern of the tracheal tumor. The thickness of the wall adjacent to the tumor in the tracheal lumen was measured by a physician using Volume Wizard workstation so as to determine the presence of tracheal malignancy in the patients.

The control group was subjected to serum tumor marker testing before and after treatment. Morning fasting elbow venous blood (5 mL) was collected from each patient, and centrifuged to

obtain serum. Then, serum levels of carcinoembryonic antigen (CEA), soluble fragment of cytokeratin 19 (CYFRA 21-1), and neuron-specific enolase (NSE) were determined using electrochemiluminescence immunoassay (Cobase 411 Electrochemiluminescence Instrument, Original Supporting reagent, State Food and Drug Administration No. 3402843, 2011).

Normal ranges of the above indicators were based on the ranges indicated in the assay kit (i.e. CEA: 0 - 3 ng/mL, CYFRA 21 - 1: 0 - 3.3 ng/mL, and NSE: 0 - 16.3 ng/mL).

Evaluation of parameters/indices

General patient/subject information

General patient/subject information included number of hospitalizations, name, gender, age, body mass, Body Mass Index (BMI), educational level, living habits, monthly income, and underlying diseases.

In the study group, patients' pathological types comprised squamous carcinoma, adenocarcinoma, and mucosa-associated lymphoma. The number of patients in each pathological type was noted.

Multi-slice spiral CT examination

The characteristics of multi-slice spiral CT performance of the tracheal malignancies were determined.

Diagnostic values of multi-slice spiral CT examination and serum tumor marker test before treatment

Receiver operating characteristic (ROC) curve was used to analyze the diagnostic values of multi-slice spiral CT examination and serum tumor marker test before treatment. The criteria for multi-slice spiral CT examination were determined by physicians, and serum tumor markers were considered positive only when all three criteria were met.

Statistical analysis

The data processing software used in this study was SPSS 20.0, while GraphPad Prism 7 (GraphPad Software, San Diego, USA) was used to generating graphs. Counted data were analyzed using Chi-square test, while measured data were analyzed using Student's *t*-test. Statistical significance was assumed at $p < 0.05$.

RESULTS

General information on patients/subjects

There were no statistically significant differences in general information between the two groups of subjects ($p > 0.05$). These data are shown in Table 1.

Outcome of pathological staging

The 60 patients enrolled in this study consisted of 30 cases of squamous carcinoma, 22 cases of adenocarcinoma, and 8 cases of mucosa-associated lymphoma, the percentage compositions of which are shown in Figure 1.

Multi-slice spiral CT results

Multi-slice spiral CT before treatment showed that 35 patients with tracheal malignant tumors exhibited expansive hyperplasia to the lumen, and 25 patients with bulging tumors had saddle-like hyperplasia with irregular surfaces, and uneven margins, and the tracheal and bronchial walls adjacent to the luminal nodule had mean thickness of 5.96 ± 0.65 mm. However, after treatment, the thickness of the tracheal and bronchial walls adjacent to the luminal nodule decreased, with a mean value of 4.65 ± 0.48 mm.

Before treatment, the mean enhancement value of contrast-enhanced CT was 18.98 ± 1.23 Hu, and the mean tumor diameter was 3.68 ± 0.23 cm. In contrast, after treatment, the mean enhancement value was increased to 25.98 ± 1.44 Hu, while the mean tumor diameter was reduced to 2.54 ± 0.20 cm, in the test group.

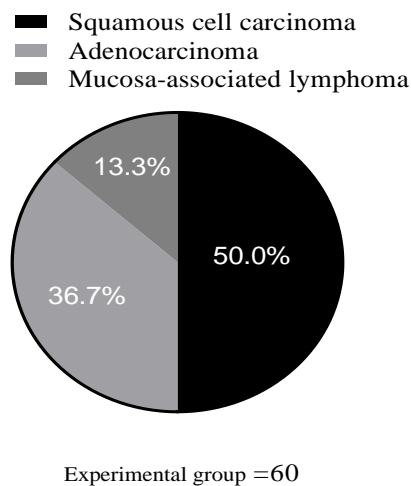


Figure 1: Pathological staging of patients in the test group {n(%)}. The black area represents squamous carcinoma (30 cases, 50.0 %); the light gray area is adenocarcinoma (22 cases, 36.7 %); and the dark gray area is mucosa-associated lymphoma (8 cases, 13.3 %)

Table 1: Comparison of subjects' general information between the 2 groups

Parameter	Study group (n=60)	Control group (n=60)	χ^2/t	P-value
Gender			0.135	0.714
Male	32	34		
Female	28	26		
Age (years)				
Range	34-68	32-70		
Mean age	50.65 ± 2.32	50.54 ± 2.68	0.240	0.811
Mean weight (kg)	58.98 ± 1.22	58.96 ± 1.20	0.091	0.928
BMI (kg/m ²)	22.10 ± 1.23	22.16 ± 1.24	0.266	0.791
Underlying disease				
Diabetes	16	14	0.178	0.673
Hypertension	18	20	0.154	0.695
Place of residence			0.036	0.850
Urban	38	37		
Rural	22	23		
Monthly income			0.034	0.853
≥ 4000	35	34		
< 4000	25	26		
Living habits				
Smoking history	26	28	0.135	0.714
Drinking history	27	25	0.136	0.713
Educational level			0.034	0.855
High school and below	32	33		
University and above	28	27		

Diagnostic values of multi-slice spiral CT examination and serum tumor markers

Before treatment, multi-slice spiral CT showed 56 true positive cases and 54 true negative cases, with a diagnostic sensitivity of 93.3 %, and a specificity of 90.0 %.

The results of serum tumor marker testing showed 50 true positive cases and 48 true negative cases, with a diagnostic sensitivity of 83.3 % and specificity of 80.0 %.

DISCUSSION

Primary tracheal malignancy is relatively rare in clinics, with incidence accounting for only 0.5 - 1.2 % of all malignancies [11]. Although the percentage mortality of this disease is much lower than those of other lung cancers, early diagnostic errors and delayed treatment reduce the survival of patients. Therefore, it is important to enhance the detection of tracheal malignancies and carry out systematic monitoring of the treatment process in patients. Currently, imaging is the main strategy used for the diagnosis of tracheal malignancies. Chest radiography assesses tumor size and tumor infiltration, and MRI allows assessment of tissue and vascular involvements in patients [12].

However, chest radiography may predispose to underestimation of tracheal wall involvement, while the application of magnetic resonance imaging and positron emission computed tomography is associated with some limitations. Recent investigations have demonstrated that multi-slice spiral CT examination is a better technique for identification of intraluminal and extraluminal lesions [13]. It is also useful for evaluation of the extent and degree of infiltration of lesions into the cartilaginous ring. Moreover, multi-slice spiral CT examination sufficiently shortens the acquisition time for volumetric scans, which facilitates long-distance and wide-area thin-section scanning and improves early detection rates [14].

The 60 patients included in this study comprised 30 cases of squamous carcinoma, 22 cases of adenocarcinoma, and 8 cases of mucosa-associated lymphoma. The overall degree of detection with multi-slice spiral CT was 91.7 %, indicating that this diagnostic modality is beneficial for detecting subtle lesions, and for reducing the possibility of missed diagnosis and misdiagnosis. These advantages are crucial for the development of treatments based on accurate diagnosis.

The high percentage of lesion detection with multi-slice spiral CT stems from its capacity to generate multi-angle and multi-level three-dimensional images. The MPR technique allows for arbitrary adjustment of window width and window position, which enables the physician to simultaneously observe the inside and outside of the tube lumen, especially the coronal and sagittal positions. In addition, it provides complete and clear images of tracheal malignancies, thereby fully minimizing the disadvantages of two-dimensional images and serum tumor marker tests [15].

The use of multi-slice spiral CT before treatment showed that 35 patients with tracheal malignant tumors had expansive hyperplasia into the lumen, and 25 patients with bulging tumors had saddle-like hyperplasia with irregular surfaces, uneven margins, and the tracheal and bronchial walls adjacent to the luminal nodule, had mean thickness of 5.96 ± 0.65 mm. Before treatment, the mean enhancement value of contrast-enhanced CT was 18.98 ± 1.23 Hu, and the mean tumor diameter was 3.68 ± 0.23 cm. These results are consistent with previous reports of the appearance of endotracheal malignancies in the form of nodular tumors with irregular margins and wall thickening in the tracheal lumen. Thus, multi-slice spiral CT and MPR techniques are effective in detecting tumors in the tracheal lumen. Most tracheal malignant tumors are spherical in shape, while the tracheal wall is circular in cross-section, and the only part of the spherical tumor in contact with the wall is the base of the tumor. Consequently, a mass adjacent to the tracheal wall is likely to be regarded as the base of the tumor from cross-sectional observation, which reduces the accuracy of observation. It has been demonstrated that 3D images of the central trachea are useful complements to cross-sectional images, and that multi-slice spiral CT provides a clearer view of tracheal tumors, reduces the possibility of false positives, and effectively screens recurrence after treatment [16,17].

In the present study, after treatment, the thickness of the tracheal and bronchial walls adjacent to the luminal nodule decreased to a mean value of 4.65 ± 0.48 mm; the mean enhancement value was 25.98 ± 1.44 Hu, while the mean tumor diameter was reduced to 2.54 ± 0.20 cm. These data confirm that multi-slice spiral CT has potential for effective monitoring of the progress of patients treated with adiponectin, and it can be used throughout the diagnosis and treatment process, with satisfactory diagnostic efficacy [18].

CONCLUSION

Multi-slice spiral CT has promising diagnostic value for patients with tracheal malignancies after adiponectin treatment. Therefore, further clinical trials are required to validate this finding.

DECLARATIONS

Acknowledgements

None provided.

Funding

None provided.

Ethical approval

This study was approved by the review board of the ethical review committee of Emergency General Hospital (approval no. 201700230).

Availability of data and materials

The datasets used and/or analyzed during the current study are available from the corresponding author on reasonable request.

Conflict of Interest

No conflict of interest associated with this work.

Contribution of Authors

The authors declare that this work was done by the authors named in this article and all liabilities pertaining to claims relating to the content of this article will be borne by them.

Open Access

This is an Open Access article that uses a funding model which does not charge readers or their institutions for access and distributed under the terms of the Creative Commons Attribution License (<http://creativecommons.org/licenses/by/4.0>) and the Budapest Open Access Initiative (<http://www.budapestopenaccessinitiative.org/read>), which permit unrestricted use, distribution, and reproduction in any medium, provided the original work is properly credited.

REFERENCES

- Shao D, Gao Q, Cheng Y, Du DY, Wang SY, Wang SX. The Prognostic Value of 18F-Fluorodeoxyglucose PET/CT in the Initial Assessment of Primary Tracheal

Malignant Tumor: A Retrospective Study Korean. *J Radiol.* 2021; 22(3): 425-434.

- Tanaka T, Amano H, Tanaka Y, Takahashi Y, Tajiri T, Tainaka T, Shiota C, Sumida W, Yokota K, Makita S, et al. Safe diagnostic management of malignant mediastinal tumors in the presence of respiratory distress: a 10-year experience. *BMC Pediatr* 2020; 20(1): 292.
- Chen L, Qi L, Zhang J, Ma Q, Chai X. Neutrophil-lymphocyte ratio as a prognostic factor for minute clear cell renal cell carcinoma diagnosed using multi-slice spiral CT. *Medicine (Baltimore)* 2021; 100(23): e26292.
- Chaddha U, Hogarth DK, Murgu S. Bronchoscopic Ablative Therapies for Malignant Central Airway Obstruction and Peripheral Lung Tumors. *Ann Am Thorac Soc* 2019; 16(10): 1220-1229.
- Jin Y, Al Sawalhi S, Zhao D, Cai H, Odeh AM, Xie H, Song J. Behavior of primary tracheal glomus tumor, uncertain malignant potential subtype. *Gen Thorac Cardiovasc Surg* 2019;67(11): 991-995.
- Nemade H, Nusrath S, Y J, Jonathan GT, Chandra Sekhara Rao S LM, Fonseca D, Subramanyeshwar Rao T. Primary Malignant Peripheral Nerve Sheath Tumor of the Trachea: a Case Report with Brief Review of Literature. *Indian J Surg Oncol* 2019; 10(2): 392-395.
- Ma G, Zhang X, Wang M, Xu X, Xu B, Guan Z. Role of 18F-FDG PET/CT in the differential diagnosis of primary benign and malignant unilateral adrenal tumors. *Quant Imaging Med Surg* 2021; 11(5): 2013-2018.
- Ma H, Kan Y, Yang JG. Clinical value of 68Ga-DOTA-SSTR PET/CT in the diagnosis and detection of neuroendocrine tumors of unknown primary origin: a systematic review and meta-analysis. *Acta Radiol* 2021; 62(9): 1217-1228.
- Marchioni A, Andrisani D, Tonelli R, Piro R, Andreani A, Cappiello GF, Meschiari E, Dominici M, Bavieri M, Barbieri F, Taddei S, Casalini E, Falco F, Gozzi F, Bruzzi G, Fantini R, Tabbi L, Castaniere I, Facciolongo N, Clini E; EVERMORE Study group. Integrated interventional bronchoscopy in the treatment of locally advanced non-small lung cancer with central Malignant airway Obstructions: a multicentric Retrospective study (EVERMORE). *Lung Cancer* 2020; 148: 40-47.
- Wang SC, Yin LK, Zhang Y, Xue LM, Ye JD, Tao GY, Yu H, Qiang JW. CT diagnosis and prognosis prediction of tracheal adenoid cystic carcinoma. *Eur J Radiol* 2021; 140:109746.
- Gupta S, Goyal P, Yang Y, Fitzgerald W. Tracheal Inflammatory Myofibroblastoma: A Rare Tumor of the Trachea. *Cureus* 2019; 11(4): e4484.
- Wang H, Cheng Q, Kong L, Shen L. [Application of Enhanced Recovery after Surgery in Interventional Treatment of Tracheal Malignant Tumor]. *Zhongguo Fei Ai Za Zhi* 2019; 22(1): 1-5. Chinese.
- Wan Y, Hao H, Meng S, Li Z, Yu F, Meng Chi, Chao Q, Gao J. Application of low dose pancreas perfusion CT combined with enhancement scanning in diagnosis of

- pancreatic neuroendocrine tumors. *Pancreatology* 2021; 21(1): 240-245.
14. Mlika M, Hamdi B, Marghli A, El Mezni F. About a lymphoepithelioma-like carcinoma of the lung with an endotracheal localization. *Tunis Med* 2018; 96(7): 451-453.
 15. Gompelmann D, Eberhardt R, Schuhmann M, Heussel CP, Herth FJ. Self-expanding Y stents in the treatment of central airway stenosis: a retrospective analysis. *Thorax* 2013; 7(5): 255-63.
 16. Özütemiz C, Neil EC, Tanwar M, Rubin NT, Ozturk K, Cayci Z. The Role of Dual-Phase FDG PET/CT in the Diagnosis and Follow-Up of Brain Tumors. *AJR Am J Roentgenol* 2020; 215(4): 985-996.
 17. Yoshizaki A, Yamamoto M, Hirabayashi A, Ono Y, Hatakeyama Y, Nakata K, Tamura D, Tachihara M, Kamiryo H, Kobayashi K, et al. Fatal Hemoptysis Due to Endobronchial Aspergilloma in the Hyperinflated Native Lung after Single-Lung Transplantation for Lymphangiomyomatosis: A Case Report. *Kobe J Med Sci* 2020; 65(4): E114-E117.
 18. Hao MH, Zhang F, Liu XX, Zhang F, Wang LJ, Xu SJ, Zhang JH, Ji HL, Xu P. Qualitative and quantitative analysis of catechin and quercetin in flavonoids extracted from *Rosa roxburghii* Tratt. *Trop J Pharm Res* 2018 ;17(1): 71-76.