



Needle in a haystack: Needle wandering to the heart

Authors: Kamil Baczewski, Krzysztof Olszewski, Marek Czajkowski, Michał Sojka,
Jacek Zawiślak, Klaudia Arykiewicz, Janusz Stażka

Article type: Clinical vignette

Received: September 30, 2022

Accepted: November 9, 2022

Early publication date: November 28, 2022

This article is available in open access under Creative Common Attribution-Non-Commercial-No Derivatives 4.0 International (CC BY-NC-ND 4.0) license, allowing to download articles and share them with others as long as they credit the authors and the publisher, but without permission to change them in any way or use them commercially.

Needle in a haystack: Needle wandering to the heart

Short title: Needle in a heart

Kamil Baczewski¹, Krzysztof Olszewski¹, Marek Czajkowski¹, Michał Sojka², Jacek Zawisłak³, Klaudia Arykiewicz³, Janusz Stążka¹

¹Department of Cardiac Surgery, Medical University of Lublin, Lublin, Poland

²Department of Interventional Radiology and Neuroradiology, Medical University of Lublin, Lublin, Poland

³Department of Cardiology, Medical University of Lublin, Lublin, Poland

Correspondence to:

Kamil Baczewski, MD, PhD,
Department of Cardiac Surgery,
Medical University of Lublin,
Żwirki i Wigury 4/16 20–029 Lublin, Poland,
phone: +48 537 493 963,
e-mail: drkamilbaczewskigmail.com

Chest trauma can be classified as either penetrating or blunt trauma. Blunt trauma is more common, but penetrating trauma can be seriously life threatening. Stab injuries account for 9.5% of thoracic penetrating injuries, making them the most common etiology of penetrating injuries [1]. Injuries caused by self-harm or attempted suicide are very rare. The first successful suturing of a heart wound was performed by Ludwig Rehn in 1896. This groundbreaking operation ushered in the era of cardiac surgery [2].

A 72-year-old woman was admitted to a psychiatric ward after a suicide attempt. From the medical interview, the patient stuck a sewing needle in her chest. Chest X-ray and physical examination confirmed the location of the needle in the subcutaneous tissue (Figure 1A). Due to the stable condition of the patient and the location of the foreign body, the patient was qualified for observation. After 3 days, the patient developed non-specific chest ailments. A control chest X-ray showed needle displacement from the subcutaneous tissue to the pericardial sac (Figure 1B). The patient was transferred to the cardiosurgical ward in order to extend the diagnosis and qualify for surgical treatment. On admission, the patient was cardiovascularly

stable without tamponade of the pericardial sac. On physical examination, there was no sign of the puncture on the chest wall. Due to age, according to ECTS guidelines, a coronary angiography was performed prior to the procedure in order to exclude coronary artery disease. In order to confirm the localization of the foreign body, a computed tomography (CT) of the chest was performed, which confirmed further displacement of the foreign body into the outflow path of the right ventricle. Even though this is a highly arrhythmogenic area no arrhythmias were observed during hospitalization (Figure 1C). Before surgery patient was consulted by the interventional radiologist. There was a risk of lasso loop slipping off the needle (the needle material is too hard and cannot be bend or broke like stent or peacemaker wire by intravascular tools) and therefore endovascular removal was impossible. The patient was qualified for cardiac surgery in the hybrid operating room. After sternotomy, a fusion was found in the pericardial sac, probably corresponding to the point where the needle entered the heart (Figure 1D). Under X-ray control, a foreign body was located near the outflow path from the right ventricle (Figure 1E). After opening the right ventricle, the needle was surgically removed (Figure 1F). The right ventricle was sutured with stitches on the pads. After the operation, the patient was transferred to the intensive care unit, where she stayed for 3 days. The course of hospitalization was without complications. After the psychiatric consultation, the patient was discharged home in good general condition.

Article information

Conflict of interest: None declared.

Funding: None.

Open access: This article is available in open access under Creative Common Attribution-Non-Commercial-No Derivatives 4.0 International (CC BY-NC-ND 4.0) license, allowing to download articles and share them with others as long as they credit the authors and the publisher, but without permission to change them in any way or use them commercially. For commercial use, please contact the journal office at kardiologiapolska@ptkardio.pl.

REREFENCES

1. Jain A, Sekusky AL, Burn B. Penetrating chest trauma. In: StatPearls 2021 [Internet]. .
2. Blatchford J. Ludwig rehn: the first successful cardiorrhaphy. *Ann Thorac Surg.* 1985; 39(5): 492–495, doi: [10.1016/s0003-4975\(10\)61972-8](https://doi.org/10.1016/s0003-4975(10)61972-8), indexed in Pubmed: [3888132](https://pubmed.ncbi.nlm.nih.gov/3888132/).

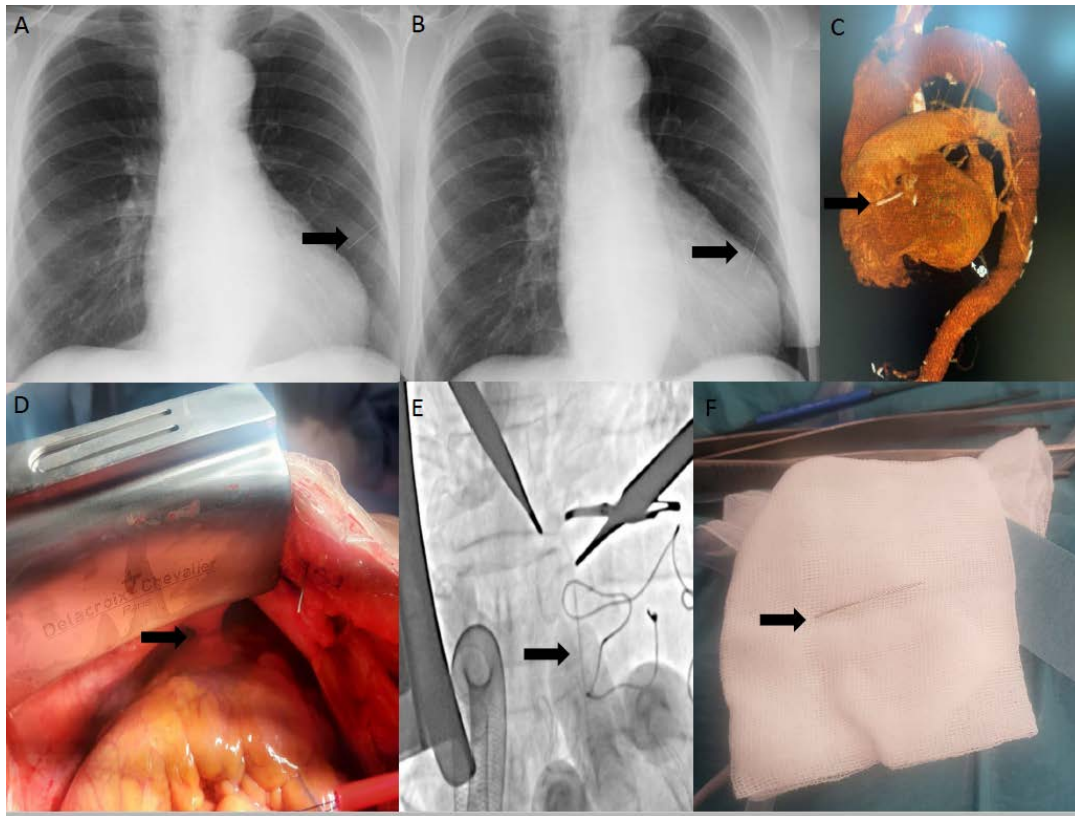


Figure 1. **A.** First chest X-ray: needle in the subcutaneous tissue. **B.** Second chest X-ray: needle in the pericardial sac. **C.** Computed tomography scan: foreign body near outflow path of the right ventricle. **D.** Intraoperative image: fusion in the pericardial sac. **E.** Live X-ray image: confirmed localization of needle. **F.** Needle after removed