

Науковий вісник Львівського національного університету
ветеринарної медицини та біотехнологій імені С.З. Гжицького.

Серія: Ветеринарні науки

Scientific Messenger of Lviv National University
of Veterinary Medicine and Biotechnologies.

Series: Veterinary sciences

ISSN 2518–7554 print

ISSN 2518–1327 online

doi: 10.32718/nvlvet10810

<https://nvlvet.com.ua/index.php/journal>

UDC 619:618:636.4:616-093

Measuring of the heifers ovaries and probiotic defence of the mucous membranes

L. Roman[✉], S. Sidashova², L. Korejba³, S. Ulyzko¹, N. Todorov¹, I. Popova¹, V. Chorny¹, V. Kushnir¹, B. Gutyj⁴

¹Odessa State Agrarian University, Odessa, Ukraine

²Agrarian doradcha (advisory) service of Odessa region, Odessa, Ukraine

³Dnipro State Agrarian and Economic University, Dnipro, Ukraine

⁴Stepan Gzhytskyi National University of Veterinary Medicine and Biotechnologies Lviv, Lviv, Ukraine

Article info

Received 19.09.2022

Received in revised form

19.10.2022

Accepted 20.10.2022

Odessa State Agrarian University,
Panteleymonivska Str., 13,
Odessa, 65012, Ukraine.
Tel.: +38-098-326-20-60
E-mail: liliyroman64@gmail.com

Agrarian doradcha (advisory)
service of Odessa region,
Panteleymonivska Str., 13,
Odessa, 65012, Ukraine.

Dnipro State Agrarian and
Economic University,
Serhii Efremov Str., 25,
Dnipro, 49600, Ukraine.

Stepan Gzhytskyi National
University of Veterinary
Medicine and Biotechnologies Lviv,
Pekarska Str. 50, Lviv,
79010, Ukraine.

Roman, L., Sidashova, S., Korejba, L., Ulyzko, S., Todorov, N., Popova, I., Chorny, V., Kushnir, V., & Gutyj, B. (2022). Measuring of the heifers ovaries and probiotic defence of the mucous membranes. Scientific Messenger of Lviv National University of Veterinary Medicine and Biotechnologies. Series: Veterinary sciences, 24(108), 69–74. doi: 10.32718/nvlvet10810

The results of the influence of complex probiotic defence of the mucous membranes of the reproductive system and intestines on the development of the corpus luteum of the cycle in heifers have been presented. By the method of differential palpation diagnostics in vivo, it was reliably examined that in the experimental group after carrying out procedures for the normalization of mucous membranes with the multicomponent probiotic drug “Multibacterin Veterinary Ba + La”, the number of heifers with high-quality of corpus luteum the ovaries was 48.21% more, and the number of cases of premature luteolysis was 12.50 % less ($P < 0.01$). The level of pregnancy in heifers in the experiment was on average 60.38 %, in the control – 46.94 %, which confirmed the positive effect of the probiotic protection of the mucous membranes on increasing the embryo survival by optimizing the conditions for embryonic nutrition on the surface of the endometrium.

Key words: heifers, palpation, diagnose, morphometry, corpus luteum, *Bacillus subtilis*, *Lactobacillus acidophilus*.

Introduction

Reproduction of broodstock is a main problem of modern industrial complexes. Significant progress in the development of reproductive biotechnology in recent years has significantly improved the genetic potential and productive qualities of specialized dairy cows around the world.

At the same time, scientists emphasize a significant imbalance between the production of genetic resources, the frozen semen production of which has millions of doses, and an extremely small number of offspring, namely, replacement heifers, obtained from highly productive cows (Golubets, 2019; Stryzheniuk et al., 2020). The

implementation of embryo transplantation (ET) biotechnology into production can significantly expand the reproductive potential of highly productive cows (Instruction of ..., 1987; Iablonskyi, 2011; Golubets, 2019). However, the data on the survival rate of pre-implantation embryos mentioned in the literature indicate a lack of progress at the transfer stage: the efficiency of nonsurgical embryo transfer to recipient heifers remains below 50 %, which significantly reduces the profitability of this method in practice (Himstra et al., 2010).

Analysis of literature data and our own research results for previous years showed that the low quality of animals – recipients, a significant polymorphism in stage

of the corpus luteum of the ovaries remains the problem of TE biotechnology.

The corpus luteum is a temporary secretory gland of the ovary and is formed at the site of the ovulated dominant follicle and produces the hormone progesterone, which inhibits the further development of follicles and during the entire luteal phase of the sexual cycle creates conditions that ensure the preparation of the uterus and its endometrium for implantation of the embryo and its nutrition in the early stages of pregnancy. Ukrainian authors show that the level of progesterone fluctuates with the development of the corpus luteum from 6.00 nmol/l on the first day of the cycle to an increase in the level on the 13th day by 7.8 times, and from the 14th day it begins to decrease until the first day of the next cycle (Davydova, 2006; Bugrov, 2014). In a number of other studies, mismatched boundaries of the length of the luteal and follicular phases of the cycle are given, which indicates a significant influence of external factors on the diagnostic results (Baban et al., 2009; Iablonskyi, 2011).

With the aim of increasing the efficiency of modern biotechnological methods of reproduction of cows, the most diagnostically important are days 7–8 of the luteal phase of the sexual cycle, which are a technological window for transcervical transplantation of pre-implantation embryos into recipient females.

Long-term studies have shown that embryo transplantation from highly productive donor cows can increase the yield of female offspring with valuable genetic potential by 3.5–12 or more times, which significantly removes the biological limit of infertility in cattle (Soroculova, 2013; Golubets, 2019; Roman et al., 2020).

A long-term study of the characteristics of the sexual cycle of cows in all countries with a developed livestock industry has contributed to a significant improvement in the methods of reproductive biotechnology, including methodological approaches to the selection of female recipients (Buhrov, 2014; Golubets, 2019). However, even today, indicators of the size and morphological characteristics of the yellow bodies of the cycle in cows or heifers remain a factor limiting the number of recipients suitable for transfer. At the same time, literary sources dwell on the improvement of hormonal schemes for the preparation of recipients, ignoring the protective and nutritional properties of their mucous membranes, given the fact that early embryos depend on the histotrophic type of nutrition obtained from the cells of the uterus endometrium (Baban et al., 2009).

Recently, there has been a significant increase in the use of probiotic preparations and feed additives in dairy cattle breeding, both as an alternative to pharmacological therapy and to increase the productivity of animals. It's considered that probiotics can significantly decrease the use of antibiotics in animal husbandry, which cause microbial resistance, which is extremely dangerous for humans (Hu et al., 2014). In numerous experiments, the mechanism of the biological effect of probiotics on a macroorganism was revealed. It was proved that agents containing symbiotic strains of microorganisms have a positive effect on metabolism, productivity growth, preservation of immunity, and improvement in the quality

of milk and meat (Young, 2002; Duda, 2010; Prysoka et al., 2010; Savustyanenko, 2016).

The effect of the use of ecologically correct methods of normalization of mucous membranes with preparations containing symbiotic microflora on the development of the yellow bodies of the ovaries of the cows has not yet been studied.

The aim of the study

The aim of our work was to study in vivo (in the real course of the luteal phase) the morphometric indicators of the development of the corpus luteum of the ovaries for 7–7.5 days sexual cycle in heifers-recipients before the non-surgical transfer of pre-implantation embryos

Materials and methods

The experimental part of the work was carried out in a dairy complex of an industrial type, which was a reproducer of the Ukrainian red dairy cattle breed. In the conditions of loose keeping of young stock on walking grounds equipped with feeding tables and automatic drinkers, two groups of analogous heifers were selected by the method of periods in accordance with zootechnical requirements for transfer to the reproduction workshop: age of 15–16 months with live weight ≥ 350 kg (on average 367.67 kg), without clinical signs of gynecological diseases. The feeding ration of the livestock corresponded to modern nutritional standards (total mixed ration), after outweighing, all animals received a course of complex preparations containing vitamins A, E, D, group B, etc. The entire livestock was provided with anti-epizootic measures and vaccinations in accordance with the current veterinary requirements.

All biotechnological and veterinary procedures were carried out in accordance with the requirements for the welfare of animals, after fixing the heifers in special pens, no harm was caused to their health during the procedures (FAO..., 2010).

Both groups of heifers received the main diet all the time. In the experiment, a complex scheme of probiotic protection of mucous membranes was additionally applied: feeding - by giving a solution per os (1:10 with purified water) of the probiotic drug "Veterinary Multibacterin Ba + La"; gynecological - vaginal irrigation with a sterile solution (1:10) of the same remedy (producer - LLC Vidrodzhennya M, Ukraine) (Nastanova ..., 2003).

Pharmacological features of the drug "Veterinary Multibacterin Ba + La" are suitable for use as replacement therapy for the prevention and treatment of respiratory, gastrointestinal diseases of animals (colic bacteriosis and salmonellosis), dysbacteriosis, correction of gastrointestinal microflora during antibiotic therapy, mycotoxicosis, as growth-stimulating and immunostimulating dietary supplements. The drug can be used simultaneously with other therapeutic agents, it is environmentally friendly, does not cause complications and side effects, does not accumulate in the organs and tissues of animals; contraindications - not established. The preparation is made from strains of microorganisms *Bacillus subtilis* and *Lactobacillus acidophilus*, which are deposited in the Bank of

Microorganisms of the National Academy of Sciences of Ukraine (Nastanova ..., 2003).

The scientific novelty of the experiment consisted in the complexity of the methodological approach to the procedures for the normalization of the mucous membranes of several cavities of the macroorganism at the same time: the intestines and reproductive system of heifers before the artificial insemination. For 3 weeks, young animals were given 15–20 ml of the drug with food (by aeration of freshly created monofeed), the end of food normalization coincided with the beginning of transfer procedures (artificial insemination). A week before artificial insemination, the heifers underwent daily four-fold irrigation of the mucous membranes of the reproductive system (intravaginally and epicervically using disposable catheters with sterile warm (30–35 °C) solution of the drug “Veterinary Multibacterin Ba + La” 15 ml (dilution 1:10 with distilled water).

At the end of the experimental period, 7–7.5 days after the fixed day 0 of the induced sexual cycle, all heifers that had high-quality ovarian corpuscles were subjected to the procedure of non-surgical transcervical transfer of deconserved embryos (TE) in vivo (n = 18), the rest of the

animals were artificially inseminated (AI) on the next 0-th day of the cycle (n = 84). Heifers with chronic atrophic and degenerative changes in ovarian tissues, confirming irreversible destructive processes, were excluded from the reproduction group (n = 10). Pregnancy diagnostics was carried out using an ultrasound scanner (KX5200 Kaixin) in 35–40 days after artificial insemination.

During the experiment, zootechnical methods were used (visual observation of the livestock, fixation of the ethological characteristics of animals at different stages of the sexual cycle) and special methods of palpation differential diagnosis of morphofunctional formations of the gonads of cows using the modifications shown by us in previous publications (Sidashova & Humennyi, 2016; Sidashova, 2017; Sidashova et al., 2019).

To quantify and compare the development of the corpus luteum of the ovaries of heifers during a fixed period of a spontaneous or induced sexual cycle by palpation, a working scale was preliminarily developed (Table 1), taking into account the recommendations of a number of authors and the results of our own studies (Bugrov, 2014; Sidashova et al., 2019).

Table 1

Working scale for evaluating the results of palpation differential diagnosis of the morphofunctional state of the corpus luteum of the heifers ovaries on days 7–7.5 days of the luteal phase of the cycle

Characteristics of diagnostic signs	Short designation of palpation data *			
	CL+	CL	CL lysis	0
Morphology: shape, contours of the corpus luteum	Typical rounded shape with clear contours and a fossa in the center; an organized radial structure of luteocytes is palpable	Rounded or slightly altered shape with some indistinctness of the contours, the fossa is poorly expressed or displaced from the center	Atypical shape – angular, flattened, with blurred contours, the fossa in the center is not palpable, the structure of the organization of luteocytes is not palpable	
Corpus luteum consistency	Typical elastic	Elastic and more softened	Loose, soft, atypical, or hard (connective tissue transformation)	There are no morphofunctional formations on the surface of the ovary
Morphometry: corpus luteum diameter, cm	1.5–1.9	1.1–1.4	≤ 1.0	
General assessment of the development of the corpus luteum in accordance with the day of the cycle (7–7.5 days)	High-quality functional corpus luteum	Functional corpus luteum of satisfactory quality	Non-functional corpus luteum in the stage of premature lysis	

Note: * – data is given in unilateral form for a functional ovary; taking into account the fact that the diameter of the corpus luteum of the right ovary, as more developed and dominant in this herd, as a rule, exceeded those on the left ovary by 0.2–0.3 cm.

The generalized data was summarized, biometrically processed using the IBMS Statistics – 2011 (Version 20) software package and presented in tables and figures as models (Sidashova et al., 2019).

Results and discussion

The results of differentiated palpation diagnostics of heifers on days 7–7.5 of the sexual cycle, presented in table 2, showed that after preliminary probiotic treatment with the drug “Veterinary Multibacterin Ba + La” of the intestinal and reproductive system mucous membranes, a significant optimization of the morphofunctional state was noted in the experimental group ovaries.

Table 2

Comparison of polymorphism in the development of yellow bodies on the 7th day of the cycle in heifers in the control and experimental groups (n = 112)

Indicators	Control (M ± m)		Experience (M ± m)		± m
	Goal.	%	Goal.	%	
Total heifers were examined by palpation	56	100	56	100	
Among them, it was revealed:					
CL+	1	1.79	19	33.93	18.96
CL	12	21.43	21	37.50*	1.75
CL lysis	20	35.71	13	23.21*	0.65
0	21	37.50	3	5.36	0.14
Degenerative gonadopathies **	2	3.57	0	0.00	0.00

Note: * – P < 0.01 compared to the control group; ** – follicular cysts

The yellow bodies with typical morphometric characteristics (CL +) were palpated in 35.50 % of cows in the experiment, which allowed to carry out in vivo transplantation of pre-implantation embryos in accordance with the current instructions (Instruction ..., 1987; Golubets, 2019). In the control group, only 1.79 % of cows had similar parameters of the corpus luteum, which suggested transferring to recipients with satisfactory indicators of the development of the corpus luteum (CL) (Sidashova et al., 2018; 2019).

The corpus luteum with signs of premature lysis, which indicated a hormonal imbalance in the body of heifers, was detected in the control in 35.71 % of cases, in the experiment – in 23.21% (P < 0.01), which showed the dominant influence of economic paratypical factors on the processes of luteogenesis in the ovaries of cows in industrial conditions with a large number of stress factors. However, it should be noted that the positive influence of the normalization of the mucous membranes of the intestine and the reproduction system was reflected in the fact that in the experiment the state of ovarian hypotrophy and the complete absence of morphofunctional formations during the calm stage of the sexual cycle was revealed only in 5.36 % of heifers, at the same time in control - in 37.50 % of animals. A significant number of functionally defective sexual cycles revealed in the control group indicated a violation of hemodynamics in the tissues of the reproductive organs and the possible toxic effect of feed ingredients. The data in Table 1 show a significant polymorphism of the corpus luteum in the group of analogous heifers during the critical period of the sexual cycle from the point of view of reproductive biotechnology (7–7.5 days). The technique of comparing palpation data in vivo is shown in Fig. 1 and 2 is described in detail in our previous publications (Sidashova & Humennyi, 2016; Sidashova et al., 2019).

Development of methods, models and photos – by the author (Sidashova et al., 2019).

In addition to the revealed functional pathologies of the ovaries in the form of hypotrophy of the follicular layer and insufficient development of luteocytes (in the experiment 23.21 %, in the control – 35.71 %; P < 0.01), in the control group of heifers, 3.57 % of cows with degenerative changes were found, namely with cystic degeneration of non-ovulated follicles. In the experiment, such gonadopathies were absent, which indicated a therapeutic correction of the course of the sexual cycle in heifers

under the influence of the normalization of metabolic processes, including hormonal processes in the body (Roman et al., 2020).

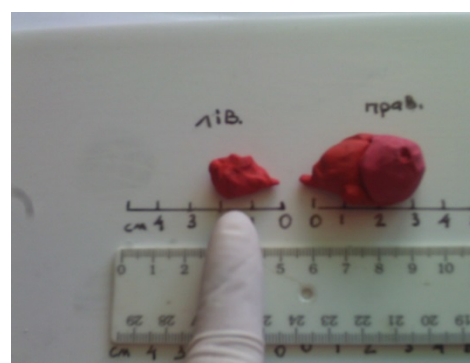

Fig. 1. Methods of morphometry in vivo of palpation diagnostics data using life-size volumetric ovarian models

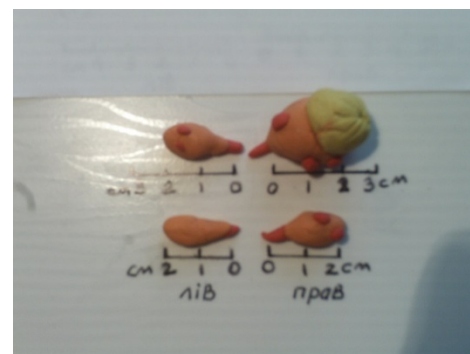


Fig. 2. Comparison of the morphometric parameters in vivo of the ovaries of two heifers at the stage of 7.5 days of the sexual cycle according to the visualization of volumetric models: top – quality corpus luteum (CL +) of the right ovary; below – the absence of luteogenesis on both gonads, hypotrophy

According to a number of researchers, the diameter of the corpus luteum of the ovaries in cows has strong positive correlations with the number of luteocytes and the level of progesterone secretion and indicates of the synchronous course of physiological processes of preparing the organs of the reproductive system for implantation of the embryo and maintaining its further development. The studies of author confirmed the normal content of progesterone in the blood of cows on the 7-th and 8th days of the luteal phase of the cycle within 36.14 and 39.21 nmol/l, respectively. The average diameter of corpus luteum

ranged from 1.33 to 1.36 cm (right) and 1.20 to 1.30 cm (left) (Bugrov, 2014; Roman et al., 2020). Thus, the data of our studies show that the correspondence of the corpus luteum in the experiment to the specific morphometric parameters indicates that this temporary secretory gland produced the optimal amount of progesterone.

As the experimental results showed, additional colonization of the mucous membranes of the reproductive system of the heifers in the experimental group with symbiotic microorganisms contributed to the improvement of both the nutritional function of the mucous membranes and their protective effect due to the detoxification of surfaces from ingested toxins from the external environment saturated with pathogenic and non-pathogenic microorganisms (Duda, 2010). At the same time, the probiotic protection of the intestinal mucous membranes created an additional barrier against the penetration of pathogenic microflora and bacterial poisons from the feed mixture into the blood and lymph of animals. All this increases in the level of digestibility of feed and metabolic pro-

cesses, including the optimization of the production of necessary hormonal compounds by cells and glands.

A number of researchers believe that feed intoxication is one of the significant negative factors leading to a decrease in the level of pregnancy in cows (Bakulina, 2001) on roughage was noted (Baban et al., 2016; Roman et al., 2020). Therefore, it is clear that the high capacity for biological transformation of toxins in the *Bacillus subtilis*, which are part of the drug, led to a significant cleansing of the mucous membranes, and the action of the microorganisms of the normal flora *Lactobacillus acidophilus* contributed the accumulation of nutrients and biologically active compounds. During the first weeks after implantation, the embryo of cattle has a histotrophic type of nutrition, i.e. its development depends entirely on the quality of the nutrient medium of the endometrium of the uterus.

The effectiveness of the onset of pregnancy after non-surgical transfer of deconserved embryos or artificial insemination of heifers is shown in Table 3.

Table 3

The effectiveness of the onset of pregnancy in the control and experimental groups, n = 102

Indicators	Control (head -%)	Experiment (head -%)
AI procedures performed	41	43
Became pregnant	19 – 46.34	26 – 60.47
TE procedures performed	8	10
Became pregnant	4 – 50.00	6 – 60.00
Total% of pregnancy by group	46.94	60.38

The effectiveness of the onset of pregnancy in the experimental group of heifers after embryo transfer was higher by 10 %, and after artificial insemination – by 14.03 %, which confirmed our previous conclusions of the positive influence of a complex probiotic effect on the mucous membranes of animals. It should be noted that the regenerative capacity of the epithelial cells of the mucous membranes, which received microtrauma as a result of transcervical insertion of a catheter during the transfer of early embryos deep into the uterine horn of the recipients, improved (Roman et al., 2020). According to the results of the study of transfer mentioned above we have received a patent for a method of the preventive use of the remedy “Veterinary Multibacterin Ba + La”.

The data from various domestic and foreign sources on the increase in the efficiency of reproduction of female cattle after the prophylactic use of probiotic preparations and feed additives coincide with our results (Soroculova, 2013), however, it should be noted that there is a significant variability in fertilization levels in different groups of females, which indicates a significant influence of factors the environment on their fertility and the prospects for further optimization of probiotic protection schemes.

Conclusions

By the method of differential palpation diagnostics in vivo, significant polymorphism in the development of the corpus luteum on the 7–7.5th day of the cycle in heifers-recipients was established: the corpus luteum corresponded to the term of the luteal phase – 23.22 %; premature

luteolysis of the corpus luteum – 35.71 %; gonadopathies with significant ovarian tissue hypotrophy or degenerative changes – 41.07 %.

The use of a complex scheme of probiotic protection of the mucous membranes of heifers using the multicomponent preparation “Veterinary Multibacterin Ba + La” showed a significant positive effect of normal microflora procedures on the morphometric parameters of the ovarian corpus luteum.

In the experimental group of heifers, high-quality corpus luteum on days 7–7.5 of the luteal phase of the sexual cycle was, higher by 48.21 % (P < 0.01), and the incidence of premature lysis of the corpus luteum was less by 12.50 % (P < 0.01).

Conflict of interest

The authors state that there is no conflict of interest.

References

- Baban, O. A., Kharuta, H. H., & Papachenko, I. V. (2009). Histologichni zminy v yaiechnykh koriv pry hipofunktsii. *Veterynarna medytsyna Ukrainy*, 5, 26–30 (in Ukrainian).
- Baban, O. A., Papachenko, I. V., Velbivets, M. V., & Lototskyi, V. V. (2016). *Histostruktura yaiechnykh riznykh rozmiriv vid koriv za anafrodyzii*. *Naukovyi visnyk veterynarnoi medytsyny. Bila Tserkva. BNAU*, 2, 5–10. URL: http://nbuv.gov.ua/UJRN/nvvm_2016_2_3 (in Ukrainian).

- Bakulina, L. F. (2001). Probiotics based on spore-forming microorganisms of the genus *Bacillus* and their use in veterinary medicine. *Biotechnology*, 2, 48–56.
- Buhrov, O. D. (2014). *Vyivlennia i vybirka koriv i telyts u statevii okhoti (metodychni rekomendatsii)*. Vyd. 3-ye, dop. i pererob., Kharkiv (in Ukrainian).
- Davydova, Yu. Iu. (2006). Morfolohichni zminy folikuliv ta zhovtykh til u pryrodnomu statevomu tsykli u koriv. *Zb. nauk.-tekhnich.biuletenu Instytutu tvarynnytstva UAAN*, 92, 32–38 (in Ukrainian).
- Duda, L. V. (2010). Korrekciya disbioticheskikh sostojanij zhivotnyh i pticy s pomoshh'ju probioticheskikh preparatov na osnove *Bacillus subtilis*. *Veterinarna medycyna Ukraini*, 7, 45–46 (in Russian).
- FAO. 2010. № 3. Breeding strategies for sustainable management of animal genetic resources. *FAO Animal Production and Health Guidelines*. № 3. Rome. Italy: FAO of the UN, Commission on Genetic resources for Food and Agriculture.
- Golubets, L. V. (2019). *Innovative technologies in breeding and selection of pedigree cattle: monograph*. Grodno: GGAU.
- Hadzalo, Ya. M. (2016). Problemy prodovolchoi bezpeky v konteksti realizatsii spilnoi stratehii MEB, VOOZ ta FAO «Iedyne zdorovia». *Veterinarna medytsyna*, 102, 11–13 (in Ukrainian).
- Himstra, S.-J., de Haas, Y., Maki-Tanila, A., & Gandini, G. (2010). *Local cattle breeds in Europe. Development of policies and strategies for self-sustaining breeds*. Wageningen: Academic Publishers, the Netherlands, 154. DOI: 10.3920/978-90-8686-697-7.
- Hu, Y., Dun, Y., Li, S., et al. (2014). Effect of *Bacillus subtilis* KN-42 on gross performance, diarrhea and faecat flora of weaned piglets. *Asian-Australas J. Sci.*, 27(8), 1131–1140. DOI: 10.5713/ajas.2013.13737.
- Iablonskyi, V. A. (2011). *Veterynarne akusherstvo, hinekolohiia ta biotekhnolohiia vidtvorennia tvaryn z osnovamy androlohii; Pidruchnyk*. Vinnytsia: Nova knyha (in Ukrainian).
- Instructions for the transplantation of cattle embryos. M., 1987. 92 p.
- Nastanova po zastosuvanniu preparatu Multybakteryn veterynarnyi (mono - ta poli komponentni probiotyky). *Skhvaleno Vchenoiu radoiu DNDKI vetpreparativ ta kormovykh dobavok (protokol № 2 vid 12.02.2003 r.)*. 3 s. (in Ukrainian).
- Pryskoka, V. A., Sobko, Yu. A., & Panchenko, O. O. (2010). Mikroorhanizmy: zmina spivvidnoshen mizh populiatsiiamy ta nadlyshkovyi rist yak peredumova vynykennia zakhvoriuvan. *Veterynarna medytsyna*, 9, 30–33 (in Ukrainian).
- Roman, L., Broshkov, M., Popova, I., Hierdieva, A., Sidashova, S., Bogach, N., Ulizko, S., & Gutyj, B. (2020). Influence of ovarian follicular cysts on reproductive performance in the cattle of new Ukrainian red dairy breed. *Ukrainian journal of Ecology*, 10(2), 426–434. DOI: 10.15421/2020_119.
- Roman, L., Sidashova, S., Danchuk, O., Popova, I., Levchenko, A., Chorny, V., Bobritska, O., & Gutyj, B. (2020). Functional asymmetry in cattle ovaries and donor-recipients embryo. *Ukrainian Journal of Ecology*, 10(3), 139–146. DOI: 10.15421/2020_147.
- Roman, L., Sidashova, S., Popova, I., Stepanova, N., Chorny, V., Sklyarov, P., Koreyba, L., & Gutyj, B. (2020). The impact of lateral localization of the procedure on the effectiveness of transplants of pre-implantation embryos in heifers-recipient. *Ukrainian Journal of Ecology*, 10(6), 121–126. DOI: 10.15421/2020_270.
- Savustyanenko, A.V. (2016). Mechanisms of action of probiotics based on *Bacillus subtilis*. *Journal of Actual Infectology*, 1, 35–44. DOI: 10.22141/2312-413x.2.11.2016.77529.
- Sidashova, S. O. (2017). Povnotsinnist statevoi tsyklichnosti remontnykh telyts v umovakh promyslovoho vyrobnytstva. *Naukovo-informatsiyni visnyk KhDAU*, 9, 54–58 (in Ukrainian).
- Sidashova, S. O., & Humennyi, O. H. (2016). Vplyv probiotychnoho zakhystu slyzovykh na funktsiiu yaiechnykhiv laktuiuchykh koriv. *Naukovi visnyk veterynarnoi medytsyny*. Bila Tserkva. BNAU, 2, 17–24 (in Ukrainian).
- Sidashova, S. O., Avdosieva, I. K., Hryhorasheva, I. M., & Humennyi, O. H. (2019). Zastosuvannia pro biotychnoho preparatu «Multybakterin veterynarnyi suspensziia» dlia pidvyshchennia efektyvnosti transplantatsii embrioniv velykoi rohatoi khudoby (metodychni rekomendatsii). Lviv, DNDKI vetpreparativ ta kormovykh dobavok. Odesa, Odeskyi derzhavnyi ahrarnyi universytet (in Ukrainian).
- Sidashova, S. O., Shcherbak, O. V., Kovtun, S. I., & Trotskyi, P. A. (2019). Orhanizatsiia treninhu z diahnozyky stanu yaiechnykhiv koriv i telyts za transplantatsii embrioniv (metodychni rekomendatsii). Chubynske (in Ukrainian).
- Soroculova, I. (2013). Modern status and perspectives of as probiotics. *J. Prob. Health.*, 1(4), 1000–1016. DOI: 10.4172/2329-8901.1000e106.
- Stryzheniuk, V. S., Hutyi, B. V., Sidashova, S. A., Khalak, V. I., Humennyi, O. H., & Stadnytska, O. I. (2020). Patent Ukrainy 145560. Kyiv: Derzhavne patentne vidomstvo Ukrainy (in Ukrainian).
- Young, D., Hassell, T., & Duongan, Y. (2002). Chronic factors infections: Living with unwanted guests. *Nature Immunology*, 3:1026–1032. DOI: 10.1038/ni1102-1026.