

## CASE REPORT

## Idiopathic Hypereosinophilic Syndrome with Unusual Presentation: Two Case Reports And Review of Literature

SURIA AA<sup>1</sup>, HAFIZAH H<sup>2</sup>, NURASYIKIN Y<sup>1</sup>, AZLIN I<sup>1</sup>, YOUSUF R<sup>1</sup>, AZMA RZ<sup>1</sup>, HAMIDAH NH<sup>1</sup>

<sup>1</sup>Department of Pathology, Faculty of Medicine, Universiti Kebangsaan Malaysia, Jalan Yaacob Latif, Bandar Tun Razak, 56000 Cheras, Kuala Lumpur.

<sup>2</sup>Department of Pathology, Hospital Sultanah Bahiyah, Jalan Langgar, 05460, Alor Setar, Kedah Darul Aman.

### ABSTRAK

Sindrom hipereosinofil idiomatik (HES) boleh mengakibatkan morbiditi dan mortaliti yang ketara. Pesakit biasanya mempunyai bilangan darah putih eosinofil yang tinggi untuk jangka masa yang berpanjangan dan menyebabkan tanda-tanda kerosakan organ dalaman. Protein yang merosakkan yang terhasil oleh granul eosinofilik bertanggungjawab terhadap kerosakan tisu dan sistem organ. Kami laporkan dua kes sindrom hipereosinofil idiomatik dan cabaran luar biasa yang ditimbulkan oleh penyakit ini yang jarang berlaku. Kedua-dua pesakit itu adalah wanita muda yang mengalami demam gred tinggi dan gejala bersamaan. Penemuan makmal menunjukkan sel darah putih periferi yang tinggi dengan neutrofilia dan eosinofilia yang dominan. Diagnosis idiomatik HES dibuat selepas tiada punca sekunder eosinofilia dijumpai. Walau bagaimanapun, keadaan pesakit pertama dirumitkan dengan beberapa trombosis vena. Rawatan heparin intravena dimulakan dan kemudiannya ditukar kepada subkutaneus heparin molekul rendah (LMWH). Pesakit kemudian mengalami efusi pleura. Rawatan diteruskan dengan intravena Tazoscin, tablet Prednisolone dan tablet Hydroxyurea dan pesakit beransur pulih. Namun, dua minggu kemudian, tiba-tiba keadaan pesakit kembali parah dan meninggal dunia. Di sisi lain, pesakit kedua mengalami demam, trombositopenia, anemia hemolitik, kegagalan buah pinggang akut dan defisit neurologi yang merupakan sebahagian daripada Trombotik Trombositopenik Purpura (TTP). Pertukaran plasma telah dimulakan dan keadaan pesakit beransur baik. Walau bagaimanapun, beberapa episod hipoksia yang dialami telah mengakibatkan kecederaan otak kekal yang memerlukan trakeostomi untuk bantuan ventilasi yang berpanjangan. Tujuan utama rawatan HES adalah untuk meminimumkan kerosakan tisu yang boleh disebabkan oleh hypereosinofilia. Oleh itu, diagnosis dan rawatan awal adalah penting untuk mencegah penyebaran penyakit dan kerosakan organ.

**Address for correspondence and reprint requests:** Dr. Suria Abdul Aziz. Department of Pathology, Faculty of Medicine, Universiti Kebangsaan Malaysia, Jalan Yaacob Latif, Bandar Tun Razak, 56000, Cheras, Kuala Lumpur. Malaysia. Tel: +603-91455443 Email: suria.abdulaziz@gmail.com

*Kata kunci: eosinofilia, sindrom hypereosinofilik, trombosis, trombotik trombotik trombositopenik purpura*

## ABSTRACT

Idiopathic hypereosinophilic syndrome (HES) is an uncommon disorder which usually presents with prolonged and significant primary eosinophilia with end-organ dysfunction. Damaging proteins released by the eosinophilic granules are responsible for the tissues and organ system damage. Here we report two cases of idiopathic HES. Both the patients were young lady presented with high grade fever and concomitant symptoms. Laboratory findings showed leucocytosis with predominant neutrophilia and marked eosinophilia. A diagnosis of idiopathic HES was made after excluding secondary causes of eosinophilia. However, the first patient was complicated with multiple venous thrombosis and intravenous heparin was started which was later changed to subcutaneous low molecular weight heparin (LMWH). The patient developed pleural effusion and consolidation. Intravenous Tazoscine, tablet Prednisolone and tablet Hydroxyurea was started and the patient responded well. Despite treatment, two weeks later, suddenly the patient collapsed and unfortunately succumbed. On the other hand, the second patient was complicated with fever, thrombocytopenia, haemolytic anaemia, acute renal failure and neurological deficit which were part and parcel of thrombotic thrombocytopenic purpura (TTP). Plasma exchange was commenced and patient's condition had slowly improved. Nevertheless, the hypoxia which she sustained during the multiple episodes of fits had resulted in permanent brain injury and thus requiring a tracheostomy for prolonged ventilatory support. Currently, there is no cure for HES. The main aim of treatment is to minimise the tissue damage caused by the hypereosinophilia. Early diagnosis and intervention are therefore crucial in preventing the spread of the disease and the end-organ damage.

Keywords: idiopathic hypereosinophilic syndrome, thromboses, thrombotic thrombocytopenic purpura

---

## INTRODUCTION

Idiopathic hypereosinophilic syndrome (HES) is defined as eosinophilia ( $\geq 1.5 \times 10^9/L$ ) persisting for at least 6 months, with no underlying cause and is associated with signs of organ involvement and dysfunction (Swerdlow et al. 2008). The key

feature of HES is the continuous eosinophilia which may result in organ dysfunction. It has considerable clinical diversity and the prognosis also varies widely. Up to the 1970s, prognosis for HES was extremely poor with mean survival of nine months and a three-year survival rate of only 12% (Gotlib 2015). A later study found

a 5-year survival rate of 80%, which decreases to 42% at 15 years (Gotlib 2015). The prognosis largely depends on the subtypes of eosinophilia which are myeloproliferative, lymphocytic, and idiopathic variants. The myeloproliferative subtype is characterised by chromosomal abnormality, tyrosine kinase-producing genes rearrangement, increased dysplastic bone marrow mast cells resulting in increased serum tryptase, vitamin B12 excess and splenomegaly. The lymphocytic subtype is the result of aberrant phenotype T-cell resulting in increased interleukin 5, interleukin 3 and granulocyte-macrophage colony stimulating factor. The clonal proliferation of these abnormal lymphocytes can progress to lymphoma. No particular chromosomal abnormality has been associated with idiopathic HES and therefore it is a diagnosis of exclusion (Swerdlow et al. 2008; Gotlib 2015).

Majority of idiopathic HES patients (70%) are between 20-50 years of age. Nevertheless, idiopathic hypereosinophilia has been described in infants and children (Gotlib 2015). The male-to-female ratio was 1.47 and majority of the affected men are FIP1L1-PDGFRA (F/P) of myeloproliferative variants of HES whilst other subtypes have no gender bias (Gotlib 2015). The end organs frequently involved include cardiac, respiratory, skin, gastrointestinal, and neurological systems (Narayan et al. 2003; Narisa et al. 2013). It was reported that about 25% of patients developed thromboembolism and about 5% to 10% of them resulted in

death. The thrombosis can be cardiac, intra-abdominal, cerebral, cutaneous, and deep venous. Among them, deep venous thrombosis (DVT) is a rare, but often a fatal complication of HES (Gao et al. 2016). Thrombotic thrombocytopenic purpura (TTP) is another very rare presentation with HES (Liapis et al. 2005). Here we present, two patients with multiple venous thrombosis and TTP, respectively as a complication of HES.

## CASE REPORT

### Case 1

A 21-year-old lady, presented with a 3-months history of high grade fever with nausea, diarrhoea, weight loss of about 5 kg within that duration and bilateral upper limb swelling. There was no history of trauma, allergy or consuming traditional medications. She was pale with palpable multiple bilateral cervical lymphadenopathy,

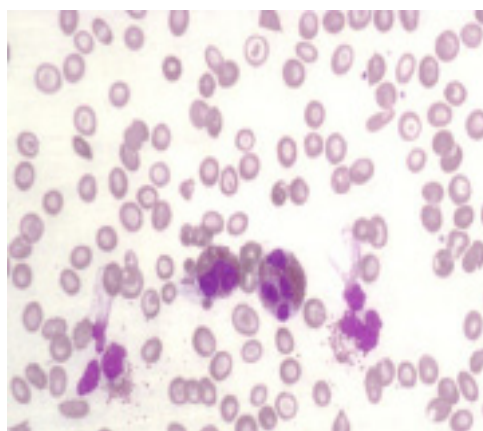


Figure 1(A): Peripheral blood film; Eosinophilia showing two intact hypersegmented and partial degranulation of eosinophils (Wright stain; x 40 objective).

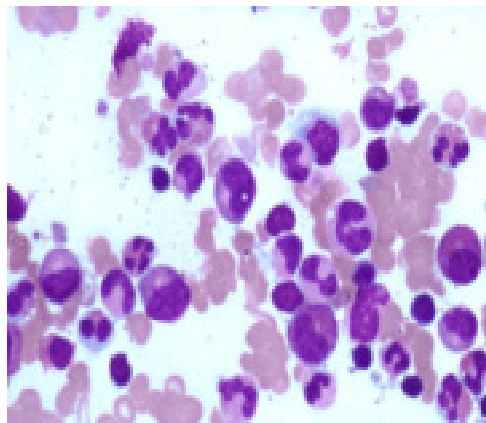


Figure 1(B): Bone marrow aspirate; some of the eosinophils are dysplastic with hypersegmented nucleus (MGG stain, x 40 objective).

bilateral upper limb swelling and hepatomegaly. Laboratory evaluation revealed, haemoglobin-8.5 g/dL, white cell count (WBC)- $61.8 \times 10^9/L$ , predominantly with neutrophilia (47.3%) and marked eosinophilia (42.7%), platelet count- $233 \times 10^9/L$ . Erythrocytes sedimentation rate and C-reactive protein (CRP) were high with normal prothrombin time (PT) and activated prothrombin time (APTT). Peripheral blood film (PBF) (Figure 1A) showed mild hypochromic microcytic anaemia with some target cells and pencil cells. Leucocytosis was evidenced with predominantly eosinophilia showing partial degranulation and hypersegmented nucleus. Bone marrow aspirate (BMA) showed normocellular bone marrow fragments with cellular cell trails. All stages of granulocytic maturation series were present but increased in the eosinophils and their precursors (50% of the nucleated cells) (Figure 1B). There was no excess of blast.

There was a mild increase in serum

B12 concentration (740 pmol/L), reduced serum folate (4 pmol/L), and normal serum iron, total iron binding capacity (TIBC) and serum ferritin. Total protein and albumin levels were normal. Panel immunoglobulin showed an increased IgG level of 2280 mg/dL with normal IgM and IgA levels. Anti-nuclear antibody (ANA) was positive (1:640 dilution) however anti-double stranded deoxyribonucleic acid (DNA) was negative. Her stool examination was negative for ova and parasitic infestation. In view of high fever, serial blood cultures, throat swab, and viral screening were performed and all were negative. Conventional cytogenetics analysis and fluorescence in situ hybridization did not detect any common chromosomal abnormality. Molecular analysis by polymerase chain reaction showed no BCR/ABL translocation. A diagnosis of idiopathic HES was made after excluding secondary causes of eosinophilia.

Computed Tomography (CT) scan of neck, thorax and abdomen showed multiple cervical and anterior mediastinal lymphadenopathy and right hilar lymphadenopathy with parenchymal involvement. In addition, thrombosis was found in the left internal jugular vein (IJV), both external jugular veins (EJV) and left subclavian vein (LScV). Ultrasound Doppler of the neck and upper thorax also showed similar findings of extensive venous thrombosis of the left IJV, EJV and brachiocephalic veins (BcV). Ultrasound of the enlarged liver exhibited homogenous enhancement, indicating infiltration. Later, the patient developed shortness of breath and

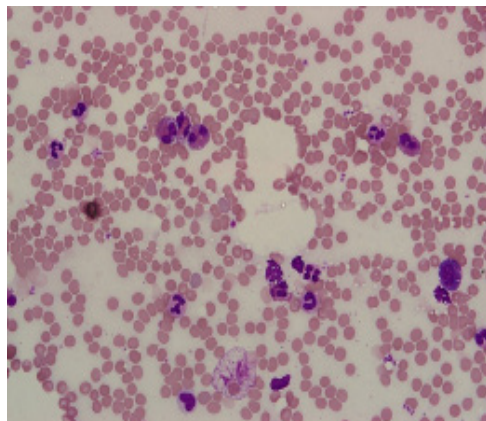


Figure 2(A): Peripheral blood film; Hyper eosinophilia with presence eosinophilic precursors (Wright stain x 40 objective).

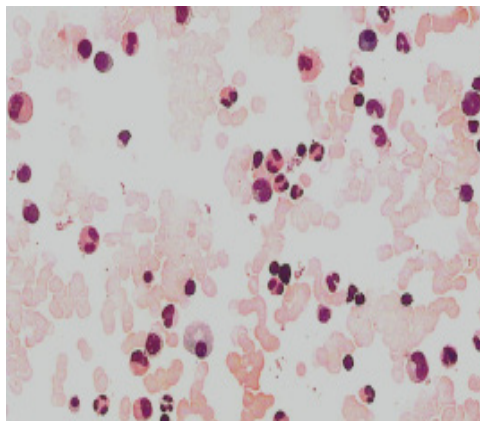


Figure 2(B): Bone marrow aspirate; Hyper eosinophilia (MGG stain x20 objective).

transferred to the intensive care unit (ICU) for close monitoring. Repeat CT scan showed multiple thoracic deep vein thromboses (DVT). She was initially started on intravenous heparin and later changed to subcutaneous low molecular weight heparin (LMWH). Chest radiograph showed pleural effusion with consolidation. Patient was started on intravenous Tazoscin 4.5 gram TDS, tablet Prednisolone 35 mg daily and tablet Hydroxyurea 1 gram BD. Her eosinophils and neutrophils count gradually reduced and clinically patient was able to be extubated.

However, two weeks later, she suddenly collapsed and developed left sided body weakness. CT scan showed massive right occipital and bilateral centrum semiovale infarcts with possibility of cortical vein thrombosis on the left parietal convexity. Unfortunately, she succumbed to the disease despite all the supportive management.

### Case 2

A 20-year-old lady admitted with 2 months history of intermittent fever associated with facial oedema and rashes particularly over the upper-limbs and hips. Clinically, she was febrile and tachycardic with hepatomegaly. Her PBF showed leucocytosis ( $20 \times 10^9/L$ ), predominantly absolute neutrophilia (51%) and eosinophilia (36%). Platelet count was  $300 \times 10^9/L$ . The impression at that time was a hyper-allergic reaction with concomitant infection. She was started on intravenous Ceftriaxone. However, she progressively deteriorated with worsening of the rash, facial oedema and developed pleural effusion with gross ascites. She persistently showed leucocytosis ( $19.1 \times 10^9/L$ ), predominantly with hyper-eosinophilia (49%) and neutrophilia (39%). Pleural tapping was done and reported as exudative fluid with absence of any abnormal cells or acid-fast bacilli, but with higher eosinophil count.

The BMA was normocellular but an increased eosinophil count was noted (29%) with no excess of blast (Figure 2A & 2B). There was no evidence of lymphoma or leukaemia. Molecular and cytogenetic studies did not detect any abnormalities. After excluding the possible secondary causes, this patient was also diagnosed with idiopathic HES.

Treatment with high dose methylprednisolone was started and clinically patient responded well with gradual drop in the blood eosinophil count. The patient was discharged with slow tapering of oral prednisolone. However, subsequently she presented again with fever and a sudden onset of bilateral loss of vision. Eye examination revealed bilateral retinal oedema. There was no evidence of vasculitis. Some degree of macula oedema was present. She was diagnosed to have bilateral retinal infarct. At that time, her PBF showed pancytopenia with haemoglobin 6.4 g/dL, platelet count  $34 \times 10^9/L$ , WBC count  $2.3 \times 10^9/L$ , haematocrit 0.20% and evidence of microangiopathic haemolytic anaemia with presence of macrocytosis, polychromasia, microspherocytes, schistocytes and basophilic stippling. Numerous nucleated red cells and pinched cells with occasional immature WBC were seen. Platelet count was reduced but some large platelets were seen with no platelet clumping. Other evidence of haemolysis were an increased reticulocyte count (19.27%) as well as increased liver enzymes with LDH (5613), unconjugated bilirubin (27 mmol/L), ALT (69IU/L) and AST (136 IU/L). The coagulation

profile was prolonged with PT 13.5 seconds, APTT 46.7 seconds and INR 1.4. There was also evidence of acute renal failure with increase in urea (25.1 mmol/L) and creatinine (209 mmol/L). Sodium and potassium levels were normal, 132 mmol/L and 4.7 mmol/L respectively. Ultrasound of the urinary system did not find any evidence of obstructive uropathy. The C3 and C4 levels were low, 58 mg/dL and 10 mg/dL respectively. The CRP level was high, 5.3 mg/dL (0.0-0.8 mg/dL). The IgG anti-cardiolipin was raised, 7 units (0-5 units). However, ANF, ENA screen and ANCA (IF) were negative.

While in the ward, she developed a few episodes of seizure. A serial CT brain reported to be normal. She also developed acute lung injury secondary to aspiration pneumonia. She was put on maintenance intravenous Phenytoin and intravenous Valproate to control the recurrent fits. At this juncture, in view of the history of fever, thrombocytopenia, haemolytic anaemia, acute renal failure and neurological deficit, a diagnosis of TTP was made and the patient was commenced on plasmapheresis with total plasma exchange. Patient's condition slowly improved and the platelet count reached  $150 \times 10^9/L$  after 25 cycles of plasmapheresis. During the treatment, she received multiple transfusions with fresh frozen plasma, cryoprecipitate and platelet concentrate. Nevertheless, the hypoxia which she sustained during the multiple episodes of fits had resulted in permanent brain injury and thus requiring a tracheostomy for prolonged ventilatory support.

## DISCUSSION

These two case reports illustrate two cases of HES associated with multiple simultaneous venous thromboses and TTP respectively. Both these conditions are rare complication of idiopathic HES. Clinical features of idiopathic HES are diversified; varied from asymptomatic to grave symptoms with multiple organ involvement (Swerdlow et al. 2008). The level or duration of eosinophilia does not correspond with the severity of the organs damage (Gotlib 2015). In both these present cases, it could not be ascertained the length of time that the patients were having eosinophilia as the presentation was sudden onset and both patients were purportedly well before then.

Thromboembolic events are a leading cause of morbidity and mortality in HES patients (Gao et al. 2016). The pathogenesis is due to release of different eosinophil-derived mediators and cytokines causing activation and damage of endothelial cells and platelets. In addition, release of tissue factor and plasminogen activator inhibitor from eosinophils may promote thrombogenesis (Simon & Klion 2012; Sui et al. 2013). Immobility, genetic hypercoagulability, hormone therapy or advanced atherosclerosis also plays a part in thrombosis (Sui et al. 2013). Anticoagulation should be considered in the treatment to avoid the fatal complication. The management of these patients remains difficult. In our first patient, although she responded well initially with heparin and other supportive measures, but subsequently, she

succumbed to massive intracerebral thrombosis regardless the burden of eosinophilia was greatly reduced. In HES, recurrence of thrombosis even after reduced eosinophilia may be due to residual endothelial damage from prolonged eosinophilia, warfarin failure, or potentially eosinophil-independent mechanisms (Leon-Ferre et al. 2013). The chronic suppressive treatment for eosinophilia should not be interrupted due to the risk of new thromboembolic events which can be life-threatening (Buyuktas et al. 2012).

The pathogenesis of TTP is due to the deficiency of A Disintegrin-like and Metalloprotease with Thrombospondin Type-1 Motif-13 (ADAMTS-13) (Ohguchi et al. 2009). Other susceptibility factors such as endothelial cell damage and increased quantities of unusually large multimers of vWF may also contribute (Rick et al. 2004). The intravascular degranulation of eosinophils readily leads to complex formation due to the intense basic property of the granules. This facilitates activation of the complement system, kinin generation and coagulation, leading to endothelial damage. Therefore, the endothelial damage together with a decrease activity of ADAMTS-13, may have contributed to the TTP in the second case. However, the enzyme activity cannot be ascertained as its assessment is highly specialized and are not available at our centre. There are only few reported cases of TTP associated with HES. Two reported cases of HES with TTP were caused by vascular endothelial damage by eosinophil (Liapis et al. 2005). Another two cases developed

secondary to the inhibitor against ADAMTS-13, and one patient was suspected secondary to drug imatinib-mesylate induced (Ohguchi et al. 2009; Al Aly et al. 2005).

It is important to diagnose the TTP properly to reduce the mortality with the prompt delivery of plasma exchange. Therefore, like any other acute haematological malignancies rapid recognition is necessary to initiate treatment decision and disease monitoring (Hafiza et al. 2011; Narisa et al. 2013). The untreated mortality of TTP is 90%. However, early death still follows and approximately half of the deaths in UK occurred within 24 hour of presentation, primarily in women (Scully et al. 2008). In our present case, although the patient survives, she sustained brain hypoxia leading to brain damage and requiring tracheostomy.

## CONCLUSION

In conclusion, these are the two cases of idiopathic HES, a rare disorder; diagnosed based on the clinical presentation and bone marrow biopsy with the exclusion of secondary causes. The first case presented multiple simultaneous thromboses and patient ultimately succumbed to death secondary to the complications. The second case was complicated with TTP and managed by plasma exchange. Proper management and earlier diagnosis can help to extend the survival in HES patients. Nevertheless, this disease remains difficult to manage. Therefore, careful monitoring of the patients is very important and

treatment should be initiated as early as possible.

## REFERENCES

- Al Aly, Z., Philoctete Ashley, J.M., Gellens, M.E., Gonzalez, E.A. 2005. Thrombotic thrombocytopenic purpura in a patient treated with imatinib mesylate: true association or mere coincidence? *Am J Kidney Dis* **45**: 762-8.
- Buyuktas, D., Eskazan, A.E., Borekci, S., Umut, S., Ongen, Z., Tuzuner N., Soysal T. 2012. Hypereosinophilic syndrome associated with simultaneous intracardiac thrombi, cerebral thromboembolism, and pulmonary embolism. *Internal Medicine* **51**(3): 309-13.
- Gao, S., Wei, W., Chen, J., Tan, Y., Yu, C., Litzow, M.R., Liu, Q. 2016. Hypereosinophilic syndrome presenting with multiple organ infiltration and deep venous thrombosis, A case report and literature review. *Medicine* **95**: 35 (e4658).
- Gotlib, J. 2015. World Health Organization-defined eosinophilic disorders: 2015 update on diagnosis, risk stratification, and management. *Am J Hematol* **90**(11): 1077-89.
- Hafiza, A., Azura, A.H., Azma, R.Z., Azlin, I., Zarina, A.L., Hamidah, N.H. 2011. Early lineage switch from T-acute lymphoblastic leukaemia to common B-ALL. *Med & Health* **6**(2): 131-8.
- Leon-Ferre, R.A., Weiler, C.R., Halldanarson, T.R. 2013. Hypereosinophilic syndrome presenting as an unusual triad of eosinophilia, severe thrombocytopenia, and diffuse arterial thromboses, with good response to mepolizumab. *Clinical Advances in Hematology & Oncology* **11**(5): 317-9.
- Liapis, H., Ho, A.K., Brown, D., Mindel, G., Gleich, G. 2005. Thrombotic microangiopathy associated with the hypereosinophilic syndrome. *Kidney Int* **67**: 1806-11.
- Narayan, S., Ezughah, F., Standen, G.R., Pawade, J., Kennedy, C.T. 2003. Idiopathic hypereosinophilic syndrome associated with cutaneous infarction and deep venous thrombosis. *Br J Dermatol* **148**: 817-20.
- Narisa, S.S., Shanti, P., Jeevinesh, N.A., Sakthiswary, R. 2013. Eosinophilic gastroenteritis as the initial manifestation of hypereosinophilic syndrome. *Med & Health* **8**(2): 94-9.
- Ohguchi, H., Sugawara, T., Harigae, H. 2009. Thrombotic thrombocytopenic purpura complicated with hypereosinophilic syndrome. *Inter Med* **48**: 1687-90.
- Rick, M.E., Austin, H., Leitman, S.F., Krizek, D.M., Aronson, D.L. 2004. Clinical usefulness of a functional assay for the von Willebrand factor cleaving protease (ADAMTS 13) and its inhibitor



- in a patient with thrombotic thrombocytopenic purpura. *Am J Hematol* 75(2): 96-100.
- Scully, M., Yarranton, H., Liesner, R., Cavenagh, J., Hunt, B., Benjamin, S., Bevan, D., Mackie, I., Machin, S. 2008. Regional UK TTP registry: correlation with laboratory ADAMTS 13 analysis and clinical features. *British Journal of Haematology* 142: 819-26.
- Simon, H.U, Klion, A. 2012. Therapeutic approaches to patients with hypereosinophilic syndromes. *Semin Hematol* 49(2): 160-70.
- Sui, T., Li, Q., Geng, L., Xu, X., Li, Y. 2013. A case of hypereosinophilic syndrome presenting with multiorgan thromboses associated with intestinal obstruction. *Turk J Hematol* 30: 311-4.
- Swerdlow, S.H., Campo, E., Harris, N.L., Jaffe, E.S., Pileri, S.A., Stein, H., Thiele, J., Vardiman, J.W. Chronic eosinophilic leukaemia, not otherwise specified. 2008. In *WHO Classification of Tumours of Haematopoietic and Lymphoid Tissues* 4<sup>th</sup> edition. Lyon: International Agency for research on Cancer; 51-53.

Received: 16 Apr 2018

Accepted: 13 Aug 2018