

Kent Academic Repository

Full text document (pdf)

Citation for published version

Song, Wenhua, Zheng, Yi, Dong, Mei, Zhong, Lin, Bazoukis, George, Perone, Francesco, Li, Guangping, Ng, Chi Fai, Baranchuk, Adrian, Tse, Gary and others (2023) Electrocardiographic features of immune checkpoint inhibitor-associated myocarditis. *Current problems in cardiology*, 48 (2). ISSN 1535-6280.

DOI

<https://doi.org/10.1016/j.cpcardiol.2022.101478>

Link to record in KAR

<https://kar.kent.ac.uk/98195/>

Document Version

Publisher pdf

Copyright & reuse

Content in the Kent Academic Repository is made available for research purposes. Unless otherwise stated all content is protected by copyright and in the absence of an open licence (eg Creative Commons), permissions for further reuse of content should be sought from the publisher, author or other copyright holder.

Versions of research

The version in the Kent Academic Repository may differ from the final published version.

Users are advised to check <http://kar.kent.ac.uk> for the status of the paper. **Users should always cite the published version of record.**

Enquiries

For any further enquiries regarding the licence status of this document, please contact:

researchsupport@kent.ac.uk

If you believe this document infringes copyright then please contact the KAR admin team with the take-down information provided at <http://kar.kent.ac.uk/contact.html>



Electrocardiographic Features of Immune Checkpoint Inhibitor-Associated Myocarditis

Wenhua Song^{a,†}, Yi Zheng^{a,†}, Mei Dong^b, Lin Zhong^b,
George Bazoukis^{c,d}, Francesco Perone^e,
Guangping Li^a, Chi Fai Ng^f, Adrian Baranchuk^g,
Gary Tse^{a,h,i,j,**}, and Tong Liu^{a*}

From the ^a Tianjin Key Laboratory of Ionic-Molecular Function of Cardiovascular Disease, Department of Cardiology, Tianjin Institute of Cardiology, Second Hospital of Tianjin Medical University, Tianjin, China, ^b Department of Cardiology, Affiliated Yantai Yuhuangding Hospital of Qingdao University, Yantai Shandong, China, ^c Department of Cardiology, Larnaca General Hospital, Larnaca, Cyprus, ^d Department of Basic and Clinical Sciences, University of Nicosia Medical School, 2414, Nicosia, Cyprus, ^e Cardiac Rehabilitation Unit, Rehabilitation Clinic "Villa delle Magnolie", Castel Morrone, Caserta, Italy, ^f SH Ho Urology Centre, Department of Surgery, Faculty of Medicine, The Chinese University of Hong Kong, Hong Kong, China, ^g Division of Cardiology, Kingston Health Science, Center, Queen's University, Kingston, Ontario, Canada, ^h Epidemiology Research Unit, Cardiovascular Analytics Group, Hong Kong, China, ⁱ Kent and Medway Medical School, University of Kent and Canterbury Christ Church University, Canterbury, Kent, UK and ^j School of Nursing and Health Studies, Hong Kong, Metropolitan University, Hong Kong, China.

Abstract: Immune checkpoint inhibitors (ICIs) are associated with immune-related adverse events including myocarditis, whilst improving cancer-related outcomes. There is thus a clinical need to identify electrocardiographic manifestations of ICI-related myocarditis to guide clinical management. PubMed was searched for clinical studies and case reports describing electrocardiographic changes in patients with ICI-related myocarditis. A total of 6 clinical studies and 79 case reports were included. This revealed a range of presentations for patients on ICIs, including supraventricular arrhythmias, ventricular arrhythmias and heart block, and new changes of ST-T

† Co-first authors/equal contributions.

Conflicts of interest: The authors declare no conflict of interest.

Disclosures: None. This is an open access article under the CC BY license

(<http://creativecommons.org/licenses/by/4.0/>)

Curr Probl Cardiol 2022;48:101478

0146-2806/\$ – see front matter

<https://doi.org/10.1016/j.cpcardiol.2022.101478>

segment unrelated to coronary artery disease, ST-segment elevation or depression and T-wave abnormalities. Several patients showed low voltages in multiple leads and new onset Q-wave development. Patients with ICI-related myocarditis may develop new arrhythmia and ST-T changes, and infrequently low voltages in multiple leads. (Curr Probl Cardiol 2022;48:101478.)

Background

The development of immune checkpoint inhibitors (ICIs) represents a significant breakthrough in tumor therapy. Despite showing better efficacy than traditional anticancer agents, the use of ICIs can lead to potentially life-threatening immune-related adverse events, including cardiovascular complications such as myocarditis.^{7,70,72,103} ICI-induced myocarditis is rare, with an estimated incidence ranging from 0.1% to 1%. Previous findings have showed that ICI-related myocarditis usually occurs in the early stage of ICI treatment and could deteriorate rapidly with a fatality rate up to 30-50%.³¹ Therefore, it is necessary to ensure early identification and diagnosis of myocarditis in patients receiving ICIs.

Recent reports have demonstrated the involvement of the cardiac conduction system, which can lead to cardiac arrhythmias⁷² and have a negative impact on the prognosis of the patients. Since electrocardiogram (ECG) is a simple, noninvasive and cheap investigation, it could be used as a first line screen tool for cardiovascular abnormalities in ICI users. Therefore, in this systematic review, we will summarize the electrocardiographic characteristics of patients with ICI-related myocarditis and hope to provide early recognition to this potentially fatal complication.

Methods

Data sources and searches

PubMed was systematically searched by two cardiologists using the keywords “(immune checkpoint inhibitor) AND (myocarditis)” for articles published on or before October 8, 2022. By reading the full texts, clinical studies and case reports that meet the following conditions were included. The inclusion criteria were as follows: (1) ICI-associated myocarditis was clearly diagnosed by the patient’s ICI medication,

comprehensive clinical manifestations and laboratory tests, etc.; (2) standard

12-lead electrocardiogram was provided; (3) for clinical studies, patients were identified as suffering from ICI-related myocarditis with the provision of ECG findings; (4) publication in English language. References which were in line with the criteria were also included. The following details were extracted from each study: age, sex, type of malignant tumor and ICIs.

A total of 79 case series or reports^{1-6,8-12,15-18,20-23,25-30,32-39,41,42,44,45,47-49,52-54,56,58,60-66,68,69,71,73-75,77-86,88,89,91-98,100} and 6 clinical studies^{13,18,50,67,88,103} were included. The demographic characteristics (such as age, sex), type of tumor and ICI prescribed, symptoms, clinical examinations, cardiological measures and the outcome of patients during hospitalization were obtained.

Electrocardiographic evaluation

For clinical studies, the ECG findings and characteristic changes in patients with ICI myocarditis were extracted by 2 cardiologists, and cross-validated. Similarly, for case reports, the standard 12-lead ECG provided were analyzed by 2 cardiologists independently, with any disagreements resolved by a third cardiologist.

Statistical analysis

The baseline characteristics and ECG findings were expressed as frequency and proportion. Continuous variables were provided as median or mean values.

Results

Case report

A total of 418 cases were found in the literature. Of these, 252 cases were excluded because they provided no descriptions on the relationship between myocarditis and ECG findings, and another 81 cases were also excluded as no ECGs were shown. Finally, 79 studies were included. Nine studies were case series, 70 were case reports, with a total of 91 patients included (Fig 1). Of these, 31% were women (28/91), with a median age of 68 years. The commonest indication for ICI use was lung cancer (n = 23, 25.27%), followed by melanoma (n = 16, 17.58%) and cancers affecting the urogenital and digestive tract (n = 14, 15.38%, respectively). Amongst the included cohort, 38.46% and 31.87% were

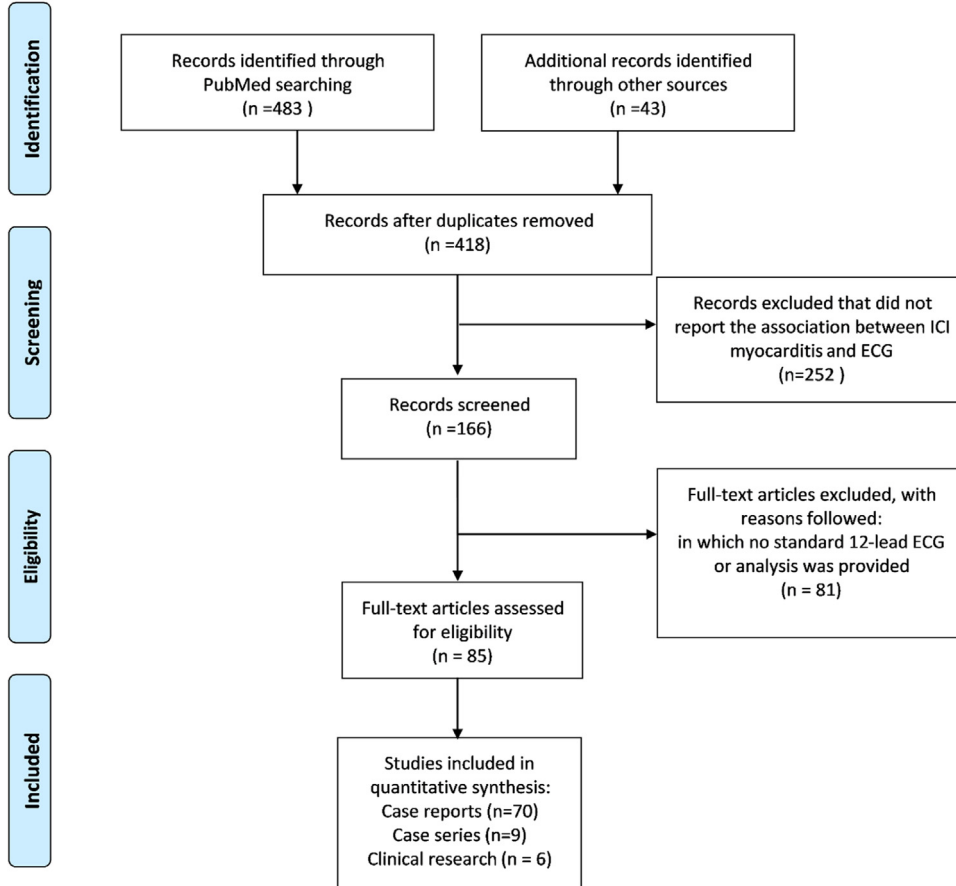


FIG 1. Flow diagram of the study selection process.

treated with nivolumab and pembrolizumab, respectively, followed by ipilimumab (18.68%), camrelizumab (7.69%), bevacizumab (5.49%), sintilimab (4.40%), and durvalumab (3.30%). The commonest symptoms reported were dyspnea (42.86%) and fatigue (41.76%). The others included fever (10.99%), palpitation (12.09%), and chest pain (9.89%). Seven patients (7.69%) were asymptomatic and were diagnosed during

TABLE 1. Clinical characteristics of the patients included in this meta-analysis

Clinical characteristics	N(%)
Age(year)	68 (60.00,74.00)
Female(%)	28 (30.77%)
Tumor	
Gastrointestinal tumor(%)	14 (15.38%)
Urinary tumor(%)	14 (15.38%)
Lung tumor(%)	23 (25.27%)
Thymoma(%)	9 (9.89%)
Melanoma (%)	16 (17.58%)
Hematologic malignancy (%)	5 (5.49%)
Other solid tumors (%)	10 (10.99%)
ICI	
Camrelizumab (%)	7 (7.69%)
Nivolumab (%)	35 (38.46%)
Ipilimumab (%)	17 (18.68%)
Pembrolizumab (%)	29 (31.87%)
Sintilimab (%)	4 (4.40%)
Durvalumab (%)	3 (3.30%)
Bevacizumab (%)	5 (5.49%)
Others(%)	9 (9.89%)
Duration of ICI therapy(days)*	21 (16,42)
Presenting signs/symptom	
Fever (%)	10 (10.99%)
Fatigue/ shortness of breath (%)	38 (41.76%)
Dyspnea (%)	39 (42.86%)
Chest pain (%)	9 (9.89%)
Palpitations (%)	11 (12.09%)
Asymptomatic (%)	7 (7.69%)
Cardiac intervention	
Pacemaker (%)	32 (35.16%)
ICD(%)	2 (2.20%)
IABP(%)	3 (3.30%)
ECMO(%)	1 (1.10%)
Outcome	
Dead(%)	40 (43.96%)
Alive(%)	50 (54.94%)
NA(%)	1 (1.10%)

ICI, immune checkpoint inhibitor; ICD, implantable cardioverter defibrillator; IABP, intra-aortic balloon pump; ECMO, extracorporeal membrane oxygenation; NA, not available.

*Two cases did not report the time from the administration of ICI to the date of diagnosis of ICI myocarditis, n = 89.

their pretreatment preparation for ICI treatment (Table 1). The median time from when the first initiation of ICI to myocarditis occurred is 21 days. During hospitalization, in addition to hormone therapy, a total of 32 (35.16%) patients received temporary or permanent pacemaker implantation, and a small number of patients received advanced life support therapy with intra-aortic balloon pumps (3/91) or extracorporeal membrane oxygenation (1/91). The all-cause mortality was 43.96% (40/91) (Table 1).

The electrocardiogram findings are shown in Table 2. A total of 86 patients had new changes in ECG compared to the baseline. The manifestations described were arrhythmias, conduction block, ST-T changes, T-wave abnormalities, new onset Q-wave, and low voltages in multiple leads. Arrhythmias were more common in patients with ICI-related myocarditis and can be manifested as supraventricular and ventricular arrhythmias. For supraventricular arrhythmias, the commonest type was sinus tachycardia (12.09%), of which one patient had transient atrial fibrillation during hospitalization. In addition, there were 5 cases of atrial fibrillation or flutter and one case of sinus arrest followed by atrial fibrillation. It should be noted that among the case studies included, 6 patients developed ventricular tachycardia (Fig 2). Of these, one patient was in critical condition, developing atrial fibrillation and high-degree atrioventricular block. In addition, premature atrial contractions (n = 3) and

TABLE 2. Electrocardiographic findings of patients included in this meta-analysis

Electrocardiographic findings		N(%)
Sinus arrhythmia	Sinus arrest	1 (1.10%)
	Sinus tachycardia	11 (12.09%)
	Sinus bradycardia	1 (1.10%)
Atrial arrhythmia	Premature atrial contractions	3 (3.30%)
	Atrial flutter	2 (2.20%)
	Atrial fibrillation	3 (3.30%)
Ventricular arrhythmia	Premature ventricular contractions	6 (6.59%)
	Ventricular tachycardia	6 (6.59%)
Atrioventricular block	First-degree atrioventricular block	6 (6.59%)
	Second-degree atrioventricular block	2 (2.20%)
	Third-degree atrioventricular block	19 (20.88%)
Bundle branch block	Left bundle branch block	8 (8.79%)
	Right bundle branch block	18 (19.78%)
ST-T segment changes	ST-segment elevation	19 (20.88%)
	ST segment depression	5 (5.49%)
	T wave inversion	6 (6.59%)
Others	New Q wave	1 (1.10%)
	Low voltage	3 (3.30%)
	No change	5 (5.49%)

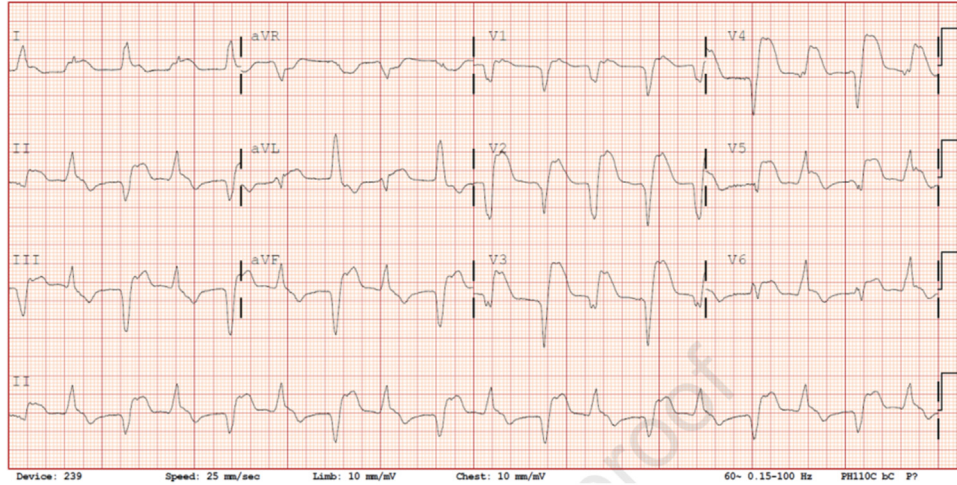


FIG 2. ECG reproduced from Yogasundaram et al. with permission.⁹⁵ A 69-year-old man with metastatic castration-resistant prostate cancer admitted to hospital 74 days after treatment with pembrolizumab, and the electrocardiogram demonstrated bidirectional accelerated idioventricular rhythm with the alternating QRS axis. Retrograde p waves are best visualized in lead V1.

premature ventricular contractions (n = 6) were also observed. For conduction abnormalities, atrioventricular block and bundle branch block were reported. Twenty-seven patients (27/91, 29.67%) had atrioventricular block, of which the commonest type was complete atrioventricular block (19/27, 70.37%) (Fig 3). Patients with complete atrioventricular block often suffered from severe conditions, with complications such as ventricular tachycardia (n = 2) and left bundle branch or right bundle branch block. The number of patients had first-degree atrioventricular block and second-degree atrioventricular block were 6 (22.22%) and 2 (7.41%), respectively. Bundle branch block included left bundle branch block (n = 8) and right bundle branch block (n = 18). Patients also developed left anterior hemiblock block (n = 2) or left posterior hemiblock (n = 1), or complete atrioventricular block (n = 1). Interestingly, one patient had a first electrocardiogram showed left bundle branch block, followed by right bundle branch block several days later. Finally, ST-T changes unrelated to coronary artery disease were reported in ICI-related myocarditis, with ST segment elevation found in 19 cases, ST segment depression in five patients and T-wave inversion in 6 patients. In addition, new onset Q-wave was observed in one patient in an absence of coronary artery lesions from coronary angiography. Rarely, low voltages in multiple leads were observed (n = 3), which was infrequently associated with pericardial effusion. Only 5 patients showed no significant dynamic changes in their ECG when compared to their baseline ECG (Table 2).

Clinical studies

A total of 6 clinical studies were included, all of which were retrospective studies. No prospective clinical studies were identified. One study was published in 2018, two studies in 2020 and three studies in 2021. Two studies were retrospectively analyzed and reported by a single center, with a relatively small sample size. Of the other four studies, the largest consisted of 140 patients with ICI-related myocarditis matched with 179 ICI users without myocarditis. In this study, the type of tumor was not limited, and it was found that the duration of QRS was closely related to MACE development. Another study suggests that patients with ICI-related myocarditis had a faster heart rate, longer QRS and QTc durations on the ECG compared to those without myocarditis. One case-control study including patients with ICI-related myocarditis explored the effects of intensified immunosuppressive therapy (IIST) on the clinical outcome of patients. Previous studies have found that patients who need IIST tend

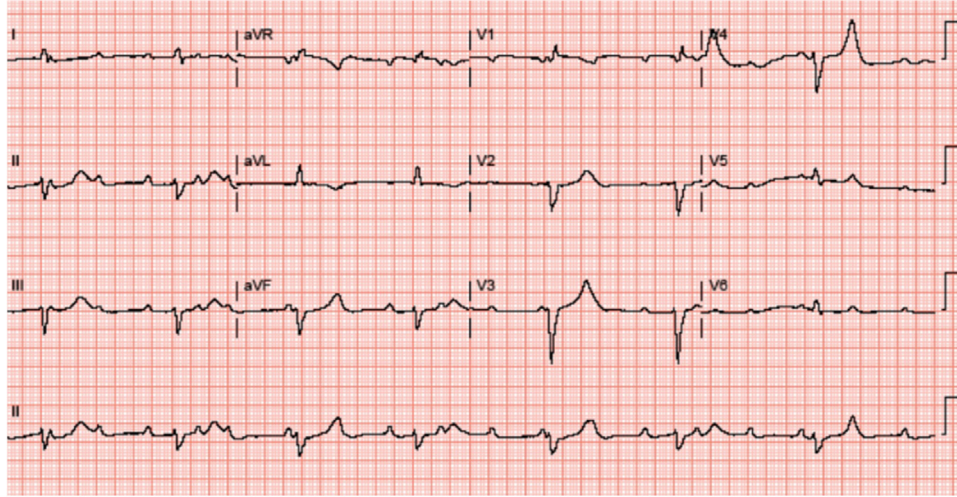


FIG 3. ECG reproduced from Bukamur et al. with permission.¹¹ An 88-year-old woman with squamous cell carcinoma of the lung admitted to hospital 2 cycles after treatment with nivolumab, and during her hospital stay, she developed complete atrioventricular block as seen in the electrocardiogram.

TABLE 3. Summary of clinical studies included in this review

Author	Year	Study Design	No. of Patients	Cancer Type	ICI type	ECG features	Major findings
Chen R et al.	2021	retrospective	10 myocarditis cases	Solid tumors	anti- PD1 anti- PDL1	Heart block	Cardiac conduction disorders including atrioventricular block (AVB) and bundle branch block were found in seven (70%) patients. One patient presented III°AVB, which eventually progressed to complete AVB. In total, three (30.0%) patients experienced more than one type of life-threatening complication. Two (20.0%) patients were admitted to ICU, three (30.0%) patients were put on mechanical ventilation, two (20.0%) patients received the plasma exchange therapy, and one patient was implanted with a pacemaker. Two (20.0%) of the patients succumbed and died, with a median duration of 7.5 days from diagnosis of cardiac immune-related adverse effects to death.
Zlotoff DA et al.	2021	retrospective	140 myocarditis cases and 179 controls treated with ICI	Various	anti- PD1 anti- PDL1 anti- CTLA4	QRS duration	The QRS duration is increased in ICI myocarditis and is associated with increased MACE risk. After adjustment, each 10 ms increase in the QRS duration conferred a 1.3-fold increase in the odds of MACE.
Power JR et al.	2021	retrospective	147 myocarditis cases	NA	NA	heart rate; QRS and QT corrected for heart rate; SokolowLyon Index	Presenting ECG showed elevated heart rate, prolonged QRS and prolonged QT corrected for heart rate compared with baseline ECG. SokolowLyon Index (sum of S wave in V1 and R wave in V5 or V6) showed a significant decrease in voltage from baseline. The incidence of left bundle-branch block and sinus tachycardia was increased versus baseline. In aggregate, conduction disorders

(continued on next page)

Mahmood SS et al.	2018	retrospective	35 myocarditis cases and 105 controls treated with ICI	Various	anti- PD1 anti- PDL1 anti- CTLA4	Heart block	and repolarization abnormalities were significantly increased. Patients with ICI-myocarditis were more likely to experience all-cause mortality within 30 days if they developed complete heart block or life-threatening ventricular arrhythmias. Nearly one-half of all myocarditis cases experienced a MACE: cardiovascular death (n = 6), cardiogenic shock (n = 3), cardiac arrest (4), or CHB (n = 3). Causes of death included 2 sudden deaths, 1 witnessed and 1 unwitnessed, 2 documented ventricular arrhythmias, and 2 of progressive cardiogenic shock.
Cautela J et al.	2020	case-control study	60(36 were treated with intensified immunosuppressive therapy and 24 were not)	Various	anti- PD1 anti- PDL1 anti- CTLA4	Heart block; arrhythmia	Patients requiring intensified immunosuppressive therapy (IIST) had a significantly higher prevalence of sustained ventricular arrhythmia, complete atrioventricular block, cardiogenic shock and troponin elevation. Moreover, they were more likely to have other immune-related adverse events simultaneously, especially myositis and myasthenia gravis. Patients who required IIST were more likely to die from any cause.
Wang F et al.	2020	retrospective	3 myocarditis cases	Solid tumors	anti-PD1 anti-PDL1	Heart block; arrhythmia	One case died on day 56 because of heart and respiratory failure, and the other died on day 34 because of tumor progression. The third case recovered after treatment. The typical clinical manifestations are palpitations, dyspnea, and fatigue. One patient had no clear symptoms. Electrocardiograms showed grade 3 of atrioventricular block and frequent ventricular premature contraction in one case, and frequent ventricular and atrial premature contraction in the other case.

ECG, electrocardiography. ICI, immune checkpoint inhibitor. MACE, major adverse cardiac events.

to have worse overall condition and higher incidence of arrhythmias and malignant cardiovascular events (Table 3).

Discussion

ICIs restore the immune response of CD8+ and CD4+T cells to cancerous tissues by blocking the inhibitory effects of ligand-receptor interactions and have improved the quality of life and survival of patients with many different cancers. However, their immune-related adverse events (IrAEs) affecting different organ systems cannot be neglected.^{19,76,90,101} ICI-related cardiovascular toxicity includes myocarditis, pericarditis, arrhythmia, heart failure, vasculitis and venous thromboembolism.^{14,24,43,51,55,87,99,102} ICI-associated myocarditis is characterized by acute inflammation of the myocardium and may show electrophysiological abnormalities such as ventricular arrhythmias, pulseless electrical activity or complete atrioventricular block, which can progress to acute heart failure or sudden death.^{50,72}

The underlying mechanism may be related to T-cell-mediated cytotoxicity involving the cardiac conduction system. Histological studies have shown that ICI-mediated cardiomyocyte necrosis is characterized by infiltration of CD4+ and CD8+T cells, similar to the development of acute cardiac rejection after transplantation.^{31,46} Lymphocyte infiltration can involve sinoatrial node and atrioventricular node, especially in patients with new-onset bifascicular block and first degree heart block during ICI treatment, reflecting conduction abnormalities across the atrioventricular node or at more distal parts of the conduction system, with a high risk of progression into complete atrioventricular block.⁹² Clinically, patients with complete atrioventricular block and ventricular arrhythmias are often in critical condition with increased mortality. Indeed, ICI-related myocarditis is associated with a fatality rate of 30%-50%,³¹ and thus continuous monitoring of vital signs, cardiac status and ECGs for such patients is needed.

In this study, previously reported cases of ICI-related myocarditis were systematically searched and the ECG findings were summarized. Amongst the 91 patients included, sinus arrhythmias (mostly sinus tachycardia, about 12.09%), atrial fibrillation/atrial flutter, ventricular arrhythmias (including ventricular extrasystole and ventricular tachycardia), heart conduction block, new ST-T abnormalities, T-wave changes, low voltages and new onset Q-waves were detected. Previous clinical studies have reported that ICI-related myocarditis may be associated with ECG changes, mostly arrhythmias. The incidence of ICI-related atrial

arrhythmias is about 1%-3%, of which atrial fibrillation is more common; the incidence of ventricular arrhythmias is about 5%-10%, and is associated with 40% mortality.^{40,57} However, the incidence of complete atrioventricular block is unclear. Power et al. found that nearly 7.5% of patients with ICI-related myocarditis have second degree atrioventricular block and 17% have complete atrioventricular block.⁶⁷ Of the above ECG changes, the incidence of heart block was the highest (about 58.24%), where complete atrioventricular block accounted for 20.88%, followed by right bundle branch block (19.78%).

In addition, we found that ICI-related myocarditis may present with ST-T segment changes unrelated related to coronary artery disease. In this study, 32.97% of the patients had new ST-T changes, excluding vascular lesions after coronary angiography, which could return to normal after high-dose hormone immunosuppressive therapy. Furthermore, some non-specific changes can also be seen in patients with ICI myocarditis, such as multilead low voltage, which may be associated with large pericardial effusion or cardiomyopathy; In addition, there was another patient whose electrocardiogram showed new Q-waves, which ruled out coronary artery disease after coronary angiography. Maybe the appearance of Q-waves was also related to the involvement of ICI related conduction system.

Finally, it is reported that ICI myocarditis usually occurs in the early stage of ICI treatment. Moslehi et al. retrospectively analyzed 101 cases of ICI-associated myocarditis in Vigibase, a pharmacovigilance database by WHO designed to identify drug-associated adverse events. 64% of the patients developed myocarditis after the first or second administration of ICI. The average onset time of myocarditis was 27 days (5-155 days), and 76% occurred in the first six weeks of treatment. Another prospective study of 35 cases of ICI-associated myocarditis from eight centers found that 81% of ICI-associated myocarditis occurred within the first 4 cycles (from the median of 34 days at the beginning of treatment).^{50,59} In their study, the median time from when the first initiation of ICI to myocarditis occurred was 21 days, which was consistent with the previous findings. Patients may have asymptomatic or develop nonspecific symptoms such as progressive fatigue, muscle soreness or weakness, palpitations, chest pain, presyncope, or syncope, shortness of breath and edema. In severe cases, cardiogenic shock or sudden death may occur. Cardiovascular symptoms may be masked or co-present by other irAEs (such as myositis, pneumonia, and hypothyroidism) or lung symptoms associated with malignant tumors or complications.

Limitations and future directions

Some limitations of this study should be recognized. First of all, the case reports included in this study are all from PubMed, and the clinical information available is limited, and the ECG quality of some cases was variable. Second, this study is a retrospective collection of published case reports and clinical studies, there is a specific selection bias. Finally, publication time and attending institutions are different, especially the case reports, diagnosis and treatment programs are different.

By searching the previously published case reports and clinical studies on the changes of ECG in patients with ICI myocarditis, this study emphasizes the feasibility of early identification of ICI-myocarditis using the ECG, which may allow early treatment to improve prognosis. However, the specific physiological mechanism of the disease is not clear and needs to be further explored. Second, most of the clinical reports published are retrospective, and the sample size is relatively small. In the future, clinical studies with a larger sample size are needed to further clarify the ECG manifestations of patients with ICI-related myocarditis.

Conclusion

Myocarditis is a common cardiovascular complication in patients treated with ICIs. The electrocardiogram of patients with ICI-related myocarditis may show new arrhythmias and ST-T changes, and a few patients may show low voltages on multiple leads. A small number of patients had no symptoms and no apparent ECG abnormalities. Monitoring is essential because of its high mortality, with early identification potentially allowing prompt treatment to improve patients' prognosis.

Sources of funding

The work was funded by Tianjin Key Medical Discipline (Specialty) Construction Project (TJYXZDXX-029A).

REFERENCES

1. Aghel N, Gustafson D, Di Meo A, et al. Recurrent myocarditis induced by immune-checkpoint inhibitor treatment is accompanied by persistent inflammatory markers despite immunosuppressive treatment. *JCO Precis Oncol* 2021;5:PO.20.00370.
2. Agrawal N, Khunger A, Vachhani P, et al. Cardiac toxicity associated with immune checkpoint inhibitors: case series and review of the literature. *Case Rep Oncol* 2019;12:260–76.

3. Al-Obaidi A, Parker NA, Choucair K, Alderson J, Deutsch JM. A case of acute heart failure following immunotherapy for metastatic lung cancer. *Cureus* 2020;12:e8093.
4. Alhumaid W, Yogasundaram H, Senaratne JM. Slow bidirectional ventricular tachycardia as a manifestation of immune checkpoint inhibitor myocarditis. *Eur Heart J* 2021;42:2868.
5. Arora P, Talamo L, Dillon P, et al. Severe combined cardiac and neuromuscular toxicity from immune checkpoint blockade: an institutional case series. *Cardiooncology* 2020;6:21.
6. Balanescu DV, Donisan T, Palaskas N, et al. Immunomodulatory treatment of immune checkpoint inhibitor-induced myocarditis: Pathway toward precision-based therapy. *Cardiovasc Pathol* 2020;47:107211.
7. Ball S, Ghosh RK, Wongsangsak S, et al. Cardiovascular Toxicities of Immune Checkpoint Inhibitors: JACC Review Topic of the Week. *J Am Coll Cardiol* 2019;74:1714–27.
8. Behling J, Kaes J, Munzel T, Grabbe S, Loquai C. New-onset third-degree atrioventricular block because of autoimmune-induced myositis under treatment with anti-programmed cell death-1 (nivolumab) for metastatic melanoma. *Melanoma Res* 2017;27:155–8.
9. Berg DD, Vaduganathan M, Nohria A, et al. Immune-related fulminant myocarditis in a patient receiving ipilimumab therapy for relapsed chronic myelomonocytic leukaemia. *Eur J Heart Fail* 2017;19:682–5.
10. Bi H, Ren D, Wang Q, Ding X, Wang H. Immune checkpoint inhibitor-induced myocarditis in lung cancer patients: a case report of sintilimab-induced myocarditis and a review of the literature. *Ann Palliat Med* 2021;10:793–802.
11. Bukamur HS, Mezughi H, Kareem E, Shahoub I, Shweihat Y. Nivolumab-induced third degree atrioventricular block in a Patient with Stage IV Squamous Cell Lung Carcinoma. *Cureus* 2019;11:e4869.
12. Cao J, Li Q, Zhi X, et al. Pembrolizumab-induced autoimmune Stevens-Johnson syndrome/toxic epidermal necrolysis with myositis and myocarditis in a patient with esophagogastric junction carcinoma: a case report. *Transl Cancer Res* 2021;10:3870–6.
13. Cautela J, Zerouh S, Gaubert M, et al. Intensified immunosuppressive therapy in patients with immune checkpoint inhibitor-induced myocarditis. *J Immunother Cancer* 2020;8.
14. Chan JSK, Lakhani I, Lee TTL, et al. Cardiovascular outcomes and hospitalizations in Asian patients receiving immune checkpoint inhibitors: a population-based study. *Curr Probl Cardiol* 2022;48:101380.
15. Chang A, Nasti TH, Khan MK, et al. Myocarditis with radiotherapy and immunotherapy in multiple myeloma. *J Oncol Pract* 2018;14:561–4.
16. Charles J, Giovannini D, Terzi N, et al. Multi-organ failure induced by Nivolumab in the context of allo-stem cell transplantation. *Exp Hematol Oncol* 2019;8(8).
17. Chen Q, Huang DS, Zhang LW, Li YQ, Wang HW, Liu HB. Fatal myocarditis and rhabdomyolysis induced by nivolumab during the treatment of type B3 thymoma. *Clin Toxicol (Phila)* 2018;56:667–71.

18. Chen R, Peng L, Qiu Z, et al. Case report: cardiac toxicity associated with immune checkpoint inhibitors. *Front Cardiovasc Med* 2021;8:727445.
19. Cheung YM, Wang W, McGregor B, Hamnvik OR. Associations between immune-related thyroid dysfunction and efficacy of immune checkpoint inhibitors: a systematic review and meta-analysis. *Cancer Immunol Immunother* 2022;71:1795–812.
20. Cohen M, Mustafa S, Elkherpitawy I, Meleka M. A fatal case of pembrolizumab-induced myocarditis in non-small cell lung cancer. *JACC Case Rep* 2020;2:426–30.
21. Dalal F, Dalal H, Baltz B. Pembrolizumab-induced myocarditis and delayed acute inflammatory demyelinating polyradiculoneuropathy. *Cureus* 2022;14:e27112.
22. Delgado-Lazo V, Abdelmottaleb W, Popescu-Martinez A. Pembrolizumab-induced myocarditis and pancreatitis in a patient with colon cancer: a case report. *Cureus* 2022;14:e26034.
23. Delombaerde D, Vervloet D, Berwouts D, et al. Ipilimumab- and nivolumab-induced myocarditis in a patient with metastatic cholangiocarcinoma: a case report. *J Med Case Rep* 2022;16:275.
24. Dong M, Yu T, Zhang Z, et al. ICIs-related cardiotoxicity in different types of cancer. *J Cardiovasc Dev Dis* 2022;9:203.
25. Fuentes-Antras J, Peinado P, Guevara-Hoyer K, Del Arco CD, Sanchez-Ramon S, Aguado C. Fatal autoimmune storm after a single cycle of anti-PD-1 therapy: A case of lethal toxicity but pathological complete response in metastatic lung adenocarcinoma. *Hematol Oncol Stem Cell Ther* 2020;15:63–7.
26. Ganatra S, Neilan TG. Immune checkpoint inhibitor-associated myocarditis. *Oncologist* 2018;23:879–86.
27. Giancaterino S, Abushamat F, Duran J, Lupercio F, DeMaria A, Hsu JC. Complete heart block and subsequent sudden cardiac death from immune checkpoint inhibitor-associated myocarditis. *HeartRhythm Case Rep* 2020;6:761–4.
28. Gibson R, Delaune J, Szady A, Markham M. Suspected autoimmune myocarditis and cardiac conduction abnormalities with nivolumab therapy for non-small cell lung cancer. *BMJ Case Rep* 2016;2016:bcr2016216228.
29. Guiney TE, Lopes MS, Kalra MK, Mooradian MJ, Neilan TG, Stone JR. Case 30-2019: a 65-year-old woman with lung cancer and chest pain. *N Engl J Med* 2019;381:1268–77.
30. Gupta R, Zaid S, Sayed A, et al. Atezolizumab induced myocarditis on a background of cardiac amyloidosis. *Am J Ther* 2019;26:e795–7.
31. Hu JR, Florido R, Lipson EJ, et al. Cardiovascular toxicities associated with immune checkpoint inhibitors. *Cardiovasc Res* 2019;115:854–68.
32. Hu X, Wei Y, Shuai X. Case Report: glucocorticoid effect observation in a ureteral urothelial cancer patient with ici-associated myocarditis and multiple organ injuries. *Front Immunol* 2021;12:799077.
33. Hyun JW, Kim GS, Kim SH, et al. Fatal simultaneous multi-organ failure following pembrolizumab treatment for refractory thymoma. *Clin Lung Cancer* 2020;21:e74–7.
34. Inayat F, Masab M, Gupta S, Ullah W. New drugs and new toxicities: pembrolizumab-induced myocarditis. *BMJ Case Rep* 2018. 2018.

35. Iwasaki S, Hidaka H, Uojima H, et al. A case of immune checkpoint inhibitor-associated myocarditis after initiation of atezolizumab plus bevacizumab therapy for advanced hepatocellular carcinoma. *Clin J Gastroenterol* 2021;14:1233–9.
36. Jain V, Mohebtash M, Rodrigo ME, Ruiz G, Atkins MB, A B. Autoimmune myocarditis caused by immune checkpoint inhibitors treated with antithymocyte globulin. *J Immunother* 2018;47:332–5.
37. Jespersen MS, Fano S, Stenor C, Moller AK. A case report of immune checkpoint inhibitor-related steroid-refractory myocarditis and myasthenia gravis-like myositis treated with abatacept and mycophenolate mofetil. *Eur Heart J Case Rep* 2021;5: ytab342.
38. Ji H, Wen Z, Liu B, Chen H, Lin Q, Chen Z. Sintilimab induced ICIAM in the treatment of advanced HCC: a case report and analysis of research progress. *Front Immunol* 2022;13:995121.
39. Johnson DB, Balko JM, Compton ML, et al. Fulminant myocarditis with combination immune checkpoint blockade. *N Engl J Med* 2016;375:1749–55.
40. Joseph L, A CN, Patel A, et al. Incidence of cancer treatment induced arrhythmia associated with immune checkpoint inhibitors. *J Atr Fibrillation* 2021;13:2461.
41. Katsume Y, Isawa T, Toi Y, et al. Complete atrioventricular block associated with pembrolizumab-induced acute myocarditis: the need for close cardiac monitoring. *Intern Med* 2018;57:3157–62.
42. Khan A, Riaz S, Carhart R, Jr.? Pembrolizumab-induced mobitz type 2 second-degree atrioventricular block. *Case Rep Cardiol* 2020;2020:8428210.
43. Laenens D, Yu Y, Santens B, et al. Incidence of cardiovascular events in patients treated with immune checkpoint inhibitors. *J Clin Oncol* 2022;JCO2101808.
44. Laubli H, Balmelli C, Bossard M, Pfister O, Glatz K, Zippelius A. Acute heart failure due to autoimmune myocarditis under pembrolizumab treatment for metastatic melanoma. *J Immunother Cancer* 2015;3:11.
45. Lee DH, Armanious M, Huang J, Jeong D, Druta M, Fradley MG. Case of pembrolizumab-induced myocarditis presenting as torsades de pointes with safe re-challenge. *J Oncol Pharm Pract* 2020;26:1544–8.
46. Li KHC, Ho JCS, Recaldin B, et al. Acute cellular rejection and infection rates in alemtuzumab vs traditional induction therapy agents for lung and heart transplantation: a systematic review and meta-analysis. *Transplant Proc* 2018;50:3723–31.
47. Liu Z, Fan Y, Guo J, Bian N, Chen D. Fulminant myocarditis caused by immune checkpoint inhibitor: a case report and possible treatment inspiration. *ESC Heart Fail* 2022;9:2020–6.
48. Lorente-Ros A, Rajjoub-Al-Mahdi EA, Monteagudo Ruiz JM, et al. Checkpoint immunotherapy-induced myocarditis and encephalitis complicated with complete AV block: not all hope is lost. *JACC Case Rep* 2022;4:1032–6.
49. Mahmood SS, Chen CL, Shapnik N, Krishnan U, Singh HS, Makker V. Myocarditis with tremelimumab plus durvalumab combination therapy for endometrial cancer: a case report. *Gynecol Oncol Rep* 2018;25:74–7.
50. Mahmood SS, Fradley MG, Cohen JV, et al. Myocarditis in Patients Treated With Immune Checkpoint Inhibitors. *J Am Coll Cardiol* 2018;71:1755–64.

51. Malaty MA-O, Amarasekera AT, Li C, Scherrer-Crosbie M, Tan TA-O. Incidence of immune checkpoint inhibitor mediated cardiovascular toxicity: A systematic review and meta-analysis. *Eur J Clin Invest* 2022;e13831.
52. Martin Huertas R, Saavedra Serrano C, Perna C, Ferrer Gomez A, Alonso Gordo A. Cardiac toxicity of immune-checkpoint inhibitors: a clinical case of nivolumab-induced myocarditis and review of the evidence and new challenges. *Cancer Manag Res* 2019;11:4541–8.
53. Matsui H, Kawai T, Sato Y, et al. A fatal case of myocarditis following myositis induced by pembrolizumab treatment for metastatic upper urinary tract urothelial carcinoma. *Int Heart J* 2020;61:1070–4.
54. Matsuo K, Ishiguro T, Najama T, Shimizu Y, Kobayashi Y, Mutou M. Nivolumab-induced myocarditis successfully treated with corticosteroid therapy: a case report and review of the literature. *Intern Med* 2019;58:2367–72.
55. Mauro AG, Hunter K, Salloum FN. Cardiac complications of cancer therapies. *Adv Cancer Res* 2022;155:167–214.
56. McDowall LM, Fernando SL, Ange N, Yun J, Chia KKM. Immune checkpoint inhibitor-mediated myocarditis and ventricular tachycardia storm. *HeartRhythm Case Rep* 2019;5:497–500.
57. Mir H, Alhussein M, Alrashidi S, et al. Cardiac complications associated with checkpoint inhibition: a systematic review of the literature in an important emerging area. *Can J Cardiol* 2018;34:1059–68.
58. Miyauchi Y, Naito H, Tsunemori H, et al. Myocarditis as an immune-related adverse event following treatment with ipilimumab and nivolumab combination therapy for metastatic renal cell carcinoma: a case report. *J Med Case Rep* 2021;15:508.
59. Moslehi JJ, Salem J-E, Sosman JA, Lebrun-Vignes B, Johnson DB. Increased reporting of fatal immune checkpoint inhibitor-associated myocarditis. *Lancet* 2018:391.
60. Naganuma K, Horita Y, Matsuo K, et al. An autopsy case of late-onset fulminant myocarditis induced by nivolumab in gastric cancer. *Intern Med* 2022;61:2867–71.
61. Nguyen LS, Bretagne M, Arrondeau J, et al. Reversal of immune-checkpoint inhibitor fulminant myocarditis using personalized-dose-adjusted abatacept and ruxolitinib: proof of concept. *J Immunother Cancer* 2022;10:e004699.
62. Nierstedt RT, Yeahia R, Barnett KM. Unanticipated myocarditis in a surgical patient treated with pembrolizumab: a case report. *A A Pract* 2020;14:e01177.
63. Nishikawa T, Kunimasa K, Ohta-Ogo K, et al. Sinus node dysfunction co-occurring with immune checkpoint inhibitor-associated myocarditis. *Intern Med* 2022;61:2161–5.
64. Nishikawa T, Tamiya M, Ohta-Ogo K, et al. A case of lung cancer with very-late-onset immune checkpoint inhibitor-related myocarditis. *CJC Open* 2022;4:651–5.
65. Osinga TE, Oosting SF, van der Meer P, et al. Immune checkpoint inhibitor-associated myocarditis: case reports and a review of the literature. *Neth Heart J* 2022;30:295–301.
66. Portoles Hernandez A, Blanco Clemente M, Escribano Garcia D, et al. Checkpoint inhibitor-induced fulminant myocarditis, complete atrioventricular block and myasthenia gravis—a case report. *Cardiovasc Diagn Ther* 2021;11:1013–9.

67. Power JR, Alexandre J, Choudhary A, et al. Electrocardiographic manifestations of immune checkpoint inhibitor myocarditis. *Circulation* 2021;144:1521–3.
68. Reddy N, Moudgil R, Lopez-Mattei JC, et al. Progressive and reversible conduction disease with checkpoint inhibitors. *Can J Cardiol* 2017;33. 1335 e1313-1335 e1315.
69. Robert S C ME, DS G. Autoimmune myocarditis with av block: too much of a good thing? *Am Coll Cardiol* 2018. <https://www.acc.org/education-and-meetings/patient-case-quizzes/2018/05/29/06/46/autoimmune-myocarditis-with-av-block>.
70. Saba NF, Mody MD, Tan ES, et al. Toxicities of systemic agents in squamous cell carcinoma of the head and neck (SCCHN); A new perspective in the era of immunotherapy. *Crit Rev Oncol Hematol* 2017;115:50–8.
71. Saibil SD, Bonilla L, Majeed H, et al. Fatal myocarditis and rhabdomyositis in a patient with stage IV melanoma treated with combined ipilimumab and nivolumab. *Curr Oncol* 2019;26:e418–21.
72. Salem J-E, Manouchehri A, Moey M, et al. Cardiovascular toxicities associated with immune checkpoint inhibitors: an observational, retrospective, pharmacovigilance study. *The Lancet Oncology* 2018;19:1579–89.
73. Salido Iniesta M, Lopez Lopez L, Carreras Costa F, Sionis A. A different type of acute myocarditis: a case report of acute autoimmune myocarditis mediated by anti-PD-1 T lymphocyte receptor (pembrolizumab). *Eur Heart J Case Rep* 2020;4:1–6.
74. Schiopu SRI, Kasmann L, Schonermark U, et al. Pembrolizumab-induced myocarditis in a patient with malignant mesothelioma: plasma exchange as a successful emerging therapy-case report. *Transl Lung Cancer Res* 2021;10:1039–46.
75. Shindo A, Yamasaki M, Uchino K, Yamasaki M. Asymptomatic Myocarditis with Mild Cardiac Marker Elevation Following Nivolumab-Induced Myositis. *Int Heart J* 2022;63:180–3.
76. Sonpavde GP, Grivas P, Lin Y, Hennessy D, Hunt JD. Immune-related adverse events with PD-1 versus PD-L1 inhibitors: a meta-analysis of 8730 patients from clinical trials. *Future Oncol* 2021;17:2545–58.
77. Stein-Merlob AF, Hsu JJ, Colton B, et al. Keeping immune checkpoint inhibitor myocarditis in check: advanced circulatory mechanical support as a bridge to recovery. *ESC Heart Fail* 2021;8:4301–6.
78. Su L, Liu C, Wu W, Cui Y, Wu M, Chen H. Successful therapy for myocarditis concomitant with complete heart block after pembrolizumab treatment for head and neck squamous cell carcinoma: a case report with literature review. *Front Cardiovasc Med* 2022;9:898756.
79. Szuchan C, Elson L, Alley E, et al. Checkpoint inhibitor-induced myocarditis and myasthenia gravis in a recurrent/metastatic thymic carcinoma patient: a case report. *Eur Heart J Case Rep* 2020;4:1–8.
80. Tan JL, Mugwagwa AN, Cieslik L, Joshi R. Nivolumab-induced myocarditis complicated by complete atrioventricular block in a patient with metastatic non-small cell lung cancer. *BMJ Case Rep* 2019:12.
81. Tan NYL, Anavekar NS, Wiley BM. Concomitant myopericarditis and takotsubo syndrome following immune checkpoint inhibitor therapy. *BMJ Case Rep* 2020;13.

82. Tanabe J, Watanabe N, Endo A, Nagami T, Inagaki S, Tanabe K. Asymptomatic immune checkpoint inhibitor-associated myocarditis. *Intern Med* 2021;60:569–73.
83. Todo M, Kaneko G, Shirotake S, et al. Pembrolizumab-induced myasthenia gravis with myositis and presumable myocarditis in a patient with bladder cancer. *IJU Case Rep* 2020;3:17–20.
84. Tsuruda T, Yoshikawa N, Kai M, et al. The cytokine expression in patients with cardiac complication after immune checkpoint inhibitor therapy. *Intern Med* 2021;60:423–9.
85. Veccia A, Kinspergher S, Grego E, et al. Myositis and myasthenia during nivolumab administration for advanced lung cancer: a case report and review of the literature. *Anticancer Drugs* 2020;31:540–4.
86. Wakefield C, Shultz C, Patel B, Malla M. Life-threatening immune checkpoint inhibitor-induced myocarditis and myasthenia gravis overlap syndrome treated with abatacept: a case report. *BMJ Case Rep* 2021;391:933.
87. Wang F, X W. Cardiovascular toxicities associated with immune checkpoint inhibitors: an updated comprehensive disproportionality analysis of the FDA adverse event reporting system. *J Clin Pharm Ther* 2022;47:1576–84.
88. Wang F, Sun X, Qin S, et al. A retrospective study of immune checkpoint inhibitor-associated myocarditis in a single center in China. *Chin Clin Oncol* 2020;9:16.
89. Wang Q, Hu B. Successful therapy for autoimmune myocarditis with pembrolizumab treatment for nasopharyngeal carcinoma. *Ann Transl Med* 2019;7:247.
90. Wilson NR, Lockhart JR, Garcia-Perdomo HA, Oo TH, Rojas-Hernandez CM. Management and outcomes of hematological immune-related adverse events: systematic review and meta-analysis. *J Immunother* 2022;45:13–24.
91. Xie X, Wang F, Qin Y, et al. Case report: fatal multiorgan failure and heterochronous pneumonitis following pembrolizumab treatment in a patient with large-cell neuroendocrine carcinoma of lung. *Front Pharmacol* 2020;11:569466.
92. Xu Y, Hong L, Liu T. Ominous electrocardiographic abnormalities in a patient with hepatocellular carcinoma. *JAMA Intern Med* 2022;182:674–5.
93. Yamaguchi S, Morimoto R, Okumura T, et al. Late-onset fulminant myocarditis with immune checkpoint inhibitor nivolumab. *Can J Cardiol* 2018;34:812.e811–.
94. Yang ZX, Chen X, Tang SQ, Zhang Q. Sintilimab-induced myocarditis overlapping myositis in a patient with metastatic thymoma: a case report. *Front Cardiovasc Med* 2021;8:797009.
95. Yogasundaram H, Alhumaid W, Chen JW, et al. Plasma exchange for immune checkpoint inhibitor-induced myocarditis. *CJC Open* 2021;3:379–82.
96. Zhang B, Gyawali L, Liu Z, Du H, Yin Y. Camrelizumab-related lethal arrhythmias and myasthenic crisis in a patient with metastatic thymoma. *Case Rep Cardiol* 2022;2022:4042909.
97. Zhang C, Qin S, Zuo Z. Immune-related myocarditis in two patients receiving camrelizumab therapy and document analysis. *J Oncol Pharm Pract* 2021:10781552211027339.
98. Zhang L, Jones-O'Connor M, Awadalla M, et al. Cardiotoxicity of Immune Checkpoint Inhibitors. *Curr Treat Options Cardiovasc Med* 2019;21:32.

99. Zhang N, Tse G, Liu T. Neutrophil-lymphocyte ratio in the immune checkpoint inhibitors-related atherosclerosis. *Eur Heart J* 2021;42:2215.
100. Zhao LZ, Liu G, Li QF, Chen G, Jin GW. A case of carrelizumab-associated immune myocarditis. *Asian J Surg* 2022;45:496–7.
101. Zhou J, Chau YA, Yoo JW, et al. Liver Immune-related Adverse Effects of Programmed Cell Death 1 (PD-1) and Programmed Cell Death Ligand 1 (PD-L1) Inhibitors: A Propensity Score Matched Study with Competing Risk Analyses. *Clin Oncol (R Coll Radiol)* 2022;34:e316–7.
102. Zhou J, Lee S, Lakhani I, et al. Adverse Cardiovascular Complications following prescription of programmed cell death 1 (PD-1) and programmed cell death ligand 1 (PD-L1) inhibitors: a propensity-score matched Cohort Study with competing risk analysis. *Cardiooncology* 2022;8:5.
103. Zlotoff DA, Hassan MZO, Zafar A, et al. Electrocardiographic features of immune checkpoint inhibitor associated myocarditis. *J Immunother Cancer* 2021;9.