



Classification and Management of Pontocerebellar-Petrosal Bridging Veins

Juan F. Villalonga^{1,2}, Matías Baldoncini³, José I. Pailer¹, Amparo Saenz¹, Alice Giotta Lucifero⁴, Sabino Luzzi^{4,5}, Derek O. Pipolo¹, Alvaro Campero^{1,2}

■ **OBJECTIVES:** The risks and benefits of coagulating intradural venous elements during a retrosigmoid approach for trigeminal neurovascular decompression has not been accurately established. The objectives of this study were to identify the veins that drain into the superior petrosal sinus, classify them in relation to the suprameatal tubercle, and determine the implication of their coagulation.

■ **METHODS:** A retrospective study of 3-dimensional surgical videos of retrosigmoid approaches for trigeminal neurovascular decompression from the Laboratory of Neurosurgical Innovations of Tucumán (LINT) digital archive was carried out. The veins encountered were classified into 3 groups: retromeat, meatal and premeatal. The neurosurgical postoperative complication scale proposed by Landriel et al. was utilized to assess complications from venous coagulation. A grade 0 was added for patients without complications. The STATA 14 program was utilized for statistical analysis.

■ **RESULTS:** The pontocerebellar-petrosal veins of 28 patients who underwent trigeminal decompressive surgery were analyzed. In 7 cases these were found in the retromeat region; 100% were sacrificed. Eleven cases revealed veins within the meatal region; 90.91% were coagulated. Veins in the premeatal region were found in 14 cases; 57.14% were sacrificed. In the postoperative follow-up, 27 patients were grade 0 and 1 patient developed postoperative meningitis (grade Ib complication). No patient suffered vascular complications.

■ **CONCLUSIONS:** The venous elements identified in trigeminal neurovascular decompressive surgery are variable. We propose classifying them into retromeat, meatal, and premeatal groups. Retromeat and meatal veins can be safely sacrificed for appropriate visualization of the neurovascular conflict. The premeatal venous elements should be coagulated only in justified cases.

INTRODUCTION

Trigeminal neurovascular decompressive surgery is a valid therapeutic alternative for the treatment of trigeminal neuralgia refractory to medical treatment.¹⁻³

The retrosigmoid approach is the gold standard for accessing the area of trigeminal neurovascular involvement.⁴⁻⁶ Using this microsurgical corridor, several pontine, mesencephalic, middle cerebellar peduncle, or cerebellar veins draining into the superior petrosal sinus are encountered.⁷⁻¹⁰ At this point, the neurosurgeon is faced with the need to access the region where neurovascular decompression is required, while at the same time preserving as much as possible the veins that are in its path.

After analyzing the literature, there are no specific studies that establish concrete risks and benefits of coagulating the venous elements during this procedure.

The objectives of this study were to identify the veins that drain into the superior petrosal sinus, classify them in relation to the suprameatal tubercle, and determine the implication of their coagulation.

Key words

- Bridging veins
- Microsurgery
- Retrosigmoid approach
- Trigeminal neuralgia

Abbreviations and Acronyms

LINT: Laboratory of Neurosurgical Innovations of Tucumán

From the ¹Laboratory of Neurosurgical Innovations of Tucumán, Facultad de Medicina, Universidad Nacional de Tucumán, Tucumán, Argentina; ²Department of Neurological Surgery, Hospital Padilla, Tucumán, Argentina; ³Laboratory of Microsurgical Neuroanatomy,

Second Chair of Gross Anatomy, School of Medicine, University of Buenos Aires, Argentina; ⁴Neurosurgery Unit, Department of Clinical-Surgical, Diagnostic and Pediatric Sciences, University of Pavia, Italy; and ⁵Neurosurgery Unit, Department of Surgical Sciences, Fondazione IRCCS Policlinico San Matteo, Pavia, Italy

To whom correspondence should be addressed: Matías Baldoncini, M.D.
[E-mail: drbaldoncini@matias@gmail.com]

Citation: *World Neurosurg.* (2022) 160:e481-e486.
<https://doi.org/10.1016/j.wneu.2022.01.054>

Journal homepage: www.journals.elsevier.com/world-neurosurgery

Available online: www.sciencedirect.com

1878-8750/\$ - see front matter © 2022 Elsevier Inc. All rights reserved.

METHODS

Identification and Classification of the Venous Elements Within the Approach

To identify the venous elements during surgery, a retrospective study of 3-dimensional surgical videos from the Laboratory of Neurosurgical Innovations of Tucumán (LINT) digital archive was carried out. The corresponding surgeries ($n = 28$) were performed between January 2017 and June 2020 in Tucumán, Argentina. They were recorded and processed as explained in a previous publication by our team.¹¹

In order to classify the veins in this microsurgical corridor, they were divided into 3 groups: retromeat, meatal, and premeatal (Figure 1).

Implications of Coagulation of the Venous Elements

To assess whether venous coagulation generated any type of complication and categorize its severity, the neurosurgical post-operative complication scale proposed by Landriel et al. was utilized.¹² A modification to this scale was made, adding a grade 0 for patients who did not suffer any type of complication (Table 1).

Every patient was evaluated according to a strict clinical and radiologic protocol. A detailed neurologic examination and clinical follow-up was carried out during the days of hospitalization and in outpatient controls. For neuroimaging follow-up, a head computed tomography was performed in the immediate post-operative period to assess the existence of venous infarction or posterior fossa edema and a brain magnetic resonance imaging including diffusion-weighted imaging and fluid-attenuated inversion recovery sequences was performed at 3 months post-operatively to rule out ischemic sequelae.

Statistical Analysis

To describe the proportions of veins, absolute and relative frequency were used. For statistical analysis, the STATA 14 program (StataCorp, College Station, TX) was utilized.

RESULTS

Identification and Classification of the Venous Elements Within the Approach

The pontocerebellar-petrosal veins of 28 patients who underwent trigeminal decompressive surgery were analyzed. After evaluating the pattern of these veins, they were divided into 3 groups according to their relationship with the internal auditory meatus: retromeat, meatal, and premeatal.

In 7 cases at least 1 vein was found in the retromeat region (in 4 cases a single vein was found and in 3 cases 2 veins were found) (Figure 2). Of these, 100% of the veins encountered were sacrificed. Within the meatal region (Figure 3), we found that in 7 cases 1 vein was detected, while in 4 cases 2 veins were observed. Of these, 90.91% (10 of 11) were coagulated. Only 1 of the 11 veins found in this region was left intact.

Furthermore, in the premeatal region (Figure 4), 3 cases were found with 1 vein and 11 cases with 2 veins. A total of 57.14% (8 of 14) of the veins found in this region were coagulated. The premeatal region was the area where more veins were found and most preserved.

In our series, 27 of 28 patients were grade 0 (without complications). One patient developed postoperative meningitis requiring medical treatment (grade 1b). It should be noted that this is not a complication in direct relation to venous coagulation. No patient presented radiologic signs of ischemic stroke during follow-up.

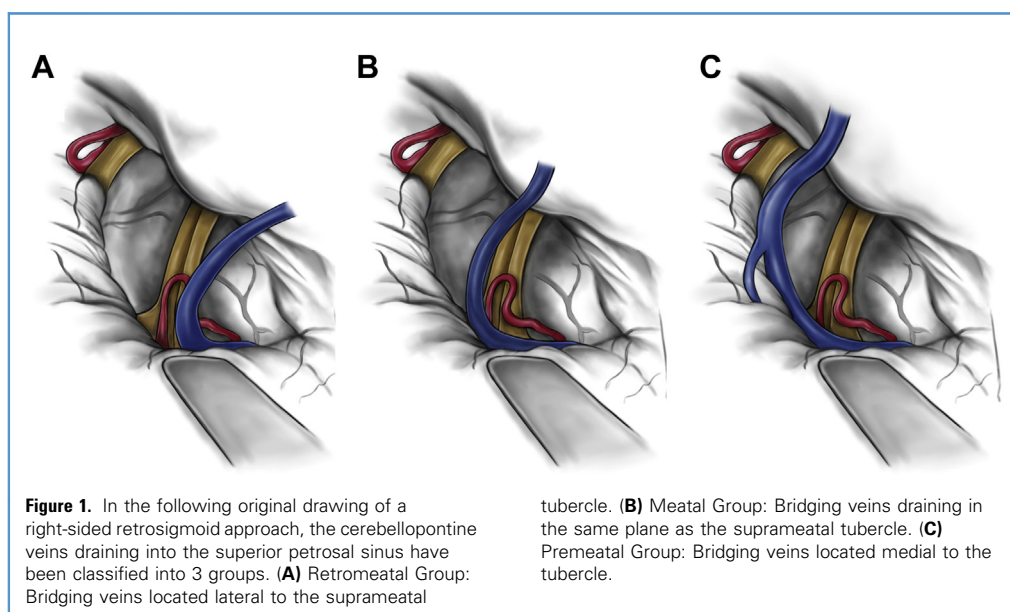


Table 1. Modified Scale of Landriel et al. for Neurosurgical Complications

Grade 0. No complications.
Grade I. Any non—life-threatening deviation from normal postoperative course, not requiring invasive treatment. Grade Ia: Complication requiring no drug treatment. Grade Ib: Complication requiring drug treatment.
Grade II. Complication requiring invasive treatment such as surgical, endoscopic, or endovascular interventions. Grade IIa: Complication requiring intervention without general anesthesia. Grade IIb: Complication requiring intervention with general anesthesia.
Grade III. Life-threatening complications requiring management in intensive care unit. Grade IIIa: Complication involving single organ failure. Grade IIIb: Complication involving multiple organ failure.
Grade IV. Complication resulting in death. Surgical complications: Adverse events that are directly related to surgery or surgical technique. Medical complications: Adverse events that are not directly related to surgery or surgical technique.

DISCUSSION

Petrous veins are divided into superior and inferior petrosal veins based on whether they drain into the superior or inferior petrosal sinus.^{9,13,14}

The superior petrosal veins are among the largest and most frequent veins in the posterior fossa. They can be formed by the terminal segment of a single vein or by a common trunk formed by the union of several veins. The most common tributaries are the transverse pontine and pontotrigeminal veins, the common trunk of the lateral group of the superior hemispheric veins, and the veins of the cerebellar fissure and middle cerebellar peduncle.^{9,15-19}

The superior petrosal veins are subdivided into lateral, intermediate, and medial groups based on the relationship between their site of entry to the superior petrosal sinus and the internal acoustic meatus. The intermediate group drains into the sinus above the internal acoustic meatus, the medial group drains into the sinus medial to the meatus, and the lateral group drains lateral to the meatus.

The medial group is the most frequent, followed by the lateral. They generally have a common trunk formed by the union of 2 or 3 of the following veins: transverse pontine veins, pontotrigeminal veins, and the veins of the cerebellar fissure and the middle cerebellar peduncle. The latter can also enter the sinus directly without joining another vein. The most common veins of the lateral group form a common trunk arising from the union of the superior and inferior hemispheric veins and the vein of the

cerebellopontine fissure. Intermediate superior petrosal veins can present as a single vein, the cerebellopontine fissure vein.

It is enough to review the most relevant aspects of the surgical technique in this surgery to understand why we decided to focus on the study of the venous components. Two critical points deserve to be highlighted in trigeminal nerve decompressive surgery:

- Cerebellar retraction with a spatula at its superolateral margin (between the tentorial and petrosal sides). For this, it may be necessary to coagulate and cut bridging veins. This maneuver allows access to the entrance area of the V cranial nerve and avoidance of VIII cranial nerve traction, reducing the possibility of postoperative hearing loss.
- Consideration of whether it is necessary to sacrifice tributary branches of the petrosal vein. In some cases, this can allow adequate access to the entrance area of the V cranial nerve.

Contemporary anatomic textbooks emphasize the veins of the superior neurovascular complex as significant tributaries to the superior petrosal sinus. However, a series of bridging veins between the cerebellar surface and petrous bone are not described in detail. In our study, the presence of these were observed in 28 of 28 patients. Coagulation of these did not have significant clinical implications. However, we consider that it is important to mention their existence for practical surgical management.

Based on the intraoperative findings evidenced in the present work, we have classified these veins from a surgical point of view into 3 large venous elements: retromeat, meatal, and premeatal (Figure 1). This is a simple classification to be used in the operating room daily, allowing systematization of coagulation or preservation of the venous elements encountered during the intradural time of the retrosigmoid corridor.

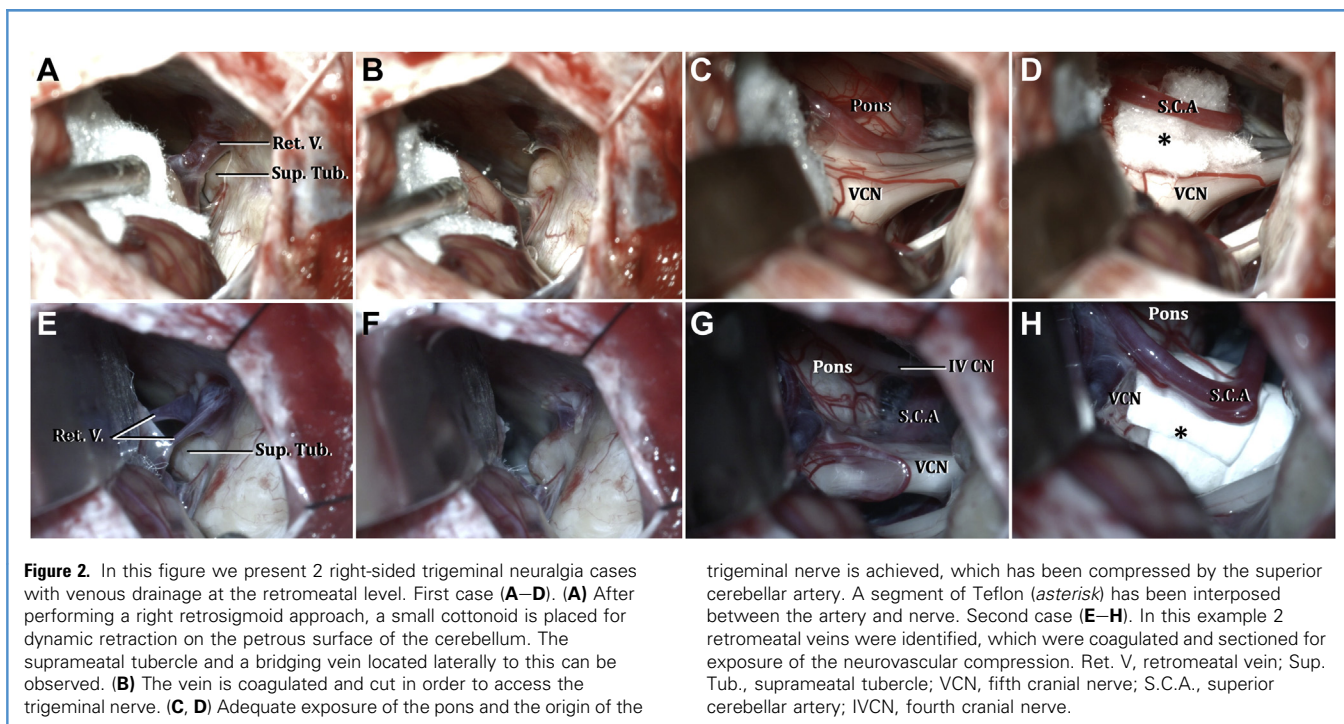
All of the retromeat veins and more than 90% of the meatal veins in our study were coagulated; in the postoperative follow-up, no patient suffered complications of a vascular nature.

This classification may also be useful for neurosurgeons performing neurovascular decompressions endoscopically. Although there is less retraction when working with an endoscope, we must be careful for preservation of the premeatal veins. In cases where the suprimeatal tubercle obstructs the vision medially, 30-degree endoscopes are useful for observation of the trigeminal nerve, areas of neurovascular compression and premeatal veins without the need to drill the tubercle.

The present series was studied retrospectively, acknowledging the imperfections of this methodology. Further series with larger numbers of patients are required to obtain conclusions that can be validated for application in daily practice.

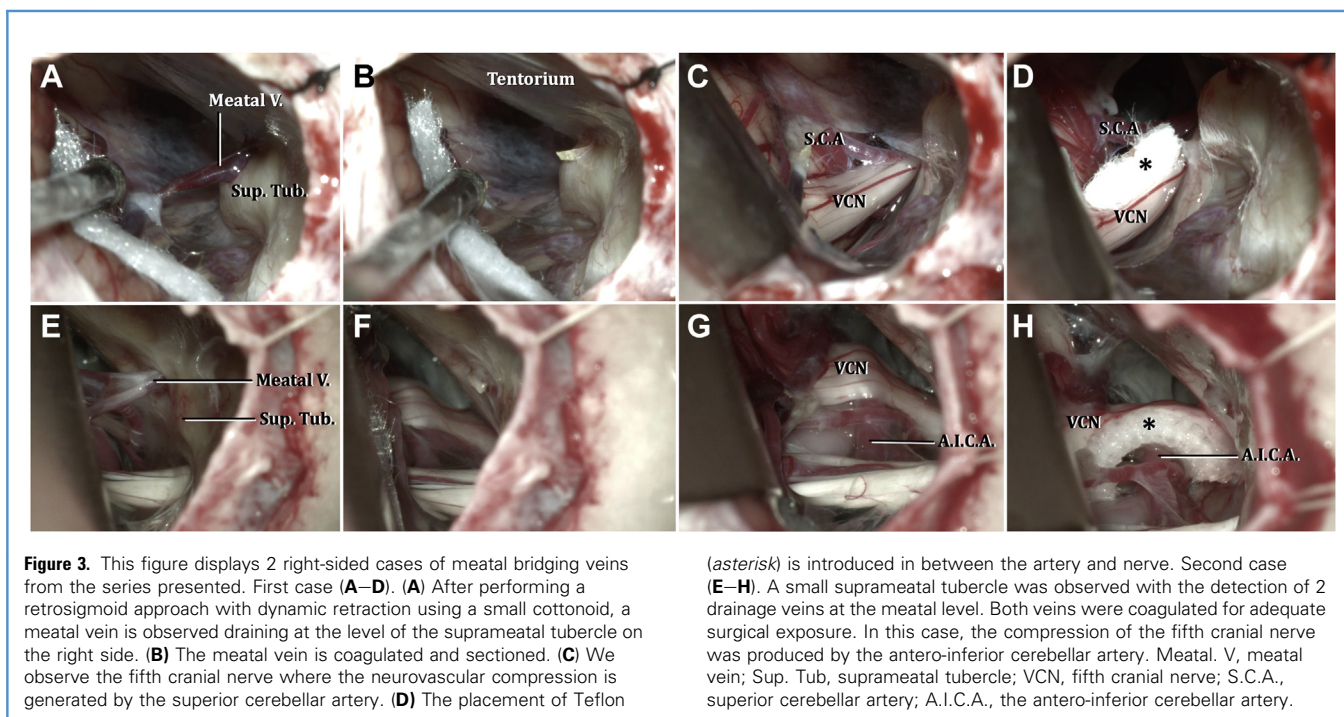
CONCLUSIONS

The venous elements identified in trigeminal neurovascular decompressive surgery are variable. One possibility is to classify



them into 3 groups: retromeatal, meatal, and premeatal. Retromeatal and meatal veins can be safely sacrificed in order to achieve appropriate visualization of the neurovascular conflict at its

entrance to the brainstem. The premeatal venous elements should be coagulated only in justified cases because they are draining from midbrain structures in the midline.



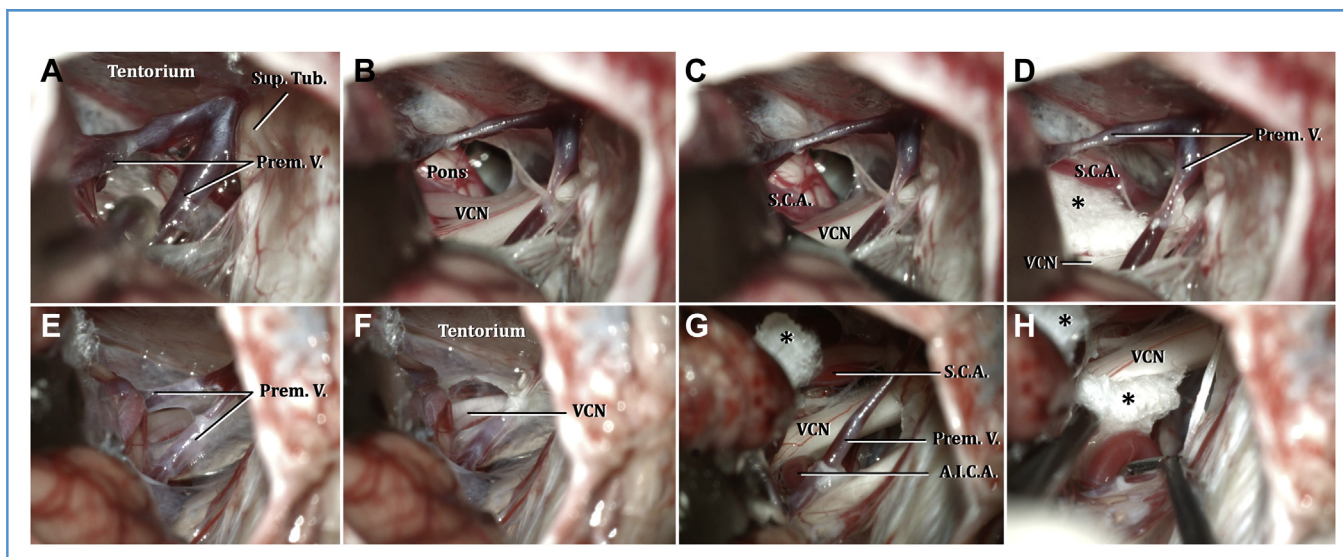


Figure 4. In this figure we present two cases of premeatal bridging veins found in right-sided trigeminal neuralgia. First case (A–D). (A, B) After performing a retrosigmoid approach with dynamic retraction using a small cottonoid, two draining veins were observed at the premeatal level. The preservation of both veins was determined due to midline localization and the probable drainage of brainstem structures. The surgical corridor was created between the angle formed by both premeatal veins. (C, D) In this case, the superior cerebellar artery was found to be the source of the trigeminal compression. A segment of Teflon (asterisk) was placed

between the artery and nerve. Second case (E–H). (E, F) In this case, 2 premeatal veins were identified, where only coagulation of the superior vein was necessary. The inferior premeatal vein was preserved throughout the surgical procedure. (G, H) The trigeminal nerve underwent a double neurovascular compression by the superior cerebellar artery upwards and the anterior-inferior cerebellar artery below. Two segments of Teflon (asterisk) were placed between the nerve and arteries. Prem. V, premeatal vein; Sup. Tub, suprameatal tubercle; VCN, fifth cranial nerve; S.C.A., superior cerebellar artery; A.I.C.A., the antero-inferior cerebellar artery.

CRedit AUTHORSHIP CONTRIBUTION STATEMENT

We confirm that the manuscript has been read and approved by all named authors and that there are no other persons who satisfied

the criteria for authorship but are not listed. We further confirm that the order of authors listed in the manuscript has been approved by all of us.

REFERENCES

- Lovely TJ, Jannetta PJ. Microvascular decompression for trigeminal neuralgia. Surgical technique and long-term results. *Neurosurg Clin N Am.* 1997;8: 11-29.
- Jannetta PJ, McLaughlin MR, Casey KF. Technique of microvascular decompression: technical note. *FOC.* 2005;18:1-5.
- Campero A, Campero A, Ajler P. Descompresión microvascular en neuralgia del trigémino: reporte de 36 casos y revisión de la literatura. *Surg Neurol Int.* 2014;5:441.
- Dumot C, Sindou M. Trigeminal neuralgia due to neurovascular conflicts from venous origin: an anatomical-surgical study (consecutive series of 124 operated cases). *Acta Neurochir.* 2015;157: 455-466.
- Dumot C, Brinzeu A, Berthiller J, Sindou M. Trigeminal neuralgia due to venous neurovascular conflicts: outcome after microvascular decompression in a series of 55 consecutive patients. *Acta Neurochir.* 2017;159:237-249.
- Dumot C, Sindou M. Veins of the cerebellopontine angle and specific complications of sacrifice, with special emphasis on microvascular decompression surgery. A review. *World Neurosurg.* 2018;117:422-432.
- Matsushima T, Fukui M, Suzuki S, Rhoton AL Jr. The microsurgical anatomy of the infratentorial lateral supracerebellar approach to the trigeminal nerve for tic douloureux. *Neurosurgery.* 1989;24: 890-895.
- Matsushima T, Huynh-Le P, Miyazono M. Trigeminal neuralgia caused by venous compression. *Neurosurgery.* 2004;55:334-339.
- Rhoton AL Jr. The posterior fossa veins. *Neurosurgery.* 2000;47(3 suppl):S69-S92.
- Tatagiba MS, Roser F, Hirt B, Ebner FH. The retrosigmoid endoscopic approach for cerebellopontine-angle tumors and microvascular decompression. *World Neurosurg.* 2014;82(6 suppl): S171-S176.
- Campero A, Baldoncini M, Villalonga JF, Abarca-Olivas J. Three-dimensional microscopic surgical videos: a novel and low-cost system. *World Neurosurg.* 2019;132:188-196.
- Landriel Ibanez FA, Hem S, Ajler P, et al. A new classification of complications in neurosurgery. *World Neurosurg.* 2011;75:709-715 [discussion: 604-711].
- Choudhari KA. Superior petrosal vein in trigeminal neuralgia. *Br J Neurosurg.* 2007;21:288-292.
- Toda H, Iwasaki K, Yoshimoto N, et al. Bridging veins and veins of the brainstem in microvascular decompression surgery for trigeminal neuralgia and hemifacial spasm. *Neurosurg Focus.* 2018;45:E2.
- Narayan V, Savardekar AR, Patra DP, et al. Safety profile of superior petrosal vein (the vein of Dandy) sacrifice in neurosurgical procedures: a systematic review. *Neurosurg Focus.* 2018;45:E3.
- Zhong J, Li S-T, Xu S-Q, Wan L, Wang X. Management of petrosal veins during microvascular decompression for trigeminal neuralgia. *Neurol Res.* 2008;30:697-700.
- Zhong J, Zhu J, Sun H, et al. Microvascular decompression surgery: surgical principles and

technical nuances based on 4000 cases. *Neurol Res.* 2014;36:882-893.

18. Pathmanaban ON, O'Brien F, Al-Tamimi YZ, Hammerbeck-Ward CL, Rutherford SA, King AT. Safety of superior petrosal vein sacrifice during microvascular decompression of the trigeminal nerve. *World Neurosurg.* 2017;103:84-87.
19. Toda H, Goto M, Iwasaki K. Patterns and variations in microvascular decompression for

trigeminal neuralgia. *Neurol Med Chir (Tokyo).* 2015; 55:432-441.

Conflict of interest statement: The authors declare that the article content was composed in the absence of any commercial or financial relationships that could be construed as a potential conflict of interest.

Received 22 November 2021; accepted 12 January 2022

Citation: *World Neurosurg.* (2022) 160:e481-e486.
<https://doi.org/10.1016/j.wneu.2022.01.054>

Journal homepage: www.journals.elsevier.com/world-neurosurgery

Available online: www.sciencedirect.com

1878-8750/\$ - see front matter © 2022 Elsevier Inc. All rights reserved.