



Postoperative vacuum therapy following AMS™ LGX 700® inflatable penile prosthesis placement: penile dimension outcomes and overall satisfaction

Gabriele Antonini¹ · Ettore De Berardinis¹ · Gian Maria Busetto¹ · Francesco Del Giudice¹ ¹ · Benjamin I. Chung² · Simon L. Conti² · Matteo Ferro³ · Gennaro Musi³ · Ramiro Fragas⁴ · Ottavio De Cobelli³ · Isabella Sperduti⁵ · Martin S. Gross⁶ · Paul E. Perito⁷

Received: 5 December 2018 / Revised: 16 January 2019 / Accepted: 22 January 2019
© Springer Nature Limited 2019

Abstract

Penile shortening after inflatable penile prosthesis for erectile dysfunction is a common postoperative patient complaint and can reduce overall satisfaction with the procedure. In this prospective study we report our results regarding penile dimensions and patient satisfaction outcomes after 1 year of follow-up from AMS™ LGX700® penile prosthesis implant with 6 months of vacuum erectile device therapy. Seventy-four selected patients with medically refractory erectile dysfunction underwent AMS™ LGX 700® IPP placement. Postoperatively, patients were assigned vacuum device therapy for 5 min twice daily. Follow-up continued for 1 year after surgery. Dimensional and functional results were assessed. Baseline median preoperative stretched penile length and girth were 14 cm (range 10–17) and 9 cm (range 7–12), respectively. At the end of the study penile median dimensional outcomes were 17 cm (range 13–23) for length and 11 cm (range 10–13) for girth while a median number of 24 pumps (range 18–29) to fully inflate the device was seen. Baseline median International Index of Erectile Function (IIEF-5) score was 9 (range 5–11), at 6 months 20 (range 18–26) and at 1 year was 25 (range 20–27) ($p < 0.0001$). Median Erectile Dysfunction Inventory of Treatment Satisfaction (EDITS) score at the end of the follow-up was 74 (range 66–78). Our postoperative rehabilitation program is feasible and should be recommended after prosthesis surgery in order to increase overall satisfaction with the procedure. Penile postoperative dimensional outcomes were statistically significant improved and complications were negligible.

These authors contributed equally: Gabriele Antonini, Ettore De Berardinis

These authors contributed equally: Martin S. Gross, Paul E. Perito

✉ Gabriele Antonini
gabrieleantoninimd@gmail.com

¹ Department of Urology, Sapienza Rome University, Policlinico Umberto I, Viale del Policlinico 155, Rome 00161, Italy

² Department of Urology, Stanford University Medical Center, 300 Pasteur Dr, Palo Alto, CA 94304, USA

³ Division of Urology, European Institute of Oncology, Via Giuseppe Ripamonti, 435, 20141 Milan, Italy

Introduction

Erectile dysfunction (ED) is the persistent inability to maintain an erection sufficient to permit satisfactory sexual performance [1]. ED has many causes, and when the condition is refractory to medical management inflatable penile prosthesis (IPP) insertion is an excellent therapeutic solution [2]. Many of the multifactorial causes of ED, as well as

⁴ Clinica Central Ciria Garcia, Ave. Lazaro e/ 18y 20, Pya, La, Cárdenas, La Habana, Cuba

⁵ Biostatistical Unit, Regina Elena National Cancer Institute, Via Elio Chianesi, 53, 00144 Roma, Italy

⁶ Section of Urology, Dartmouth-Hitchcock Medical Center, 1 Medical Center Dr, Lebanon, NH 03766, USA

⁷ Department of Urology, Coral Gables Hospital, 3100 Douglas Rd, Coral Gables, FL 33134, USA

coexisting conditions like Peyronie's disease (PD), result in penile fibrosis and shortening [3].

IPP placement has high rates of patient satisfaction, but penile length loss is often a common postoperative patient complaint and can reduce overall satisfaction with the procedure [4, 5]. There is no consensus in the literature on postoperative prevention and/or rehabilitation for penile shortening after IPP placement. Several strategies to maintain penile length have been described. These techniques vary from pre-insertion traction therapies to intraoperative corporoplasty augmentation, but high-level evidence and guidelines are lacking [6, 7].

In 2006, the AMS™ (Boston Scientific, Marlborough, MA, USA) LGX 700® IPP was introduced. This prosthesis was designed to minimize penile length loss via cylinder expansion in both length and girth. In theory this would provide erections comparable to normal penises while preserving original penile dimensions [8]. Data concerning length improvement and/or overall patient satisfaction with this device remain controversial and are based on small non-randomized studies.

Penile traction therapies and vacuum erections devices (VEDs) have been shown to successfully restore penile length in patients with short penises secondary to many conditions. These include hypoplastic penis, postoperative shortened penis, dysmorphophobia, and Peyronie's disease (PD) [9–12]. Despite the favorable results seen in patients with these conditions, to our knowledge there are no studies regarding VED use for postoperative corporal body lengthening after IPP implantation.

In this prospective study our patients underwent AMS™ LGX 700® IPP placement and additionally used a VED as an adjuvant therapy in the early postoperative period to stretch the tunica albuginea. The goal of this additional treatment was to prevent the pseudo-capsule “coffin effect” and to maximize length and girth outcomes. We report our results regarding penile dimensions and patient satisfaction outcomes after 1 year of follow-up from IPP surgery with 6 months of VED therapy.

Materials and methods

Between September 2014 and January 2017, 106 patients with medically refractory ED who desired a definitive solution for their condition were enrolled in this prospective two institution non-randomized study. The study was conducted under an institutional review board protocol from the Andrology Clinic in the Department of Gynecological-Obstetric Sciences and Urological Sciences, Sapienza Rome University, Italy, and at the Urology Division of Coral Gables Hospital, FL, USA. The study was conducted in line with European Urology and Good Clinical Practice

guidelines, with ethical principles laid down in the latest version of the Declaration of Helsinki. Informed consent was obtained from every patient in order to participate in the study.

Exclusion criteria included: previous pelvic surgery and/or oncologic pelvic treatment, previous penile surgery (including previous IPP and/or penile lengthening surgery), penile curvature or deformity defined as a single or multiple palpable plaques confirmed via penile ultrasonography studies. In accordance with these criteria 32 patients were excluded and 74 patients were selected for further study. All of them underwent AMS™ (Boston Scientific, Marlborough, MA, USA) LGX 700® infrapubic IPP placement. All the procedures were performed by two experienced implant surgeons with identical surgical technique previously described [13]. Patients were given cefuroxime BID for 2 days preoperatively and then were given vancomycin and gentamicin dosed at ideal body weight in the immediate preoperative period. No postoperative antibiotics were used.

The length of the implanted cylinders was accurately selected according to the intraoperative measurements with the aim to ensure correct sizing. In all the cases, a 100 ml AMS Conceal™ reservoir was placed in the abdominal wall space.

Penile length and girth were defined as the distance from the pubic bone to the urethral meatus along the dorsum of the shaft of the penis and as the circumference along the base of the penis respectively. Penile measurements were registered at three different times: 1 week prior to surgery measuring stretched flaccid penile length and girth at baseline (I) and following intracorporeal injection of 10–20 mcg of alprostadil (II), and then during the scheduled postoperative visits at maximum inflation (III). All the patients were measured in the supine position and each measurement was carried out by the two same expert surgeons. In an effort to assess corporal tissue expansion we compared the number of pumps required to maximally inflate the device at 2 weeks after discharge and at each postoperative scheduled evaluation.

After discharge patients were taught how to activate and deactivate the device at a median of 8 (range 5–12) days following surgery. They were encouraged to cycle it twice daily 10–15 min per day. Starting 3 weeks after discharge, patients were asked to use a vacuum device for a 12-week period (Medis®, Vacuum Therapy Devices, Milan, Italy and Osbon ErecAid®, Vacuum Therapy System, Collierville, TN, USA) without the constriction ring for 5 min twice daily after full device inflation was achieved.

Patients were asked to complete the International Index of Erectile Function (IIEF-5) questionnaire before surgery and at the end of the follow-up. Questions 1–5 regarding erectile function and question 15 on personal confidence were used in order to pre- and postoperatively determine the

grade of ED [14, 15]. Patients' quality of life after IPP implantation was defined using the Erectile Dysfunction Inventory of Treatment Satisfaction (EDITS) scale which evaluates satisfaction of ED treatment modalities on a 0–100 scale [16].

Follow-up with a standard postoperative evaluation at 12, 24, and 48 weeks was performed.

Descriptive statistics were used to describe the patients' characteristics. Normality distribution of data was assessed by Wilk-Shapiro tests and where necessary by QQ-plots. The comparison of measures obtained at different time points in the same patients was performed by Wilcoxon and Friedman non-parametric tests. Bonferroni correction for multiple comparisons was applied, when appropriate. The level of significance was set at $p \leq 0.05$. SPSS software was used for all statistical evaluations (SPSS version 21.0, SPSS Inc., Chicago, Illinois, USA).

Results

Seventy-four patients with a median age of 56 (range 43–66) years completed the study. Table 1 and Table 2 summarize patients' characteristics and ED etiology,

Table 1 Patients characteristics ($n = 74$)

Variables	
Age (years), median (range)	56 (43–66)
BMI (kg/m^2), median (range)	29 (21–34)
Hypertension, n (%)	41 (55.4)
IGT, n (%)	36 (48.6)
Diabetes, n (%)	5 (6.7)
Smoking status, n (%)	
Never	32 (43.2)
Active smoker	24 (32.4)
Ex-smoker	18 (24.3)
Marital status, n (%)	
Married	63 (85.1)
Single	11 (14.8)
Duration of ED before implant, months, median (range)	38 (25–49)
Previous ED treatment, n (%)	
None	0
PDE5i	28 (37.8)
ICI	29 (39.1)
PDE5i + ICI	8 (10.8)
MUSE	9 (12.1)

Values are expressed as median (range)

PD Peyronie disease, ED erectile dysfunction, BMI body mass index, IGT impaired glucose tolerance, PDE5i phosphodiesterase type 5 inhibitor, ICI intracavernosal alprostadil injection, MUSE intraurethral alprostadil administration, n number

Table 2 Erectile dysfunction etiology

ED etiology	n (%)
Venous leakage	29 (39.1)
Adverse reaction/intolerance to PDE5i and/or ICI	19 (25.6)
Peripheral vasculopathy	
Metabolic syndrome	10 (13.5)
Diabetes	5 (6.7)
Coronary heart disease	8 (10.8)
Vasculitis systemic	3 (4)

ED erectile dysfunction, n number, PDE5i phosphodiesterase type 5 inhibitor, ICI intracavernosal alprostadil injection

respectively. A median of 52 (range 49–56) weeks of follow-up was achieved for the patient cohort. All surgical procedures were carried out within a median operative time of 37 min (range 28–46) and no intraoperative complications were reported. All the patients were discharged the day after the surgery with the prosthesis inflated to ~70%.

Median implant length (including rear tips extenders) was 19 cm (range 16–21). Figure 1 summarizes penile dimensional outcomes at baseline and at scheduled postoperative evaluations while Fig. 2 shows the statistically significant improvement in the median pumps needed to fully inflate the device over the follow-up ($p < 0.0001$).

Comparing penile sizes at any time during follow-up, penile length outcomes were always statistically significantly increased ($p < 0.0001$). Data regarding girth showed variation postoperatively when compared with the baseline, but at the end of follow-up, the dimensions remained not-statistically different from those obtained via the preoperative ICI [median 11 cm (range 9–12) vs. 11 cm (range 10–13); $p = 0.36$] (see Fig. 1b). No patient reported a shortening in the length compared to the baseline flaccid stretched measurements [median 14 cm (range 10–17) vs. 17 cm (range 13–23); $p < 0.0001$] while, more importantly, no statistical difference was seen between the baseline ICI-induced penile length and the measurements at the end of follow-up [median 17 cm (range 11–19) vs. 17 cm (range 13–23); $p = 0.48$] (see Fig. 1a).

Table 3 summarizes intraoperative and postoperative complications. Two (2.7%) infections were seen, with one device explanted 1.4 months after the surgery. The other patient underwent 4 days of intravenous vancomycin and a gram-negative antibiotic, followed by 1 month of oral trimethoprim-sulfamethoxazole and rifampin and the infection was resolved. One (1.3%) patient developed distal crossover of the prosthesis cylinders and underwent surgical repair via the “distal corporal anchoring stitch” technique previously described [17]. At 45 weeks of follow-up, 1 (1.3%) device malfunctioned requiring device removal and replacement.

Preoperative, mid- and long-term IIEF-5 scores were compiled. Baseline median IIEF-5 score was 9 (range

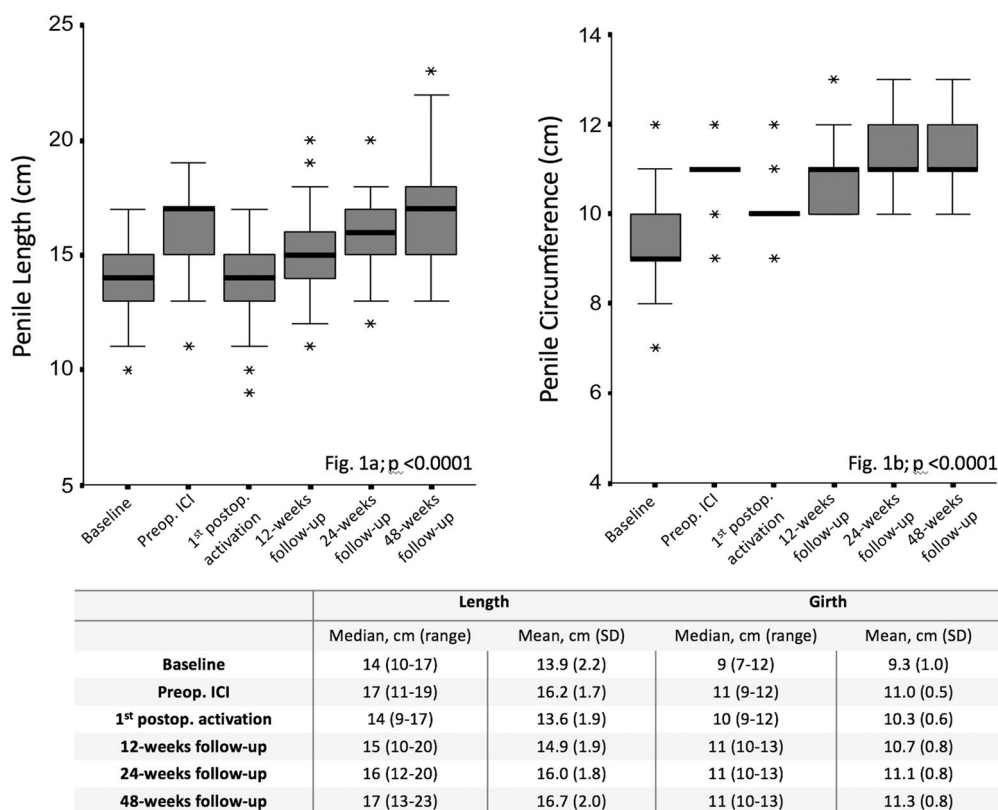


Fig. 1 Comparison between penile length (a) and girth (b) over the follow-up. Penile outcomes improvements were always statistically significant over time ($p < 0.0001$)

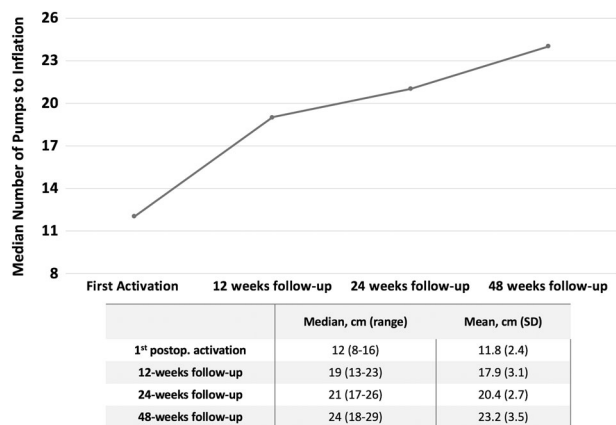


Fig. 2 Trend of the median pumps needed to fully activate the device over the follow-up ($p < 0.0001$)

5–11), at 6 months 20 (range 18–26) and at 1 year was 25 (range 20–27) ($p < 0.0001$). Median EDITS score at the end of the follow-up was 74 (range 66–78).

Discussion

Regardless of the indication, IPP placement is a viable solution for ED with high satisfaction rates (92–100% in

Table 3 Intra- and postoperative complications

Variables	<i>n</i> (%)
Intraoperative complications	0 (0)
Early complications (within 3 months), <i>n</i> (%)	
Infection requiring equipment explant	1 (1.3)
Infectious manifestation treated with antibiotics	1 (1.3)
Prosthesis extrusion	1 (1.3)
Scrotal hematoma, total, <i>n</i> (%)	9 (12.1)
Mild scrotal swelling	8 (88.8)
Scrotal hematoma (conservative treatment)	1 (11.1)
Long-term complications (follow-up 12 months)	
Mechanical failure	1 (1.3)
Shortening of the penis	0
Palpable subcutaneous indurations	1 (1.3)
Neurological impairment (gland iposesibility)	1 (1.3)
Worsened erectile dysfunction	0

ED erectile dysfunction, *n* number, PDE5i phosphodiesterase type 5 inhibitor, ICI intracavernosal alprostadil injection

patients and 91–95% in partners) [2, 18–20]. Despite these results, one of the most common and prevalent complaints following surgery is penile length loss. Some evidence shows that “short penis syndrome” may represent patient

misperceptions after surgery, but several studies have demonstrated that length and girth were objectively reduced when compared to preoperative measurements [5, 21, 22].

In their prospective evaluation, Wang et al. reported a significant decreased penile length (from 0.2 to 3.0 cm) after IPP implantation when compared with the erection achieved preoperatively by ICI. Although only eleven patients were included in this prospective cohort, the 45.5% of the cases (five patients) reported a subjective complaint of penile size loss and none believed that their erect penile length was longer after surgery [23]. Osterberg et al. also found that 86% of men subjectively perceived a change in penile length following IPP implantation. Of their patients, 57% had an objective decrease in their postoperative penile length ≥ 1 cm when compared with their pharmacological induced preoperative penile length [24].

Deveci et al. conducted a prospective analysis that showed that, of 56 patients enrolled, 72% of the cases experienced a subjective reduction in penile dimensions. No difference was seen in mean change of erectile function measured by IIEF score between the groups (72% decreased length, 19% no change, 9% minimal increase), but a significant difference existed for mean change in the satisfaction domain score and for the overall EDITS score for those with shorter penile length [5]. None of the aforementioned studies reported a postoperative measurement preservation strategy.

In 2006, the AMS 700 LGX replaced the Ultrex IPP device (American Medical Service [AMS], Minneapolis, MN, USA), which was introduced to provide length and girth expansion to reduce postoperative length loss complaints and restore an erection comparable with the natural one in terms of both length and girth. Controversy exists surrounding the use of longer LGX devices in longer penises [25]. Longer LGX devices, such as the 21 cm device, can be prone to instability, aneurysm, or s-shaped deformity. We did not use 21 cm LGX device in these patients and our preference is to use 18 cm LGX with rear tip extenders to prevent these device complications, which were not seen in our series.

Negro et al. recently published the results of a prospective experience in a small cohort of 36 patients with one-year follow-up who underwent AMS 700 LGX placement. The authors described an average increase of 10% (1.2 ± 0.4 cm) at 12 months versus baseline length measures without the adoption of any adjunctive postoperative strategy for penile size preservation/augmentation. No patients experienced penile length loss and an overall increased satisfaction was detected in both IIEF and EDITS domains. No data regarding penile circumference measures were reported [26].

The concept of “postoperative rehabilitation” after IPP placement was first developed by Henry et al. in their

prospective series of patients undergoing Coloplast Titan™ (Coloplast, Minneapolis, MN, USA) IPP placement. In this innovative study, the authors incorporated an aggressive method of cylinder sizing during implantation designed to maximize length of the Bioflex® cylinders and introduced a daily, prolonged cycling program for 1 year postoperatively. All of the objective measurements were statistically significantly increased at 12 months follow-up and the 63.3% of the patients reported an improved subjective satisfaction with penile dimensions from prior to implantation [27].

The primary end-point of our prospective study was to analyze changes in length and girth outcomes following a postoperative VED protocol after AMS 700 LGX implantation to maximize the optimal expansive potential of this device. We also believe that, regardless of the device, a postoperative penile rehabilitation protocol with VED is necessary to allow the cylinders to properly expand in the peripheral residual cavernosal tissue, as this stretches the tunica albuginea and prevents the pseudo-capsule coffin effect. With this in mind, our study population specifically did not include patients with any risk factors for corporal fibrosis (i.e., PD, previous radical prostatectomy, etc.) because of the increased likelihood of developing fibrosis and scar tissue formation after surgery, which could compromise cylinder expansion.

In a large series of patients who underwent different types of IPP placement, Sellers et al. showed that a scheduled preoperative VED protocol was able to obtain several important goals like increased ease of corpus cavernosal dilatation, accommodation of a larger cylinders intraoperatively, and improved patient satisfaction with postoperative length [28]. In addition to these beneficial effects of VED devices, we believe that postoperative vacuum pump therapy may also play an important role in the improvement of microscopic compliance of the areolar cavernous tissue and in the achievement of a better collateral oxygenation of the residual cavernosal tissue surrounding the cylinders and the glans. These changes, along with the overall penile measurement improvement, could reflect the high median level of erectile function and treatment satisfaction delineated by the IIEF-5 and EDITS scores at the end of follow-up in our cohort.

In our experience the minimally invasive infrapubic approach allowed our patients to activate the device early, after a median of 8 days (range 5–12) from the surgery. This early activation might be able to support the device expansion within the corpora and to prevent the formation of a rigid pseudo-capsule surrounding the cylinders. Moreover, the beginning of an early postoperative VED program (starting from 3 weeks from the surgery) was seen to be safe and effective in stretching the tunica and allowing the device to expand progressively in the surrounding

tissues during follow-up was achieved. This is primarily seen in the maintenance of erect length and girth in our population over the course of the study. This is also seen in the increasing trend in the number of the pumps required to fully activate the device [1st activation: median 12 (range 8–16) vs. 48 weeks: median 24 (range 18–29); $p < 0.0001$]. Unlike Henry et al., we did not report a reduction in post-operative pumps to activate the device in the first post-operative period. This could be explained by our use of a minimally invasive infrapubic approach as compared to the penoscrotal approach and from the beneficial effects of early use of the VED.

Several limitations of our study should be noted. This is not a randomized double-blind controlled study. Our results are prospective but no control arm was created for comparison. All surgical procedures were performed by high-volume experienced surgeons and results may not be similar with less experienced implanters.

Conclusions

AMS™ LGX 700® IPP insertion together with a post-operative VED program is a safe and highly satisfactory combined approach to preserve penile dimensional outcomes in our selected cohort of patients without increased risk for corporal fibrosis. It is important for patients to have some skin in the game concerning their postoperative rehabilitation and a robust cycling/VED plan accomplishes just that. We believe that our postoperative rehabilitation program is feasible and should be recommended after prosthesis surgery in order to increase overall satisfaction with the procedure.

Compliance with ethical standards

Conflict of interest The authors declare that they have no conflict of interest.

Publisher's note: Springer Nature remains neutral with regard to jurisdictional claims in published maps and institutional affiliations.

References

1. NIH, C.D.P.o.I. NIH Consensus Conference. Impotence. *JAMA*. 1993;270:83.
2. Bettocchi C, Palumbo F, Spilotros M, Lucarelli G, Palazzo S, Battaglia M, et al. Patient and partner satisfaction after AMS inflatable penile prosthesis implant. *J Sex Med*. 2010;7(1 Pt 1):304–9.
3. Gonzalez-Cadavid NF. Mechanisms of penile fibrosis. *Sex Med*. 2009;6(Suppl 3):353–62.
4. Furlow WL, Goldwasser B, Gundian JC. Implantation of model AMS 700 penile prosthesis: long-term results. *J Urol*. 1988 Apr;139:741–2.
5. Deveci S, Martin D, Parker M, Mulhall JP. Penile length alterations following penile prosthesis surgery. *Eur Urol*. 2007 Apr;51:1128–31.
6. Dillon BE, Chama NB, Honig SC. Penile size and penile enlargement surgery: a review. *Int J Impot Res*. 2008;20:519–29.
7. Egydio PH, Kuehhas FE. Penile lengthening and widening without grafting according to a modified 'sliding' technique. *BJU Int*. 2015;116:965–72.
8. Chung PH, Siegel JA, Tausch TJ, Klein AK, Scott JM, Morey AF. Inflatable penile prosthesis as tissue expander: what is the evidence? *Int Braz J Urol*. 2017;43:911–6.
9. Gontero P, Di Marco M, Giubilei G, Bartoletti R, Pappagallo G, Tizzani A, et al. Use of penile extender device in the treatment of penile curvature as a result of Peyronie's disease. Results of a phase II prospective study. *J Sex Med*. 2009;6:558–66.
10. Gontero P, Di Marco M, Giubilei G, Bartoletti R, Pappagallo G, Tizzani A, et al. A pilot phase-II prospective study to test the "efficacy" and tolerability of a penile-extender device in the treatment of "short penis. *BJU Int*. 2009;103:793–7.
11. Levine LA, Newell M, Taylor FL. Penile traction therapy for treatment of Peyronie's disease: a single-center pilot study. *J Sex Med*. 2008;5:1468–73.
12. Antonini G, De Berardinis E, Del Giudice F, Busetto GM, Lauretti S, Fragas R, et al. Inflatable penile prosthesis placement, scratch technique and postoperative vacuum therapy as a combined approach to definitive treatment of Peyronie's disease. *J Urol*. 2018;200:642–7.
13. Antonini G, Busetto GM, De Berardinis E, Giovannone R, Vicini P, Del Giudice F, et al. Minimally invasive infrapubic inflatable penile prosthesis implant for erectile dysfunction: evaluation of efficacy, satisfaction profile and complications. *Int J Impot Res*. 2016;28:4–8.
14. Rosen RC, Riley A, Wagner G, Osterloh IH, Kirkpatrick J, Mishra A, et al. The international index of erectile function (IIEF): a multidimensional scale for assessment of erectile dysfunction. *Urology*. 1997;49:822–30.
15. Pisano F, Falcone M, Abbona A, Oderda M, Soria F, Peraldo F, et al. The importance of psychosexual counselling in the re-establishment of organic and erotic functions after penile prosthesis implantation. *Int J Impot Res*. 2015;27:197–200.
16. Althof SE, Corty EW, Levine SB, Levine F, Burnett AL, McVary K, et al. EDITS: development of questionnaires for evaluating satisfaction with treatments for erectile dysfunction. *Urology*. 1999;53:793–9.
17. Antonini G, Busetto GM, Del Giudice F, Ferro M, Chung BI, Conti SL, et al. Distal corporal anchoring stitch: a technique to address distal corporal crossovers and impending lateral extrusions of a penile prosthesis. *J Sex Med*. 2017;14:767–73.
18. Hellstrom WJ, Montague DK, Moncada I, Carson C, Minhas S, Faria G, et al. Implants, mechanical devices, and vascular surgery for erectile dysfunction. *J Sex Med*. 2010;7(1 Pt 2):501–23.
19. Montague DK. Penile prosthesis implantation in the era of medical treatment for erectile dysfunction. *Urol Clin North Am*. 2011;38:217–25.
20. Falcone M, Rolle L, Ceruti C, Timpano M, Sedigh O, Preto M, et al. Prospective analysis of the surgical outcomes and patients' satisfaction rate after the AMS Spectra penile prosthesis implantation. *Urology*. 2013;82:373–6.
21. Akin-Olugbade O, Parker M, Guhring P, Mulhall J. Determinants of patients satisfaction following penile prosthesis surgery. *16 J Sex Med*. 2006;3:743–8.
22. Levine LA, Becher EF, Bella AJ, Brant WO, Kohler TS, Martinez-Salamanca JI, et al. Penile prosthesis surgery: current recommendations from the international consultation on sexual medicine. *J Sex Med*. 2016;13:489–518.
23. Wang R, Howard GE, Hoang A, Yuan JH, Lin HC, Dai YT. Prospective and long-term evaluation of erect penile length

- obtained with inflatable penile prosthesis to that induced by intracavernosal injection. *Asian J Androl.* 2009;11:411–5.
24. Osterberg EC, Maganty A, Ramasamy R, Eid JF. Pharmacologically induced erect penile length and stretched penile length are both good predictors of post-inflatable prosthesis penile length. *Int J Impot Res.* 2014;26:128–31.
 25. Wallen JJ, Barrera EV, Ge L, Pastuszak AW, Carrion RE, Perito PE, et al. Biomechanical comparison of inflatable penile implants: a cadaveric pilot study. *J Sex Med.* 2018;15:1034–40.
 26. Negro CL, Paradiso M, Rocca A, Bardari F. Implantation of AMS 700 LGX penile prosthesis preserves penile length without the need for penile lengthening procedures. *Asian J Androl.* 2016;18:114–7.
 27. Henry GD, Carrion R, Jennermann C, Wang R. Prospective evaluation of postoperative penile rehabilitation: penile length/girth maintenance 1 year following Coloplast Titan inflatable penile prosthesis. *J Sex Med.* 2015;12:1298–304.
 28. Sellers T, Dineen M, Salem EA, Wilson SK. Vacuum preparation, optimization of cylinder length and postoperative daily inflation reduces complaints of shortened penile length following implantation of inflatable penile prosthesis. *Adv Sex Med.* 2013;3:14–18.