

## Distal Corporal Anchoring Stitch: A Technique to Address Distal Corporal Crossovers and Impending Lateral Extrusions of a Penile Prosthesis



Gabriele Antonini, PhD, MD,<sup>1</sup> Gian Maria Busetto, PhD, MD,<sup>1</sup> Francesco Del Giudice, MD,<sup>1</sup> Matteo Ferro, PhD, MD,<sup>2</sup> Benjamin I. Chung, MD,<sup>3</sup> Simon L. Conti, MD,<sup>3</sup> Alfredo Suarez Sarmiento, MD,<sup>4</sup> Arianna Pacchiarotti, PhD, MD,<sup>5</sup> Ettore De Berardinis, MD,<sup>1</sup> and Paul E. Perito, MD<sup>4</sup>

### ABSTRACT

**Background:** Unidentified distal crossovers, delayed distal crossovers, and impending lateral extrusion are complications of penile prosthesis implant insertion but are not as common as prosthesis infection or mechanical failure.

**Aim:** To evaluate results of a surgical technique, the distal corporal anchoring stitch, that addresses fixation of the penile prosthesis in patients with these complications.

**Methods:** A lateral sub-coronal incision is used on the side where the crossover or laterally extruding cylinder should be positioned. Dissection is carried through the Buck fascia, followed by a transverse incision of the tunica albuginea, where the distal aspect of the affected cylinder is delivered. A 4-0 PDS suture is threaded through the distal cylinder ring of the implant. A new, properly positioned intracorporal channel is created and the suture is passed through the distal end of the channel. Once the suture is through the glans and the cylinder is in the correct position, a small cruciate incision is made on the glans at the location of the anchor stitch. The suture is tied with the knot buried in the glans tissue.

**Outcomes:** Fifty-three patients underwent treatment of their distal penile implant crossover with a distal corporoplasty using this method and their anatomic and functional outcomes and overall satisfaction were evaluated.

**Results:** This technique ensured that the cylinder remained in the newly created, appropriately positioned channel. No patients developed infections, wound-healing defect, glandular hypoesthesia, anesthesia, or altered sensation or pain in the glans related to the suture and only two reported recurrence of a lateral herniation that did not require further treatment.

**Clinical Implications:** Distal fixation of the penile prosthesis is a useful surgical adjunct to treating patients with prosthetic lateral extrusions or crossovers that can be applied in almost all cases.

**Strengths and Limitations:** Considering these rare complications, our experience is based on a relatively large number of patients and showed a low incidence of complications and a high satisfaction rate. The main limitation of this study is the retrospective nature of the data and the series included patients from two high-volume surgeons that might not be generalizable to all practices.

**Conclusion:** The distal corporal anchoring stitch is safe and effective in securing distal fixation of the extruding inflatable penile prosthesis. **Antonini G, Busetto GM, Del Giudice F, et al. Distal Corporal Anchoring Stitch: A Technique to Address Distal Corporal Crossovers and Impending Lateral Extrusions of a Penile Prosthesis. J Sex Med 2017;14:767–773.**

Copyright © 2017, International Society for Sexual Medicine. Published by Elsevier Inc. All rights reserved.

**Key Words:** Distal Corporal Crossover; Impending Lateral Extrusion; Penile Prosthesis

### INTRODUCTION

Erectile dysfunction has an incidence ranging from 2% to 83% that varies with age and comorbidities and has an important

effect on male sexuality and quality of life that can the female partner's sexual life.<sup>1</sup> Inflatable penile prosthesis (IPP) implantation is a reliable treatment in almost all cases of medically

Received March 2, 2017. Accepted April 17, 2017.

<sup>1</sup>Department of Urology, Sapienza University of Rome, Rome, Italy;

<sup>2</sup>Department of Urology, Milan European Oncology Institute (IEO), Milan, Italy;

<sup>3</sup>Department of Urology, Stanford University Medical Center, Stanford, CA, USA;

<sup>4</sup>Miami Urology Specialists, FL, USA;

<sup>5</sup>Department of Urology, Rome San Filippo Neri Hospital, Italy

Copyright © 2017, International Society for Sexual Medicine. Published by Elsevier Inc. All rights reserved.

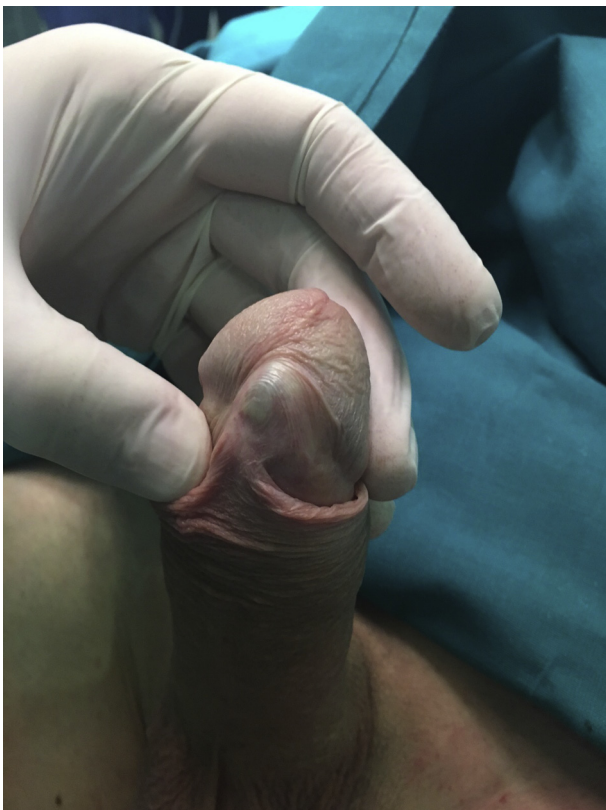<http://dx.doi.org/10.1016/j.jsxm.2017.04.669>

**Table 1.** Patient characteristics

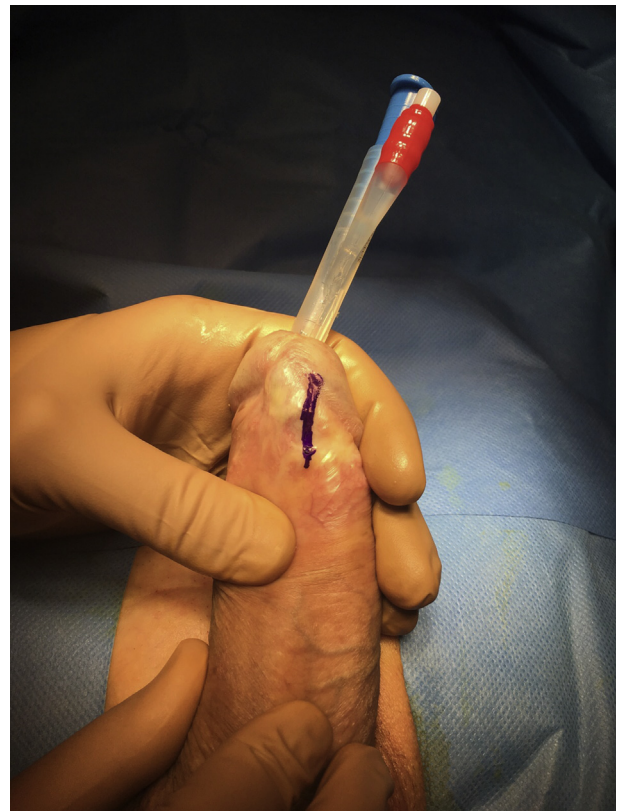Patients, N (%)	53 (100)
Age (y), median (range)	61.3 (44–71)
BMI (kg/m <sup>2</sup> ), median (range)	25.7 (21–29)
Hypertension, n (%)	22 (41.5)
Diabetes, n (%)	13 (24.5)
Active smokers, n (%)	18 (33.9)
Pathogenesis of ED, n (%)	
Multifactorial	33 (62.2)
Iatrogenic	20 (37.7)
IPP	0
Type of device implanted, n (%)	
AMS	23 (43.4)
Coloplast	30 (56.6)
Years from implant to surgical revision, median (range)	4.2 (1–9)
Site of corporal extrusion, n (%)	
Lateral extrusion	39 (73.5)
Unidentified distal crossovers	9 (16.9)
Delayed distal crossovers	5 (9.4)

BMI = body mass index; ED = erectile dysfunction; IPP = inflatable penile prosthesis.

refractory erectile dysfunction. As a demonstration of safety and effectiveness, recent data have reported satisfactory operation rates for primary implantation of 96% at 5 years and 60% at 15 years.<sup>2</sup>



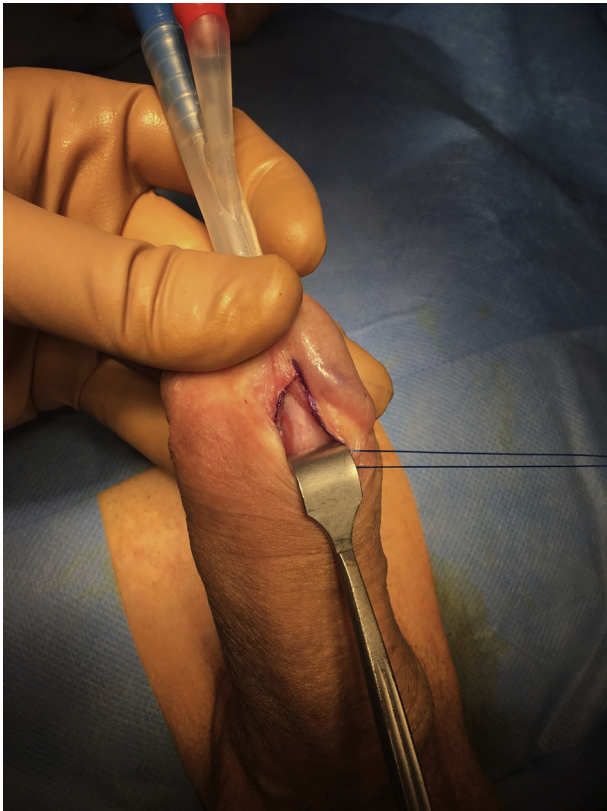**Figure 1.** Identification of impending extrusion or crossover. Figure 1 is available in color at [www.jsm.jsexmed.org](http://www.jsm.jsexmed.org).



**Figure 2.** Longitudinal incision localization. Figure 2 is available in color at [www.jsm.jsexmed.org](http://www.jsm.jsexmed.org).

After the first IPP implantation reported by Scott et al<sup>3</sup> in 1973, many advances in surgical technique and device technology have increased patient safety and satisfaction.<sup>4</sup> As expected, complications occur more commonly in patients with diabetes, spinal cord injury, and immunosuppression. Reported revision surgery for IPP implantation is more commonly required for cosmetic and erosion problems as opposed to mechanical failure.<sup>5</sup> The most common device failure is fluid leak from the prosthesis, whereas supersonic transport deformity, cylinders aneurismal dilatation, cylinders crossover, and impending lateral extrusion are less common.<sup>6</sup> It has been suggested that device replacement compared with repair leads to improved outcomes.<sup>5–7</sup>

When dealing with crossovers and impending lateral extrusions, it is important to determine which cases have evidence of urethral or skin extrusions and which cases have frank erosion. These complications are not as common as PP infection or mechanical failure but are as well described. In almost all cases, surgical repair is required and can be carried out with or without prosthesis explantation. The most ventral and distal portions of the corpora cavernosa are the thinnest, which has been suggested as the cause of the extrusions that commonly occur in these areas.<sup>8</sup> Crossovers and extrusions can be tested by placing a metal instruments such a Brooks dilator on the healthy corpora cavernosa and a second instrument on the contralateral corpora; this maneuver will accentuate the real anatomy and ensure an accurate evaluation of the damage.



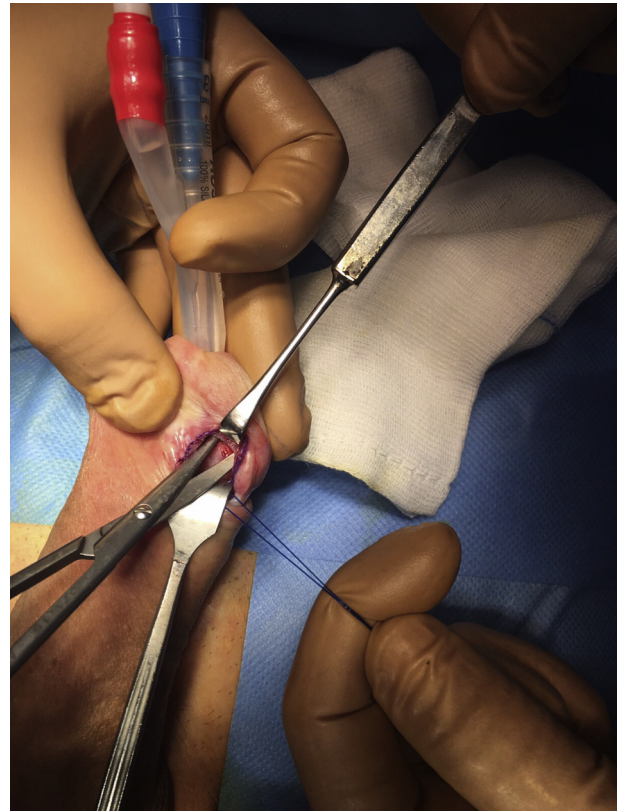**Figure 3.** Sub-coronal longitudinal incision. Figure 3 is available in color at [www.jsm.jsexmed.org](http://www.jsm.jsexmed.org).

In our experience, distal corporal crossover and impending lateral extrusion of a PP can cause pain and place the patient at high risk for erosion. Distal fixation of an IPP is a useful surgical adjunct to treating patients with previously unidentified distal crossovers, delayed distal crossovers, and impending lateral extrusion. We provide another novel method for its management, the distal corporal anchoring stitch, and describe its outcomes in a two-surgeon case series.

To evaluate reliability and safety of the technique in this series, intraoperative and postoperative results were recorded. Patient satisfaction was evaluated using international validated questionnaires (Erectile Dysfunction Inventory of Treatment Satisfaction [EDITs] and the five-item International Index of Erectile Function [IIEF-5]).

## METHODS

This retrospective study was conducted from January 2009 through June 2015 in 53 patients with an average age of 61.3 years. All patients had three-piece IPP models. Thirty Coloplast (Coloplast Corp, Minneapolis, MN, USA; 56.6%) and 23 AMS (American Medical Systems, Minnetonka, MN, USA; 43.4%) IPPs had been placed. Thirty-nine patients presented lateral extrusion of the prosthesis cylinders, 9 presented unidentified distal crossovers, and 5 presented delayed distal crossovers (patients' late recognition of crossover).

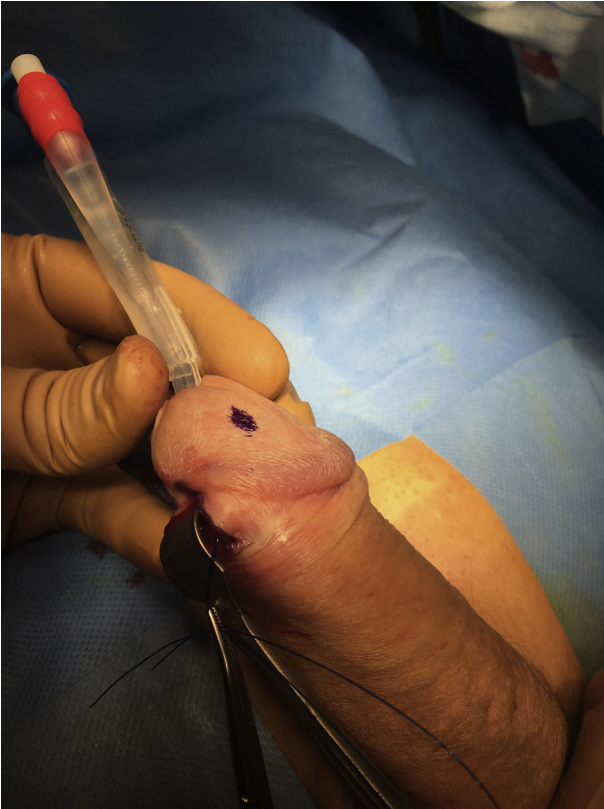

**Figure 4.** A new, properly positioned intracorporal channel. Figure 4 is available in color at [www.jsm.jsexmed.org](http://www.jsm.jsexmed.org).

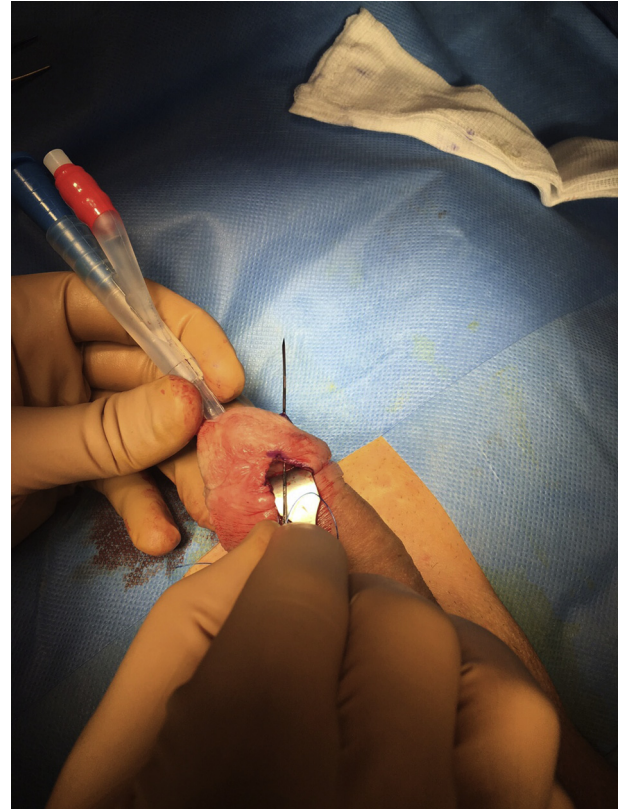
After evaluating each patient's history, risk factors, absence of infections, and Peyronie disease with corporal fibrosis, we proceeded with the distal corporal anchoring stitch technique. All patients underwent primary surgery and all procedures were carried out by one surgeon at the Urology Division of Coral Gables Hospital (Coral Gables, FL, USA) and another surgeon at the Department of Urological Sciences of Sapienza Rome University (Rome, Italy) (Table 1).

The study was approved by the institutional review boards and internal ethics committee and the committee for research in human subjects (Department of Gynecological-Obstetric Sciences and Urological Sciences, Sapienza Rome University, Ethical Committee). All treatments applied constituted routine standard care and the study was conducted in accord with European Urology and Good Clinical Practice guidelines, with ethical principles laid down in the most recent version of the Declaration of Helsinki.

With patients under local or general anesthesia, the skin is shaved and prepped for 10 minutes with a povidone-iodine solution, an 18-Fr Foley catheter with straight drainage is placed, and a dose of intravenous cefazolin is administered. The first step of the procedure is identification of the impending extrusion or crossover after inflation of the prosthesis (Figure 1). A lateral, longitudinal, and sub-coronal incision of 1 cm is made on the side where the crossover or laterally extruding cylinder should be positioned (Figures 2 and 3). To avoid prosthesis



**Figure 5.** External suture final localization through the distal end of the channel. Figure 5 is available in color at [www.jsm.jsexmed.org](http://www.jsm.jsexmed.org).



**Figure 6.** PDS suture passed through the distal end of the channel. Figure 6 is available in color at [www.jsm.jsexmed.org](http://www.jsm.jsexmed.org).

damage, it is important to use cautery with a needle-point electrode. Dissection is carried through the Buck fascia, followed by a transverse incision of the tunica albuginea, where the distal aspect of the affected cylinder is delivered. A 4-0 PDS suture is threaded through the distal cylinder ring of the implant after the original suture is removed. The pseudocapsule incision is made with a cold steel scalpel on the proximal and distal aspects. A new, properly positioned intracorporal channel is created using scissors and Hegar dilators (Figure 4). Using a Keith needle and a Furlow device, the 4-0 PDS is passed through the distal end of this channel (Figures 5–7). Once the suture is through the glans and the cylinder is in the correct position, a small cruciate incision is made on the glans, at the location of the anchor stitch. The suture is tied with the knot buried in the glans tissue (Figure 8). This creates a fibrotic process that fixes the prosthesis to the glans. The cruciate incision is closed with Dermabond (Ethicon, Cincinnati, OH, USA). The corporoplasty incision is closed in standard fashion and routine postoperative care is followed (Figures 9 and 10).

Intraoperative and postoperative data were analyzed using a minimum follow-up period of 15 months. Intraoperative data included complications and postoperative data included complications and patient's satisfaction with operation of the prosthesis. Postoperative erectile function was evaluated using the validated, self-administered IIEF-5 that is based on five questions

about erectile function (score = 5–25), and the EDITS is based on 16 items about erectile function and sexual intercourse satisfaction after treatment divided in 11 questions for the patient and 5 for the partner (score = 0–100).

## RESULTS

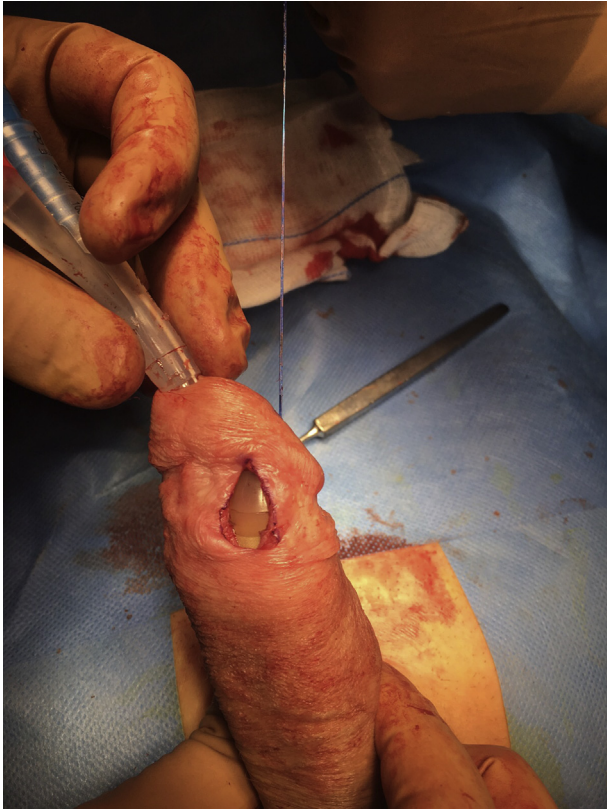Fifty-three patients with a mean age of 61.3 years (range = 44–71 years) underwent treatment of their distal IPP crossover with a distal corporoplasty using the distal corporal anchoring stitch technique (39 lateral extrusions, 9 unidentified crossovers, and 5 delayed crossovers). The age of the IPP was 1 to 9 years. The surgical procedure was the same and carried out by two different surgeons in two different centers.

There were no intraoperative complications and the median time to complete the procedure was 69 minutes (range = 52–121 minutes).

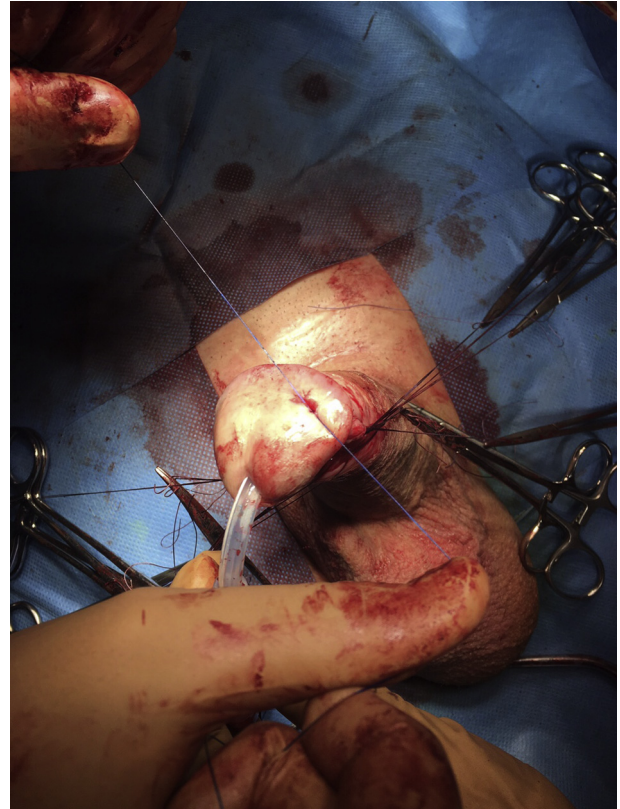
Fifty patients (94.3%) were discharged the day after surgery. Only 3 (5.7%) remained for 2 days.

After surgery the median follow-up time was 46.8 months (minimum = 15 months).

The postoperative results showed that no patients developed any infections, wound-healing defect, glandular hypoesthesia, anesthesia, or altered sensation or pain in the glans related to the suture and only two patients (3.8%) reported recurrence of a



**Figure 7.** PDS suture tightened through the channel. Figure 7 is available in color at [www.jsm.jsexmed.org](http://www.jsm.jsexmed.org).



**Figure 8.** Suture knot buried in the glans tissue. Figure 8 is available in color at [www.jsm.jsexmed.org](http://www.jsm.jsexmed.org).

lateral herniation. None of the prostheses required replacement because of extrusion, mechanical failure, or infection.

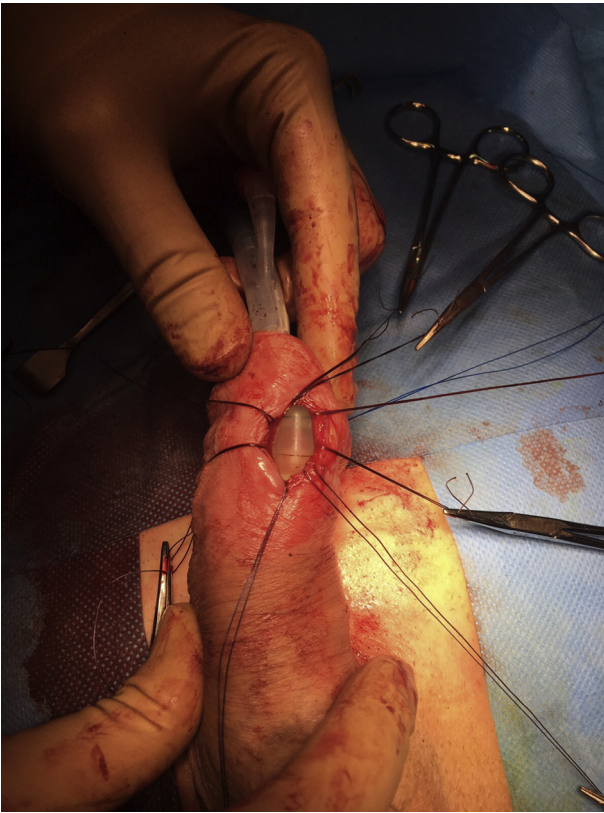
For patients' satisfaction after surgery, the mean IIEF-5 score was  $18.8 \pm 3.4$  and the mean EDITS score was  $79.1 \pm 19.8$ . After stratifying cases by EDIT score (0–20 = very unsatisfied, 21–40 = moderately unsatisfied, 41–60 = moderately satisfied, 61–80 = very satisfied, 81–100 = completely satisfied), 2 patients were moderately unsatisfied, 8 were moderately satisfied, 33 were very satisfied, and 10 were completely satisfied (Table 2).

## DISCUSSION

Our data showed low rates of complications and no reoperations. Onyeji et al<sup>9</sup> studied 14,969 patients who underwent IPP placement and found a reoperation rate of 6.4% at a median follow-up of 95.1 months; 2.5% of procedures were performed for infectious complications, whereas 3.9% of procedures were performed for non-infectious ones, and there is a statistically significant difference in the incidence of complications between the low- and high-volume implant surgeons. In another series analyzing 214 revision surgeries, the investigators reported that 5.7% of revised prostheses developed infection, impending extrusion, and/or erosion. After these events, the complication developed in 5% of cases if the prosthesis was

completely replaced compared with 9.1% if the damage was only repaired.<sup>10</sup>

Distal corporal crossover and impending lateral extrusion are non-infectious complications of IPP implantation and we present a surgical technique that can be a reliable alternative to other proposed procedures. Dilatation of the corpora during IPP implantation has been reported as the most dangerous surgical step for the delayed occurrence of complications.<sup>11</sup> In 1998 the first management of impending penile prosthesis erosion was performed on five patients by Smith et al<sup>12</sup> using a polytetrafluoroethylene distal windsock graft. This approach was technically complex and required considerable graft preparation, but the results were good with a low incidence of complications in a small series. After this first experience, other techniques have been proposed by different surgeons based on small patient samples and divided into cases with evidence of urethral or skin extrusion and cases without. For cases without erosion, Alter et al<sup>13</sup> proposed a technique that reinforces the corpora cavernosa using an autologous flap of the tunica vaginalis (rectus fascia grafted together with the tunica vaginalis) that, after 2 weeks of stabilization, can be used to cover the defect. Mulcahy<sup>14</sup> proposed a distal corporoplasty for the same distal extrusion. After a corporotomy, to expose the fibrotic sheath around the prosthesis, a new plane extending in the glans is identified and the prosthesis is repositioned. Shaer<sup>15</sup>

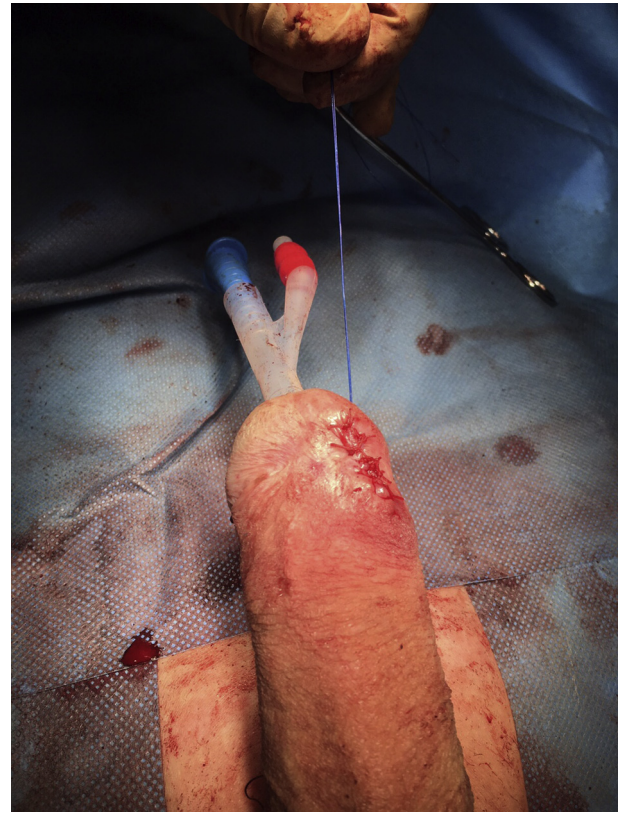

**Figure 9.** Closure of longitudinal sub-coronal incision. Figure 9 is available in color at [www.jsm.jsexmed.org](http://www.jsm.jsexmed.org).

reported on three cases with frank erosion and described a total penile disassembly with exogenous graft positioning or a double-breasting primary technique to reinforce the area of the damage. Another series comparing techniques included 28 patients in which 10 underwent fixation using a Gore-Tex windsock and 18 underwent the full Mulcahy corporoplasty. Results were satisfactory, with a slight advantage, in results and complications, for corporoplasty.<sup>16</sup>

Our series are based on a technique that does not require replacement of the prosthesis and can be carried out in patients with two-piece and three-piece equipment. It is based on a larger number of patients than many other series and has an equally low incidence of complications and a high incidence of satisfaction. The risk of altered sensation, because of glans incision and manipulation, was not reported by any of our patients.

Based on our experience, we believe it is important to follow some simple steps to obtain better results. Before starting the procedure, the prosthesis must be inflated and the tip of the cylinder must be positioned in the middle of the hemi-glans. The lateral sub-coronal incision should be 1 cm long and must be longitudinal to limit sensory nerve damage. The glans incision, even with bleeding, should be small and cruciate to better tighten the anchor stitch. The anchor stitch should be reabsorbable to avoid stitch sensation and to avoid problems in case device replacement is required in the future because a repeat



**Figure 10.** Final result of corporoplasty incision. Figure 10 is available in color at [www.jsm.jsexmed.org](http://www.jsm.jsexmed.org).

trans-glansular incision might be necessary to remove the cylinder. Placing a catheter during the procedure is important to better control the urethra even if the approach is performed

**Table 2.** Perioperative and postoperative data

Follow-up (mo), median (range)	46.8 (15–107)
Operative time (min), median (range)	69 (52–121)
Hospital stay, n (%)	
1 d	50 (94.3)
2 d	3 (5.6)
Intraoperative complications, n (%)	0
Postoperative complications, n (%)	
Infections	0
Wound-healing defect	0
Glandular hypoesthesia	0
Glandular pain or discomfort	0
Mechanical failure of device	0
Lateral extrusion recurrence	2 (3.7)
Postoperative IIEF-5 score, mean $\pm$ SD	18.8 $\pm$ 3.4
Postoperative EDITS score, mean $\pm$ SD	79.1 $\pm$ 19.8
EDITS scoring group	
Very unsatisfied (score = 0–20)	2 (3.7)
Moderately unsatisfied (score = 41–60)	8 (15)
Moderately satisfied (score = 61–80)	33 (62.2)
Very satisfied (score = 80–100)	10 (18.8)

EDITS = Erectile Dysfunction Inventory of Treatment Satisfaction; IIEF-5 = five-item International Index of Erectile Function.

through a lateral incision and not with a corporoplasty. An altered sensation from the glans incision and manipulation was not reported by any of our patients.

Shindel et al<sup>17</sup> proposed a similar technique but reported on results from only six patients and used permanent sub-glanular sutures that we believe would be likely to cause bother and changes in sensation. Last but not least, previous proposed modalities for managing these complications carry the risk of recurrence secondary to a tenuous or absent tunica.

To date, a validated tool to assess satisfaction after PP implantation has not been realized. However, the IIEF and EDITS are validated questionnaires to evaluate erectile function and satisfaction. Even if not recognized for this use, these questionnaires were used to rate patient and partner satisfaction after surgery and to evaluate erection validity and durability.

The main limitation of our study is the retrospective nature of the data and this series included patients from two high-volume surgeons that might not be generalizable to all practices.

## CONCLUSIONS

The distal corporal anchoring stitch is a safe and effective technique in securing distal fixation of the IPP. Patient and partner satisfaction is high and intra- and postoperative complications are rare. We believe this is a feasible technique for experienced surgeons that can be applied in almost all cases of prosthetic lateral extrusions or crossovers.

**Corresponding Author:** G.M. Busetto, Sapienza Rome University, Policlinico Umberto I, Viale del Policlinico, 155, 00161 Rome, Italy. Tel: +39-335-823-6550; Fax: 390649974280; E-mail: [gianmaria.busetto@uniroma1.it](mailto:gianmaria.busetto@uniroma1.it)

*Conflicts of Interest:* The authors report no conflicts of interest.

*Funding:* None.

## STATEMENT OF AUTHORSHIP

### Category 1

#### (a) Conception and Design

G. Antonini; G.M. Busetto; P.E. Perito

#### (b) Acquisition of Data

G. Antonini; F. Del Giudice; P.E. Perito

#### (c) Analysis and Interpretation of Data

G.M. Busetto; M. Ferro; E. De Berardinis

### Category 2

#### (a) Drafting the Article

G.M. Busetto

#### (b) Revising It for Intellectual Content

B.I. Chung; S.L. Conti

### Category 3

#### (a) Final Approval of the Completed Article

A. Suarez Sarmiento; A. Pacchiarotti

## REFERENCES

1. Porst H, Sharlip I. History and epidemiology of male sexual dysfunction. In: Porst H, Buval J, eds. *Standard practice in sexual medicine*. Malden, MA: Blackwell Publishing; 2006. p. 43-48.
2. Rajpurkar A, Dhabuwala CB. Comparison of satisfaction rates and erectile function in patients treated with sildenafil, intracavernous prostaglandin E1 and penile implant surgery for erectile dysfunction in urology practice. *J Urol* 2003;170:159-163.
3. Scott FB, Bradley WE, Timm GW. Management of erectile impotence: use of implantable inflatable prosthesis. *Urology* 1973;2:80-82.
4. Antonini G, Busetto GM, De Berardinis E, et al. Minimally invasive infrapubic inflatable penile prosthesis implant for erectile dysfunction: evaluation of efficacy, satisfaction profile and complications. *Int J Impot Res* 2016;1:4-8.
5. Henry GD, Wilson SK, Delk JR II, et al. Revision washout decreases penile prosthesis infection in revision surgery: a multicenter study. *J Urol* 2005;173:89-92.
6. Levine LA, Becher E, Bella A, et al. Penile prosthesis surgery: current recommendations from the International Consultation on Sexual Medicine. *J Sex Med* 2016;13:489-518.
7. Henry GD, Wilson SK, Delk JR II, et al. Penile prosthesis cultures during revision surgery: a multicenter study. *J Urol* 2004;172:153-156.
8. Hsu GL, Brock G, Martinez-Pineiro L, et al. Anatomy and strength of the tunica albuginea: its relevance to penile prosthesis extrusion. *J Urol* 1994;151:1205-1208.
9. Onyeji IC, Sui W, Pagano MJ, et al. Impact of surgeon case volume on reoperation rates after inflatable penile prosthesis surgery. *J Urol* 2017;197:223-229.
10. Henry GD, Donatucci CF, Connors W, et al. An outcome analysis of over 200 revision surgeries for penile prosthesis implantation: a multicenter study. *J Sex Med* 2012;9:309-315.
11. Henry GD, Laborde E. A review of surgical techniques for impending distal erosion and intraoperative penile implant complications: part 2 of a three-part review series on penile prosthetic surgery. *J Sex Med* 2012;9:927-936.
12. Smith CP, Kraus SR, Boone TB. Management of impending penile prosthesis erosion with a polytetrafluoroethylene distal wind sock graft. *J Urol* 1998;160:2037-2040.
13. Alter GJ, Greisman J, Werthman PE, et al. Use of a prefabricated tunica vaginalis fascia flap to reconstruct the tunica albuginea after recurrent penile prosthesis extrusion. *J Urol* 1998;159:128-132.
14. Mulcahy JJ. Distal corporoplasty for lateral extrusion of penile prosthesis cylinders. *J Urol* 1999;161:193-195.
15. Shaer O. Management of distal extrusion of penile prosthesis: partial disassembly and tip reinforcement by double breasting or grafting. *J Sex Med* 2008;5:1257-1262.
16. Carson CC, Noh CH. Distal penile prosthesis extrusion: treatment with distal corporoplasty or Gortex windsock reinforcement. *Int J Impot Res* 2002;14:81-84.
17. Shindel AW, Brant WO, Mwamukonda K, et al. Transglanular repair of impending penile prosthetic cylinder extrusion. *J Sex Med* 2010;7:2884-2890.