



THE UNIVERSITY *of* EDINBURGH

Edinburgh Research Explorer

Mondor's Disease of the Breast: A cutaneous thromboembolic manifestation of Covid-19?

Citation for published version:

Renshaw, L, Dixon, M, Anderson, J & Turnbull, AK 2022, 'Mondor's Disease of the Breast: A cutaneous thromboembolic manifestation of Covid-19?', *The Breast*. <https://doi.org/10.1016/j.breast.2022.11.006>

Digital Object Identifier (DOI):

[10.1016/j.breast.2022.11.006](https://doi.org/10.1016/j.breast.2022.11.006)

Link:

[Link to publication record in Edinburgh Research Explorer](#)

Document Version:

Publisher's PDF, also known as Version of record

Published In:

The Breast

Publisher Rights Statement:

This is an open access article under the CC BY-NC-ND license (<http://creativecommons.org/licenses/by-nc-nd/4.0/>).


General rights

Copyright for the publications made accessible via the Edinburgh Research Explorer is retained by the author(s) and / or other copyright owners and it is a condition of accessing these publications that users recognise and abide by the legal requirements associated with these rights.

Take down policy

The University of Edinburgh has made every reasonable effort to ensure that Edinburgh Research Explorer content complies with UK legislation. If you believe that the public display of this file breaches copyright please contact openaccess@ed.ac.uk providing details, and we will remove access to the work immediately and investigate your claim.





Mondor's disease of the breast: A cutaneous thromboembolic manifestation of Covid-19?

Lorna Renshaw^{a,b}, J Michael Dixon^{a,b}, Julia Anderson^c, Arran K. Turnbull^{a,b,*}

^a Edinburgh Breast Unit, Western General Hospital, Edinburgh, Scotland, United Kingdom

^b Edinburgh Cancer Research Centre, MRC Institute of Genetics and Cancer, Edinburgh, Scotland, United Kingdom

^c Department of Haematology, Royal Infirmary of Edinburgh, Scotland, United Kingdom

ABSTRACT

Background: Mondor's disease is a rare disorder characterised by thrombosis of superficial veins within the subcutaneous tissue of the breast and other organs. While factors such as trauma, infection, physical exertion, breast cancer and breast surgery have been implicated, in the majority no cause is identified.

Patients: Twenty patients presented with a clinical diagnosis of Mondor's disease to the Edinburgh Breast Services in 2020. We present the etiopathogenic data as well as clinical and imaging diagnostic findings.

Results: During 2020, the annual incidence of Mondor's disease, in the UK's largest breast unit, increased five-fold compared to data from the previous year. This variation in the frequency of cases corresponded to trends in the frequency of Covid-19 infection during the pandemic. None of the patients had diagnosed COVID and few had any known etiopathogenic causes for their Mondor's.

Conclusion: Several recent studies have provided evidence for links between Covid-19 and thromboembolic events. Isolated reports have proposed a link between Covid-19 and Mondor's disease of the penis. Here we present data on a large series of Mondor's disease of the breast supporting a link between breast Mondor's and Covid-19.

1. Introduction

A recent article entitled COVID-19 Era: "Mondor's disease and Rembrandt. What ties?" [1] emphasises the need to be aware of rare varieties of venous thrombosis such as Mondor's disease. Characterised by thrombosis of the superficial veins within the subcutaneous tissue of the breast and other organs, Mondor's disease is rare enough that most primary care clinicians will never personally have seen a case [2]. Cases of cord-like lesions on the chest wall were first reported in the early 1850s. Henri Mondor, a French surgeon, reported a case series in 1939.

The aetiology of Mondor's disease of the breast and local chest wall is multifactorial, although in many cases no specific events are identified. The most common etiopathogenic factors are traumatic events, excessive physical exercise, breast surgery (including augmentation, reduction mammoplasty and breast biopsy), infections, use of the oral contraceptive pill and pregnancy. Underlying breast cancer has been reported in up to 12.7% of cases and is considered a synchronous marker. Mondor's disease can occur in males as well as females (ratio 9:1) [3,4].

Patients with acute Mondor's disease typically present with pain, tenderness, and a linear area of skin erythema. There is usually a tender

palpable cord rather than a palpable nodule. Because the thrombosed vein can be tortuous and vary in calibre it is often unevenly thrombosed. The palpable abnormality can thus be a torturous row of small nodules. In severe cases the inflammatory reaction around the acutely thrombosed vein causes retraction and dimpling, that may only be noticeable in the upright position. The vein most commonly involved is the thoracoepigastric vein, which courses from the inferolateral aspect of the breast downwards towards the abdomen. The second most commonly involved vein is the lateral thoracic vein, which courses from the lateral aspect of the breast to the axilla [2]. Interestingly, the shoulder harness component of seat belts parallels the route of these two veins and car accidents involving seatbelts can result in Mondor's through trauma.

1.1. Radiological findings

At ultrasonography, the thrombosed vessel appears as a superficially located, long, tubular, anechoic structure with a beaded appearance that does not have any flow on colour or spectral Doppler studies. The entire course of the thrombosed vessel is often not visible on mammographically dense breast [4,7].

It was noted that more cases of Mondor's were being seen in the

* Corresponding author. Cancer Research UK Edinburgh Centre, MRC Institute of Genetics & Cancer, The University of Edinburgh, Western General Hospital, Crewe Road South, Edinburgh, UK.

E-mail address: A.Turnbull@ed.ac.uk (A.K. Turnbull).

<https://doi.org/10.1016/j.breast.2022.11.006>

Received 5 October 2022; Accepted 17 November 2022

Available online 17 November 2022

0960-9776/© 2022 Published by Elsevier Ltd. This is an open access article under the CC BY-NC-ND license (<http://creativecommons.org/licenses/by-nc-nd/4.0/>).

breast clinics during the COVID 19 pandemic and the aim of the current study was to quantify the rate of Mondor’s disease of the breast throughout the pandemic in 2020 before vaccination started in the UK.

1.2. Patient cohorts and data collection

The Edinburgh Breast Unit is the largest UK centre. All Patients within the Edinburgh catchment area of approximately 450,000 people are seen at the Edinburgh Breast Unit or by consultants working within the Unit. In a typical year, 7–8000 new patients are referred for assessment. All diagnostic records from new patient clinics throughout Breast Services in Edinburgh were reviewed from 01/01/2019 to 31/12/2020. For cases seen outwith the Edinburgh Breast Unit based at the Western General Hospital, only the final recorded diagnosis was available for this study. Dates of consultations, clinical findings, past medical history including any history of COVID-19 infection, results of imaging studies, patient ages and details of clinical examinations were available for all Edinburgh Breast Unit patients. This study was registered with the Cancer Data and Information Programme at the Edinburgh Cancer Centre on 08/07/2020 under reference CIR20081 and was approved for publication.

2. Results

2.1. Incidence of Mondor’s disease and Covid-19

In 2019, over a 12 month period, there were 4 reported cases of Mondor’s disease in the new patient setting out of 7123 patients seen in clinic during this period (incidence of 0.06%, incidence rate 1:1781). This falls just below the reported annual incidence of 0.07–0.96% [5]; however, it should be noted that our figures pertain only to the new patient clinic. The reported annual incidence combines cases diagnosed in new patient clinics with those seen in surgical follow-up and long-term follow-up breast cancer clinics, where Mondor’s is not infrequently seen shortly after breast surgery. In the first quarter of 2020 (January 1st-March 31st) from a total of 1884 new patient referrals there was only 1 diagnosis of Mondor’s disease (incidence of 0.05%). During the second quarter (April 1st – June 30th), which corresponds to the first wave of Covid-19 in the Scotland, there were 1764 new patients seen and there were 10 cases of Mondor’s disease (incidence of 0.57%). In the third quarter (July 1st – Sept 30th) 1548 new patient referrals were seen and five cases of Mondor’s disease were diagnosed (incidence of 0.32%). During the final quarter of 2020, 1937 new patients were assessed and there were four cases of Mondor’s disease diagnosed (incidence of 0.21%). Overall, in 2020, over a 12-month period, 7133 new patients were seen and 20 cases of Mondor’s disease were diagnosed (incidence of 0.28%, incidence rate of 1:446). This equates to an incidence ratio rate in 2020 compared with 2019 of 4.99 (P = 0.0009), and thus the incidence rate of Mondor’s disease was approximately 5 times higher in 2020 compared to 2019. The number of cases of Mondor’s disease recorded each month throughout 2020 was positively correlated with the Scottish Government’s reported monthly cases of Covid-19 (Spearman’s Rho $r = 0.35$) and despite low numbers of Mondor’s disease cases recorded overall, noticeable peaks in monthly incidence throughout 2020 could be observed to coincide with both the 1st (March–May 2020) and 2nd wave (September onwards 2020) of the Covid-19 pandemic, although there were insufficient cases for robust statistical comparison (Fig. 1).

3. Patient characteristics

Table 1 shows the patient characteristics for the cohort of patients diagnosed with Mondor’s disease during 2020. Further details are given in Supplementary Table 1. Overall 20 Caucasian women were diagnosed with Mondor’s disease during this study. 16 patients were diagnosed in new patient clinics at the Edinburgh Breast Unit and 4 others seen at

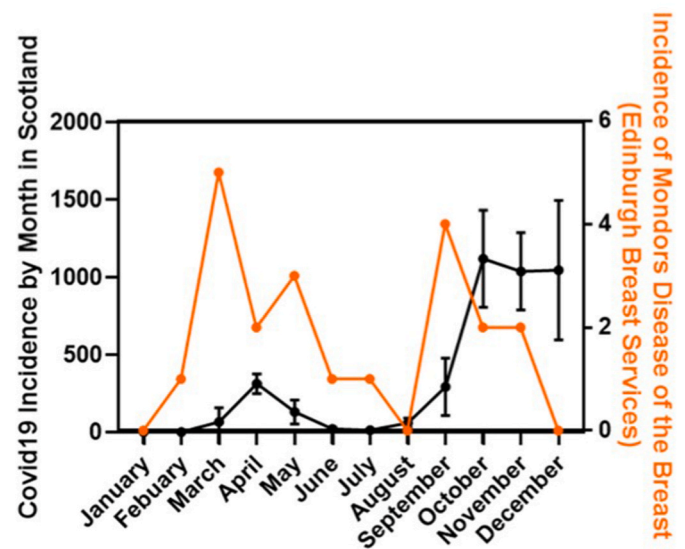


Fig. 1. Monthly incidence of Mondor’s disease of the breast diagnosed at Edinburgh Breast Services and monthly incidence of Covid-19 in Scotland. Graph showing mean and standard deviation for daily incidence of Covid-19 new diagnoses recorded for each month in Scotland during 2020 from the Scottish Government Population Health Directorate (left y-axis) and the total number of Mondor’s disease cases diagnosed within Edinburgh Breast Services during 2020 (right y-axis, orange).

Table 1

Patient characteristics and summary of imaging performed for the cohort of 20 patients diagnosed with Mondor’s disease during 2020.

Clinical Details	Numbers
Location of Mondor’s Disease	
Breast	18
Abdominal Wall	2
Predisposing Factors	
Reported injury/trauma	1
Infection	1
Previous breast cancer with ipsilateral surgery	5
Age at diagnosis of Mondor’s Disease	25–70
Other co-morbidities	
Current active smoker	1
Reported alcohol excess	1
Diabetes Mellites	1
Obesity	3
Mammography performed	
Yes	9
No	11
US performed	
Yes	9
No	11

other clinics in Edinburgh. Diagnoses were based on clinical examination with or without radiological investigations. All patients were female with ages ranging from 25 to 70, and eight of the women (40%) were under 35 years of age. One patient was a current smoker, and one was an ex-smoker, who also admitted to excess alcohol intake. All others were non-smokers and reported average alcohol consumption. In terms of previous medical history, three patients were clinically obese with BMI >30, and 1 of these patients also had both hypertension and type 2 diabetes mellitus. No patients in the study were pregnant or taking the oral contraceptive pill (OCP).

Diagnosis of Mondor’s disease was made by highly experienced Breast clinicians (6 breast surgeons, 1 breast radiologist and 2 advanced nurse practitioners), each diagnosing between 1 and 5 cases. All were familiar with Mondor’s disease and had seen and diagnosed the condition previously. Most patients were diagnosed with Mondor’s disease

based solely on history and physical examination, although some also had imaging and all had salient signs and symptoms of localised pain, tenderness, cording and retraction/indentation, features observed during the acute phase. One patient was diagnosed on imaging alone and had a previous breast cancer diagnosis. A clinical photograph of one representative patient with Mondor's disease of the breast is shown in Fig. 2.

Of the 20 reported cases 18 were found in the breast and 2 were found in the abdominal wall immediately beneath the breast. In both these cases, previous breast surgery had been performed. Thirteen women had no recognised predisposing factors such as recent injury or trauma, recent physical activity, recent infection, or previous cancer. Of the remaining seven, one reported excessive gardening prior to presentation, one was found to have a recent likely skin infection of the breast and four had previous invasive breast cancer treated at least one year prior to the diagnosis of Mondor's so were not in the acute post-operative phase when Mondor's is often seen. One had lobular carcinoma in situ (LCIS) diagnosed over 5 years prior to being diagnosed with Mondor's. In all but one of these five patients the previous excised breast lesion was ipsilateral to the presentation of Mondor's disease, however the patient with a previous contralateral lesion also had a risk reducing contralateral mastectomy ipsilateral to the presentation of Mondor's disease. No patients had clinical or radiological evidence of locoregional or systemic recurrence at time of Mondor's disease diagnosis in the new patient clinic. Only one patient was on active treatment, in the form of adjuvant tamoxifen, at time of presentation.

None of the 20 women was tested for Covid-19, and none reported any recent symptoms of Covid-19 on direct questioning (such as a high temperature, a new continuous cough, or a loss of change in sense of smell or taste) or reported a past history of Covid-19 on the day of their clinic appointment. As this is a retrospective study, we have no information on symptoms or diagnosis of Covid-19 prior to attendance at the breast unit. No patients in this study had received any Covid-19 vaccination prior to their presentation.

3.1. Radiological findings

Nine patients had mammography, 8 with a clinical diagnosis of Mondor's disease of the breast and one with Mondor's located on the abdominal wall. Of the eight with breast Mondor's, all but one had normal mammograms. In the other a defined beaded, elongated structure was seen on mammography related to the Mondor's. Of those that did not have mammography, 9 were 40 years old or younger and

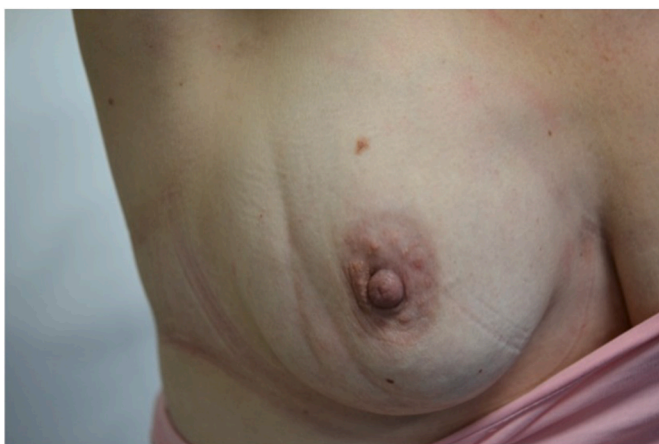

Fig. 2. Medical photograph of Mondor's disease from one of the patients who presented during 2020. A linear bifurcating indentation, representing a thrombosed vessel, can be seen coursing down the lateral aspect of the right breast, typical of Mondor's disease. Signed informed consent was obtained from the patient allowing for used and publication of the above photograph.

mammography is not routinely performed due to the breast density associated with younger age – and in these women Mondor's was diagnosed confidently on clinical examination alone. Nine patients had ultrasound scans of the breast, two of which were performed at a peripheral clinic and reports were not available for this study. Of the seven reported scans, four confirmed the presence of thrombosed or corded vessels at the corresponding locations identified during clinical examination.

Patient 11 was a 52 year old woman who presented with a 3 week history of likely infection of the left breast underwent radiological investigations by both mammography and ultrasound (Fig. 2). Clinically between 2 and 3 o'clock there was a visible thrombosed superficial vein extending vertically across left breast lateral to left areola. At the lower end around 3–4 o'clock, there appeared to be a resolved area of skin infection. Mammograms were reported as normal while the focused ultrasound scan showed a thrombosed superficial vessel, consistent with a diagnosis of Mondor's disease (Fig. 3).

4. Discussion

Here we present a cohort of 20 patients with a diagnosis of Mondor's disease made by experienced clinicians who are familiar with the disease and its appearance. In the majority of patients, a diagnosis was made on clinical examination alone. Although the numbers of imaging studies performed in this cohort is small, our data suggests that focused ultrasound is superior to mammography for the visualisation of Mondor's disease.

In this retrospective study, we demonstrate that there was a significantly higher incidence of Mondor's disease seen in the Edinburgh Breast Services during March to December 2020 compared with the previous year. We are also the first to observe that this increased incidence of Mondor's disease of the breast coincided with the onset of the Covid-19 pandemic. While the overall number of cases of Mondor's disease is small, the peaks in incidence of Mondor's disease coincided with the 1st and 2nd waves of Covid-19 in Scotland seen during 2020. It has been reported that Covid-19 predisposes to both venous and arterial thromboembolism due to excessive inflammation, hypoxia, immobilisation and diffuse intravascular coagulation. Thrombotic complications were reported in 31% of patients in one ITU setting during the pandemic [6]. Indeed, recent studies have provided further evidence for a link between Covid-19 and thromboembolism [11–14] and Long Covid and thromboembolism [18,19]. A number of recent case reports have also suggested a link between Mondor's disease of the penis and Covid-19 [10,15,16]. It is recognised that large numbers of people had asymptomatic Covid-19 infection. A recent meta-analysis suggested that the proportion of asymptomatic Covid-19 infections may have been as high as one third [20]. In 2020, there was no widespread testing and lateral flow tests were not available. None of the patients we studied had Covid-19 vaccination either. Our explanation for our findings is that patients with Mondor's may have had a previous infection with Covid-19 and that Mondor's was a late feature of the prior infection, a feature of Long Covid or that they had a current or recent asymptomatic Covid-19 infection and during this infection developed Mondor's. By the time they were reviewed in the breast clinic they were in the recovery phase of Covid-19, this explains why they had none of the characteristic Covid-19 symptoms were present at the time of their clinic appointment.

A literature review published in 2018 of 186 cases of Mondor's disease of the chest wall, concluded that 45% of cases were idiopathic and in 55% likely etiopathogenic causes could be discerned [8]. The most common etiopathogenic factors described include traumatic events, excessive physical exercise, breast surgery, infections, concomitant OCP and pregnancy. In our cohort 1 of the 20 women reported excessive gardening prior to presentation and 1 presented with a 3-week history of a likely breast skin infection, none of the others reported any recent common predisposing factors suggesting that only 10% of patients in our study had a possible etiopathogenic cause. Some studies

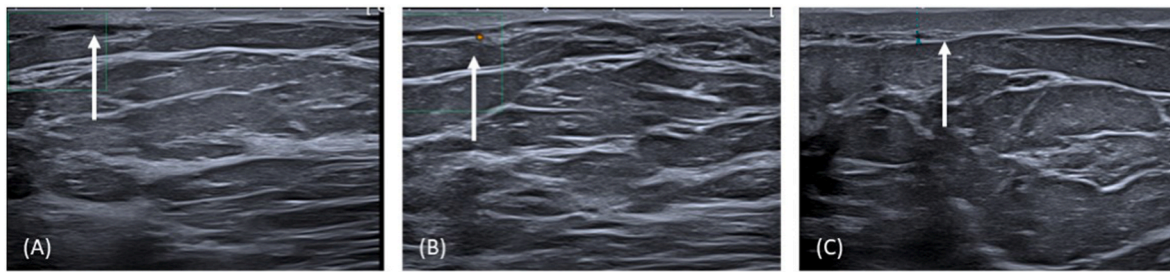


Fig. 3. Ultrasound Images. Focused ultrasound scan of reddened area in left lateral breast and region superior. There was skin thickening measuring 3.8 mm at the site of the red skin in the left lateral breast at 3–4 o'clock (C). No underlying collection was present. Slightly superior at 2–3 o'clock at the site of ridge-like lumpiness, there was an elongated blood vessel lying below the dermis, which was not completely compressible and does not demonstrate colour flow on doppler (A + B). Appearances are in keeping with thrombosis and a diagnosis of Mondor's disease of the breast.

have reported underlying breast cancer in up to 12.7% of Mondor's disease cases [3,4]. Five patients in our study had a history of previously treated breast cancer (4 invasive and 1 lobular carcinoma in situ) and all had surgery, but this was at least a year ago or longer. In 4 of these cases the breast lesion was ipsilateral to the Mondor's presentation and in the remaining case, while the original cancer was on the contralateral side, the patient also had a risk reducing mastectomy on the side of the Mondor's disease. Interestingly, this patient was also on adjuvant tamoxifen at the time of presentation which is known to increase the risk of thrombotic events such as VTE [17]. The remaining 65% of patients in our study did not have any evident cause or risk factors for Mondor's disease.

Patients do not often present in the acute phase of Mondor's disease immediately after trauma. Instead, they present some weeks later when the signs of trauma and inflammation have resolved and only a palpable abnormality remains. By this time there has often been partial recanalisation of the thrombosed vein, so the classic palpable cord is no longer present. It is possible that during the Covid-19 lockdown, patients presented to their GP in the more acute phase of the disease possibly due to the fact they were not working and were able to attend appointments more readily or had more rapid access to telephone/video consultations. In addition, clinic appointment waiting times for Edinburgh Breast Services new patient referrals was only 1–2 weeks during this period, so patients were seen quickly and were thus more likely to be seen in the acute phase.

As this was a retrospective study, we only have limited data on recent or previous symptoms/diagnoses of Covid-19 from the patients in this study. A temperature check and verbal general wellbeing questionnaire was used on arrival to clinic and would have alerted staff to any patients with Covid-19 symptoms such as a new cough, shortness of breath or high temperature at that particular time. None of the patients in this study were pyrexial or had any of these symptoms in the week prior to their clinic visit. None of the patients in this study had received a Covid-19 vaccination by the time of their diagnosis of Mondor's disease.

We have continued to audit incidence of Mondor's disease of the breast, and we have again recorded a higher than expected number of cases in 2021. Interestingly, we noted a skew to older age of diagnosis of Mondor's disease in 2021 compared to 2020. We have also noted a number of cases where a diagnosis of Mondor's disease occurred shortly after receiving the Oxford/Astra Zeneca Covid-19 vaccine which has been reported to increase risk of thromboembolic events [21]. The main difference in 2021 compared to 2020 was the wide-spread roll-out of the Covid-19 vaccine programme, where younger individuals were preferentially given the Pfizer, and latterly the Moderna, vaccine in Scotland while older individuals were given the Oxford/Astra Zeneca vaccine. This may account for the skew to older age that we observed in 2021 data compared to 2020. The Pfizer and Moderna vaccines have not been widely reported to increase the risk of thromboembolic events but may have ameliorated the effects of Covid-19 thus accounting for the reduced incidence of Mondor's disease we recorded in this age group in 2021. We

continue to analyse the 2021 data, which will form the basis of a follow-on study. We chose to report only the 2020 data here as this is not impacted in anyway by the vaccine roll-out which did not start until 2021.

5. Conclusion

This is an observational study. There appears to be a link between the increase in the number of cases of Mondor's disease and the Covid-19 pandemic. No Covid-19 testing was performed but there was no evidence of current Covid-19 symptoms, although some patients may have been asymptomatic carriers. As we had no ethical approval or informed consent, testing patients was not considered appropriate. Other studies have suggested an association of Mondor's disease in other sites and Covid-19. It would be interesting to know if a similar surge in cases of Mondor's was observed in other breast units or associated specialities.

Mondor's disease is a self-limiting process, and the standard treatment strategy has not yet been established due to the paucity of clear evidence. Treatment is conservative and targeted at symptom relief. The condition usually resolves within 4–8 weeks. In our experience, the application of non-steroidal anti-inflammatory gel accelerates resolution. Anticoagulants are not usually recommended; however, some studies have reported the effectiveness of anticoagulation therapy in the acute phase of Mondor's disease [9].

We believe that this study provides the first evidence for Covid-19 as a likely etiopathogenetic risk factor for Mondor's disease of the breast and recommend that a Covid-19 history should be taken from patients presenting to breast clinics with signs and symptoms consistent with Mondor's disease.

Declaration of competing interest

The authors declare that they have no known competing financial interests or personal relationships that could have appeared to influence the work reported in this paper.

Acknowledgements

We would like to acknowledge the contribution of our colleagues Mr Dhananjay Kulkarni and Mr Oliver Young.

Appendix A. Supplementary data

Supplementary data to this article can be found online at <https://doi.org/10.1016/j.breast.2022.11.006>.

References

- [1] Agus, G. COVID-19 Era: Mondor's disease and Rembrandt. What ties?. *Veins and Lymphatics*. 9. 2020 10.4081/vl.2020.9107.

- [2] Stavros AT, Rapp CL, Parker SH. Breast ultrasound. Philadelphia, Pennsylvania: Lippincott Williams & Wilkins; 2004. p. 429–35.
- [3] Catania S, Zurrida S, Veronesi P, Galimberti V, Bono A, Pluchinotta A. Mondor's disease and breast cancer. May 1 *Cancer* 1992;69(9):2267–70. [https://doi.org/10.1002/1097-0142\(19920501\)69:9<2267::aid-cnrcr2820690910>3.0.co;2-u](https://doi.org/10.1002/1097-0142(19920501)69:9<2267::aid-cnrcr2820690910>3.0.co;2-u). PMID: 1562972.
- [4] Ben Hamida K, Ghaleb M, Triki A, Jebir I, Makhlouf R, Touinsi H. Mondor's disease of the breast: a case series. Apr 2 *J Med Case Rep* 2021;15(1):188. <https://doi.org/10.1186/s13256-021-02708-6>. PMID: 33810810; PMCID: PMC8019160.
- [5] Salemis NS, Vasilara G, Lagoudianakis E. Mondor's disease of the breast as a complication of ultrasound-guided core needle biopsy: management and review of the literature. *Breast Dis* 2015;35(1):73–6. <https://doi.org/10.3233/BD-140374>. PMID: 24989360.
- [6] Klok FA, Kruip MJHA, van der Meer NJM, Arbous MS, Gommers DAMPJ, Kant KM, Kaptein FHJ, van Paassen J, Stals MAM, Huisman MV, Endeman H. Incidence of thrombotic complications in critically ill ICU patients with COVID-19. *Jul Thromb Res* 2020;191:145–7. <https://doi.org/10.1016/j.thromres.2020.04.013>. Epub 2020 Apr 10. PMID: 32291094; PMCID: PMC7146714.
- [7] Yanik B, Conkbayir I, Oner O, Hekimoğlu B. Imaging findings in Mondor's disease. *Feb J Clin Ultrasound* 2003;31(2):103–7. <https://doi.org/10.1002/jcu.10134>. PMID: 12539252.
- [8] Amano M, Shimizu T. Mondor's disease: a review of the literature. *Sep. 15 Intern Med* 2018;57(18):2607–12. <https://doi.org/10.2169/internalmedicine.0495-17>. Epub 2018 May 18. PMID: 29780120; PMCID: PMC6191595.
- [9] Belleflamme M, Penaloza A, Thoma M, Hainaut P, Thys F. Mondor disease: a case report in ED. *Sep Am J Emerg Med* 2012;30(7):1325.e1–3. <https://doi.org/10.1016/j.ajem.2011.06.031>. Epub 2011 Aug 19. PMID: 21855258.
- [10] Balawender K, Pliszka A, Surowiec A, Rajda S. COVID-19 infection as a new risk factor for penile Mondor disease. *Apr 12 BMC Urol* 2022;22(1):57. <https://doi.org/10.1186/s12894-022-01002-x>. PMID: 35413893; PMCID: PMC9005161.
- [11] Schulman S, Hu Y, Konstantinides S. Venous thromboembolism in COVID-19. *Dec Thromb Haemostasis* 2020;120(12):1642–53. <https://doi.org/10.1055/s-0040-1718532>. Epub 2020 Oct 24. PMID: 33099284; PMCID: PMC7869046.
- [12] Dobesh PP, Trujillo TC. Coagulopathy, venous thromboembolism, and anticoagulation in patients with COVID-19. *Nov Pharmacotherapy* 2020;40(11): 1130–51. <https://doi.org/10.1002/phar.2465>. Epub 2020 Nov 3. PMID: 33006163; PMCID: PMC7537066.
- [13] Ali MAM, Spinler SA. COVID-19 and thrombosis: from bench to bedside. *Apr Trends Cardiovasc Med* 2021;31(3):143–60. <https://doi.org/10.1016/j.tcm.2020.12.004>. Epub 2020 Dec 16. PMID: 33338635; PMCID: PMC7836332.
- [14] Kyriakoulis KG, Kokkinidis DG, Kyprianou IA, Papanastasiou CA, Archontakis-Barakakis P, Doundoulakis I, Bakoyiannis C, Giannakoulas G, Palaiodimos L. Venous thromboembolism in the era of COVID-19. *Mar Phlebology* 2021;36(2): 91–9. <https://doi.org/10.1177/0268355520955083>. Epub 2020 Sep 10. PMID: 33249999.
- [15] Fabiani A, Filosa A, Maglia D, Principi E, Stramucci S. COVID-19 vaccination and penile Mondor disease. There is any relationship?. *Mar 30 Arch Ital Urol Androl* 2022;94(1):121–2. <https://doi.org/10.4081/aiua.2022.1.121>. PMID: 35352537.
- [16] Lessiani G, Boccattoda A, D'Ardes D, Cocco G, Di Marco G, Schiavone C. Mondor's disease in SARS-CoV-2 infection: a case of superficial vein thrombosis in the era of COVID-19. *Sep. 1 Eur J Case Rep Intern Med* 2020;7(10):001803. <https://doi.org/10.12890/2020.001803>. PMID: 33083359; PMCID: PMC7546552.
- [17] Nevasaari K, Heikkinen M, Taskinen PJ. Tamoxifen and thrombosis. *Oct 28 Lancet* 1978;2(8096):946–7. [https://doi.org/10.1016/s0140-6736\(78\)91668-9](https://doi.org/10.1016/s0140-6736(78)91668-9). PMID: 81964.
- [18] Wang C, Yu C, Jing H, Wu X, Novakovic VA, Xie R, Shi J. Long COVID: the nature of thrombotic sequelae determines the necessity of early anticoagulation. *Apr 5 Front Cell Infect Microbiol* 2022;12:861703. <https://doi.org/10.3389/fcimb.2022.861703>. PMID: 35449732; PMCID: PMC9016198.
- [19] Kumar MA, Krishnaswamy M. Arul JNPost COVID-19 sequelae: venous thromboembolism complicated by lower GI bleedBMJ Case Reports. *CP* 2021;14: e241059.
- [20] Oran DP, Topol EJ. The proportion of SARS-CoV-2 infections that are asymptomatic : a systematic review. *Ann Intern Med* 2021 May;174(5):655–62. <https://doi.org/10.7326/M20-6976>. Epub 2021 Jan 22. PMID: 33481642; PMCID: PMC7839426.
- [21] Franchini M, Liunbruno GM, Pezzo M. COVID-19 vaccine-associated immune thrombosis and thrombocytopenia (VITT): diagnostic and therapeutic recommendations for a new syndrome. *Aug Eur J Haematol* 2021;107(2):173–80. <https://doi.org/10.1111/ejh.13665>. Epub 2021 Jun 9. PMID: 33987882; PMCID: PMC8239516.