

# Photodynamic therapy for the successful management of cyclosporine-related gum hypertrophy: A novel therapeutic option

Journal of Public Health Research  
2022, Vol. 11(4), 1–6  
© The Author(s) 2022  
DOI: 10.1177/22799036221116177  
journals.sagepub.com/home/phj  


Cinzia Casu<sup>1,2</sup> , Martina Salvatorina Murgia<sup>2</sup> ,  
Germano Orrù<sup>2</sup>  and Alessandra Scano 

## Abstract

**Background:** Drug-induced gingival overgrowth is associated with the intake of three classes of drugs: anticonvulsants, immunosuppressants, and calcium channel blockers. It is clinically characterized by hyperplasia of the gingival connective tissue which appears edematous, bloody, and purplish-red in color. In more severe cases, drug-induced gingival hyperplasia negatively affects the patient's quality of life, making it difficult to eat and practice good oral hygiene. Drug-induced gingival overgrowth therapy is controversial and, in fact, no studies in the literature highlight a well-defined therapeutic protocol. The therapies that are described provide primarily for non-surgical periodontal treatment and second-line surgical treatment. The aim of this work is to highlight a case of drug-induced gingival hyperplasia which was completely resolved thanks to photodynamic therapy which is completely free from side effects.

**Design and Methods:** Photodynamic therapy was performed on an 18 year-old female patient with LEDs at a power of 450–470 nm and 5500 mW/cm<sup>2</sup> + 7500 mW/cm<sup>2</sup>, combined with a *Curcuma longa*-based photosensitizer. A single session was performed, with applications of approximately 30 s for each interdental papilla.

**Results:** The patient improved markedly after only one cycle of PDT. There was an absence of clinically detectable inflammation, edema, and rubor of the involved dental papillae. At the 4, 6, and 12 week follow-ups there were no recurrences.

**Conclusions:** This case report highlights the first case of drug-induced gingival hypertrophy entirely treated with photodynamic therapy to be described in the literature. Therefore, although it is only a case report, this therapy which is free from side effects should be investigated as an alternative to current therapies.

## Keywords

Cyclosporin, drug-induced gingival overgrowth, light-emitting diode, photodynamic therapy

Date received: 12 July 2022; accepted: 9 July 2022

## Introduction

Drug-induced gingival overgrowth (DIGO) is a well-known clinical condition. DIGO is clinically characterized by hyperplasia of the gingival connective tissue which appears edematous, bloody, and purplish-red in color.<sup>1</sup> Furthermore, the most commonly affected site is keratinized mucosa on the maxillary and anterior mandibular vestibular sides.<sup>1</sup> In severe cases, DIGO can cover the entire surface of the teeth compromising chewing, occlusion and esthetics, as well as adequate maintenance of oral hygiene practices.<sup>2,3</sup> The literature shows that three types of drugs are mainly associated with DIGO:

- anticonvulsants (phenytoin);
- immunosuppressants (cyclosporine A);
- calcium channel blockers (Nifedipine, Verapamil, diltiazem).<sup>4</sup>

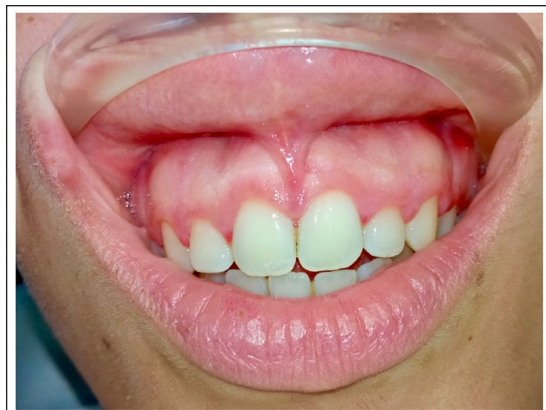<sup>1</sup>International Ph.D. in Innovation Sciences and Technologies, University of Cagliari, Cagliari, Italy

<sup>2</sup>Department of Surgical Science, Oral Biotechnology Laboratory, University of Cagliari, Cagliari, Italy

### Corresponding author:

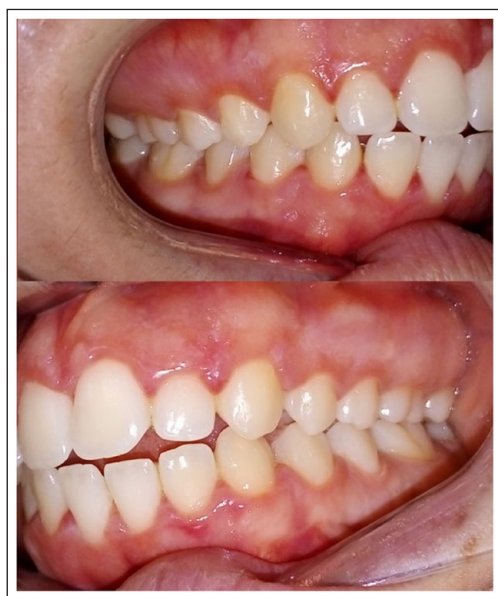Cinzia Casu, International Ph.D. in Innovation Sciences and Technologies, University of Cagliari, Cagliari, Italy, Cagliari 09124  
Emails: ginzia.85@hotmail.it; cinzia.casu2@unica.it



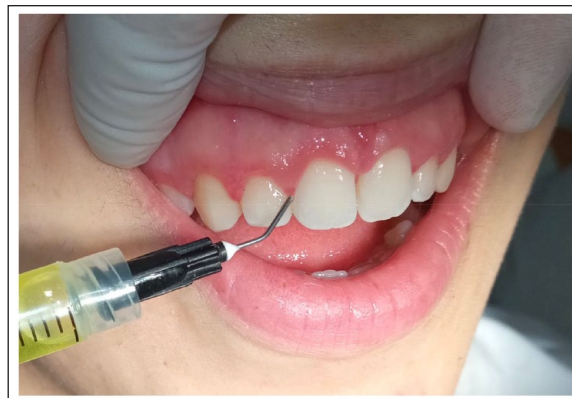

**Figure 1.** Initial clinical condition of the patient in frontal view.

In particular, cyclosporine induced gingival overgrowth affects 25%–81% of patients and usually occurs within 6 months of starting treatment.<sup>5,6</sup> Another problem is the high recurrence rate of this condition.<sup>6</sup> Although numerous studies have been performed, the etiopathogenetic mechanisms underlying drug-induced gingival hyperplasia are still unclear.<sup>7</sup> Some studies have shown an increase in the proliferation of gingival fibroblasts and keratinocytes, an over-regulation of some salivary inflammatory cytokines including interleukin (IL) -1 $\alpha$ , IL-6, and IL-8, and an increase in cellular apoptotic processes.<sup>1,5</sup> Furthermore, chronic irritative factors including tartar and dental plaque are determinants in the most severe and massive pictures of drug-induced gingival hyperplasia.<sup>8</sup> DIGO therapy is controversial and, in fact, there are no studies in the literature that highlight a well-defined therapeutic protocol. In

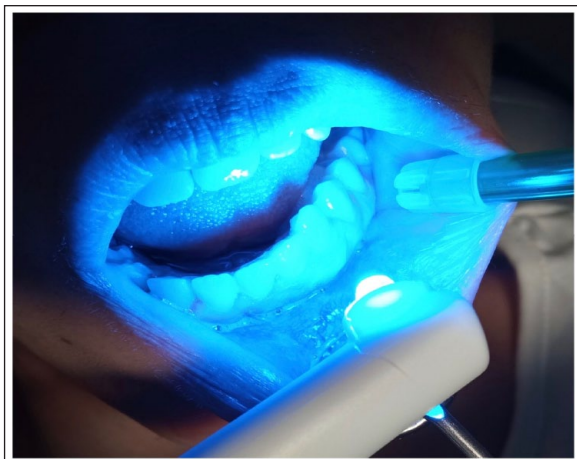


**Figure 2.** Initial clinical condition of the patient in lateral view.



**Figure 3.** Application of the photosensitizer.

some cases, it may be useful to suspend the drug and replace it, with all the complications that may arise.<sup>8</sup> In the literature, numerous studies have shown that scaling and root planing have given good results.<sup>9–11</sup> The rationale behind this therapy is the reduction in inflammation and the mechanical removal of plaque and tartar.<sup>12</sup> Often, when non-surgical periodontal therapy does not lead to an effective reduction in DIGO, surgical treatment follows, that is, the removal of the hyperplastic gingiva with a cold or electric scalpel.<sup>13,14</sup> Unfortunately, such treatments are not well tolerated by patients because of the adverse effects such as local bleeding, surgery times, post-operative pain, infectious complications, and adherence to a liquid and cold diet in the following weeks.<sup>15,16</sup> It would therefore be interesting to evaluate the clinical efficacy of other unconventional therapies. The light-emitting diode (LED) was developed in 1962 by an American electrical engineer called Nick Holonyak JR. It is a special type of diode capable of emitting a small amount of light when passed through an electric current. Starting from this technological innovation, researchers have been able to develop LEDs with different wavelengths and with a photon density clinically useful for the treatment of an extended area of the target tissue. They are also characterized by high reliability, long life, high efficiency, and low consumption. The use of LEDs at certain wavelengths allows the activation of specific photosensitizers, which is known as photodynamic therapy (PDT). Today, technology has led us to have increasingly high-performance and small-sized LED lamps with tips specifically designed to work in limited environments such as those within the oral cavity.<sup>17</sup> There are many fields of application of PDT in dentistry,<sup>18</sup> for example, in the treatment of periodontitis,<sup>19</sup> Herpes simplex infections,<sup>20,21</sup> oral lichen planus,<sup>22,23</sup> leukoplakia,<sup>24,25</sup> as well as squamous cell carcinoma.<sup>26</sup> The aim of this work is thus to illustrate a case of drug-induced hyperplasia healing in a patient with rheumatoid arthritis by means of PDT.



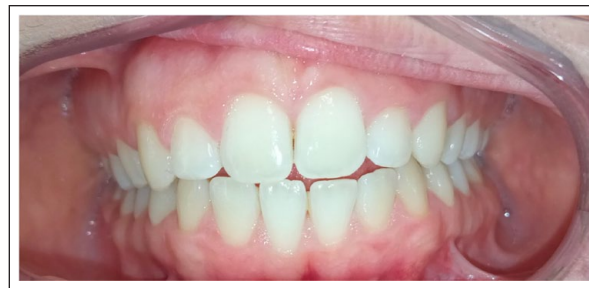**Figure 4.** Activation of the light.

## Design and methods

An 18-year-old patient suffering from gingival swelling was brought to our attention (Figures 1 and 2). She had been suffering for 5 months from increasing gingival enlargement in maxillary and mandibular teeth and also gingival bleeding while brushing her teeth or eating. She had a history of rheumatoid arthritis localized in her left knee, which had been treated with oral cyclosporine (10 mg once daily) for the past 5 years. The patient also has good control of home oral hygiene. It was decided to try treatment with PDT with the aim of reducing inflammation and the bacterial load on the sites involved. PDT was performed with LED at a power of 450–470 nm and 5500 mW/cm<sup>2</sup> + 7500 mW/cm<sup>2</sup> (lumina max lad, Dentalica, Italy), combined with a *Curcuma longa*-based photosensitizer (Figure 3). A single session was performed, with applications of about 30 s for each interdental papilla between 1.3 and 2.3, and between 3.3 and 4.3 (Figure 4) after the introduction of the photosensitizer (both in the pocket and on the vestibular side of the papillae). The latter consisted of 3% H<sub>2</sub>O<sub>2</sub> + *Curcuma longa* powder, mixed with distilled water to reach a volume of 1.5 ml. The product was shaken and used after a few minutes, sprinkling the sites to be treated. The light was emitted by a long blunt 8 mm tip and then activated at a distance of 0.5 cm from the lesion. At the end of the application, the dye was removed with the aid of a sterile gauze and physiological solution.

## Results

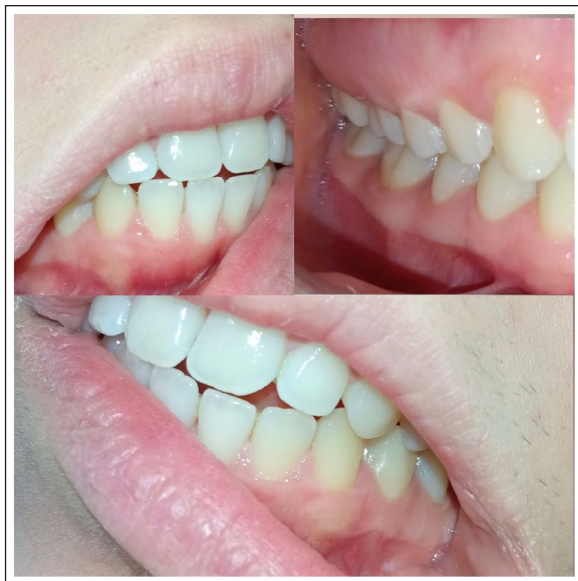The patient improved markedly after only one cycle of PDT. There was an absence of clinically-detectable inflammation, edema, and rubor of the involved dental papillae (Figures 5 and 6). At the 4, 6, and 12 week follow-ups there were no recurrences. A noteworthy aspect is that the patient was not subjected to any oral hygiene practices in the outpatient setting and therefore the therapeutic effects are entirely attributable to PDT.



**Figure 5.** Clinical condition after photodynamic therapy in frontal view.

## Discussion

PDT is an unconventional therapy used in numerous branches of medicine.<sup>27</sup> PDT's mechanism of action is based on the application of a photosensitive compound called photosensitizer which has a high affinity for damaged or infected cells. The photosensitizer absorbs light at a certain wavelength, activating itself, and leading to the selective elimination of damaged cells.<sup>28</sup> In fact, during this phase, reaction processes take place involving molecular oxygen with the consequent formation of reactive oxygen species (ROS) capable of stimulating the cell death circuits of microorganisms and infected cells.<sup>29</sup> The great advantage of PDT is that the photosensitizer only accumulates in damaged tissues, resulting in selective destruction.<sup>30</sup> The causes of the high affinity to damaged tissues could be justified by the high affinity of the photosensitizer to low density lipoproteins (LDL). These have the role of providing the cholesterol necessary to build cell membranes during cell division.<sup>31</sup> Clinically, this affinity translates into a complete absence of PDT side effects.<sup>32,33</sup> In addition, PDT is painless, extremely practical, repeatable and simple to perform, making it particularly suitable for outpatient clinical practice. In fact, these properties are the reason why PDT is widely used in oral medicine and dentistry,<sup>34–40</sup> but the search for new PTs effective against the most common oral pathologies remains however worthy of note. The photosensitizer used in this case report was curcumin. In particular, curcumin, extracted from the rhizomes of the *Curcuma longa* plant, is emerging in the literature on account of its anti-inflammatory, antibacterial, antiviral, and anticancer properties.<sup>41–43</sup> Furthermore, numerous studies in the literature have highlighted the immunomodulating properties of curcumin in patients with HIV, Alzheimer's disease, and multiple sclerosis.<sup>44–50</sup> A key property for its use as a photosensitizer is that the light absorption peak of curcumin is around 400–500 nm.<sup>51</sup> The uniqueness of this study is the lack of any studies on the application of PDT in the treatment of DIGOs. In fact, only one work in the literature used PDT with a diode laser (810 nm) only after having performed Er: YAG laser-assisted gingivectomy & gingivoplasty (2940 nm).<sup>52</sup> Based



**Figure 6.** Clinical condition after photodynamic therapy in lateral view.

on the evidence available from RCTs and recent meta-analyses, a very recent narrative review by Sculean et al. found that the combination of scaling and root planing and PDT in patients with mild to moderate periodontitis can lead to clinical improvements that are significantly greater than root planning alone in non-surgical treatment. In cases of stage III and grade IV periodontitis, PDT provides clinical improvements, although PDT cannot be replaced with systemic antibiotic therapy (based on amoxicillin and metronidazole). Furthermore, it is noted that PDT may be indicated as a useful tool for the treatment of moderate residual periodontal pockets during maintenance therapy.<sup>53</sup> In particular, Sreedhar et al. also demonstrated that photodynamic therapy with curcumin has been shown to be useful as an adjunct to non-surgical periodontal therapy. Furthermore, multiple cycles of PDT are more beneficial for the improvement of clinical and microbiological parameters than a single application.<sup>54</sup> It is important to emphasize that rheumatoid arthritis is an autoimmune disease that has long been associated with periodontal disease and recent studies on the oral microbiome have highlighted its role in arthritis.<sup>55-57</sup> An association was clearly demonstrated between the abundance of oral *Porphyromonas gingivalis* in patients with rheumatoid arthritis compared to healthy controls.<sup>58</sup> The study by Mahdi et al. found that PDT using only/just curcumin, hydrogen peroxide, and erythrosine as photosensitizers exerted a moderate bactericidal effect on *P. gingivalis* which greatly improved in conjugation with visible light.<sup>59</sup> The survival rate of *P. gingivalis* reached zero percent when the suspension was exposed to blue-light-activated curcumin and hydrogen peroxide for 2 min. Furthermore, curcumin exerted a notable antibacterial activity against *F. nucleatum*

compared to erythrosine and hydrogen peroxide ( $p=0.00$ ). Therefore, in this specific case, PDT with curcumin could have also determined significant therapeutic effects on the systemic pathology. Therefore, although this is only a case report, with all the limitations present, it is important not to underestimate PDT with curcumin in the treatment of DIGOs precisely because of the results obtained and the absence of comorbidities and side effects that would have been obtained by changing the drug.

### Acknowledgements

One of the authors, C. C. performed their activity in the framework of the International Ph.D. in Innovation Sciences and Technologies at the University of Cagliari, Italy.

### Contributions

CC, MSM, GO conceptualization, data collection, data analysis, manuscript writing, editing. All authors made a substantive intellectual contribution, read and approved the final version of the manuscript and agreed to be accountable for all aspects of the work.

### Declaration of conflicting interests

The author(s) declared no potential conflicts of interest with respect to the research, authorship, and/or publication of this article.

### Funding

The author(s) received no financial support for the research, authorship, and/or publication of this article.

### Ethics approval and consent to participate

The study was conducted according to the guidelines of the Declaration of Helsinki. The work is an observational study carried out during routine clinical practice and did not regard uncodified therapeutic protocols from European law. The subject's privacy and confidentiality were never compromised in this study.

### Patient consent for publication

Informed written consent was obtained from the subject and from the parents of the subject involved in this study.

### Informed consent

Written informed consent was obtained from a legally authorized representative(s) for anonymized patient information to be published in this article.

### Significance for Public Health

This case report highlights the first case of drug-induced gingival hypertrophy entirely treated with photodynamic therapy to be described in the literature. This type of therapy does not foresee any type of complications or adverse outcome. Furthermore, it avoids the pharmacological changes that are associated with drug therapy which are often destabilizing for the patient. Another


fundamental aspect is the absence of any plaque removal therapy which would have affected the results obtained. Therefore, although this is only a case report, it deserves further investigation because it could lead to positive outcomes in the treatment of this condition which would enormously influence the quality of life of affected patients.

### ORCID iDs

Cinzia Casu  <https://orcid.org/0000-0002-7962-2712>

Martina Salvatorina Murgia  <https://orcid.org/0000-0002-0504-098X>

Germano Orrù  <https://orcid.org/0000-0003-1032-4431>

Alessandra Scano  <https://orcid.org/0000-0001-7241-9001>

### Availability of data and materials

All data generated or analyzed during this study are included in this published article.

### References

- Kumar S, Guliani A and Vinay K. Cyclosporine-induced gingival hypertrophy. *JAMA Dermatol* 2019; 155(4): 487.
- Tyldesley WR and Rotter E. Gingival hyperplasia induced by cyclosporin-A. *Br Dent J* 1984; 157(9): 305–309.
- Bader G, Lejeune S and Messner M. Reduction of cyclosporine-induced gingival overgrowth following a change to tacrolimus. A case history involving a liver transplant patient. *J Periodontol* 1998; 69(6): 729–732.
- Agrawal AA. Gingival enlargements: differential diagnosis and review of literature. *World J Clin Cases* 2015; 3(9): 779–788.
- Ponnaiyan D and Jegadeesan V. Cyclosporine A: novel concepts in its role in drug-induced gingival overgrowth. *Dent Res J* 2015; 12(6): 499–506.
- Seymour RA and Jacobs DJ. Cyclosporin and the gingival tissues. *J Clin Periodontol* 1992; 19(1): 1–11.
- Guo J, Wang W, Yao L, et al. Local inflammation exacerbates cyclosporine a-induced gingival overgrowth in rats. *Inflammation* 2008; 31(6): 399–407.
- Mohan RP, Rastogi K, Bhushan R, et al. Phenytoin-induced gingival enlargement: a dental awakening for patients with epilepsy. *BMJ Case Rep* 2013; 2013: bcr2013008679.
- Pundir AJ, Pundir S, Yeltiwar RK, et al. Treatment of drug-induced gingival overgrowth by full-mouth disinfection: a non-surgical approach. *J Indian Soc Periodontol* 2014; 18(3): 311–315.
- Quirynen M, De Soete M, Boschmans G, et al. Benefit of “one-stage full-mouth disinfection” is explained by disinfection and root planing within 24 hours: a randomized controlled trial. *J Clin Periodontol* 2006; 33(9): 639–647.
- Castronovo G, Liani G, Fedon A, et al. The effect of nonsurgical periodontal treatment on the severity of drug-induced gingival overgrowth in transplant patients. *Quintessence Int* 2014; 45(2): 115–124.
- Somacarrera ML, Lucas M, Scully C, et al. Effectiveness of periodontal treatments on cyclosporine-induced gingival overgrowth in transplant patients. *Br Dent J* 1997; 183(3): 89–94.
- Mavrogiannis M, Ellis JS, Thomason JM, et al. The management of drug-induced gingival overgrowth. *J Clin Periodontol* 2006; 33(6): 434–439.
- Muralikrishna T, Kalakonda B, Gunupati S, et al. Laser-assisted periodontal management of drug-induced gingival overgrowth under general anesthesia: a viable option. *Case Rep Dent* 2013; 2013: 387453.
- Campos L, Gallottini M, Pallos D, et al. High-power diode laser on management of drug-induced gingival overgrowth: report of two cases and long-term follow-up. *J Cosmet Laser Ther* 2018; 20(4): 215–219.
- Srivastava AK, Kundu D, Bandyopadhyay P, et al. Management of amlodipine-induced gingival enlargement: series of three cases. *J Indian Soc Periodontol* 2010; 14(4): 279–281.
- Zecha JA, Raber-Durlacher JE, Nair RG, et al. Low-level laser therapy/photobiomodulation in the management of side effects of chemoradiation therapy in head and neck cancer: part 2: proposed applications and treatment protocols. *Support Care Cancer* 2016; 24(6): 2793–2805.
- Pražmo EJ, Kwaśny M, Łapiński M, et al. Photodynamic therapy as a promising method used in the treatment of oral diseases. *Adv Clin Exp Med* 2016; 25(4): 799–807.
- Joseph B, Janam P, Narayanan S, et al. Is antimicrobial photodynamic therapy effective as an adjunct to scaling and root planing in patients with chronic periodontitis? A systematic review. *Biomolecules* 2017; 7(4): 79.
- La Selva A, Negreiros RM, Bezerra DT, et al. Treatment of herpes labialis by photodynamic therapy: study protocol clinical trial (SPIRIT compliant). *Medicine* 2020; 99(12): e19500.
- Lago ADN, Fortes ABC, Furtado GS, et al. Association of antimicrobial photodynamic therapy and photobiomodulation for herpes simplex labialis resolution: case series. *Photodiagnosis Photodyn Ther* 2020; 32: 102070.
- Hesse J, Schmalzfuss A and Kvaal SI. Photodynamic therapy of oral lichen planus. *Photochem Photobiol Sci* 2020; 19(10): 1271–1279.
- Mostafa D and Tarakji B. Photodynamic therapy in treatment of oral lichen planus. *J Clin Med Res* 2015; 7(6): 393–399.
- Chen Q, Dan H, Tang F, et al. Photodynamic therapy guidelines for the management of oral leucoplakia. *Int J Oral Sci* 2019; 11(2): 14.
- Li Y, Wang B, Zheng S, et al. Photodynamic therapy in the treatment of oral leukoplakia: a systematic review. *Photodiagnosis Photodyn Ther* 2019; 25: 17–22.
- Keyal U, Bhatta AK, Zhang G, et al. Present and future perspectives of photodynamic therapy for cutaneous squamous cell carcinoma. *J Am Acad Dermatol* 2019; 80(3): 765–773.
- Luo D, Carter KA, Miranda D, et al. Chemophototherapy: an emerging treatment option for solid tumors. *Adv Sci* 2017; 4(1): 1600106.
- Kwiatkowski S, Knap B, Przystupski D, et al. Photodynamic therapy - mechanisms, photosensitizers and combinations. *Biomed Pharmacother* 2018; 106: 1098–1107.
- Luksiene Z. Photodynamic therapy: mechanism of action and ways to improve the efficiency of treatment. *Medicina* 2003; 39(12): 1137–1150.

30. Vrouenraets MB, Visser GW, Snow GB, et al. Basic principles, applications in oncology and improved selectivity of photodynamic therapy. *Anticancer Res* 2003; 23(1B): 505–522.
31. Cruz PMR, Mo H, McConathy WJ, et al. The role of cholesterol metabolism and cholesterol transport in carcinogenesis: a review of scientific findings, relevant to future cancer therapeutics. *Front Pharmacol* 2013; 4: 119.
32. Lopez MA, Passarelli PC, Marra M, et al. Photodynamic therapy (PDT) in non-surgical treatment of periodontitis. *J Biol Regul Homeost Agents* 2020; 34(5 Suppl. 3): 67–78.
33. Meisel P and Kocher T. Photodynamic therapy for periodontal diseases: state of the art. *J Photochem Photobiol B* 2005; 79(2): 159–170.
34. Casu C and Nosotti MG. Photodynamic therapy for halitosis: could be possible? *Biointerface Res Appl Chem* 2021; 11: 7493–7500.
35. Casu C and Mannu C. Atypical afta major healing after photodynamic therapy. *Case Rep Dent* 2017; 2017: 8517470.
36. Tionardus M and Setiawatie EM. Photosensitizer in periodontal antimicrobial photodynamic therapy: a literature review. *AIP Conf Proc* 2020; 2314(1): 060017.
37. Javed F. Halitosis and photodynamic therapy. *Photodiagnosis Photodyn Ther* 2020; 32: 102006.
38. Plotino G, Grande NM and Mercade M. Photodynamic therapy in endodontics. *Int Endod J* 2019; 52(6): 760–774.
39. Albaker AM, ArRejaie AS, Alrabiah M, et al. Effect of photodynamic and laser therapy in the treatment of peri-implant mucositis: a systematic review. *Photodiagnosis Photodyn Ther* 2018; 21: 147–152.
40. Murgia MS, Orrù G, Loddo M, et al. International conference on infectious diseases oral HSV infections: molecular biology and photodynamic therapy as new diagnostic and therapeutic tools. *J Infect Non Infect Dis* 2020; 1: 23.
41. Menon VP and Sudheer AR. Antioxidant and anti-inflammatory properties of curcumin. *Adv Exp Med Biol* 2007; 595: 105–125.
42. Noorafshan A and Ashkani-Esfahani S. A review of therapeutic effects of curcumin. *Curr Pharm Des* 2013; 19(11): 2032–2046.
43. Schiborr C, Kocher A, Behnam D, et al. The oral bioavailability of curcumin from micronized powder and liquid micelles is significantly increased in healthy humans and differs between sexes. *Mol Nutr Food Res* 2014; 58(3): 516–527.
44. Kulkarni AP, Murthy KH and Kotwal GJ. Study of interaction of curcumin, a potential anti-neuroinflammatory agent, with C3 and C3b using QCM-D technology. *Mol Immunol* 2007; 44: 200–201.
45. Prasad S and Tyagi AK. Curcumin and its analogues: a potential natural compound against HIV infection and AIDS. *Food Funct* 2015; 6(11): 3412–3419.
46. Kumari N, Kulkarni AA, Lin X, et al. Inhibition of HIV-1 by curcumin A, a novel curcumin analog. *Drug Des Devel Ther* 2015; 9: 5051–5060.
47. Sharma A, Yadav A, Gupta N, et al. Multifunctional mesoporous curcumin encapsulated iron-phenanthroline nanocluster: a new Anti-HIV agent. *Colloids Surf B Biointerfaces* 2019; 180: 289–297.
48. Ghanaatian N, Lashgari NA, Abdolghaffari AH, et al. Curcumin as a therapeutic candidate for multiple sclerosis: molecular mechanisms and targets. *J Cell Physiol* 2019; 234(8): 12237–12248.
49. Yang M, Akbar U and Mohan C. Curcumin in autoimmune and rheumatic diseases. *Nutrients* 2019; 11(5): 1004.
50. Chainoglou E and Hadjipavlou-Litina D. Curcumin in Health and diseases: Alzheimer's disease and Curcumin analogues, derivatives, and hybrids. *Int J Mol Sci* 2020; 21(6): 1975.
51. Araújo NC, Fontana CR, Bagnato VS, et al. Photodynamic antimicrobial therapy of curcumin in biofilms and carious dentine. *Lasers Med Sci* 2014; 29(2): 629–635.
52. Ke J and Tomov G. 2-combined laser-assisted therapies of drug-induced gingival hyperplasia. In: *Laser in periodontics*, 2019, pp.11–16.
53. Sculean A, Deppe H, Miron R, et al. Effectiveness of photodynamic therapy in the treatment of periodontal and peri-implant diseases. *Monogr Oral Sci* 2021; 29: 133–143.
54. Sreedhar A, Sarkar I, Rajan P, et al. Comparative evaluation of the efficacy of curcumin gel with and without photo activation as an adjunct to scaling and root planing in the treatment of chronic periodontitis: a split mouth clinical and microbiological study. *J Nat Sci Biol Med* 2015; 6(Suppl 1): S102–S109.
55. Ogrendik M. Rheumatoid arthritis is linked to oral bacteria: etiological association. *Mod Rheumatol* 2009; 19(5): 453–456.
56. Cheng Z, Meade J, Mankia K, et al. Periodontal disease and periodontal bacteria as triggers for rheumatoid arthritis. *Best Pract Res Clin Rheumatol* 2017; 31(1): 19–30.
57. Lee YH, Lew PH, Cheah CW, et al. Potential mechanisms linking periodontitis to rheumatoid arthritis. *J Int Acad Periodontol* 2019; 21(3): 99–110.
58. Ceccarelli F, Orrù G, Pilloni A, et al. Porphyromonas gingivalis in the tongue biofilm is associated with clinical outcome in rheumatoid arthritis patients. *Clin Exp Immunol* 2018; 194(2): 244–252.
59. Mahdi Z, Habiboallh G, Mahbobeh NN, Mina ZJ, Majid Z, Nooshin A. Lethal effect of blue light-activated hydrogen peroxide, curcumin and erythrosine as potential oral photosensitizers on the viability of Porphyromonas gingivalis and Fusobacterium nucleatum. *Laser Ther.* 2015 Mar 31;24(2):103-111.