

New perspectives on the treatment of hidradenitis suppurativa

Victoria Amat-Samaranch, Eugènia Agut-Busquet, Eva Vilarrasa and Lluís Puig 

Ther Adv Chronic Dis

2021, Vol. 12: 1–34

DOI: 10.1177/
20406223211055920

© The Author(s), 2021.
Article reuse guidelines:
[sagepub.com/journals-
permissions](https://sagepub.com/journals-permissions)

Abstract: Hidradenitis suppurativa (HS) is a chronic inflammatory skin disease characterized by the presence of painful nodules, abscesses, chronically draining fistulas, and scarring in apocrine gland-bearing areas of the body. The exact pathogenesis of HS is not yet well understood, but there is a consensus in considering HS a multifactorial disease with a genetic predisposition, an inflammatory dysregulation, and an influence of environmental modifying factors. Therapeutic approach of HS is challenging due to the wide clinical manifestations of the disease and the complex pathogenesis. This review describes evidence for effectiveness of current and emerging HS therapies. Topical therapy, systemic treatments, biological agents, surgery, and light therapy have been used for HS with variable results. Adalimumab is the only US Food and Drug Administration (FDA) approved biologic agent for moderate-to-severe HS, but new therapeutic options are being studied, targeting different specific cytokines involved in HS pathogenesis. Comparing treatment outcomes between therapies is difficult due to the lack of randomized controlled trials. Treatment strategy should be selected in concordance to disease severity and requires combination of treatments in most cases.

Keywords: acne inversa, anti-IL-17, anti-TNF-alpha, biologics, hidradenitis suppurativa, small molecules, therapies

Received: 12 May 2021; revised manuscript accepted: 8 October 2021

Introduction

Hidradenitis suppurativa (HS) is a chronic, relapsing, inflammatory skin disease characterized by the inflammation of hair follicles in apocrine gland-bearing areas of the body, manifesting as painful nodules, abscesses, chronically draining fistulas, and scarring.^{1,2} It is a disabling disease with great psychological and functional impact on patients due to pain and malodorous discharge of the lesions. Prevalence estimates vary depending on the method of data collection and ethnic background, but range between 0.7% and 1.2%, according to the largest cross-sectional and registry-based studies;³ in most patients, onset of HS takes place after puberty, and the disease predominantly affects women in Western countries.⁴

Due to the polymorphic nature of HS manifestations and patient characteristics, several attempts at phenotypic classification have been published;

in a recent two-step cluster analysis of Mediterranean patients that included biomarkers, two endotypic clusters have been identified: cluster 1 (65% of patients) is characterized by non-obese males with early onset HS, nodular lesions in posterior sites, history of pilonidal sinus, high serum levels of IL-10, and presence of gamma-secretase mutations; and cluster 2 (35% of patients), characterized by obese females or males with later onset HS, lesions in anterior sites, more sinuses and abscesses, less nodules, and higher serum concentrations of IL-1, C-reactive protein, IL-17, and IL-6, which is more related to systemic inflammation.⁵

The pathogenesis of HS is not yet well understood, but there is a consensus in considering HS a multifactorial disease with implication of different immunological factors.^{6–8} This makes HS a complex disease with a challenging approach.⁹

Correspondence to:

Lluís Puig
Department of
Dermatology, Hospital de
la Santa Creu i Sant Pau,
Universitat Autònoma de
Barcelona, Mas Casanovas
90, 08041 Barcelona,
Spain.
lpuig@santpau.cat

Victoria Amat-Samaranch
Eugènia Agut-Busquet
Eva Vilarrasa
Department of
Dermatology, Hospital de
la Santa Creu i Sant Pau,
Universitat Autònoma de
Barcelona, Mas Casanovas
90, 08041, Barcelona,
Spain



Table 1. Hurley score.

Hurley score	
Hurley I	Single or multiple isolated nodules and abscesses without sinus tracts or scarring
Hurley II	Recurrent abscesses with ≥ 1 sinus tracts and scarring, separated by normal skin
Hurley III	Multiple lesions coalescing into inflammatory plaques, with extensive sinuses and scarring involving the entire region
Refined Hurley score	
Absence of sinus tracts	Hurley I A: ≤ 2 involved areas and < 5 abscesses or nodules B: > 2 body areas or ≥ 5 abscesses or nodules – predominantly fixed lesions C: > 2 body areas or ≥ 5 abscesses or nodules – migratory lesions
Presence of sinus tracts	Hurley II A: $< 1\%$ of BSA, without abscesses or nodules B: $< 1\%$ of BSA, with ≤ 2 affected body areas with abscesses or nodules C: $< 1\%$ of BSA, with > 2 affected body areas with abscesses or nodules Hurley III: $\geq 1\%$ of BSA of the involved body site with interconnected inflammatory sinus tracts

BSA, Body Surface Area.

While mild disease can be usually controlled with lifestyle modifications, weight loss, stop smoking, topical treatment, and oral antibiotics, management of moderate-to-severe HS, frequently refractory to conventional treatments,¹⁰ is a great challenge for clinicians, and new therapeutic avenues are under study.

The aim of this article is to provide a narrative review of current, new, and future potential treatments of HS, with a special focus on medical modalities. A PubMed search was conducted, including the terms ‘hidradenitis suppurativa’, ‘treatment’, OR ‘therapy’, and the different treatments discussed in this article. Also, all the clinical trials of HS in www.clinicaltrials.gov were reviewed. To be included, studies had to discuss HS and treatment as a primary theme, be written in English, and be published in a peer-reviewed journal. After collecting the information, we collated, summarized, and reported the results using narrative synthesis.

Disease severity and outcome measures

Numerous tools have been described for assessment of patients with HS. Hurley staging has been recommended in the clinical setting,⁹ since it is simple and helps determine therapeutic needs (Table 1).¹¹ However, it does not count the

number of affected areas and fails to assess disease activity or treatment response. In an attempt to solve these limitations, the Refined Hurley staging has been proposed (Table 1).¹² Abscess and nodule counts (AN count) is feasible to perform in clinical practice and may facilitate therapeutic decisions.⁹

In research settings, the Hidradenitis Suppurativa Clinical Response (HiSCR) is the most validated and widely used measure for assessing treatment response. Patients who achieve HiSCR should show a 50% reduction in the sum of abscesses and inflammatory nodules, no increase in the number of abscesses, and no increase in the number of draining fistulas from baseline.¹³ The Modified Sartorius Score (mSS), the Hidradenitis Suppurativa Physician’s Global Assessment (HS-PGA), the Hidradenitis Suppurativa Severity Index (HSSI), and the International Hidradenitis Suppurativa Severity Score System (ISH4)¹⁴ are used in clinical trials too (Tables 2 and 3).⁹ The last four are also useful in daily practice.

Pathogenesis

Genetic, environmental, and immunologic factors intervene in the pathogenesis of HS (Figure 1).¹⁵

Approximately 30% of patients with HS have a positive family history. Monogenic HS is rare and

Table 2. Other outcome measures used in clinical trials.

HS-PGA					
Clear: 0	0 abscesses 0 draining fistulas 0 inflammatory nodules 0 non-inflammatory nodules				
Minimal: 1	0 abscesses 0 draining fistulas 0 inflammatory nodules ≥1 non-inflammatory nodules				
Mild: 2	0 abscesses, 0 draining fistulas, 1–4 inflammatory nodules OR 1 abscess or draining fistula and 0 inflammatory nodules				
Moderate: 3	0 abscesses, 0 draining fistulas, ≥5 inflammatory nodules OR 1 abscess or draining fistula and ≥1 inflammatory nodule OR 2–5 abscesses or draining fistulas and <10 inflammatory nodules				
Severe: 4	2–5 abscesses or draining fistulas ≥10 inflammatory nodules				
Very severe: 5	>5 abscesses or draining fistulas				
HSSI					
	Number of sites	Body surface area	Number of inflammatory lesions	No. of dressing changes during work hours	Pain (visual analog scale)
Stage 0	0	0	0	0	0–1
Stage 1	1	1	1–2	0	0–1
Stage 2	2	2–3	2–3	1	2–4
Stage 3	3	4–5	4–5	>1	5–7
Stage 4	≥4	>5	>5	>1	8–10
mSS					
Anatomic regions affected	3 points per each region affected: axilla, groin, gluteal, other				
Number and type of lesions	1 point for nodule 6 points for fistula (per each region)				
Longest distance between two lesions	1 point if <5 cm 3 points if 5–10 cm 9 points if >10 cm If one lesion, use same point system for size of lesion				
Lesions clearly separated by normal skin	0 points if yes 9 points if no				
HS-PGA, Hidradenitis Suppurativa Physician's Global Assessment; HSSI, Hidradenitis Suppurativa Severity Index; mSS, Modified Sartorius Score.					

Table 3. IHS4.

IHS4 (points) = number of nodules \times 1 + number of abscesses \times 2 + number of draining tunnels (fistulas/sinuses) \times 4

Mild HS: \leq 3 points

Moderate HS: 4–10 points

Severe HS: \geq 11 points

HS, hidradenitis suppurativa; IHS4, International Hidradenitis Suppurativa Severity Score System.

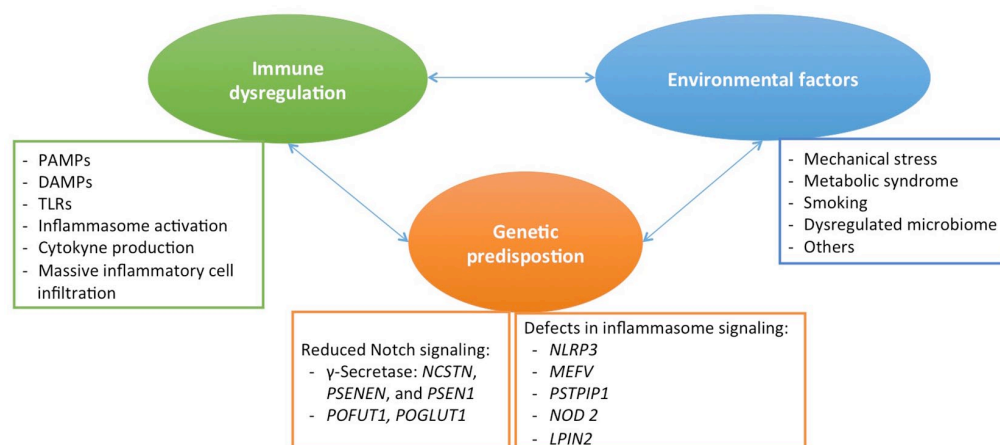


Figure 1. Causes of HS: Genetic, environmental, and immunologic factors intervene in the pathogenesis of HS. Monogenic HS can be divided into defects in Notch and γ -Secretase signaling pathways (*PSENEN*, *NCSTN* and *PSEN1*, *POFUT1*, *POGLUT1*) and defects in inflammasome function (*NLRP3*, *MEFV*, *NOD2*, *NLRP12*, *LPIN2*). Lifestyle factors including friction, smoking, obesity, and a dysbiosis have demonstrated to be contributors to HS development.

LPIN2, lipin 2; *MEFV*, Mediterranean fever; *NCSTN*, nicastrin; *NLRP3*, nucleotide-binding domain leucine-rich repeat containing protein 3; *NOD2* and *PSTPIP1*, proline-serine-threonine-phosphatase-interactive protein 1; *POFUT1*, O-fructosyltransferase 1; *POGLUT1*, protein O-glucosyltransferase 1; *PSEN*, presenilin; *PSENEN*, presenilin enhancer, gamma-secretase subunit.

can be classified into (1) defects in Notch and γ -secretase signaling pathways that lead to a severe comedone-predominant HS phenotype and (2) defects in inflammasome function that results in an inflammatory phenotype of HS with additional systemic features (Figure 1).¹⁶

The genes encoding for proteins of the γ -secretase transmembrane complex with most widely described mutations in HS are *PSENEN* (coding for presenilin enhancer), *NCSTN* (*nicastrin*), and *PSEN1* (*presenilin-1*).¹⁷ These mutations usually show familiar aggregation with autosomal dominant inheritance and incomplete penetration but have also been observed in sporadic cases.^{17–20} These mutations result in reduced signaling of the Notch pathway (involved in cell maturation

and differentiation) that leads to hyperkeratinization of the follicular epithelium, abnormal keratinocyte differentiation, disruption of the normal hair follicle cycle, and formation of follicular cysts.^{21,22} Mutations in *POFUT1* (*O-fructosyltransferase 1*), and *POGLUT1* (*protein O-glucosyltransferase 1*), which have also been involved in decreased Notch signaling, have been described in patients with concomitant HS and Dowling-Degos disease.^{23,24} Also mutation in nicastrin have been reported in patients with HS and Dowling-Degos disease.²⁵

As regards inflammasome dysfunction, it is recognized as a central driver for many autoinflammatory disorders, some of them associated to HS, such as Familial Mediterranean fever (*MEFV*

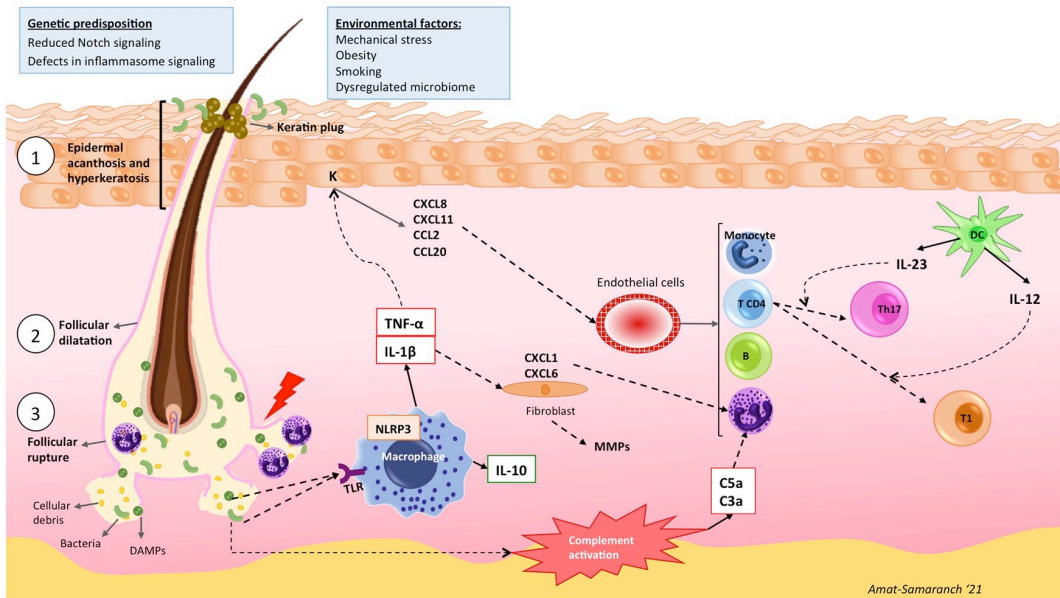


Figure 2. Early stage HS: The first event in HS lesions is hyperkeratosis and hyperplasia of the infundibular epithelium (1), produced by chronic friction, genetic predisposition, and environmental factors. This leads to follicular ‘plugging’, follicular dilatation (2), and eventual rupture (3). Bacteria and cellular debris including pathogen- and damage-associated molecular patterns (PAMPs and DAMPs) are released to the dermis initiating an innate immune response when recognized by TLRs. PAMPs and DAMPs activate the inflammasome response involving the NOD-like receptor protein 3 (NLRP3) in macrophages and neutrophils with subsequent activation of caspase-1 and activation of proinflammatory cytokines such as IL-1 β . IL-1 β provokes the production of chemokines by fibroblasts (CXCL1 and CXCL6) that will mainly attract neutrophils. TNF- α , secreted by macrophages and dendritic cells, induces the production by keratinocytes of a wide range of chemokines (CXCL8, CXCL11, CCL20, and CCL2), which attract neutrophils, subsets of T cells, and monocytes into the skin. Activated dendritic cells, through the production of IL-23 and IL-12, promote polarization of CD4 $^{+}$ T cells toward Th17 and Th1 cells, respectively. Activation of the complement pathway contributes to neutrophil activation and recruitment by C3a and C5a.

mutation).^{26,27} Inflammasome upregulation (*PSTPIP1* mutation) has also been demonstrated in pyogenic arthritis, pyoderma gangrenosum, and acne (PAPA) syndrome and pyoderma gangrenosum, acne, arthritis, and HS (PAPASH) syndrome.^{28,29} In the pyoderma gangrenosum, acne, and HS (PASH) syndrome, diverse mutations in the Notch signaling pathway and inflammasome function genes (*NCSTN*, *NOD2*, *MEFV*, *NLRP3*, *NLRP12*, *PSTPIP1*, *LPIN2*) have been reported.^{16,30}

Environmental factors such as mechanical stress,³¹ obesity,³² diabetes,³² metabolic syndrome,³³ diet,³⁴ smoking,³⁵ and hormonal factors³⁶ are known to contribute to the development or exacerbation of HS (Figure 1). Furthermore, HS has been associated to comorbidities sharing immunological dysregulation, such as axial

spondyloarthritis, inflammatory bowel disease (IBD), and psoriasis.³⁷

Skin microbiota is also considered an environmental causative factor for HS. A pattern of cutaneous dysbiosis has been associated to HS pathogenesis after observing bacterial colonization of superficial and deep HS lesions.³⁸ Bacteria play a major role in the activation of the innate immunologic response (see below), and it is also thought to play a role in the maintenance of the inflammatory response.³⁹ The exact mechanism of the influence of microbiome in HS immunologic response is not fully understood.³⁸

Follicular occlusion is the first event observed in early lesions; it is produced by infundibular keratosis and hyperplasia of the follicular epithelium (Figure 2). Local cell damage caused by

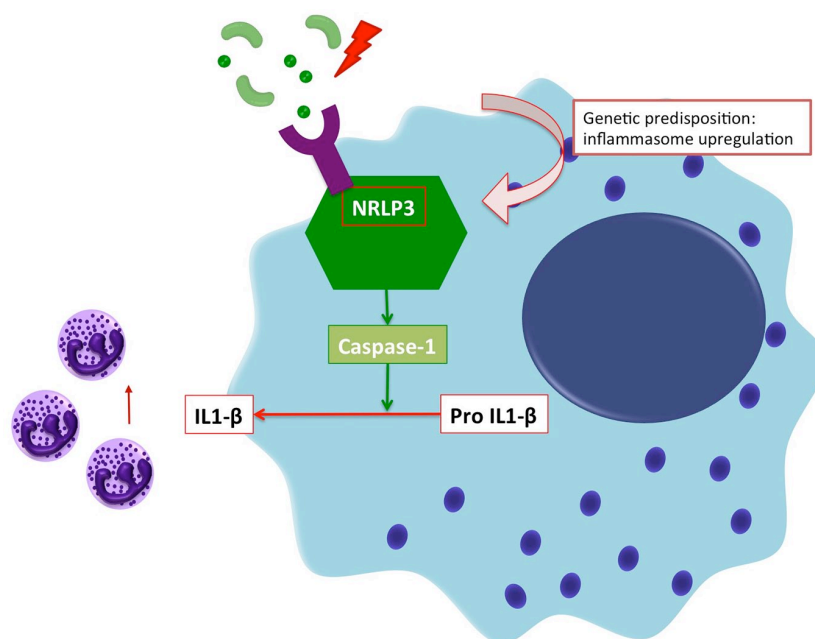


Figure 3. Inflammasome: Recognition of bacteria, PAMPs, and DAMPs activates the inflammasome through a microbial or damage-sensing protein of the NOD-like receptor family (NLRP3). NLRP3 activates Caspase-1 and cleaves pro-IL-1 β yielding its active form. Secreted IL-1 β recruits inflammatory cells (mainly neutrophils) and perpetuates the immune response. This process is favored by the presence of genetic mutations in genes that codify proteins involved in inflammasome function, such as NLRP3.

mechanical friction leads to release of cellular damage-associated molecular patterns (DAMPs) and penetration of microbial components into the follicles, which become dilated and eventually rupture.^{40,41} The release of follicular content to the dermis produces a significant inflammatory response, primarily mediated by an innate immune response to the presence of DAMPs, pathogen-associated molecular patterns (PAMPs), and microbial antigens of the commensal flora, followed by activation of Th1 and Th17 pathways. PAMPs and DAMPs released to the dermis activate macrophages through Toll-like receptor (TLR) and induce production of tumor necrosis factor-alpha (TNF- α) and, via inflammasome activation, IL-1 β (Figure 2).⁴² The inflammasome (Figure 3) is an intracellular protein complex located in macrophages and neutrophils essential for the control of the innate immune system. Recognition of PAMPs and DAMPs activates the inflammasome through a microbial or damage-sensing protein of the NOD-like receptor family (NLRP3). NLRP3 activates Caspase-1 and processes pro-IL-1 β

into its active form.¹⁶ Secretion of IL-1 β will trigger an uncontrolled activation of innate immunity, perpetuating the inflammatory activity.⁴³ IL-1 β induces the expression of CXCL1 and CXCL6 by fibroblasts, and TNF- α induces the expression of CXCL8, CXCL11, CCL2, and CCL20 by keratinocytes. These chemokines will attract granulocytes, T cells, B cells, and monocytes; the latter differentiate to macrophages (Figure 2).^{40,4} Fibroblast activation via IL-1 β also enhances the secretion of a range of matrix metalloproteinases (MMPs), IL-32, and IL-6 which implicates massive tissue immune cell infiltration, pus formation, and contributes to tissue destruction and fibrosis (Figure 4).⁴⁴

The complement system has recently attracted attention in inflammatory cutaneous disorders such as HS. The complement pathway, through C3 and C5, produces inflammation, opsonization, and bacterial lysis. C3a and C5a are strong neutrophil activators and recruiters (Figure 2), suggesting that complement inhibition might be a line of action in HS treatment.^{45,46} High blood

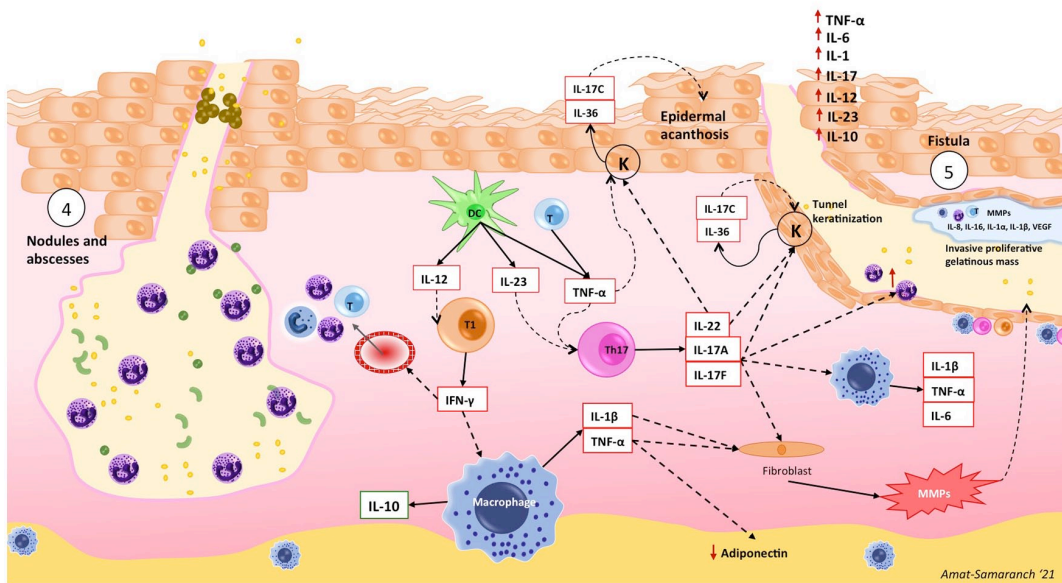


Figure 4. Advanced stage: Nodule, abscess, and fistula formation. Th1 (IL-12 polarized) cells produce $\text{INF-}\gamma$ that will activate endothelial cells to recruit more inflammatory cells and will stimulate macrophages to produce IL-10, probably as a compensatory anti-inflammatory response. $\text{TNF-}\alpha$, produced by macrophages, dendritic cells, and T lymphocytes, favors the development of Th17 cells, decreases adiponectin (anti-inflammatory hormone) secretion from adipocytes, and increases the expression of matrix metalloproteinases (MMPs). $\text{TNF-}\alpha$ contributes in recruiting inflammatory cells, and the massive infiltration will lead to the nodule and abscesses formation (4) and the production of pus. IL-17A and IL-17F stimulate neutrophils and macrophages resulting in an increase of the expression of IL-1 β , IL-6, and $\text{TNF-}\alpha$, as well as MMPs. $\text{TNF-}\alpha$, IL-17A, and IL-17F induce keratinocyte proliferation. In turn, keratinocytes produce IL-17C and IL-36, which act in an autocrine manner to further potentiate their activation and proliferation worsening epidermal acanthosis. IL-1 β activates fibroblasts and they produce MMPs, which will conduce to fistula formation (5) and fibrosis through extracellular matrix degeneration. IL-17/IL-22 signaling contributes to sinus keratinization. IL-1 α , IL-1 β , $\text{TNF-}\alpha$, IL-6, IL-17, IL-12, IL-23, and IL-10 have been identified in pus from HS lesions.

concentrations of C5a have been found in HS patients compared with healthy subjects,⁴² and reduction of nodules and draining dermal tunnels have been observed following C5a inhibition.⁴⁷

Interferon-gamma ($\text{INF-}\gamma$) is secreted by Th1 cells and activates endothelial cells contributing to the massive infiltration of inflammatory cells perpetuating the immune response (Figure 4). $\text{INF-}\gamma$ also activates macrophages to synthesize IL-10, which inhibits Th22 cells, thus leading to a reduction of IL-22 levels. The drop of IL-22 concentration will lessen the production of AMPs.⁴²

$\text{TNF-}\alpha$ is produced by macrophages and activated dendritic cells; it has multiple functions in the innate and adaptive response happening in HS.

Elevated levels of $\text{TNF-}\alpha$ can be found in skin of patients with HS and they correlate with HS severity.⁴³ It favors the development of T helper 17 (Th17) cells, decreases adiponectin (anti-inflammatory hormone) secretion from adipocytes, and increases the expression of MMPs (Figure 4).⁴² Also, a high expression of mammalian target of rapamycin gene (mTOR), implicated in cellular regulation of survival, growth, and proliferation, has been found in lesional skin. mTORC1 is important for innate and adaptive immunity and Th17 differentiation; its implication in inflammatory response in HS has been proved after the observation of a reduction of the expression of mTORC1 in lesional skin after treatment with adalimumab (ADA) during 6 weeks.⁴⁸ Anti- $\text{TNF-}\alpha$ treatment has also been shown to decrease circulating levels of IL-1 β , IL-6, IL-8, IL-10, and

IL-17A, proving its effects in innate and adaptive immunity and highlighting its modulatory effect on Th17 activity.⁴⁹

High serum levels of IL-17A have been found in HS and correlate with the severity of inflammation.⁵⁰ IL-17 stimulates neutrophils and macrophages resulting in an increase of the expression of IL-1 β , IL-6, and TNF- α , as well as caspases and MMPs in the follicular unit and perilesional skin (Figure 4).⁴² The fundamental role of IL-17 isoforms – bridging the innate and adaptive (via the IL-23/IL-17 pathway) immune responses – in the pathogenesis of HS is currently well recognized and has led to the development of clinical trials with anti-IL-17 biologic agents. Th17 cells are a lineage of CD4+ T helper cells producing canonical IL-17A and IL-17F as well as other cytokines; IL-23 produced by dendritic cells has a fundamental role in the commitment and maintenance of this polarization (Figure 2). Both IL-17 and IL-23 are increased in lesional and perilesional HS skin.^{51,52}

IL-12 and IL-23, driving Th1 and Th17 commitment, are abundantly expressed by macrophages infiltrating papillary and reticular dermis,⁵¹ and have also been targeted for therapeutic purposes.

The inflammatory components of dermal abscesses that form as a consequence of follicular disruption probably contribute to re-epithelialization and formation of dermal cysts, sinuses, fistulas, and epithelialized tunnels, which are a structural hallmark of severe HS. These epithelial structures are immunologically active, contributing IL-17C and IL-36 to the increased expression of proinflammatory cytokines and chemokines.⁵³ Their formation is dependent on IL-17/IL-22 signaling; furthermore, the Th17 cytokine IL-22 mediates proinflammatory effects on keratinocytes leading to epidermal acanthosis and hyperproliferation (Figure 4).⁵¹ These chronic epithelialized cavities contribute to create a favorable habitat for biofilm-producing bacteria, which contribute and perpetuate the inflammatory reaction.³⁹ Sinus tracts contain an invasive proliferative gelatinous mass that is attached to the sinus tract epithelium and contains inflammatory cells and cytokines (Figure 4).⁵⁴

Multiple cytokines, including IL-1 α , IL-1 β , TNF, IL-6, IL-17, IL-12, IL-23, and IL-10, have

been identified in pus secretion of HS lesions (Figure 4),⁵⁵ are involved in the pathogenesis of the disease, and have been therapeutically targeted, as discussed below.

Treatment of a multifactorial disease with complex pathogenesis such as HS is necessarily multi-pronged, with treatment algorithms based on disease severity.⁴¹ In mild stages, topical or oral antibiotics alone or combined with topical or intralesional corticosteroids, and limited surgical or para-surgical interventions, may suffice to control the disease, but as it progresses, combined therapy including systemic and surgical approaches is required.⁴¹

Treatment

Topical treatment

The role of microbiome in HS has been studied for many years and antibiotics are first-line therapy for HS, but antimicrobial treatment alone is unlikely to control disease activity. Monotherapy is considered for mild disease, but in advanced disease, combination with other treatments is needed.⁵⁶ Clinical response rates to antibiotics are difficult to compare and quantify due to the lack of controlled randomized clinical trials (RCTs).⁵⁶

Topical clindamycin 1% twice daily for 12 weeks is considered a first-line treatment for Hurley I–II stage, supported by two RCTs that showed superiority to placebo and equality to oral tetracyclines.^{57,58} Recently, an *in vitro* study evaluated a topical formulation of nanostructured lipid carriers containing clindamycin and rifampicin. They observed that this formulation leads to the accumulation of both antibiotics into the follicle, suggesting that it could be a promising formulation for topical treatment.⁵⁹ There are increasing reports of resistant bacterial stains. Knowledge of bacterial resistance profile before initiating therapy, choice of combined therapy over monotherapy, and avoidance of empiric treatments are recommended.⁶⁰

Topical resorcinol 15% once daily has been associated to good clinical response in an open-label study, including 65 patients with Hurley I and II HS. Overall, 85.2% (52/65) of patients achieved HiSCR at week 12, and >80% of reduction in

AN count was observed. The number of sinus tracts remained unchanged, but a significant reduction in the average length and thickness was observed with ultrasonography at week 12.⁶¹

A phase II open-label study is ongoing to evaluate the effect of topical gentian violet as an antiseptic and wound healing therapy in HS (NCT04388163).⁶² A phase II open-label study with topical LTX-109 aims to evaluate its antimicrobial and anti-inflammatory effects in HS treatment (NCT04756336). Also, since biofilm contributes to inflammatory response in HS, its composition and changes after applying a topical antibiofilm surfactant wound gel are under study (NCT04648631).⁶³

Finally, a phase II open-label trial with topical ruxolitinib 1.5% cream, a JAK1/JAK2 inhibitor, is expected to start promptly (NCT04414514).⁶⁴

Systemic treatment

Systemic antibiotic treatment. Tetracyclines (tetracycline, doxycycline, minocycline, lymecycline) are considered first-line oral treatment for HS based on clinical experience.¹⁰ A recent multicenter prospective cohort study showed significant decrease in IHS4 from baseline and a 40% of HiSCR achievement after 12-week treatment with tetracycline.⁶⁵ Likewise, a retrospective study comparing the efficacy of lymecycline (300 mg daily) *versus* the combination therapy clindamycin and rifampicin (600 mg plus 600 mg daily) during 10 weeks in 52 patients (26 per group) observed a 57.7% and 53.8% HiSCR achievement, respectively.⁶⁶

Clindamycin and rifampicin used at a dose of 300 mg twice daily have been proven effective in HS in several observational studies^{65,67–69} and are considered a first-line and second-line treatment for HS. A systematic review of retrospective and prospective series reported response rates from 71% to 93% in 187 patients, strongly favoring their use.⁵⁶ As recommended in international HS guidelines, systemic clindamycin and rifampicin (dosage: 300 mg twice daily) should be administered for an average length of 10 weeks in Hurley stage II/III patients presenting with several active lesions.⁷⁰ A single-center retrospective study compared the efficacy of rifampicin plus clindamycin *versus* ADA. Both treatments achieved a

statistically significant reduction of mSS, but it was greater in the ADA group. A 34% and 60% of patients achieved HiSCR, respectively.⁷¹

A prospective European cohort study that included 218 patients with HS compared efficacy and tolerability of oral tetracycline and a combination of rifampicin plus clindamycin. The results showed no significant differences in efficacy between the two treatments, regardless of the disease severity.⁶⁵

The association of daily clindamycin (600–1800 mg, according to weight) and ofloxacin (200–400 mg) for a mean observation period of 4.3 months in 65 patients led to a 33.8% (22/65) of complete response and a 24.6% (16/65) of partial response.⁷² The authors state that the overall response rates obtained (58.4) could be comparable with the ones achieved with association of rifampicin and clindamycin.⁵⁶

Prospective and retrospective cohort studies place antibiotic regimens such as rifampin–moxifloxacin–metronidazole combined therapy, iv (intravenous) ceftriaxone and iv ertapenem (particularly effective as a rescue treatment) as a third-line therapy for severe HS patients.^{56,73,74} It should be taken into account that HS international alliance guidelines recommend only one antibiotic of the same class should be used for a maximum of 12 weeks.⁷⁰

Oral retinoids. Oral retinoids have been reported to modulate IL-6 and IFN- γ activity as well as exert antiproliferative activity in keratinocytes. However, there is no compelling evidence of their effect in lesional HS skin. Acitretin results in HS are variable (doses ranging from 0.5 to 0.6 mg/kg/d and mean duration of 3–12 months), with response rates close to 50%⁷⁵ and high recurrence rates in monotherapy (up to 40% as reported by Puri and Talwar).⁷⁶ However, good clinical outcomes have been reported in some series.⁷⁷ Acitretin should be considered a second- or third-line therapy for HS.⁵⁶

Isotretinoin has shown discordant results in retrospective cohort studies and case series.⁷⁸ Better responses are reported in mild disease and with low doses (<1 mg/kg/d). Isotretinoin should be considered as a second- or third-line therapy or in patients with severe concomitant acne.⁵⁶

Alitretinoin has been evaluated in a single prospective uncontrolled study of 14 women receiving alitretinoin 10 mg/kg/d for 24 weeks. Overall, 78.5% of patients were reported to experience significant clinical improvement as assessed by mSS.⁷⁹

RCTs would be required in order to evaluate the real efficacy of oral retinoids, in as much as there are no studies comparing acitretin with isotretinoin.

Hormonal treatment. Perimenstrual exacerbations, rare postmenopausal occurrence, and improvement during pregnancy suggest that an endocrine influence for the disease,⁸⁰ but no relationship to serum and tissue hormone levels, has been found.⁸¹ Patients with polycystic ovarian syndrome and HS may benefit from hormonal therapy, either alone as monotherapy in mild-to-moderate HS or in combination therapy for more severe disease.⁵⁶ RCTs are needed to define the role of hormonal treatment as an alternative or concomitant therapy together with antibiotics or biologics.⁸² An RCT compared ethinylestradiol/noregestrel with ethinylestradiol and cyproterone acetate, both showing satisfactory clinical response.⁸³

Spirolactone 100 to 150 mg daily is also used.⁵⁶ Recently, some reports have been published on the benefits of metformin in HS, which have been attributed to its anti-androgen and anti-inflammatory effects.^{82,84} A phase III RCT with 65 patients is being conducted in order to evaluate the efficacy of metformin plus doxycycline *versus* doxycycline in monotherapy (NCT04649502).⁸⁵

Finasteride is a selective competitive inhibitor of type II 5- α reductase. Improvement of moderate-to-severe HS has been occasionally reported, but recurrences followed treatment cessation.⁸⁶ In a preliminary trial, clinical response was observed in six out of seven patients receiving finasteride (5 mg/d) as monotherapy after 8–24 months of treatment.⁸⁷ Finasteride has also been proposed as an alternative treatment in pediatric HS with appropriate tolerance and clinical response in a case series.^{88,89}

Oral and intralesional corticosteroids. Oral corticosteroids can produce pan-cytokine inhibition,⁹⁰ which agrees with the reported efficacy of systemic and intralesional corticosteroids in acute

HS flares.^{91,92} Intralesional corticosteroids can lead to rapid resolution of inflammatory nodules.^{91,93} In a multicenter retrospective study, complete resolution of inflammatory and non-inflammatory lesions was observed in 95 lesions (70.37%) treated with intralesional corticosteroids (at variable dilutions and volumes).⁹⁴ An interventional prospective study evaluated the efficacy of intralesional ultrasound-guided injections of triamcinolone plus lincomycin, at baseline and after 2 weeks; clinical and symptomatic improvement was observed in 36 out of 37 patients at week 4.⁹⁵ However, the only RCT conducted with two different doses of intralesional triamcinolone (10 and 40 mg/ml) showed no statistical differences with placebo (intralesional normal saline).⁹⁶ Comparing the results of different studies is difficult due to the diversity of dosages and volumes used. It is not clear which is the most effective concentration.⁹⁷ An ongoing phase IV RCT including 200 patients aims to evaluate three different dosages of intralesional triamcinolone (10, 20, and 40 mg/ml) and find the optimal posology (NCT04582669).⁹⁸

High dose and protracted treatment with oral corticosteroids are not recommended since HS rapidly flares after tapering, but low-dose systemic prednisolone can be a valuable adjunct therapy for recalcitrant HS.⁹⁹ American guidelines recommend the use of prednisone pulses or multiweek tapers starting at 0.5 to 1 mg/kg daily as rescue therapy for flares or as a bridge to other long-term therapy; the effect is rapid and substantial, but side effects limit their prolonged use.⁵⁶

Surgery

Recommendations for the surgical management of acute HS lesions rely on low-quality, uncontrolled, retrospective reports. Incision and drainage of acute lesions provide a rapid relief of the symptoms, but recurrence rates are close to 100%.¹⁰⁰ Deroofing, with lower recurrence rates (20–40%), is adequate to treat localized lesions or all the lesions of one anatomical site in Hurley I–II stage.¹⁰¹ Limited local excision consists in the excision of separate lesions with surgical margins; it is indicated for Hurley I–II HS and has similar recurrence rates to deroofing.^{101,102} Combination of deroofing with subsequent sinus tract excision enhances clinical results and decreases recurrence rates.¹⁰³ Wide excision is indicated for Hurley II–III HS and consists in the excision of large areas

of involved skin with wide margins.¹⁰² This technique is associated with lower recurrence rates.¹⁰⁰ The reconstruction strategy chosen after wide excision determines recurrence rates: 22% with primary closure, 11% with secondary intention healing, 2% with skin graft, and 2% with fasciocutaneous flaps.¹⁰⁴ Location of lesions can also predict clinical outcomes: perianal, vulvar, and inferior breast excisions have higher recurrence rates.⁹

Prior medical treatment can improve surgical outcomes. Combination surgery with biologic treatment has demonstrated higher rates of cure.¹⁰⁵

Laser therapy. Laser and photodynamic therapy (PDT) have been used alone and in combination with other therapies with variable results.¹⁰⁶ Comparison between treatment modalities is challenging because there are no standardized treatment protocols using these devices and settings vary between machines. Larger randomized controlled trials are needed to elucidate their role and determine the optimal treatment settings.¹⁰⁷

Long-pulsed neodymium-doped yttrium aluminum garnet (Nd:YAG) laser (1064 nm) has shown clinical improvement¹⁰⁸ and diminution of inflammation in tissue biopsy specimens.¹⁰⁸ Carbon dioxide (CO₂) laser (10,600 nm) has been used in combination with Nd:YAG or alone.¹⁰⁷ CO₂ laser (fractional mode) used before Nd:YAG enhances the depth of penetration of the latter.¹⁰⁹ Ablative CO₂ laser can be used to perform sinus deroofing or ablative destruction of lesions,¹¹⁰ and is useful in treating anesthetic scars or contractures of chronic scars.¹⁰⁷ Alexandrite laser has shown promising results in case reports and case series.¹⁰⁷ An ongoing open-label study aims to evaluate the efficacy of Alexandrite hair removal laser in 20 patients with bilateral disease (axilla or groin). One side will be treated and the other one will serve as control (NCT03054155).¹¹¹

PDT has been associated with good clinical outcomes in several studies. The photosensitizers used in different concentrations include 5-aminolevulinic acid (ALA), methyl aminolevulinate (MAL), and methylene blue (MB). PDT has been performed following either topical (ALA, MAL, and MB) or intralesional (ALA and MB) application of the photosensitizing agent. Light sources also vary, including red light (635 nm), blue light, Intense Pulsed Light (630 nm), and

laser diode (400 nm).¹⁰⁶ Response rates are not comparable between studies, but intralesional PDT seems to determine better outcomes and the axillary region has better response rates.¹¹²

Photobiomodulation is also a useful tool for non-invasive treatment of HS. It has been reported to have beneficial effects on promoting wound healing, angiogenesis, vasodilation, and relieving from pain and inflammation in an in-vitro model mimicking HS disease. It has been proposed as an adjuvant third-line treatment for the management of HS.¹¹³

Targeted biologic therapy

Table 4 summarizes the above-mentioned studies of biologic therapies.

Anti-TNF- α agents. Adalimumab. ADA is a fully human monoclonal antibody targeting soluble and transmembrane TNF- α . It is the only biologic approved for the treatment of moderate-to-severe HS in adults and adolescents by the US Food and Drug Administration (FDA) and European Medicines Agency (EMA), based on the results of two phase III trials (PIONEER I and PIONEER II).¹¹⁴ These double-blind, placebo-controlled studies enrolled 633 patients who received subcutaneous (sc) ADA 160 mg at week 0, 80 mg at week 2, and 40 mg weekly starting at week 4, or placebo. In PIONEER II, patients were permitted to continue treatment with antibiotics (tetracyclines) in stable doses.¹⁰⁴ The HiSCR with ADA was higher than with placebo at week 12 (50.6% versus 26.8%, $p < 0.001$, pooled efficacy from trials PIONEER I and II).¹¹⁵ The Dermatology Life Quality Index (DLQI) score was also improved,¹¹⁵⁻¹¹⁷ and ADA was well tolerated with the expected adverse event (AE) profile.¹¹⁵ Among the 88 patients who entered an open-label extension (OLE) study with ADA 40 mg weekly, HiSCR rates were 62.5% at week 36 and 52.3% at week 168.¹¹⁶ ADA also reduced number and duration of flares, and lengthened flare-free intervals both in short- and long-term follow-up.^{118,119}

Real-life data provided in a retrospective, multicenter cohort study showed ADA efficacy/safety and an inverse correlation between therapeutic delay and clinical response, supporting early ADA use and providing evidence for a 'window of opportunity' in HS treatment.¹²⁰ Real-life data provided in a retrospective cross-sectional study

Table 4. Biologic treatments for hidradenitis suppurativa.

Molecule	Drug	Study type	Dose	Results	Reference
TNF- α	Adalimumab	Phase III placebo-controlled RCT (PIONEER I) (n = 154)	160 mg sc at week 0, 80 mg at week 2, and 40 mg weekly starting at week 4	Percentage of patients achieving HISCOR versus placebo at week 12: 41.8% versus 26.0%, $p = 0.003$	Kimball <i>et al.</i> ¹¹⁵
		Phase III placebo-controlled RCT (PIONEER II) (n = 153)	160 mg sc at week 0, 80 mg at week 2, and 40 mg weekly starting at week 4	Percentage of patients achieving HISCOR versus placebo at week 12: 58.9% versus 27.6%, $p < 0.001$	Kimball <i>et al.</i> ¹¹⁵
		Open-label extension of phase III PIONEER I and III (n = 88)	40 mg sc every week continuously (168 weeks)	Percentage of patients achieving HISCOR: 62.5% at week 36 and 52.3% at week 168	Zouboulis <i>et al.</i> ¹¹⁶
		Retrospective real-life cohort study (n = 101)	160 mg sc at week 0, 80 mg at week 2, and 40 mg weekly starting at week 4	Percentage of patients improving HS-PGA score: 77%	Muralidharan <i>et al.</i> ¹²¹
		Retrospective, real-life multicenter cohort study (n = 389)	160 mg sc at week 0, 80 mg at week 2, and 40 mg weekly starting at week 4	Percentage of patients achieving HISCOR: 43.7% at week 16 and 53.9% at week 52	Marzano <i>et al.</i> ¹²⁰
IFX		Phase II placebo-controlled, double-blind RCT (n = 38)	5 mg/kg iv at weeks 0, 2, 4, 6, 14, and 22	Percentage of patients with $>50\%$ of decrease of HSSI index at week 8 versus placebo: 27% versus 5% ($p = 0.092$)	Grant <i>et al.</i> ¹²⁶
		Prospective open-label study (n = 42)	7.5 mg/kg iv at weeks 0, 2, and 6, then 7.5 mg/kg every 4 weeks. Dose escalation to 10 mg/kg considered after induction dose if HS-PGA score ≥ 3	Percentage of patients achieving HS-PGA 0-2: IFX 7.5: 47.6% at week 4 and 70.8% at week 12 IFX 10: 37.5% at week 4 and 50% at week 12	Ghias <i>et al.</i> ¹²⁸
Certolizumab pegol		Retrospective study and case reports (n = 6)	200 mg sc every 2 weeks 400 mg every 2 weeks	Unsuccessful response with low-dosage certolizumab Satisfactory response to certolizumab in four case reports	Sand and Thomsen, ¹³² Tampouratzi <i>et al.</i> , ¹³³ Holm <i>et al.</i> , ¹³⁴ Esme <i>et al.</i> , ¹³⁵ Wohlmut-Wieser and Alhusayen ¹³⁶
Etanercept		Phase II open-label, single-arm RCT (n = 15)	50 mg sc weekly	HS-PGA at baseline versus week 12: 4.35 versus 3.5 ($p = 0.14$) Percentage of patients improving HS-PGA: 20%; 95% CI: 4.3-48.1	Lee <i>et al.</i> ¹³⁸
Golimumab		Case reports (n = 2)	50 mg sc every 4 weeks 200 mg sc at week 0 and 100 mg every 4 weeks		van der Zee <i>et al.</i> , ¹³⁹ Tursi ¹⁴⁰

(Continued)

Table 4. (Continued)

Molecule	Drug	Study type	Dose	Results	Reference
IL-17	Secukinumab	Open-label, single-arm, pilot trial (n = 9)	300 mg sc weekly for 5 weeks, then every 4 weeks	Percentage of patients achieving HiSCR at week 24: 67%	Prussick <i>et al.</i> ¹⁴¹
		Open-label, single-arm pilot trial included (n = 20)	300 mg sc weekly for 5 weeks, then 9 patients received 300 mg every 4 weeks, and 11 patients received 300 mg every 2 weeks	Percentage of patients achieving HiSCR at week 24: 70%	Casseres <i>et al.</i> ¹⁴²
		Phase III RCTs NCT03713632, NCT03713619, NCT04179175		Pending	Novartis Pharmaceuticals ¹⁴⁴⁻¹⁴⁸
	Brodalumab	Open-label cohort study (n = 10)	210 mg sc at weeks 0, 1, and 2, then 210 mg every 2 weeks	Percentage of patients achieving HiSCR at week 12: 100%	Frew <i>et al.</i> ¹⁵²
		Open-label cohort study (n = 10)	210 mg sc weekly	Percentage of patients achieving HiSCR at week 12: 100%	Frew <i>et al.</i> ¹⁵³
	Bimekizumab	Phase II placebo-controlled, double-blind RCT (n = 90)	640 mg sc at week 0 and 320 mg every 2 weeks	Percentage of patients achieving HiSCR versus placebo at week 12: 57.3% versus 26.1% [95% CI, 11.0%-50.4%]; posterior probability of superiority = 0.998)	Giatt <i>et al.</i> ¹⁵⁵
		Phase III placebo-controlled RCT (NCT04242446, NCT04242498)		Pending	UCB Biopharma SRL ^{156,157}
	Ixekizumab	Case reports (n = 3)	160 mg sc at week 0; 80 mg at weeks 2, 4, 6, 8, 10, and 12; and 80 mg every 4 weeks	Satisfactory response to ixekizumab in three case reports	Odorici <i>et al.</i> , ¹⁵⁸ Megna <i>et al.</i> , ¹⁵⁹ Reardon <i>et al.</i> ¹⁶⁰
	CJM112	Phase II placebo-controlled, double-blind RCT (NCT02421172) (n = 66)	300 mg sc weekly for 5 weeks followed by 300 mg every 2 weeks	HS-PGA response rate versus placebo at week 16: 32.3% versus 12.5% (p = 0.9729)	Novartis Pharmaceuticals, ¹⁶² Kimball <i>et al.</i> ¹⁶³
IL-12/23	Ustekinumab	Phase II open-label study (n = 17)	45 mg sc if <90 kg and 90 mg if >90 kg at weeks 0, 4, 16, and 28	Percentage of patients achieving HiSCR at week 40: 47%	Blok <i>et al.</i> ¹⁶⁴

(Continued)

Table 4. (Continued)

Molecule	Drug	Study type	Dose	Results	Reference
		Case reports and case series (n=30)	sc weight adjusted dose 90 mg sc every 12 weeks 90 mg sc every 8 weeks	Variable response to ustekinumab	Gulliver <i>et al.</i> , ¹⁶⁵ Sharon <i>et al.</i> , ¹⁶⁶ Santos-Pérez <i>et al.</i> , ¹⁶⁷ Eisen, ¹⁶⁸ Scholl <i>et al.</i> , ¹⁶⁹ Takeda <i>et al.</i> , ¹⁷⁰ Cline and Pichardo, ¹⁷¹ Montero-Vilchez <i>et al.</i> , ¹⁷² Valenzuela-Ubrina <i>et al.</i> , ¹⁷⁵
		Retrospective multicenter study (n = 14)	iv weight adjusted dose (≤55 kg, 260 mg; 56–85 kg, 390 mg; ≥86 kg, 520 mg), followed by 90 mg sc every 8 weeks	Percentage of patients achieving HiSCR at week 16: 50%	Romani <i>et al.</i> , ¹⁷³
		Retrospective unicenter study (n = 14)	iv weight adjusted dose, followed by 90 mg sc every 8 weeks	Percentage of patients achieving HiSCR at week 16: 50%	Sánchez-Martínez <i>et al.</i> , ¹⁷⁴
IL-23	Guselkumab	Phase II placebo-controlled, double-blind RCT (NCT03628924)		Pending	Janssen Research & Development, LLC, ¹⁸³
		Case reports and case series (n = 19)	100 mg sc at weeks 0, 4, and then every 8 weeks 100 mg sc at weeks 0, 4, and then every 4 weeks	Variable response to guselkumab	Kovacs and Podda, ¹⁷⁶ Casseres <i>et al.</i> , ¹⁷⁷ Kearney <i>et al.</i> , ¹⁷⁸ Berman <i>et al.</i> , ¹⁷⁹ Jørgensen <i>et al.</i> , ¹⁸⁰ Burzi <i>et al.</i> , ¹⁸¹ Montero-Vilchez <i>et al.</i> , ¹⁸²
	Risankizumab	Case reports (n=4)	150 mg sc at weeks 0 and 4, followed by 150 mg sc every 12 weeks	Successful response, HiSCR achievement	Marques <i>et al.</i> , ¹⁸⁴ Licata <i>et al.</i> , ¹⁸⁵ Caposiena Caro <i>et al.</i> , ¹⁸⁶
		Phase II placebo-controlled, double-blind RCT (NCT03926169)		Pending	AbbVie ¹⁸⁷
	Tildrakizumab	Case series (n=5)	100 mg sc at weeks 0, 4, and 200 mg every 4 weeks thereafter	All patients showed improvement in AN count at week 8	Kok <i>et al.</i> , ¹⁸⁸
IL-1	Anakinra	Open-label phase II study (n = 6)	100 mg sc daily for 8 weeks	Mean decrease of 34.8 points in mSS. All patients experienced a rebound during an 8-week follow-up period	Leslie <i>et al.</i> , ¹⁸⁹
		Phase II placebo-controlled, double-blind RCT (n=20)	100 mg sc daily for 12 weeks	Percentage of patients achieving HiSCR versus placebo at week 12: 78% versus 30% (p=0.04) After a 12-week observation period, the HiSCR difference between groups was not significant	Tzanetakou <i>et al.</i> , ¹⁹⁰

(Continued)

Table 4. (Continued)

Molecule	Drug	Study type	Dose	Results	Reference
	Bermkinimab	Phase II placebo-controlled, double-blind RCT (NCT02643654) (n = 10)	7.5 mg/kg iv every 2 weeks	Percentage of patients achieving HiSCR versus placebo at week 12: 60% versus 10% (p = 0.035)	Kanni <i>et al.</i> ¹⁹⁶
		Open-label extension of NCT02643654 (n = 8) group)	7.5 mg/kg iv every 2 weeks (patients who had been randomized in the placebo group)	Percentage of patients achieving HiSCR at week 12: 75%	Kanni <i>et al.</i> ¹⁹⁷
		Phase II multicenter open-label study (n = 42)	400 mg sc weekly	Percentage of patients achieving HiSCR at week 12: 61% of anti-TNF naive patients and 63% of anti-TNF failure patients	Gottlieb <i>et al.</i> ¹⁹⁸
	Canakinumab	Case reports (n = 6)	150 mg sc at day 1, then monthly 150 mg sc at day 1, day 15, then monthly 150 mg every week/4 weeks/8 weeks	Variable results. Positive results in three patients. Negative results in three patients (two of them with concomitant pyoderma gangrenosum)	Houriet <i>et al.</i> , ²⁰⁰ Jaeger <i>et al.</i> , ²⁰¹ Sun <i>et al.</i> , ²⁰² Tekin <i>et al.</i> ²⁰³
PDE-4 inhibitors	Apremilast	Phase II placebo-controlled, double-blind RCT (n = 20)	30 mg po twice daily	Percentage of patients achieving HiSCR versus placebo at week 16: 53.3% versus 0% (p = 0.055)	Vossen <i>et al.</i> ²⁰⁴
		Investigator-initiated trial, placebo controlled (n = 15)	30 mg po twice daily	Absence of significant changes in inflammatory markers in lesional skin of patients receiving apremilast compared with placebo, despite clinical improvement in the apremilast group	Vossen <i>et al.</i> ²⁰⁶
Complement C5a inhibitors	IFX-1	Phase II open-label trial (n = 12)	800 mg iv on days 1, 4, 8, 15, 22, 29, 36, and 43	Percentage of patients achieving HiSCR at day 43: 75% Percentage of patients achieving HiSCR after the 3-month follow-up period: 83%	Giamarellos-Bourboulis <i>et al.</i> ⁴⁷
		Phase II placebo-controlled, double-blind RCT (NCT03487276) (n = 175)	400 mg iv every 4 weeks 800 mg every 4 weeks 800 mg every 2 weeks 1200 mg every 2 weeks Placebo	Percentage of patients achieving HiSCR, respectively: 47.1%, 40.4%, 51.5%, 38.7%, and 45.5%	InflaRx GmbH ²⁰⁷
	Avacopan	Phase II placebo-controlled, double-blind RCT (NCT03852472) <i>Ex vivo</i> study (NCT04251663)		Pending	ChemoCentryx, ²⁰⁸ Sarin ²⁰⁹
JAK inhibitors	Tofacitinib	Case report (n = 2)		Clinical improvement	Savage <i>et al.</i> ²¹⁰

(Continued)

Table 4. (Continued)

Molecule	Drug	Study type	Dose	Results	Reference
	INC054707	Phase II placebo-controlled, double-blind RCT (NCT04476043)		Pending	Incyte Corporation ²¹³
	Upadacitinib	Phase II placebo-controlled, double-blind RCT (NCT04430855)		Pending	AbbVie ²¹⁴
Other molecules	Iscalimab (anti-CD40)	Phase II placebo-controlled, double-blind RCT (NCT03827798)		Pending	Novartis Pharmaceuticals ²¹⁵
	Spesolimab (anti-IL36)	Phase II placebo-controlled, double-blind RCT (NCT04762277)		Pending	Boehringer Ingelheim ²¹⁶
	Ismidolimab (anti-IL36)	Phase II placebo-controlled, double-blind RCT (NCT04856930)		Pending	AnaptysBio, Inc. ²¹⁷
	LY 3041658 (anti-CXCR1 and CXCR2 signaling)	Phase II placebo-controlled, double-blind RCT (NCT04493502)		Pending	Eli Lilly and Company ²¹⁸
	LYS 006 (LTA4 hydrolase inhibitor)	Phase II placebo-controlled, double-blind RCTs (NCT03827798, NCT03497897)		Pending	Novartis Pharmaceuticals ^{215,219}
	KT-474	First-in-human study (phase II) (NCT04772885)		Pending	Kymera Therapeutics, Inc. ²²⁰

sc, subcutaneous; po, oral; AN, abscess and nodule; CI, confidence interval; HiSCR, Hidradenitis Suppurativa Clinical Response; HS-PGA, Hidradenitis Suppurativa Physician's Global Assessment; HSSI, Hidradenitis Suppurativa Severity Index; IFX, infliximab; LTA4, leukotriene A4; PDE-4, phosphodiesterase-4; RCT, randomized clinical trial.

showed efficacy rates and improvement in DLQI rates comparable with previous trials.¹²¹

ADA 40 mg weekly is more effective and offers more prevention of flaring than 40 mg every other week¹²² and may be continued indefinitely.¹¹⁶ Dose intensification to 80 mg weekly has been proposed for patients with insufficient response or with loss of efficacy after initial response to 40 mg/week, but larger studies are required to corroborate this observation.¹²³

Biosimilar ADA (SB5) has also been found to be effective, well tolerated, and interchangeable with originator ADA for HS treatment in a retrospective 36 weeks 'real life' observational study.¹²⁴

Calprotectin, fractalkine, and HCC-4 have been identified as potential predictive biomarkers of ADA response (86% predictive accuracy rate for ADA response).¹²⁵

The superior response to TNF- α blockade of subcutaneous nodules *versus* tunnels suggests that the formation of the latter is mediated by IL-17 rather than by TNF- α signaling.⁵³

Infliximab. Infliximab (IFX) is a chimeric monoclonal antibody targeting soluble and transmembrane TNF- α .¹¹⁴ In a phase II randomized, double-blind study, 38 patients with moderate-to-severe HS received 5 mg/kg of iv IFX on weeks 0, 2, 4, 6, 14, and 22. At week 8, 57% of patients had a < 50% decrease of HSSI vs. 5% in the placebo group ($p = 0.092$). A post-hoc analysis showed that 60% of patients had a 25% to <50% decrease in HS HSSI compared with 5.6% of patients receiving placebo ($p < 0.001$).¹²⁶ IFX also reduced inflammatory markers as well as improved mean DLQI and visual analog scores (VAS) of pain.¹²⁶ The drug was well tolerated, and no safety issues were reported.¹²⁶

Doses higher than 5 mg/kg have been proposed. Oskardmay *et al.*¹²⁷ conducted a retrospective cohort study with 52 patients treated with IFX 10 mg/kg every 6 or 8 weeks, obtaining satisfactory results. Also, a prospective study concluded that starting IFX at 7.5 mg every 4 weeks, with possible dose escalation to 10 mg, provides optimal control of disease activity.¹²⁸ New prospective placebo- or active-agent-controlled phase III trials should be done to ascertain the eventual role of IFX in HS treatment.¹²⁹

In a recent retrospective cohort study, the efficacy of IFX *versus* its biosimilar infliximab-abda has been found to be clinically equivalent (HiSCR 71% *versus* 60% at week 10, $p = 0.47$).¹³⁰

In a practice cohort study, drug survivals of ADA and IFX in HS have been found to be similar and rather low (30.5% and 48.6% at 24 months); treatment interruption was predominantly determined by ineffectiveness and side-effects.¹³¹

Certolizumab pegol. Certolizumab pegol (CZP) is a pegylated humanized monoclonal antigen-binding fragment of IgG, which binds to TNF- α . A retrospective study on off-label use of TNF-inhibitors reported no efficacy of low-dose CZP (200 mg every 2 weeks) in two patients.¹³² Several case reports purport successful results of CZP 400 mg sc every 2 weeks¹³³⁻¹³⁶ in patients with moderate to HS refractory to other biologics.

Unlike other anti-TNF- α agents, CZP is not subject to active placental transfer and would be idoneous for the treatment of pregnant patients.¹³⁷ To date, there is only one report of successful treatment of HS with CZP during pregnancy in a patient with Hurley stage III HS.¹³⁶

Other TNF- α inhibitory agents. Etanercept is a recombinant human TNF- α receptor p75-Fc fusion protein that competitively binds membrane-bound TNF- α receptors. Only one phase II open-label, single-arm RCT of etanercept has been conducted, with no significant improvement in patient- or physician-reported outcomes.¹³⁸

Golimumab is a fully human anti-TNF- α monoclonal antibody that binds to soluble and membrane-bound TNF- α . Two case reports of golimumab treatment with HS have been published;^{139,140} it was successful only in one patient with concomitant pyostomatitis vegetans and silent ulcerative colitis who was treated with golimumab 200 mg followed by 100 mg every 4 weeks.¹⁴⁰

Anti-IL-17 agents. Serum levels of IL-17 have been found to be elevated in patients with HS compared with healthy controls, and to correlate with disease severity according to the Hurley stage.⁵⁰ This has led to investigate new therapeutic strategies, even though the relative contributions of the different isoforms of IL-17 (A, F, C, etc.) have not been completely elucidated.

Secukinumab. Secukinumab (SEC) is a human monoclonal immunoglobulin G1 kappa antibody that selectively binds to IL-17A. An open-label pilot trial included nine patients with moderate-to-severe HS who were administered SEC 300 mg sc weekly for 5 weeks, then every 4 weeks for 24 weeks; 67% (6/9) of patients achieved HiSCR.¹⁴¹

A single-arm, open-label pilot trial included 20 HS patients, Hurley grades II–III, who received SEC 300 mg weekly for 5 weeks; then 9 patients were administered SEC 300 mg every 4 weeks, and 11 patients were treated with 300 mg every 2 weeks through week 24. Seventy percent (14/20) of all patients achieved HiSCR by week 24.¹⁴²

Similar results of the same protocol were observed in a retrospective study evaluating 20 Hurley IC - III HS patients previously refractory to antibiotics and anti-TNF- α (ADA or IFX): after 16 weeks, 75% (15/29) of patients achieved HiSCR and the response was maintained for an average of 14 months.¹⁴³ In two patients who developed Crohn's disease during treatment, the drug was stopped and they were successfully treated with ustekinumab (UST) and IFX, respectively.¹⁴³ There is some concern about the risk of developing IBD with anti-IL-17 treatment in HS patients, who are already at higher risk of IBD.¹⁴⁴ In a recent Italian retrospective study of HS patients treated with psoriasis dosage of SEC, 13/31 (41%) of patients achieved HiSCR at week 28, and there was no report of IBD triggering or worsening.¹⁴⁵

Three phase III RCTs of SEC for the treatment of HS are currently ongoing (NCT03713632, NCT03713619, NCT04179175).^{146–148}

SEC has been reported to induce HS in a patient with psoriasis, probably due to cytokine imbalance after treatment initiation.¹⁴⁹

Brodalumab. Brodalumab (BRO) is a monoclonal antibody that binds to the IL-17RA subunit of the IL-17 receptor dimer and blocks signaling of multiple isoforms of IL-17 (mostly IL-17A, IL-17C, and IL-17F). This may be important as each of these cytokines can drive neutrophilic inflammation, and the blockade of multiple isoforms might provide superior results to blockade of individual cytokines.

BRO has shown promising results in three case reports,^{133,150,151} and two phase I open-label trials have been conducted. An open-label cohort study included 10 patients with moderate-to-severe HS who were treated with BRO 210 mg sc at weeks 0, 1, and 2 and every 2 weeks thereafter until week 24. At week 12, all patients (10/10) achieved HiSCR (as early as week 2 in some), and 80% achieved IHS4 category change. The authors highlighted the rapid reduction of tunnel drainage and ultrasonographical signs of inflammation, usually refractory to other therapies.¹⁵² However, two patients with extensive gluteal tunnels experienced relapses of drainage 1 week after each drug administration during the maintenance period (210 mg every 2 weeks). Thus, a subset of patients with severe disease and high proportion of sinus tracts might require higher doses of BRO.¹⁵² This hypothesis was evaluated in another open-label study including 10 patients with draining tunnels and severe HS. BRO 210 mg weekly was administered for 24 weeks with good tolerance and safety profile. At week 12, 100% of patients achieved HiSCR, 80% achieved a 75% reduction in total AN count (HiSCR-75), and 50% achieved a 100% reduction (HiSCR-100). In contrast to the every 2-week dosing, cyclical disease suppression or recurrence in tunnel drainage was not observed with weekly dosing.¹⁵³

The efficacy of BRO in reducing drainage of sinus tracts is remarkable, since other therapies have been proven unsuccessful;¹⁵² blockade of keratinocyte-derived IL-17C might provide a potential explanation.

Other anti-IL-17 agents. Bimekizumab is a humanized monoclonal antibody that potently and selectively neutralizes IL-17A and IL-17F.¹⁵⁴ A phase II RCT comparing bimekizumab with placebo including 90 patients has been recently published. Bimekizumab 640 mg was administered subcutaneously at week 0 and then 320 mg every 2 weeks during 10 weeks. At week 12, HiSCR was achieved in a 57.3% of patients in the bimekizumab group and 26.1% in the placebo group (95% credible interval for difference, 11.0–50.4%; posterior probability of superiority = 0.998).¹⁵⁵ Two phase III RCTs are being conducted to evaluate the efficacy and safety of bimekizumab for HS treatment (NCT04242446, NCT04242498).^{156,157}

Ixekizumab is a humanized IgG4-type monoclonal antibody that binds with high affinity to soluble IL-17A and IL-17 A/F. There is scarce evidence of the efficacy of this drug for HS treatment; our literature review only found three recent case reports suggesting the potential usefulness of ixekizumab for HS.^{158–160}

CJM112 is a novel fully human anti-IL-17A IgG1/ κ monoclonal antibody that binds with similar affinity as ixekizumab to both human IL-17A and IL-17A/F.¹⁶¹ A phase II RCT multicenter study in patients with moderate-to-severe HS has been completed to determine the efficacy and safety of multiple doses of CJM112 (NCT02421172).¹⁶² At 16 weeks, the HS-PGA response rate was 32.3% (10/31) with CJM112, which was significantly superior to 12.5% (4/32) with placebo. The decrease in number of inflammatory lesions (abscesses, nodules, and fistulas) was 56% with CJM112 compared with 30% for placebo.¹⁶³

Anti-IL-12/23 agents. UST. UST is a human IgG1K monoclonal antibody that binds with high affinity to the p40 subunit of IL-12 and IL-23. These cytokines are thereby prevented from interacting with their IL-12Rb1 receptor protein, which is expressed on the surface of T cells and natural killer cells.¹¹⁴ Certain genetic variations within the gene encoding the common IL-12bR1 subunit of the IL-12/IL-23 receptor have been shown to be associated with a more severe course of HS.¹⁶⁴

One phase II open-label study evaluated the efficacy of UST, as measured by mSS, in 17 patients with moderate-to-severe HS. The weight-based psoriasis dosage of UST was used at weeks 0, 4, 16, and 28, followed by an observation period until week 40. At week 40, improvement of mSS was marked in 35% of patients and moderate in 47%. A 47% of patients achieved HiSCR at week 40. Although the authors compared these results with those obtained in ADA RCTs, the high dropout rate in their study carries a significant risk of bias.¹⁶⁴

Response rates to UST have been variable in several case reports and small series.^{165–172} As in the study conducted by Blok *et al.*,¹⁶⁴ psoriasis dosages have been used in most cases, but it is believed that higher doses (like those in Crohn's disease) might be necessary to control HS.¹⁶⁴

A retrospective multicenter study evaluated HS treatment with iv infusions of UST adjusted by weight (≤ 55 kg, 260 mg; 56–85 kg, 390 mg; ≥ 86 kg, 520 mg), followed by subcutaneous maintenance dose of 90 mg every 8 weeks (the regime approved for Crohn's disease) in 14 patients. Included patients had recalcitrant HS that had not responded to at least one prior biologic treatment. At 16 weeks, 50% of patients achieved HiSCR and a significant improvement of DLQI was reported in over 70% of patients.¹⁷³ A retrospective study including six patients treated with this regime obtained the same clinical response.¹⁷⁴ Moreover, in a retrospective study, HiSCR was achieved by 9/10 patients treated with UST 90 mg every 8 weeks (without induction dose).¹⁷⁵ Whether higher doses are more effective in HS requires further evaluation in RCTs.

Anti-IL-23 agents. Guselkumab. Guselkumab (GUS) is a human monoclonal antibody that targets the p19 protein subunit of extracellular IL-23. Six published case reports and retrospective case series have reported positive results treating recalcitrant HS with GUS 100 mg sc at weeks 0, 4, and then every 8 weeks.^{176–181} A case series reported poor results with higher doses of GUS (100 mg at weeks 0, 4, and then every 4 weeks): discrete improvement in two patients, no response in one patient, and worsening in one patient.¹⁸² These variable results might be explained because most patients have severe disease refractory to other biologic therapies.

A phase II randomized, placebo-controlled, double-blind study evaluating the efficacy, safety, and tolerability of three different dosages of GUS in patients with moderate-to-severe HS has been completed, but its results have not yet been published (NCT03628924).¹⁸³

Other anti-IL-23 agents. Risankizumab is a humanized immunoglobulin G1 monoclonal antibody selective to the IL-23. Three publications report clinical response to risankizumab in four patients treated at psoriasis doses (150 mg sc at week 0, week 4, and every 12 weeks thereafter).^{184–186} A phase II, double-blind RCT to evaluate the safety and efficacy of two dose levels of risankizumab in adult patients with moderate-to-severe HS is being conducted (NCT03926169).¹⁸⁷

Tildrakizumab is a humanized monoclonal antibody that targets the p19 subunit of IL-23. Only a case series reports a successful clinical response in five patients receiving tildrakizumab 100 mg sc at weeks 0, 4, and 200 mg every 4 weeks thereafter. All patients demonstrated an improvement in AN count at week 8 compared with baseline and four patients reported improvement in DLQI.¹⁸⁸

Anti-IL-1 agents. Anakinra. Anakinra is a recombinant form of human IL-1 receptor antagonist (IL-1RA), and it competitively inhibits the interaction of both IL-1 α and IL-1 β with their receptor.

The efficacy of anakinra in the literature remains controversial. An open-label phase II trial including six patients with moderate-to-severe HS treated with daily anakinra 100 mg sc for 8 weeks demonstrated a significant mean decrease of 34.8 points in mSS and improvement of DLQI in five patients, but post-treatment rebound was observed in all patients during an 8-week follow-up period.¹⁸⁹ Moreover, in an RCT including 20 patients with Hurley stage II or III, HiSCR rate was 78% in patients receiving anakinra *versus* 30% in the placebo arm at week 12 ($p=0.04$). However, after a 12-week post-treatment observation period, the HiSCR difference between groups was not significant.¹⁹⁰ Long-term efficacy and safety of anakinra was suggested in a small series of three patients with follow-up ranging from 6 months to 7 years, but all of them eventually relapsed and required a treatment switch to anti-TNF.¹⁹¹ Additional case reports and case series alternate success^{192,193} with failure.^{139,194,195}

Although the IL-1 pathway has been shown to be upregulated in HS,⁴⁴ the available evidence on anakinra together with frequent injection site reactions¹⁸⁹ make it less attractive than other potential therapeutic alternatives.

Bermekimab. Bermekimab (BER), also known as MABp1, is a recombinant human IgG1 monoclonal antibody that neutralizes IL-1 α by binding it with high affinity. High concentrations of IL-1 α in lesional skin¹⁹⁰ provide the basis for clinical development of BER as an HS treatment. Intravenous BER (7.5 mg/kg every 2 weeks) resulted in 60% of patients (6/10) achieving HiSCR *versus* 10% of patients (1/10) in the placebo group at 12 weeks.¹⁹⁶ Eight patients who had received placebo were then transitioned to

open-label i.v. BER and 75% achieved HiSCR at week 12 of the OLE period.¹⁹⁷

An open-label phase II study evaluated the efficacy of weekly BER 400 mg sc in patients with moderate-to-severe HS who were naïve (18 patients) or had failed to anti-TNF therapy (23 patients). A 61% of anti-TNF naïve and 63% of anti-TNF failure patients achieved HiSCR at week 12. There was also a significant reduction in AN count [60% ($p<0.004$) and 46% ($p<0.001$)] and VAS pain score [64% ($p<0.001$) and 54% ($p<0.001$)] in anti-TNF naïve and in anti-TNF failure group, respectively, with no drug-related AEs with the exception of injection site reactions.¹⁹⁸

BER seems a promising first-line biologic treatment option for refractory moderate-to-severe HS as well as a second-line alternative for patients with failure to anti-TNF agents.¹⁹⁹

Canakinumab. Canakinumab is a human IgG κ monoclonal antibody targeting IL-1 β and has shown positive^{200,201} and negative^{202,203} results in terms of efficacy in case reports; no RCTs are registered in www.clinicaltrials.gov.

Apremilast. Apremilast (APR) is an oral selective phosphodiesterase-4 (PDE-4) inhibitor. In a phase II RCT, 8/15 patients (53.3%) receiving APR 30 mg twice daily for 16 weeks achieved HiSCR compared with 0% in the placebo group ($p=0.055$).²⁰⁴ Four of the responders continued APR therapy, with maintenance of response after 2 years of treatment.²⁰⁵ These findings contrast with those in an investigator-initiated trial that did not detect statistically significant changes in inflammatory markers in lesional skin of HS patients receiving APR compared with placebo, despite clinical improvement in the APR group.²⁰⁶

Complement C5a inhibitors. IFX-1 is a monoclonal IgG4 kappa antibody that selectively binds to C5a and blocks its biological activity. In a phase II open-label trial, administration of IFX-1 800 mg iv on days 1, 4, 8, 15, 22, 29, 36, 43, and 50 was performed. Nine out of 12 patients (75%) achieved HiSCR at the end of treatment and 10/12 (83.3%) at the end of the 3-month follow-up period.⁴⁷ A phase II randomized placebo-controlled trial (NCT03487276) has been recently completed and has available results. In total, 175

patients were randomized to receive double-blind treatment with placebo or four different doses of IFX-1 (400 mg every 4 weeks, 800 mg every 4 weeks, 800 mg every 2 weeks, and 1200 mg every 2 weeks). HiSCR achievement was achieved in 47.1%, 40.4%, 51.5%, 38.7%, and 45.5%, respectively.²⁰⁷

Avacopan is an oral C5a receptor antagonist under development for treatment of HS, Antineutrophil cytoplasmic antibodies-associated vasculitis, and atypical hemolytic uremic syndrome. A phase II RCT is currently ongoing (NCT03852472),²⁰⁸ as well as a mechanistic study to examine the role of C5a receptors in HS (NCT04251663).²⁰⁹

JAK inhibitors. Tofacitinib is a Janus kinase inhibitor that has been used with successful results and no safety concerns in two patients with Hurley III ulcerated HS resistant to other biologics.²¹⁰

INCB054707 is an orally administered Janus kinase 1 (JAK1) inhibitor under development for the treatment of HS.¹⁹⁹ Two recently completed phase II trials (NCT03569371, NCT03607487) have assessed the safety of this drug in 10 and 35 patients, respectively. In the NCT03607487 trial, patients were randomized to receive placebo or INCB054707 30, 60, or 90 mg. Preliminary results indicate that 80% of patients treated with 30 and 60 mg had grade 1–2 AEs. With the 90 mg dose, 50% of patients had grade 1–2 AEs and a 37% had grade 3 AEs.^{211,212} Another phase II RCT including 200 patients and intending to assess drug efficacy is currently recruiting (NCT04476043).²¹³

A phase II randomized placebo-controlled trial with upadacitinib, another JAK inhibitor, is about to start promptly (NCT04430855).²¹⁴

Other molecules under development. Iscalimab (CFZ533) is a fully human anti-CD40 IgG1 monoclonal antibody that blocks the CD40–CD154 costimulatory pathway.¹⁹⁹ A phase II randomized, placebo-controlled trial assessing its efficacy and safety in HS treatment is currently recruiting patients (NCT03827798).²¹⁵

Spesolimab, a monoclonal antibody directed against the IL-36 receptor, which is under clinical development for pustular psoriasis and other

diseases characterized by neutrophilic infiltration, is also being tested in HS patients (NCT04762277).²¹⁶

Ismidolimab (ANB019) is a monoclonal antibody directed against the IL-36 receptor, with a phase II RCT registered in www.clinicaltrials.gov (NCT04856930).²¹⁷

LY 3041658 is a monoclonal antibody that neutralizes chemokines that bind to the CXCR1 or CXCR2 receptors. It is being evaluated in a phase II randomized placebo-controlled study for HS (NCT04493502).²¹⁸

LYS 006 is an orally administered leukotriene A4 (LTA4) hydrolase inhibitor under development for the treatment of HS and inflammatory acne. Patients are being recruited in two phase II trials (NCT03827798 and NCT03497897).^{215,219}

KT-474 is an oral small molecule that degrades the IL-1 receptor-associated kinase 4 (IRAK4) and is currently being evaluated for the treatment of interleukin-1 receptor (IL-1R)/TLR-driven immune-inflammatory diseases. A first-in-human study (phase I) evaluating safety, tolerability, drug pharmacokinetics and pharmacodynamics is currently in the recruitment phase (NCT04772885).²²⁰

Several small molecules are currently being developed by Pfizer, aiming for oral treatment of HS and other inflammatory diseases. Patient recruitment is ongoing in a phase II, randomized, placebo-controlled 16-week study evaluating the safety and efficacy of PF-06650833, PF-06826647, and PF-06700841 in the treatment of 192 adults with moderate-to-severe HS (NCT04092452).²²¹ PF-06650833 is an IRAK4 inhibitor under development for the treatment of HS and rheumatoid arthritis. PF-06826647 is a tyrosine kinase 2 (TYK2) inhibitor under development for the treatment of HS, psoriasis, and ulcerative colitis. PF-06700841 is a TYK2/JAK1 inhibitor that prevents IL-12 and IL-23 signaling¹⁹⁹ and is being developed for the treatment of HS and psoriasis.²²²

Where are we now and where are we going? To date, ADA is the only approved biologic treatment with extensive evidence on HS. The existence of a subset of patients with failure to ADA has derived in an intensive search for other

molecules. The wide array of treatment options provides hope to those patients with advanced and treatment-refractory disease.

As shown in this review, a large amount of new molecules are being evaluated for HS treatment. As the pathogenesis of HS is becoming better known, it is logic to expect an increase in research of new molecules.^{199,223} However, the identification of potential drugs for HS has been based on preexistent drugs for other diseases (such as psoriasis) rather than in translational research based on HS pathogenesis. This would explain poorer results in RCTs compared with those in psoriasis; even though common inflammatory pathways are activated, those in HS might be wider and different.¹⁹

Measurement of clinical outcomes in RCTs has also been subject to some criticism. On one hand, HiSCR counts the reduction in inflammatory abscess and nodules, but it does not consider draining fistulas of advanced disease. On the other hand, IHS4 considers nodules, abscesses, and draining fistulas, and thus may be a more representative outcome measure of HS. However, results in most RCTs are measured by HiSCR, which may lead to underestimation of response, since highly cicatricial disease can occur with low inflammatory nodule counts.²²⁴ Extensive historical use of HiSCR determines the need of evaluating future studies by HiSCR in order to obtain comparable results, but a change (or supplementation) of treatment outcome measures used in clinical trials is highly advisable.

The cytokine cascade of HS appears complex and has been the main objective of research in recent years, but the mechanisms underpinning the initiation and progression of inflammation remain unknown. Although high serum and tissue levels of some cytokines have been detected, their specific blockade has not been leading to high rates of complete clinical response. This reaffirms the implication of genetic and environmental factors and suggests the presence of unidentified agents modifying disease activity or determining drug resistance.¹⁹

Our ignorance of the exact pathogenesis of HS is compounded by its highly heterogeneous character, with different clinical presentations that have led to define different phenotypes of the disease.²²⁵ These variants most likely represent the

underlying pathogenetic heterogeneity of the disease. Also, clinically distinguished phenotypes have been shown to have different cytokine profiles, and thus would probably correspond to endotypes.⁵ Whether better responses can be achieved with a particular cytokine inhibitor in a concrete phenotype or endotype has not been studied so far.⁵

Furthermore, differences have been found between cytokine profiles in fistula drainage. Whether cytokines measured in pus secretion are predictors of treatment response with specific inhibitors is not known.⁵⁵

A crucial point is to start treatment early, before the disease progresses to fibrotic or clinically irreversible lesions. Efforts are being made to find disease biomarkers and to elucidate the factors of poor prognosis and early disease progression. This will help tailor treatment to HS patients.^{125,226}

In the authors' opinion, we are heading to a precision medicine approach with mediator-targeted therapies that will provide the most suitable treatment for HS depending on the predominant inflammatory pathway alteration. We are far from this objective nowadays, but hopefully it will be achieved in due course.

The main limitation of our review is potential bias in the selection of information sources; the search was extensive but not exhaustive, and not limited to randomized controlled trials. We did not intend to answer a specific research question with a meta-analysis, but to provide an expert review of the state of the art in HS treatment and the existing lines of research.

Conclusion

HS is a complex multifactorial disease that requires combination therapy, including lifestyle modifications, antimicrobial agents, hormonal therapy, surgery, and biologic therapy, if necessary. Due to the lack of effective treatments for moderate-to-severe HS, new therapeutic options are being studied, targeting specific cytokines involved in HS pathogenesis. Anti-IL-17 and anti-IL-1 α inhibition seem to be promising therapeutic options for ADA-refractory moderate-to-severe HS. Nevertheless, head-to-head clinical trials are not available yet. Current investigations on HS biomarkers will hopefully lead to improved

disease assessment, and further knowledge of the involved inflammatory phenomena and cytokine cascades/networks will lead to highly effective targeted precision therapy.

Author contributions

Dr. Victoria Amat-Samaranch and Dr. Eugènia Agut-Busquet contributed to the conceptualization of the article, drafted the initial manuscript, and reviewed the manuscript. Dr. Eva Vilarrasa and Dr. Lluís Puig made substantial contributions to the conception and design, and reviewed the manuscript for important intellectual content. All authors have approved the manuscript as submitted and agreed to be accountable for all aspects of the work.


Funding

The authors received no financial support for the research, authorship, and/or publication of this article.

Conflict of interest statement

The authors declared the following potential conflicts of interest with respect to the research, authorship, and/or publication of this article: Lluís Puig has perceived consultancy/speaker's honoraria from and/or participated in clinical trials sponsored by AbbVie, Amgen, Baxalta, Biogen, Boehringer Ingelheim, Celgene, Gebro, Janssen, JS BIOCAD, Leo-Pharma, Lilly, Merck-Serono, Merck Shsrp and Dohme (MSD), Mylan, Novartis, Pfizer, Regeneron, Roche, Sandoz, Samsung-Bioepis, Sanofi, and Union Chimique Belgue (UCB). Eva Vilarrasa has perceived consultancy/speaker's honoraria from and/or participated in clinical trials sponsored by AbbVie, Amgen, Bayer, Boehringer Ingelheim, Celgene, Gebro, Isdin, Janssen, Leo-Pharma, Lilly, Merck-Serono, MSD, Novartis, Pfizer, Roche, Sandoz, Sanofi, and UCB. Victoria Amat-Samaranch and Eugènia Agut-Busquet declare no conflicts of interest for this work. The Associate Editor of *Therapeutic Advances in Chronic Disease* is an author of this paper; therefore, the peer review process was managed by alternative members of the Board and the submitting Editor had no involvement in the decision-making process.

ORCID iD

Lluís Puig  <https://orcid.org/0000-0001-6083-0952>

References

1. Garg A, Lavian J, Lin G, *et al.* Incidence of hidradenitis suppurativa in the United States: a sex- and age-adjusted population analysis. *J Am Acad Dermatol* 2017; 77: 118–122.
2. Daxhelet M, Suppa M, White J, *et al.* Proposed definitions of typical lesions in hidradenitis suppurativa. *Dermatology* 2020; 236: 431–438.
3. Nguyen TV, Damiani G, Orenstein LAV, *et al.* Hidradenitis suppurativa: an update on epidemiology, phenotypes, diagnosis, pathogenesis, comorbidities and quality of life. *J Eur Acad Dermatol Venereol* 2021; 35: 50–61.
4. Sabat R, Jemec GBE, Matusiak Ł, *et al.* Hidradenitis suppurativa. *Nat Rev Dis Primers* 2020; 6: 18.
5. González-Manso A, Agut-Busquet E, Romani J, *et al.* Hidradenitis suppurativa: proposal of classification in two endotypes with two-step cluster analysis. *Dermatology* 2021; 237: 365–371.
6. von der Werth JM and Williams HC. The natural history of hidradenitis suppurativa. *J Eur Acad Dermatol Venereol* 2000; 14: 389–392.
7. Narla S, Azzam M, Townsend S, *et al.* Identifying key components and therapeutic targets of the immune system in hidradenitis suppurativa with an emphasis on neutrophils. *Br J Dermatol* 2021; 184: 1004–1013.
8. Zouboulis CC, Benhadou F, Byrd AS, *et al.* What causes hidradenitis suppurativa ? 15 years after. *Exp Dermatol* 2020; 29: 1154–1170.
9. Alikhan A, Sayed C, Alavi A, *et al.* North American clinical management guidelines for hidradenitis suppurativa: a publication from the United States and Canadian Hidradenitis Suppurativa Foundations: part I: diagnosis, evaluation, and the use of complementary and procedural management. *J Am Acad Dermatol* 2019; 81: 76–90.
10. Ingram JR, Collier F, Brown D, *et al.* British Association of Dermatologists guidelines for the management of hidradenitis suppurativa (acne inversa)2018. *Br J Dermatol* 2019; 180: 1009–1017.
11. Hurley H. Axillary hyperhidrosis, apocrine bromhidrosis, hidradenitis suppurativa, and familial benign pemphigus: surgical approach. In: Roenigk RK and Roenigk HH (eds) *Dermatologic surgery: principles and practice*. New York: Marcel Dekker, 1989, pp. 729–739.
12. Horváth B, Janse IC, Blok JL, *et al.* Hurley staging refined: a proposal by the Dutch

- Hidradenitis Suppurativa Expert Group. *Acta Derm Venereol* 2017; 97: 412–413.
13. Kimball AB, Sobell JM, Zouboulis CC, *et al.* HiSCR (Hidradenitis Suppurativa Clinical Response): a novel clinical endpoint to evaluate therapeutic outcomes in patients with hidradenitis suppurativa from the placebo-controlled portion of a phase 2 adalimumab study. *J Eur Acad Dermatol Venereol* 2016; 30: 989–994.
 14. Zouboulis CC, Tzellos T, Kyrgidis A, *et al.* Development and validation of the International Hidradenitis Suppurativa Severity Score System (IHS4), a novel dynamic scoring system to assess HS severity. *Br J Dermatol* 2017; 177: 1401–1409.
 15. Tricarico PM, Boniotto M, Genovese G, *et al.* An integrated approach to unravel hidradenitis suppurativa etiopathogenesis. *Front Immunol* 2019; 10: 892.
 16. Jfri AH, O'Brien EA, Litvinov IV, *et al.* Hidradenitis suppurativa: comprehensive review of predisposing genetic mutations and changes. *J Cutan Med Surg* 2019; 23: 519–527.
 17. Wang Z, Yan Y and Wang B. γ -secretase genetics of hidradenitis suppurativa: a systematic literature review. *Dermatology* 2021; 237: 698–704.
 18. Vekic DA, Frew J and Cains GD. Hidradenitis suppurativa, a review of pathogenesis, associations and management. Part 1. *Australas J Dermatol* 2018; 59: 267–277.
 19. Frew JW, Vekic DA, Woods J, *et al.* A systematic review and critical evaluation of reported pathogenic sequence variants in hidradenitis suppurativa. *Br J Dermatol* 2017; 177: 987–998.
 20. Vellaichamy G, Dimitrion P, Zhou L, *et al.* Insights from γ -secretase: functional genetics of hidradenitis suppurativa. *J Invest Dermatol* 2021; 141: 1888–1896.
 21. Wang B, Yang W, Wen W, *et al.* Gamma-secretase gene mutations in familial acne inversa. *Science* 2010; 330: 1065.
 22. Nomura T. Hidradenitis suppurativa as a potential subtype of autoinflammatory keratinization disease. *Front Immunol* 2020; 11: 847.
 23. González-Villanueva I, Gutiérrez M, Hispán P, *et al.* Novel POFUT1 mutation associated with hidradenitis suppurativa-Dowling-Degos disease firm up a role for Notch signalling in the pathogenesis of this disorder. *Br J Dermatol* 2018; 178: 984–986.
 24. Pavlovsky M, Sarig O, Eskin-Schwartz M, *et al.* A phenotype combining hidradenitis suppurativa with Dowling-Degos disease caused by a founder mutation in PSENEN. *Br J Dermatol* 2018; 178: 502–508.
 25. Garcovich S, Tricarico PM, Nait-Meddour C, *et al.* Novel nicastrin mutation in hidradenitis suppurativa-Dowling-Degos disease clinical phenotype: more than just clinical overlap? *Br J Dermatol* 2020; 183: 758–759.
 26. Vural S, Gundogdu M, Kundakci N, *et al.* Familial Mediterranean fever patients with hidradenitis suppurativa. *Int J Dermatol* 2017; 56: 660–663.
 27. Vural S, Gündoğdu M, Gökpınar İli E, *et al.* Association of pyrin mutations and autoinflammation with complex phenotype hidradenitis suppurativa: a case-control study. *Br J Dermatol* 2019; 180: 1459–1467.
 28. Calderón-Castrat X, Bancalari-Díaz D, Román-Curto C, *et al.* PSTPIP1 gene mutation in a pyoderma gangrenosum, acne and suppurative hidradenitis (PASH) syndrome. *Br J Dermatol* 2016; 175: 194–198.
 29. Marzano AV, Trevisan V, Gattorno M, *et al.* Pyogenic arthritis, pyoderma gangrenosum, acne, and hidradenitis suppurativa (PAPASH): a new autoinflammatory syndrome associated with a novel mutation of the PSTPIP1 gene. *JAMA Dermatol* 2013; 149: 762–764.
 30. Marzano AV, Damiani G, Ceccherini I, *et al.* Autoinflammation in pyoderma gangrenosum and its syndromic form (pyoderma gangrenosum, acne and suppurative hidradenitis). *Br J Dermatol* 2017; 176: 1588–1598.
 31. Boer J and Jemec GBE. Mechanical stress and the development of pseudo-comedones and tunnels in hidradenitis suppurativa/acne inversa. *Exp Dermatol* 2016; 25: 396–397.
 32. Shlyankevich J, Chen AJ, Kim GE, *et al.* Hidradenitis suppurativa is a systemic disease with substantial comorbidity burden: a chart-verified case-control analysis. *J Am Acad Dermatol* 2014; 71: 1144–1150.
 33. Gold DA, Reeder VJ, Mahan MG, *et al.* The prevalence of metabolic syndrome in patients with hidradenitis suppurativa. *J Am Acad Dermatol* 2014; 70: 699–703.
 34. Danby FW. Diet in the prevention of hidradenitis suppurativa (acne inversa). *J Am Acad Dermatol* 2015; 73(5, Suppl. 1): S52–S54.

35. Garg A, Papagermanos V, Midura M, *et al.* Incidence of hidradenitis suppurativa among tobacco smokers: a population-based retrospective analysis in the U.S.A. *Br J Dermatol* 2018; 178: 709–714.
36. Karagiannidis I, Nikolakis G, Sabat R, *et al.* Hidradenitis suppurativa/acne inversa: an endocrine skin disorder? *Rev Endocr Metab Disord* 2016; 17: 335–341.
37. Tzellos T and Zouboulis CC. Review of comorbidities of hidradenitis suppurativa: implications for daily clinical practice. *Dermatol Ther* 2020; 10: 63–71.
38. Langan EA, Recke A, Bokor-Billmann T, *et al.* The role of the cutaneous microbiome in hidradenitis suppurativa – light at the end of the microbiological tunnel. *Int J Mol Sci* 2020; 21: 1205.
39. Ring HC, Bay L, Nilsson M, *et al.* Bacterial biofilm in chronic lesions of hidradenitis suppurativa. *Br J Dermatol* 2017; 176: 993–1000.
40. Prens E and Deckers I. Pathophysiology of hidradenitis suppurativa: an update. *J Am Acad Dermatol* 2015; 73(5, Suppl. 1): S8–S11.
41. Seyed Jafari SM, Hunger RE and Schlapbach C. Hidradenitis suppurativa: current understanding of pathogenic mechanisms and suggestion for treatment algorithm. *Front Med* 2020; 7: 68.
42. Goldburg SR, Strober BE and Payette MJ. Hidradenitis suppurativa: epidemiology, clinical presentation, and pathogenesis. *J Am Acad Dermatol* 2020; 82: 1045–1058.
43. van der Zee HH, de Ruiter L, van den Broecke DG, *et al.* Elevated levels of tumour necrosis factor (TNF)- α , interleukin (IL)-1 β and IL-10 in hidradenitis suppurativa skin: a rationale for targeting TNF- α and IL-1 β . *Br J Dermatol* 2011; 164: 1292–1298.
44. Witte-Händel E, Wolk K, Tsaousi A, *et al.* The IL-1 pathway is hyperactive in hidradenitis suppurativa and contributes to skin infiltration and destruction. *J Invest Dermatol* 2019; 139: 1294–1305.
45. Lu JD, Milakovic M, Ortega-Loayza AG, *et al.* Pyoderma gangrenosum: proposed pathogenesis and current use of biologics with an emphasis on complement C5a inhibitor IFX-1. *Expert Opin Investig Drugs* 2020; 29: 1179–1185.
46. Zouboulis CC, Frew JW, Giamarellos-Bourboulis EJ, *et al.* Target molecules for future hidradenitis suppurativa treatment. *Exp Dermatol* 2021; 30(Suppl. 1): 8–17.
47. Giamarellos-Bourboulis EJ, Argyropoulou M, Kanni T, *et al.* Clinical efficacy of complement C5a inhibition by IFX-1 in hidradenitis suppurativa: an open-label single-arm trial in patients not eligible for adalimumab. *Br J Dermatol* 2020; 183: 176–178.
48. Balato A, Caiazza G, Annunziata MC, *et al.* Anti-TNF- α therapy modulates mTORC1 signalling in hidradenitis suppurativa. *J Eur Acad Dermatol Venereol* 2019; 33: e43–e45.
49. Jiménez-Gallo D, de la Varga-Martínez R, Ossorio-García L, *et al.* Effects of adalimumab on T-helper-17 lymphocyte- and neutrophil-related inflammatory serum markers in patients with moderate-to-severe hidradenitis suppurativa. *Cytokine* 2018; 103: 20–24.
50. Matusiak Ł, Szczęch J, Bieniek A, *et al.* Increased interleukin (IL)-17 serum levels in patients with hidradenitis suppurativa: implications for treatment with anti-IL-17 agents. *J Am Acad Dermatol* 2017; 76: 670–675.
51. Schlapbach C, Hänni T, Yawalkar N, *et al.* Expression of the IL-23/Th17 pathway in lesions of hidradenitis suppurativa. *J Am Acad Dermatol* 2011; 65: 790–798.
52. Moran B, Sweeney CM, Hughes R, *et al.* Hidradenitis suppurativa is characterized by dysregulation of the Th17:Treg cell axis, which is corrected by anti-TNF therapy. *J Invest Dermatol* 2017; 137: 2389–2395.
53. Navrazhina K, Frew JW, Gilleaudeau P, *et al.* Epithelialized tunnels are a source of inflammation in hidradenitis suppurativa. *J Allergy Clin Immunol* 2021; 147: 2213–2224.
54. Kidacki M, Cong Z, Flamm A, *et al.* ‘Invasive proliferative gelatinous mass’ of hidradenitis suppurativa contains distinct inflammatory components. *Br J Dermatol* 2019; 181: 192–193.
55. Kanni T, Tzanetakou V, Savva A, *et al.* Compartmentalized cytokine responses in hidradenitis suppurativa. *PLoS ONE* 2015; 10: e0130522.
56. Alikhan A, Sayed C, Alavi A, *et al.* North American clinical management guidelines for hidradenitis suppurativa: a publication from the United States and Canadian Hidradenitis Suppurativa Foundations: part II: topical, intralesional, and systemic medical management. *J Am Acad Dermatol* 2019; 81: 91–101.

57. Clemmensen OJ. Topical treatment of hidradenitis suppurativa with clindamycin. *Int J Dermatol* 1983; 22: 325–328.
58. Jemec GB and Wendelboe P. Topical clindamycin versus systemic tetracycline in the treatment of hidradenitis suppurativa. *J Am Acad Dermatol* 1998; 39: 971–974.
59. Pereira MN, Tolentino S, Pires FQ, *et al.* Nanostructured lipid carriers for hair follicle-targeted delivery of clindamycin and rifampicin to hidradenitis suppurativa treatment. *Colloids Surf B Biointerfaces* 2021; 197: 111448.
60. Bettoli V, Manfredini M, Massoli L, *et al.* Rates of antibiotic resistance/sensitivity in bacterial cultures of hidradenitis suppurativa patients. *J Eur Acad Dermatol Venereol* 2019; 33: 930–936.
61. Molinelli E, Brisigotti V, Simonetti O, *et al.* Efficacy and safety of topical resorcinol 15% as long-term treatment of mild-to-moderate hidradenitis suppurativa: a valid alternative to clindamycin in the panorama of antibiotic resistance. *Br J Dermatol* 2020; 183: 1117–1119.
62. Wake Forest University Health Sciences. Effects of gentian violet treatment on patients with hidradenitis suppurativa. Clinical Trial Registration NCT04388163, clinicaltrials.gov, <https://clinicaltrials.gov/ct2/show/NCT04388163> (2021, accessed 29 April 2021).
63. Lev-Tov H. The microbiome of hidradenitis suppurativa (HS) tunneling wounds. Clinical Trial Registration NCT04648631, clinicaltrials.gov, <https://clinicaltrials.gov/ct2/show/NCT04648631> (2021, accessed 29 April 2021).
64. Kirby JS and Milton S. Exploratory trial of ruxolitinib 1.5% cream for the treatment of early stage hidradenitis suppurativa. Clinical Trial Registration NCT04414514, clinicaltrials.gov, <https://clinicaltrials.gov/ct2/show/NCT04414514> (2021, accessed 14 April 2021).
65. van Straalen KR, Tzellos T, Guillem P, *et al.* The efficacy and tolerability of tetracyclines and clindamycin plus rifampicin for the treatment of hidradenitis suppurativa; results of a prospective European cohort study. *J Am Acad Dermatol* 2021; 85: 369–378.
66. Caposiena Caro RD, Molinelli E, Brisigotti V, *et al.* Lymecycline vs. clindamycin plus rifampicin in hidradenitis suppurativa treatment: clinical and ultrasonography evaluation. *Clin Exp Dermatol* 2021; 46: 96–102.
67. Iannone M, Janowska A, Bartolomei G, *et al.* Systemic antibiotics in hidradenitis suppurativa: efficacy and effects of body mass index and smoking pack-year on the response to therapy. *Dermatol Ther* 2021; 34: e14919.
68. Hambly R and Kirby B. Prolonged clindamycin and rifampicin for hidradenitis suppurativa: resist to prevent resistance. *Br J Dermatol* 2019; 180: 702–703.
69. Yao Y, Jørgensen A-HR, Ring HC, *et al.* Effectiveness of clindamycin and rifampicin combination therapy in hidradenitis suppurativa: a 6-month prospective study. *Br J Dermatol* 2021; 184: 552–553.
70. Zouboulis CC, Bechara FG, Dickinson-Blok JL, *et al.* Hidradenitis suppurativa/acne inversa: a practical framework for treatment optimization – systematic review and recommendations from the HS ALLIANCE working group. *J Eur Acad Dermatol Venereol* 2019; 33: 19–31.
71. Marasca C, Annunziata MC, Villani A, *et al.* Adalimumab versus rifampicin plus clindamycin for the treatment of moderate to severe hidradenitis suppurativa: a retrospective study. *J Drugs Dermatol* 2019; 18: 437–438.
72. Delaunay J, Villani AP, Guillem P, *et al.* Oral ofloxacin and clindamycin as an alternative to the classic rifampicin-clindamycin in hidradenitis suppurativa: retrospective analysis of 65 patients. *Br J Dermatol* 2018; 178: e15–e16.
73. Join-Lambert O, Coignard H, Jais J-P, *et al.* Efficacy of rifampin-moxifloxacin-metronidazole combination therapy in hidradenitis suppurativa. *Dermatology* 2011; 222: 49–58.
74. Delage M, Jais J-P, Lam T, *et al.* Rifampin-moxifloxacin-metronidazole combination therapy for severe Hurley stage 1 hidradenitis suppurativa: prospective short-term trial and one-year follow-up in 28 consecutive patients. *J Am Acad Dermatol*. Epub ahead of print 10 January 2020. DOI: 10.1016/j.jaad.2020.01.007.
75. Matusiak L, Bieniek A and Szepletowski JC. Acitretin treatment for hidradenitis suppurativa: a prospective series of 17 patients. *Br J Dermatol* 2014; 171: 170–174.
76. Puri N and Talwar A. A study on the management of hidradenitis suppurativa with retinoids and surgical excision. *Indian J Dermatol* 2011; 56: 650–651.
77. Boer J and Nazary M. Long-term results of acitretin therapy for hidradenitis suppurativa. Is acne inversa also a misnomer? *Br J Dermatol* 2011; 164: 170–175.

78. Chu S, Michelle L, Ekelem C, *et al.* Oral isotretinoin for the treatment of dermatologic conditions other than acne: a systematic review and discussion of future directions. *Arch Dermatol Res* 2021; 313: 391–430.
79. Verdolini R, Simonacci F, Menon S, *et al.* Alitretinoin: a useful agent in the treatment of hidradenitis suppurativa, especially in women of child-bearing age. *G Ital Dermatol Venereol* 2015; 150: 155–162.
80. Prens LM, Porter ML, Savage KT, *et al.* Hidradenitis suppurativa disease course during pregnancy and postpartum: a retrospective survey study. *Br J Dermatol*. Epub ahead of print 24 March 2021. DOI: 10.1111/bjd.20078.
81. Riis PT, Ring HC, Themstrup L, *et al.* The role of androgens and estrogens in hidradenitis suppurativa – a systematic review. *Acta Dermatovenerol Croat* 2016; 24: 239–249.
82. Nikolakis G, Kyrgidis A and Zouboulis CC. Is there a role for antiandrogen therapy for hidradenitis suppurativa? A systematic review of published data. *Am J Clin Dermatol* 2019; 20: 503–513.
83. Mortimer PS, Dawber RP, Gales MA, *et al.* A double-blind controlled cross-over trial of cyproterone acetate in females with hidradenitis suppurativa. *Br J Dermatol* 1986; 115: 263–268.
84. Jennings L, Hambly R, Hughes R, *et al.* Metformin use in hidradenitis suppurativa. *J Dermatolog Treat* 2020; 31: 261–263.
85. van Straalen KR. Rediscovery of metformin for the chronic disabling auto-inflammatory disease hidradenitis suppurativa. Clinical Trial Registration NCT04649502, clinicaltrials.gov, <https://clinicaltrials.gov/ct2/show/NCT04649502> (2020, accessed 29 April 2021).
86. Khandalavala BN and Do MV. Finasteride in hidradenitis suppurativa: a ‘male’ therapy for a predominantly ‘female’ disease. *J Clin Aesthet Dermatol* 2016; 9: 44–50.
87. Joseph MA, Jayaseelan E, Ganapathi B, *et al.* Hidradenitis suppurativa treated with finasteride. *J Dermatolog Treat* 2005; 16: 75–78.
88. Randhawa HK, Hamilton J and Pope E. Finasteride for the treatment of hidradenitis suppurativa in children and adolescents. *JAMA Dermatol* 2013; 149: 732–735.
89. Mota F, Machado S and Selores M. Hidradenitis suppurativa in children treated with finasteride – a case series. *Pediatr Dermatol* 2017; 34: 578–583.
90. Vossen ARJV, Ardon CB, van der Zee HH, *et al.* The anti-inflammatory potency of biologics targeting tumour necrosis factor- α , interleukin (IL)-17A, IL-12/23 and CD20 in hidradenitis suppurativa: an ex vivo study. *Br J Dermatol* 2019; 181: 314–323.
91. Riis PT, Boer J, Prens EP, *et al.* Intralesional triamcinolone for flares of hidradenitis suppurativa (HS): a case series. *J Am Acad Dermatol* 2016; 75: 1151–1155.
92. Arenbergerova M, Gkalpakiotis S, Marques E, *et al.* Corticosteroid rescue therapy in relapsing hidradenitis suppurativa treated with adalimumab. *J Eur Acad Dermatol Venereol* 2021; 35: e381–e383.
93. Luis S-R, Salvador A-S and Alejandro M-L. Ultrasound-assisted intralesional corticosteroid infiltrations for patients with hidradenitis suppurativa. *Sci Rep* 2020; 10: 13363.
94. García-Martínez FJ, Vilarrasa Rull E, Salgado-Boquete L, *et al.* Intralesional corticosteroid injection for the treatment of hidradenitis suppurativa: a multicenter retrospective clinical study. *J Dermatolog Treat* 2021; 32: 286–290.
95. Fania L, Clemente A, Sampogna F, *et al.* Intralesional ultrasound-guided combined treatment with triamcinolone plus lincomycin in hidradenitis suppurativa: a pilot study. *Dermatol Ther* 2020; 33: e13901.
96. Fajgenbaum K, Crouse L, Dong L, *et al.* Intralesional triamcinolone may not be beneficial for treating acute hidradenitis suppurativa lesions: a double-blind, randomized, placebo-controlled trial. *Dermatol Surg* 2020; 46: 685–689.
97. Saunte DML and Jemec GBE. Intralesional triamcinolone for hidradenitis suppurativa-how much is needed? *Dermatol Surg* 2021; 47: 1013–1014.
98. Montefiore Medical Center. Optimizing intralesional triamcinolone dosing for hidradenitis suppurativa. Clinical Trial Registration NCT04582669, clinicaltrials.gov, <https://clinicaltrials.gov/ct2/show/NCT04582669> (2021, accessed 29 April 2021).
99. Wong D, Walsh S and Alhusayen R. Low-dose systemic corticosteroid treatment for recalcitrant hidradenitis suppurativa. *J Am Acad Dermatol* 2016; 75: 1059–1062.
100. Mehdizadeh A, Hazen PG, Bechara FG, *et al.* Recurrence of hidradenitis suppurativa after surgical management: a systematic review and

- meta-analysis. *J Am Acad Dermatol* 2015; 73(5, Suppl. 1): S70–S77.
101. van der Zee HH, Prens EP and Boer J. Deroofing: a tissue-saving surgical technique for the treatment of mild to moderate hidradenitis suppurativa lesions. *J Am Acad Dermatol* 2010; 63: 475–480.
 102. Manfredini M, Garbarino F, Bigi L, *et al.* Hidradenitis suppurativa: surgical and postsurgical management. *Skin Appendage Disord* 2020; 6: 195–201.
 103. Dahmen RA, Gkalpakiotis S, Mardesicova L, *et al.* Deroofing followed by thorough sinus tract excision: a modified surgical approach for hidradenitis suppurativa. *J Dtsch Dermatol Ges* 2019; 17: 698–702.
 104. Ovadja ZN, Zugaj M, Jacobs W, *et al.* Recurrence rates following reconstruction strategies after wide excision of hidradenitis suppurativa: a systematic review and meta-analysis. *Dermatol Surg* 2021; 47: e106–e110.
 105. Shanmugam VK, Mulani S, McNish S, *et al.* Longitudinal observational study of hidradenitis suppurativa: impact of surgical intervention with adjunctive biologic therapy. *Int J Dermatol* 2018; 57: 62–69.
 106. Gracia Cazaña T, Berdel Díaz LV, Martín Sánchez JI, *et al.* Systematic review of light-based treatments for hidradenitis suppurativa. *Actas Dermosifiliogr* 2020; 111: 89–106.
 107. Lyons AB, Townsend SM, Turk D, *et al.* Laser and light-based treatment modalities for the management of hidradenitis suppurativa. *Am J Clin Dermatol* 2020; 21: 237–243.
 108. Mahmoud BH, Tierney E, Hexsel CL, *et al.* Prospective controlled clinical and histopathologic study of hidradenitis suppurativa treated with the long-pulsed neodymium:yttrium-aluminium-garnet laser. *J Am Acad Dermatol* 2010; 62: 637–645.
 109. Abdel Azim AA, Salem RT and Abdelghani R. Combined fractional carbon dioxide laser and long-pulsed neodymium : yttrium-aluminium-garnet (1064 nm) laser in treatment of hidradenitis suppurativa; a prospective randomized intra-individual controlled study. *Int J Dermatol* 2018; 57: 1135–1144.
 110. Madan V, Hindle E, Hussain W, *et al.* Outcomes of treatment of nine cases of recalcitrant severe hidradenitis suppurativa with carbon dioxide laser. *Br J Dermatol* 2008; 159: 1309–1314.
 111. Daveluy SD. Treatment of hidradenitis suppurativa with Eth 755 nm alexandrite laser. Clinical Trial Registration NCT03054155, clinicaltrials.gov, <https://clinicaltrials.gov/ct2/show/NCT03054155> (2020, accessed 29 April 2021).
 112. Agut-Busquet E, Romani J, Gilaberte Y, *et al.* Photodynamic therapy with intralesional methylene blue and a 635 nm light-emitting diode lamp in hidradenitis suppurativa: a retrospective follow-up study in 7 patients and a review of the literature. *Photochem Photobiol Sci* 2016; 15: 1020–1028.
 113. Tricarico PM, Zupin L, Ottaviani G, *et al.* Photobiomodulation as potential novel third line tool for non-invasive treatment of hidradenitis suppurativa. *G Ital Dermatol Venereol* 2020; 155: 88–98.
 114. Goldberg SR, Strober BE and Payette MJ. Hidradenitis suppurativa: current and emerging treatments. *J Am Acad Dermatol* 2020; 82: 1061–1082.
 115. Kimball AB, Okun MM, Williams DA, *et al.* Two phase 3 trials of adalimumab for hidradenitis suppurativa. *N Engl J Med* 2016; 375: 422–434.
 116. Zouboulis CC, Okun MM, Prens EP, *et al.* Long-term adalimumab efficacy in patients with moderate-to-severe hidradenitis suppurativa/ acne inversa: 3-year results of a phase 3 open-label extension study. *J Am Acad Dermatol* 2019; 80: 60–69.e2.
 117. Morita A, Takahashi H, Ozawa K, *et al.* Long-term analysis of adalimumab in Japanese patients with moderate to severe hidradenitis suppurativa: open-label phase 3 results. *J Dermatol* 2021; 48: 3–13.
 118. van der Zee HH, Longcore M, Geng Z, *et al.* Weekly adalimumab treatment decreased disease flare in hidradenitis suppurativa over 36 weeks: integrated results from the phase 3 PIONEER trials. *J Eur Acad Dermatol Venereol* 2020; 34: 1050–1056.
 119. Caposiena Caro RD, Cannizzaro MV, Tartaglia C, *et al.* Clinical response rate and flares of hidradenitis suppurativa in the treatment with adalimumab. *Clin Exp Dermatol* 2020; 45: 438–444.
 120. Marzano AV, Genovese G, Casazza G, *et al.* Evidence for a ‘window of opportunity’ in hidradenitis suppurativa treated with adalimumab: a retrospective, real-life

- multicentre cohort study. *Br J Dermatol* 2021; 184: 133–140.
121. Muralidharan V, Pathmarajah P, Peterknecht E, *et al.* Real life data on the biopsychosocial effects of adalimumab in the management of hidradenitis suppurativa: a multicenter cross sectional analysis and consideration of a multisystem monitoring approach to follow up. *Dermatol Ther* 2021; 34: e14643.
 122. Jemec GBE, Okun MM, Forman SB, *et al.* Adalimumab medium-term dosing strategy in moderate-to-severe hidradenitis suppurativa: integrated results from the phase III randomized placebo-controlled PIONEER trials. *Br J Dermatol* 2019; 181: 967–975.
 123. Zouboulis CC, Hansen H, Caposiena Caro RD, *et al.* Adalimumab dose intensification in recalcitrant hidradenitis suppurativa/acne inversa. *Dermatology* 2020; 236: 25–30.
 124. Ricceri F, Rosi E, Di Cesare A, *et al.* Clinical experience with adalimumab biosimilar imraldi in hidradenitis suppurativa. *Dermatol Ther* 2020; 33: e14387.
 125. Cao Y, Hong F, Conlon DM, *et al.* Potential predictive biomarkers of adalimumab response in patients with hidradenitis suppurativa. *Br J Dermatol* 2021; 185: 804–814.
 126. Grant A, Gonzalez T, Montgomery MO, *et al.* Infliximab therapy for patients with moderate to severe hidradenitis suppurativa: a randomized, double-blind, placebo-controlled crossover trial. *J Am Acad Dermatol* 2010; 62: 205–217.
 127. Oskardmay AN, Miles JA and Sayed CJ. Determining the optimal dose of infliximab for treatment of hidradenitis suppurativa. *J Am Acad Dermatol* 2019; 81: 702–708.
 128. Ghias MH, Johnston AD, Kutner AJ, *et al.* High-dose, high-frequency infliximab: a novel treatment paradigm for hidradenitis suppurativa. *J Am Acad Dermatol* 2020; 82: 1094–1101.
 129. Adelman M, Lyons AB and Hamzavi IH. Comment on ‘High-dose, high-frequency infliximab: a novel treatment paradigm for hidradenitis suppurativa’. *J Am Acad Dermatol* 2021; 84: e201–e202.
 130. Westerkam LL, Tackett KJ and Sayed CJ. Comparing the effectiveness and safety associated with infliximab vs infliximab-abda therapy for patients with hidradenitis suppurativa. *JAMA Dermatol* 2021; 157: 708–711.
 131. Prens LM, Bouwman K, Aarts P, *et al.* Adalimumab and infliximab survival in patients with hidradenitis suppurativa: a daily practice cohort study. *Br J Dermatol* 2021; 185: 177–184.
 132. Sand FL and Thomsen SF. Off-label use of TNF-alpha inhibitors in a dermatological university department: retrospective evaluation of 118 patients. *Dermatol Ther* 2015; 28: 158–165.
 133. Tampouratzi E, Kanni T, Katsantonis J, *et al.* Case report: treating a co-existence of hidradenitis suppurativa and psoriasis with different therapeutic approaches. *F1000Res* 2019; 88: 2002.
 134. Holm JG, Jørgensen A-HR, Yao Y, *et al.* Certolizumab pegol for hidradenitis suppurativa: case report and literature review. *Dermatol Ther* 2020; 33: e14494.
 135. Esme P, Akoglu G and Caliskan E. Rapid response to certolizumab pegol in hidradenitis suppurativa: a case report. *Skin Appendage Disord* 2021; 7: 58–61.
 136. Wohlmuth-Wieser I and Alhusayen R. Treatment of hidradenitis suppurativa with certolizumab pegol during pregnancy. *Int J Dermatol* 2021; 60: e140–e141.
 137. Clowse MEB, Scheuerle AE, Chambers C, *et al.* Pregnancy outcomes after exposure to certolizumab pegol: updated results from a pharmacovigilance safety database. *Arthritis Rheumatol* 2018; 70: 1399–1407.
 138. Lee RA, Dommasch E, Treat J, *et al.* A prospective clinical trial of open-label etanercept for the treatment of hidradenitis suppurativa. *J Am Acad Dermatol* 2009; 60: 565–573.
 139. van der Zee HH and Prens EP. Failure of anti-interleukin-1 therapy in severe hidradenitis suppurativa: a case report. *Dermatology* 2013; 226: 97–100.
 140. Tursi A. Concomitant hidradenitis suppurativa and pyostomatitis vegetans in silent ulcerative colitis successfully treated with golimumab. *Dig Liver Dis* 2016; 48: 1511–1512.
 141. Prussick L, Rothstein B, Joshipura D, *et al.* Open-label, investigator-initiated, single-site exploratory trial evaluating secukinumab, an anti-interleukin-17A monoclonal antibody, for patients with moderate-to-severe hidradenitis suppurativa. *Br J Dermatol* 2019; 181: 609–611.
 142. Casseres RG, Prussick L, Zancanaro P, *et al.* Secukinumab in the treatment of moderate-to-severe

- hidradenitis suppurativa: results of an open-label trial. *J Am Acad Dermatol* 2020; 82: 1524–1526.
143. Reguiaï Z, Fougerousse AC, Maccari F, *et al.* Effectiveness of secukinumab in hidradenitis suppurativa: an open study (20 cases). *J Eur Acad Dermatol Venereol* 2020; 34: e750–e751.
 144. Shalom G, Freud T, Ben Yakov G, *et al.* Hidradenitis suppurativa and inflammatory bowel disease: a cross-sectional study of 3,207 patients. *J Invest Dermatol* 2016; 136: 1716–1718.
 145. Ribero S, Ramondetta A, Fabbrocini G, *et al.* Effectiveness of secukinumab in the treatment of moderate-severe hidradenitis suppurativa: results from an Italian multicentric retrospective study in a real-life setting. *J Eur Acad Dermatol Venereol* 2021; 35: e441–e442.
 146. Novartis Pharmaceuticals. A randomized, double-blind, multicenter study assessing short (16 weeks) and long-term efficacy (up to 1 year), safety, and tolerability of 2 subcutaneous secukinumab dose regimens in adult patients with moderate to severe hidradenitis suppurativa (SUNRISE). Clinical Trial Registration NCT03713632, clinicaltrials.gov, <https://clinicaltrials.gov/ct2/show/NCT03713632> (2021, accessed 11 April 2021).
 147. Novartis Pharmaceuticals. A randomized, double-blind, multi-center study assessing short (16 weeks) and long-term efficacy (up to 1 year), safety, and tolerability of 2 subcutaneous secukinumab dose regimens in adult patients with moderate to severe hidradenitis suppurativa (SUNSHINE). Clinical Trial Registration NCT03713619, clinicaltrials.gov, <https://clinicaltrials.gov/ct2/show/NCT03713619> (2021, accessed 11 April 2021).
 148. Novartis Pharmaceuticals. A multicenter, double-blind, randomized withdrawal extension study of subcutaneous secukinumab to demonstrate long-term efficacy, safety and tolerability in subjects with moderate to severe hidradenitis suppurativa. Clinical Trial Registration NCT04179175, clinicaltrials.gov, <https://clinicaltrials.gov/ct2/show/NCT04179175> (2021, accessed 11 April 2021).
 149. Marasca C, Megna M, Balato A, *et al.* Secukinumab and hidradenitis suppurativa: friends or foes? *JAAD Case Rep* 2019; 5: 184–187.
 150. Yoshida Y, Oyama N, Iino S, *et al.* Long-standing refractory hidradenitis suppurativa responded to a brodalumab monotherapy in a patient with psoriasis: a possible involvement of Th17 across the spectrum of both diseases. *J Dermatol* 2021; 48: 916–920.
 151. Arenbergerova M, Arenberger P, Marques E, *et al.* Successful treatment of recalcitrant gluteal hidradenitis suppurativa with brodalumab after anti-TNF failure. *Int J Dermatol* 2020; 59: 733–735.
 152. Frew JW, Navrazhina K, Grand D, *et al.* The effect of subcutaneous brodalumab on clinical disease activity in hidradenitis suppurativa: an open-label cohort study. *J Am Acad Dermatol* 2020; 83: 1341–1348.
 153. Frew JW, Navrazhina K, Sullivan-Whalen M, *et al.* Weekly administration of brodalumab in hidradenitis suppurativa: an open-label cohort study. *Br J Dermatol* 2021; 184: 350–352.
 154. Adams R, Maroof A, Baker T, *et al.* Bimekizumab, a novel humanized IgG1 antibody that neutralizes both IL-17A and IL-17F. *Front Immunol* 2020; 11: 1894.
 155. Glatt S, Jemec GBE, Forman S, *et al.* Efficacy and safety of bimekizumab in moderate to severe hidradenitis suppurativa: a phase 2, double-blind, placebo-controlled randomized clinical trial. *JAMA Dermatol*. Epub ahead of print 18 August 2021. DOI: 10.1001/jamadermatol.2021.2905.
 156. UCB Biopharma SRL. A phase 3, randomized, double-blind, placebo-controlled, multicenter study evaluating the efficacy and safety of bimekizumab in study participants with moderate to severe hidradenitis suppurativa. Clinical Trial Registration NCT04242446, clinicaltrials.gov, <https://clinicaltrials.gov/ct2/show/NCT04242446> (2021, accessed 11 April 2021).
 157. UCB Biopharma SRL. A phase 3, randomized, double-blind, placebo-controlled, multicenter study evaluating the efficacy and safety of bimekizumab in study participants with moderate to severe hidradenitis suppurativa. Clinical Trial Registration NCT04242498, clinicaltrials.gov, <https://clinicaltrials.gov/ct2/show/NCT04242498> (2021, accessed 11 April 2021).
 158. Odorici G, Pellacani G and Conti A. Ixekizumab in hidradenitis suppurativa in a psoriatic patient. *G Ital Dermatol Venereol* 2020; 155: 788–789.
 159. Megna M, Ruggiero A, Di Guida A, *et al.* Ixekizumab: an efficacious treatment for both

- psoriasis and hidradenitis suppurativa. *Dermatol Ther* 2020; 33: e13756.
160. Reardon K, Levin J and Levin C. Severe hidradenitis suppurativa with herpes simplex virus 1 superinfection and clinical responsiveness to ixekizumab. *JAAD Case Rep* 2021; 9: 7–8.
 161. Kaul M, Jarvis P, Rozenberg I, *et al.* First-in-human study demonstrating the safety and clinical efficacy of novel anti-IL-17A monoclonal antibody CJM112 in moderate to severe plaque psoriasis. *J Eur Acad Dermatol Venereol* 2021; 35: 1143–1151.
 162. Novartis Pharmaceuticals. A randomized, double-blind, placebo controlled, multiple dose study to evaluate the clinical efficacy, safety, tolerability, dose relation, pharmacokinetics and pharmacodynamics of CJM112 in moderate to severe chronic hidradenitis suppurativa patients. Clinical Trial Registration NCT02421172, [clinicaltrials.gov, https://clinicaltrials.gov/ct2/show/NCT02421172](https://clinicaltrials.gov/ct2/show/NCT02421172) (2020, accessed 11 April 2021).
 163. Kimball AB, Prens E, Bechara FG, *et al.* Hidradenitis suppurativa responds to a novel anti-IL17 antibody (CJM112) in a controlled clinical trial vs placebo. In: *24th World Congress of dermatology*, Milan, 10–15 June 2019.
 164. Blok JL, Li K, Brodmerkel C, *et al.* Ustekinumab in hidradenitis suppurativa: clinical results and a search for potential biomarkers in serum. *Br J Dermatol* 2016; 174: 839–846.
 165. Gulliver WP, Jemec GBE and Baker KA. Experience with ustekinumab for the treatment of moderate to severe hidradenitis suppurativa. *J Eur Acad Dermatol Venereol* 2012; 26: 911–914.
 166. Sharon VR, Garcia MS, Bagheri S, *et al.* Management of recalcitrant hidradenitis suppurativa with ustekinumab. *Acta Derm Venereol* 2012; 92: 320–321.
 167. Santos-Pérez MI, García-Rodicio S, Del Olmo-Revuelto MA, *et al.* Ustekinumab for hidradenitis suppurativa: a case report. *Actas Dermosifiliogr* 2014; 105: 720–722.
 168. Eisen DB. Ustekinumab, another biologic with potential to help patients with hidradenitis suppurativa? *Br J Dermatol* 2016; 174: 718–719.
 169. Scholl L, Hessam S, Garcovich S, *et al.* High-dosage ustekinumab for the treatment of severe hidradenitis suppurativa. *Eur J Dermatol* 2019; 29: 659–661.
 170. Takeda K, Kikuchi K, Kanazawa Y, *et al.* Ustekinumab treatment for hidradenitis suppurativa. *J Dermatol* 2019; 46: 1215–1218.
 171. Cline A and Pichardo RO. Successful treatment of hidradenitis suppurativa in the setting of Crohn disease with combination adalimumab and ustekinumab. *Dermatol Online J* 2019; 25: 13030.
 172. Montero-Vilchez T, Pozo-Román T, Sánchez-Velicia L, *et al.* Ustekinumab in the treatment of patients with hidradenitis suppurativa: multicenter case series and systematic review. *J Dermatolog Treat*. Epub ahead of print 21 April 2020. DOI: 10.1080/09546634.2020.1755008.
 173. Romani J, Vilarrasa E, Martorell A, *et al.* Ustekinumab with intravenous infusion: results in hidradenitis suppurativa. *Dermatology* 2020; 236: 21–24.
 174. Sánchez-Martínez EM, García-Ruiz R, Moneva-Léniz LM, *et al.* Effectiveness and safety of ustekinumab in patients with hidradenitis suppurativa using intravenous induction. *Dermatol Ther* 2020; 33: e14054.
 175. Valenzuela-Ubiña S, Jiménez-Gallo D, Villegas-Romero I, *et al.* Effectiveness of ustekinumab for moderate-to-severe hidradenitis suppurativa: a case series. *J Dermatolog Treat*. Epub ahead of print 11 June 2020. DOI: 10.1080/09546634.2020.1776208.
 176. Kovacs M and Podda M. Guselkumab in the treatment of severe hidradenitis suppurativa. *J Eur Acad Dermatol Venereol* 2019; 33: e140–e141.
 177. Casseres RG, Kahn JS, Her MJ, *et al.* Guselkumab in the treatment of hidradenitis suppurativa: a retrospective chart review. *J Am Acad Dermatol* 2019; 81: 265–267.
 178. Kearney N, Byrne N, Kirby B, *et al.* Successful use of guselkumab in the treatment of severe hidradenitis suppurativa. *Clin Exp Dermatol* 2020; 45: 618–619.
 179. Berman HS, Villa NM, Shi VY, *et al.* Guselkumab in the treatment of concomitant hidradenitis suppurativa, psoriasis, and Crohn's disease. *J Dermatolog Treat* 2021; 32: 261–263.
 180. Jørgensen A-HR, Holm JG and Thomsen SF. Guselkumab for hidradenitis suppurativa in a patient with concomitant Crohn's disease: report and systematic literature review of effectiveness and safety. *Clin Case Rep* 2020; 8: 2874–2877.
 181. Burzi L, Repetto F, Ramondetta A, *et al.* Guselkumab in the treatment of severe

- hidradenitis suppurativa, a promising role? *Dermatol Ther* 2021; 34: e14930.
182. Montero-Vilchez T, Martínez-Lopez A, Salvador-Rodríguez L, *et al.* The use of guselkumab 100 mg every 4 weeks on patients with hidradenitis suppurativa and a literature review. *Dermatol Ther* 2020; 33: e13456.
 183. Janssen Research & Development, LLC. A phase 2, multicenter, randomized, placebo-controlled, double-blind, proof-of-concept study to evaluate guselkumab for the treatment of subjects with moderate to severe hidradenitis suppurativa. Clinical Trial Registration NCT03628924, [clinicaltrials.gov](https://clinicaltrials.gov/ct2/show/NCT03628924), <https://clinicaltrials.gov/ct2/show/NCT03628924> (2020, accessed 14 April 2021).
 184. Marques E, Arenberger P, Smetanová A, *et al.* Successful treatment of recalcitrant hidradenitis suppurativa with risankizumab after failure of anti-tumour necrosis factor alpha. *Br J Dermatol* 2021; 184: 966–967.
 185. Licata G, Gambardella A, Buononato D, *et al.* A case of moderate hidradenitis suppurativa and psoriasis successfully treated with risankizumab. *Int J Dermatol*. Epub ahead of print 20 June 2021. DOI: 10.1111/ijd.15704.
 186. Caposiena Caro RD, Pensa C, Lambiase S, *et al.* Risankizumab effectiveness in a recalcitrant case of hidradenitis suppurativa after anti-TNF and anti-interleukin-17 failures. *Dermatol Ther*. Epub ahead of print 29 August 2021. DOI: 10.1111/dth.15116.
 187. AbbVie. A phase 2, multicenter, randomized, placebo-controlled, double-blind study to evaluate the safety and efficacy of risankizumab in adult subjects with moderate to severe hidradenitis suppurativa. Clinical Trial Registration NCT03926169, [clinicaltrials.gov](https://clinicaltrials.gov/ct2/show/NCT03926169), <https://clinicaltrials.gov/ct2/show/NCT03926169> (2021, accessed 14 April 2021).
 188. Kok Y, Nicolopoulos J, Howard A, *et al.* Tildrakizumab in the treatment of moderate-to-severe hidradenitis suppurativa. *Australas J Dermatol* 2020; 61: e488–e490.
 189. Leslie KS, Tripathi SV, Nguyen TV, *et al.* An open-label study of anakinra for the treatment of moderate to severe hidradenitis suppurativa. *J Am Acad Dermatol* 2014; 70: 243–251.
 190. Tzanetakou V, Kanni T, Giatrakou S, *et al.* Safety and efficacy of anakinra in severe hidradenitis suppurativa: a randomized clinical trial. *JAMA Dermatol* 2016; 152: 52–59.
 191. André R, Marescaillier H, Gabay C, *et al.* Long-term therapy with anakinra in hidradenitis suppurativa in three patients. *Int J Dermatol* 2019; 58: e208–e209.
 192. Zarchi K, Dufour DN and Jemec GBE. Successful treatment of severe hidradenitis suppurativa with anakinra. *JAMA Dermatol* 2013; 149: 1192–1194.
 193. Hsiao JL, Antaya RJ, Berger T, *et al.* Hidradenitis suppurativa and concomitant pyoderma gangrenosum: a case series and literature review. *Arch Dermatol* 2010; 146: 1265–1270.
 194. Russo V and Alikhan A. Failure of anakinra in a case of severe hidradenitis suppurativa. *J Drugs Dermatol* 2016; 15: 772–774.
 195. Menis D, Maroñas-Jiménez L, Delgado-Marquez AM, *et al.* Two cases of severe hidradenitis suppurativa with failure of anakinra therapy. *Br J Dermatol* 2015; 172: 810–811.
 196. Kanni T, Argyropoulou M, Spyridopoulos T, *et al.* MABp1 targeting IL-1 α for moderate to severe hidradenitis suppurativa not eligible for adalimumab: a randomized study. *J Invest Dermatol* 2018; 138: 795–801.
 197. Kanni T, Argyropoulou M, Dinarello CA, *et al.* MABp1 targeting interleukin-1 α in hidradenitis suppurativa ineligible for adalimumab treatment: results of the open-label extension period. *Clin Exp Dermatol* 2021; 46: 162–163.
 198. Gottlieb A, Natsis NE, Kerdel F, *et al.* A phase II, open label study of bermekimab in patients with hidradenitis suppurativa shows resolution of inflammatory lesions and pain. *J Invest Dermatol* 2020; 140: 1538–1545.
 199. Folkes AS, Hawatmeh FZ, Wong A, *et al.* Emerging drugs for the treatment of hidradenitis suppurativa. *Expert Opin Emerg Drugs* 2020; 25: 201–211.
 200. Houriet C, Seyed Jafari SM, Thomi R, *et al.* Canakinumab for severe hidradenitis suppurativa: preliminary experience in 2 cases. *JAMA Dermatol* 2017; 153: 1195–1197.
 201. Jaeger T, Andres C, Grosber M, *et al.* Pyoderma gangrenosum and concomitant hidradenitis suppurativa—rapid response to canakinumab (anti-IL-1 β). *Eur J Dermatol* 2013; 23: 408–410.
 202. Sun NZ, Ro T, Jolly P, *et al.* Non-response to interleukin-1 antagonist canakinumab in two patients with refractory pyoderma gangrenosum and hidradenitis suppurativa. *J Clin Aesthet Dermatol* 2017; 10: 36–38.

203. Tekin B, Salman A and Ergun T. Hidradenitis suppurativa unresponsive to canakinumab treatment: a case report. *Indian J Dermatol Venereol Leprol* 2017; 83: 615–617.
204. Vossen ARJV, van Doorn MBA, van der Zee HH, *et al.* Apremilast for moderate hidradenitis suppurativa: results of a randomized controlled trial. *J Am Acad Dermatol* 2019; 80: 80–88.
205. Aarts P, Vossen ARJV, van der Zee HH, *et al.* Long-term treatment with apremilast in hidradenitis suppurativa: 2-year follow-up of initial responders. *J Am Acad Dermatol* 2021; 85: 258–260.
206. Vossen ARJV, van der Zee HH, Davelaar N, *et al.* Apremilast for moderate hidradenitis suppurativa: no significant change in lesional skin inflammatory biomarkers. *J Eur Acad Dermatol Venereol* 2019; 33: 761–765.
207. InflaRx GmbH. A randomized, double-blind, placebo-controlled, multicenter phase II study to determine efficacy and safety of IFX-1 in subjects with moderate to severe hidradenitis suppurativa. Clinical Trial Registration results/NCT03487276, [clinicaltrials.gov, https://clinicaltrials.gov/ct2/show/results/NCT03487276](https://clinicaltrials.gov/ct2/show/results/NCT03487276) (2021, accessed 29 April 2021).
208. ChemoCentryx. A randomized, double-blind, placebo-controlled, parallel group, phase 2 study to evaluate the safety and efficacy of avacopan in subjects with moderate to severe hidradenitis suppurativa. Clinical Trial Registration NCT03852472, [clinicaltrials.gov, https://clinicaltrials.gov/ct2/show/NCT03852472](https://clinicaltrials.gov/ct2/show/NCT03852472) (2020, accessed 14 April 2021).
209. Sarin K. Examine the roles of complement C5a receptors in hidradenitis suppurativa by ex vivo studies. Clinical Trial Registration NCT04251663, [clinicaltrials.gov, https://clinicaltrials.gov/ct2/show/NCT04251663](https://clinicaltrials.gov/ct2/show/NCT04251663) (2021, accessed 14 April 2021).
210. Savage KT, Santillan MR, Flood KS, *et al.* Tofacitinib shows benefit in conjunction with other therapies in recalcitrant hidradenitis suppurativa patients. *JAAD Case Rep* 2020; 6: 99–102.
211. Incyte Corporation. A phase 2, open-label, single-arm study of the safety of INCB054707 in participants with hidradenitis suppurativa. Clinical Trial Registration NCT03569371, [clinicaltrials.gov, https://clinicaltrials.gov/ct2/show/NCT03569371](https://clinicaltrials.gov/ct2/show/NCT03569371) (2020, accessed 14 April 2021).
212. Incyte Corporation. A phase 2, dose-escalation, placebo-controlled study of the safety of INCB054707 in participants with hidradenitis suppurativa. Clinical Trial Registration NCT03607487, [clinicaltrials.gov, https://clinicaltrials.gov/ct2/show/NCT03607487](https://clinicaltrials.gov/ct2/show/NCT03607487) (2020, accessed 14 April 2021).
213. Incyte Corporation. A phase 2, randomized, double-blind, placebo-controlled, dose-ranging study of the efficacy and safety of INCB054707 in participants with hidradenitis suppurativa. Clinical Trial Registration NCT04476043, [clinicaltrials.gov, https://clinicaltrials.gov/ct2/show/NCT04476043](https://clinicaltrials.gov/ct2/show/NCT04476043) (2020, accessed 14 April 2021).
214. AbbVie. A phase 2 multicenter randomized placebo-controlled double-blind study to evaluate upadacitinib in adult subjects with moderate to severe hidradenitis suppurativa. Clinical Trial Registration NCT04430855, [clinicaltrials.gov, https://clinicaltrials.gov/ct2/show/NCT04430855](https://clinicaltrials.gov/ct2/show/NCT04430855) (2021, accessed 14 April 2021).
215. Novartis Pharmaceuticals. A randomized, subject and investigator blinded, placebo-controlled and multi-center platform study, to assess efficacy and safety of different investigational drugs in patients with moderate to severe hidradenitis suppurativa. Clinical Trial Registration NCT03827798, [clinicaltrials.gov, https://clinicaltrials.gov/ct2/show/NCT03827798](https://clinicaltrials.gov/ct2/show/NCT03827798) (2021, accessed 14 April 2021).
216. Boehringer Ingelheim. Randomized, double-blind, placebo-controlled, study of spesolimab in patients with moderate or severe hidradenitis suppurativa. Clinical Trial Registration NCT04762277, [clinicaltrials.gov, https://clinicaltrials.gov/ct2/show/NCT04762277](https://clinicaltrials.gov/ct2/show/NCT04762277) (2021, accessed 14 April 2021).
217. AnaptysBio, Inc. A phase 2, randomized, double-blind, placebo controlled study to evaluate the efficacy and safety of imsidolimab (ANB019) in the treatment of subjects with hidradenitis suppurativa. Clinical Trial Registration NCT04856930, [clinicaltrials.gov, https://clinicaltrials.gov/ct2/show/NCT04856930](https://clinicaltrials.gov/ct2/show/NCT04856930) (2021, accessed 29 April 2021).
218. Eli Lilly and Company. A multicenter, randomized, double-blind, placebo-controlled, phase 2 study to evaluate the efficacy and safety of LY3041658 in adults with moderate-to-severe hidradenitis suppurativa. Clinical Trial Registration NCT04493502, [clinicaltrials.gov, https://clinicaltrials.gov/ct2/show/NCT04493502](https://clinicaltrials.gov/ct2/show/NCT04493502) (2021, accessed 14 April 2021).
219. Novartis Pharmaceuticals. A randomized, subject and investigator blinded, placebo

- controlled, multi-center study in parallel groups to assess the efficacy and safety of LYS006 in patients with moderate to severe inflammatory acne. Clinical Trial Registration NCT03497897, [clinicaltrials.gov](https://clinicaltrials.gov/ct2/show/NCT03497897), <https://clinicaltrials.gov/ct2/show/NCT03497897> (2021, accessed 14 April 2021).
220. Kymera Therapeutics, Inc. A phase 1 randomized, placebo-controlled, single and multiple ascending dose trial to evaluate the safety, tolerability, pharmacokinetics, and pharmacodynamics of orally administered KT-474 in healthy adult volunteers and patients with atopic dermatitis (AD) or hidradenitis suppurativa (HS). Clinical Trial Registration NCT04772885, [clinicaltrials.gov](https://clinicaltrials.gov/ct2/show/NCT04772885), <https://clinicaltrials.gov/ct2/show/NCT04772885> (2021, accessed 14 April 2021).
221. Pfizer. A phase 2A, multicenter, randomized, double-blind, placebo-controlled, 16-week study evaluating the safety and efficacy of PF-06650833, PF-06700841, AND PF-06826647 in adults with moderate to severe hidradenitis suppurativa. Clinical Trial Registration NCT04092452, [clinicaltrials.gov](https://clinicaltrials.gov/ct2/show/NCT04092452), <https://clinicaltrials.gov/ct2/show/NCT04092452> (2021, accessed 14 April 2021).
222. Forman SB, Pariser DM, Poulin Y, *et al.* TYK2/JAK1 inhibitor PF-06700841 in patients with plaque psoriasis: phase IIa, randomized, double-blind, placebo-controlled trial. *J Invest Dermatol* 2020; 140: 2359–2370.e5.
223. Del Duca E, Morelli P, Bennardo L, *et al.* Cytokine pathways and investigational target therapies in hidradenitis suppurativa. *Int J Mol Sci* 2020; 21: 8436.
224. Frew JW. Assessing the efficacy of new biologic therapies in hidradenitis suppurativa: consistency vs. bias in outcome measures in moderate and severe disease. *J Eur Acad Dermatol Venereol* 2019; 33: e298–e300.
225. Martorell A, Jfri A, Koster SBL, *et al.* Defining hidradenitis suppurativa phenotypes based on the elementary lesion pattern: results of a prospective study. *J Eur Acad Dermatol Venereol* 2020; 34: 1309–1318.
226. Çetinarslan T, Türel Ermertcan A, Özyurt B, *et al.* Evaluation of the laboratory parameters in hidradenitis suppurativa: can we use new inflammatory biomarkers? *Dermatol Ther* 2021; 34: e14835.