

Unilateral inguinofemoral lymphadenectomy in patients with early-stage vulvar squamous cell carcinoma and a unilateral metastatic sentinel lymph node is safe

W.L. Van der Kolk^a, A.G.J. Van der Zee^a, B.M. Slomovitz^b, P.J.W. Baldwin^c, H.C. Van Doorn^d, J.A. De Hullu^e, J. Van der Velden^f, K.N. Gaarenstroom^g, B.F.M. Slangen^h, P. Kjolhedeⁱ, M. Brännström^j, I. Vergote^k, C.M. Holland^l, R. Coleman^m, E.B.L. Van Dorstⁿ, W.J. Van Driel^o, D. Nunns^p, M. Widschwendter^q, D. Nugent^r, P.A. DiSilvestro^s, R.S. Mannel^t, M.Y. Tjiong^f, D. Boll^u, D. Cibula^v, A. Covens^w, D. Provencher^x, I.B. Runnebaum^y, B.J. Monk^z, V. Zanagnolo^{aa}, K. Tamussino^{ab}, M.H.M. Oonk^{a,*}, On behalf of all GROINSS-V I and II participants:

C.F. Levenback, R.H. Hermans, J. Bouda, A. Sharma, D. Luesley, P. Ellis, D.J. Cruickshank, T.J. Duncan, K. Kieser, C. Palle, N.M. Spirtos, D.M. O'Malley, M.M. Leitao, M. Geller, K. Dhar, V. Asher, D.H. Tobias, C. Borgfeldt, J.S. Lea, M. Lood, J. Bailey, B. Eyjolfsson, S. Attard-Montalto, K.S. Tewari, P. Persson, R. Manchanda, P. Jensen, L. Van Le

^a University Medical Center Groningen, University of Groningen, Groningen, the Netherlands

^b Mount Sinai Medical Center, Miami Beach, FL, United States of America

^c Cambridge University Hospitals NHS Foundation Trust, Cambridge, United Kingdom

^d Erasmus MC Cancer Institute, University Medical Center Rotterdam, Rotterdam, the Netherlands

^e Radboud University Medical Center, Nijmegen, the Netherlands

^f Amsterdam University Medical Center, Amsterdam, the Netherlands

^g Leiden University Medical Center, Leiden, the Netherlands

^h Maastricht University Medical Center+, Maastricht, the Netherlands

ⁱ Linköping University, Linköping, Sweden

^j Sahlgrenska Academy, University of Gothenburg, Göteborg, Sweden

^k Leuven Cancer Institute, Leuven, Belgium

^l Manchester University NHS Foundation Trust-St Marys Hospital, Manchester, United Kingdom

^m The University of Texas MD Anderson Cancer Center, Houston, TX, United States of America.

ⁿ University Medical Center Utrecht, Utrecht, the Netherlands

^o Center of Gynecological Oncology Amsterdam, The Netherlands Cancer Institute, Amsterdam, the Netherlands

^p Nottingham University Hospitals NHS Trust, Nottingham, United Kingdom

^q European Translational Oncology Prevention and Screening (EUTOPS) Institute, University Innsbruck, Austria

^r Leeds Teaching Hospitals NHS Trust, St James' University Hospital, Leeds, United Kingdom

^s Women and Infants Hospital of Rhode Island, Providence, RI, United States of America

^t Stephenson Cancer Center, University of Oklahoma, Oklahoma City, OK, United States of America

^u Catharina Ziekenhuis Eindhoven, the Netherlands

^v First Faculty of Medicine, Charles University and General University Hospital in Prague, Prague, Czech Republic

^w University of Toronto, Toronto, Ontario, Canada

^x CHUM, Université de Montréal, Montréal, Quebec, Canada

^y Jena University Hospital, Friedrich Schiller University, Jena, Germany

^z St Josephs Hospital and Medical Center, Phoenix, AZ, United States of America

^{aa} Department of Obstetrics and Gynaecology, European Cancer Institute, Milan, Italy

^{ab} Medical University Graz, Graz, Austria

* Corresponding author at: Gynecological Oncologist, Department of Obstetrics and Gynecology, University Medical Center Groningen, Hanzeplein 1, 9713GZ Groningen, the Netherlands.

E-mail address: m.h.m.oonk@umcg.nl (M.H.M. Oonk).

H I G H L I G H T S

- Contralateral groin metastases or recurrences in patients with unilateral SN metastasis are rare.
- Unilateral groin treatment is sufficient in patients with unilateral SN metastases.
- In near-midline vulvar cancer, unilateral SN detection is sufficient when the lymphoscintigram shows unilateral lymph flow.
- These findings offer further opportunity to safely reduce treatment-related morbidity in early-stage vulvar cancer.

A R T I C L E I N F O

Article history:

Received 23 June 2022

Accepted 18 July 2022

Available online 7 September 2022

Keywords:

Vulvar cancer

Sentinel lymph node

Inguinofemoral lymphadenectomy

Lymph node metastases

Radiotherapy

A B S T R A C T

Objective. Optimal management of the contralateral groin in patients with early-stage vulvar squamous cell carcinoma (VSCC) and a metastatic unilateral inguinal sentinel lymph node (SN) is unclear. We analyzed patients who participated in GROINSS-V I or II to determine whether treatment of the contralateral groin can safely be omitted in patients with a unilateral metastatic SN.

Methods. We selected the patients with a unilateral metastatic SN from the GROINSS-V I and II databases. We determined the incidence of contralateral additional non-SN metastases in patients with unilateral SN-metastasis who underwent bilateral inguinofemoral lymphadenectomy (IFL). In those who underwent only ipsilateral groin treatment or no further treatment, we determined the incidence of contralateral groin recurrences during follow-up.

Results. Of 1912 patients with early-stage VSCC, 366 had a unilateral metastatic SN. Subsequently, 244 had an IFL or no treatment of the contralateral groin. In seven patients (7/244; 2.9% [95% CI: 1.4%–5.8%]) disease was diagnosed in the contralateral groin: five had contralateral non-SN metastasis at IFL and two developed an isolated contralateral groin recurrence after no further treatment. Five of them had a primary tumor ≥ 30 mm. Bilateral radiotherapy was administered in 122 patients, of whom one (1/122; 0.8% [95% CI: 0.1%–4.5%]) had a contralateral groin recurrence.

Conclusion. The risk of contralateral lymph node metastases in patients with early-stage VSCC and a unilateral metastatic SN is low. It appears safe to limit groin treatment to unilateral IFL or inguinofemoral radiotherapy in these cases.

© 2022 The Authors. Published by Elsevier Inc. This is an open access article under the CC BY license (<http://creativecommons.org/licenses/by/4.0/>).

1. Introduction

Treatment of patients with unifocal early-stage vulvar squamous cell carcinoma (VSCC), smaller than 4 cm, comprises wide local excision of the primary tumor and a sentinel node (SN) procedure. When the SN contains metastatic disease a uni- or bilateral inguinofemoral lymphadenectomy (IFL) or inguinofemoral radiotherapy is performed. The Groningen International Study on Sentinel Nodes in Vulvar cancer (GROINSS-V) and Gynecological Oncology Group (GOG) studies have demonstrated that it is safe to omit IFL with a negative SN [1,2]. The use of SN biopsy has significantly reduced treatment-related morbidity in patients with early-stage vulvar cancer [1,3,4]. The European Society of Gynecological Oncology (ESGO) guidelines recommend the SN procedure in patients with unifocal VSCC <4 cm without suspicious groin nodes at imaging [5]. In case of a unilateral metastatic SN, additional treatment of the ipsilateral groin with the metastatic SN is recommended. There is little evidence, however, to guide the correct management of the contralateral groin in this situation [5]. Following publication of the GROINSS-V II study, patients with SN-metastases ≤ 2 mm can now be offered inguinofemoral radiotherapy instead of IFL [6].

The lymphatic drainage of the vulva is well documented. Most of the lymph drainage of the labia flows to the ipsilateral inguinofemoral lymph nodes. The median part of the vulva with midline structures e.g., the clitoris, shows bilateral lymph drainage [7]. The majority of patients with a lateralized tumor (defined as tumors with medial border >1 cm from the midline) show ipsilateral drainage on lymphoscintigraphy. For these patients ipsilateral SN biopsy is sufficient if no contralateral drainage is visualized on the lymphoscintigram. For near-midline tumors (medial border of the tumor within 1 cm of the midline, but not involving the midline), there is no consensus whether only ipsilateral SN biopsy is sufficient. In the majority bilateral lymph drainage is detected. For most true midline tumors (tumors involving the midline), bilateral drainage is detected on the lymphoscintigram, and in those cases,

bilateral SN biopsy should be performed. Where bilateral drainage is not identified for true midline tumors it is not safe to omit contralateral IFL, due to an increased risk of contralateral lymph node metastases, (4/32 patients (12.5%) in Coleman et al. (2013)) [8]. In those cases there is indication for contralateral IFL.

The primary aim of this study was to investigate whether limiting treatment to the ipsilateral groin is safe in patients with early-stage VSCC and a unilateral metastatic SN. The GROINSS-V studies are the largest available prospective studies on the SN-procedure in vulvar cancer and provide a robust dataset for further study. As such, an in-depth analysis of these studies should provide important evidence to guide management following unilateral SN metastasis and specifically, the management of the contralateral groin.

2. Methods

We used data from two large prospective multicenter studies in early-stage vulvar cancer: GROINSS-V I and II. GROINSS-V I investigated the safety of omitting IFL in patients with a negative SN. This study included 377 patients from 2000 to 2006 with unifocal VSCC <4 cm and no suspicious groin nodes at palpation [1]. Patients with a metastatic SN underwent uni- or bilateral IFL; IFL was omitted in patients with a negative SN. Follow-up of the included patients was updated in 2016 [6]. GROINSS-V II investigated the safety of inguinofemoral radiotherapy (50Gy) as alternative to IFL in patients with a metastatic SN. This study was conducted from 2005 to 2016 and also included patients with unifocal VSCC <4 cm without suspicious nodes at imaging. In total 1535 eligible patients were included. Five years after the first inclusion, the protocol of GROINSS-V II was amended because the isolated groin recurrence rate in patients with a metastatic SN who were treated with inguinofemoral radiotherapy went above the predefined threshold. Interim analysis showed that especially patients with SN-metastases >2 mm and/or extranodal tumor spread were at risk. From then on

patients with SN-macrometastases (>2 mm) underwent standard of care (IFL) while patients with SN-micrometastases (≤ 2 mm) continued to receive inguinofemoral radiotherapy [6]. Follow-up in both studies was performed until at least two years after primary treatment, since most groin recurrences occur within two years of primary treatment.

The SN-procedure in both studies was performed as previously described. The combination of a radioactive tracer (99mTc-labeled nano colloid) with performance of a lymphoscintigram, and blue dye was used. A lymphoscintigram was performed to determine number and localization of the SNs. The SNs were investigated by routine hematoxylin-eosin (HE) staining, and when this was negative, ultrastaging was performed (one section/500 μ m; one for HE, one for cytokeratin AE1/AE3-immunohistochemistry, and one spare section). Each SN with tumor cells was regarded as metastatic, regardless of size of the metastasis (including isolated tumor cells).

In the present study we categorized the patients into three groups according to the localization of the primary tumor. The tumor was classified as lateralized if the distance from the midline was >10 mm, near-midline if the distance from the midline was >0 mm and ≤ 10 mm, and true midline if the midline was involved. In case of missing data, we used the case record file (CRF), which included a drawing of the tumor on the vulva, to determine the position of the tumor. We analyzed lymph drainage patterns for lateralized, near-midline and true midline tumors in the group of patients for whom tumor localization was known. We analyzed the incidence of contralateral non-SN metastases in the patients with a unilateral metastatic SN who underwent

bilateral IFL. In order to evaluate the incidence of contralateral metastases in patients who did not undergo IFL of the contralateral groin, we determined the incidence of contralateral isolated groin recurrences during follow-up.

We also analyzed the risk of contralateral groin recurrence in the whole group of patients with a near-midline tumor who underwent only ipsilateral SN biopsy.

2.1. Statistical analysis

Analysis was performed using IBM SPSS statistics software version 23. The tests were two sided and *P*-values below 0.05 were considered significant. Confidence intervals were calculated with the Wilson method. To determine the significance of differences in patient characteristics between subgroups (based on tumor location), we used Chi-Square for nominal variables with expected values above five, Fisher's exact for nominal variables including expected values below five, and One Way ANOVA for scale variables.

3. Results

We analyzed 1912 patients (mean \pm SD age, 65.2 \pm 14.2 years) with early-stage VSCC from GROINSS-V I and II. Fourteen patients had an unknown tumor location and were therefore excluded from further analyses. Of the remaining 1898 patients, 723 (38.1%) had a lateralized tumor, 530 (27.9%) had a near-midline tumor and 645 (34.0%) had a

Table 1
Patient characteristics.

	Total	Lateralized tumor	Near midline tumor	True midline tumor	P-value
Women with early-stage vulvar cancer (n = 1898)	N = 1898	N = 723	N = 530	N = 645	
Mean age (SD)	65.2 years (14.3)	64.8 years (14.0)	66.1 years (14.0)	64.8 years (14.7)	0.227
Mean tumor size (SD)	19.91 mm (10.46)	18.73 mm (10.06)	20.02 mm (10.63)	21.16 mm (10.61)	< 0.001*
Mean invasion depth (SD)	3.81 mm (4.20)	4.00 mm (4.80)	3.37 mm (2.94)	3.98 mm (4.35)	0.021*
Local treatment					0.004*
- Wide local excision	1409 (74.4%)	536 (74.1%)	374 (70.8%)	499 (77.5%)	
- Radical (hemi-) vulvectomy	466 (24.6%)	183 (25.3%)	150 (28.4%)	133 (20.7%)	
- Other	20 (1.1%)	4 (0.6%)	4 (0.8%)	12 (1.9%)	
- Missing	3 (0.2%)	0 (0.0%)	2 (0.4%)	1 (0.2%)	
Lymph drainage pattern					< 0.001*
- Unilateral	745 (39.3%)	511 (70.7%)	165 (31.1%)	69 (10.7%)	
- Bilateral	1099 (57.9%)	183 (25.3%)	351 (66.2%)	565 (87.6%)	
- Unknown	54 (2.8%)	29 (4.0%)	14 (2.6%)	11 (1.7%)	
SN biopsy					
- Unilateral SN biopsy	760 (40.0%)	537 (74.3%)	157 (29.6%)	66 (10.2%)	
- Bilateral SN biopsy	1137 (59.9%)	186 (25.7%)	373 (70.4%)	578 (89.6%)	
- Unknown	1 (0.1%)	0 (0.0%)	0 (0.0%)	1 (0.2%)	
Status of SN					<0.001*
- Negative	1457 (76.8%)	581 (80.4%)	399 (75.3%)	477 (74.1%)	
- Unilateral	366 (19.3%)	138 (19.1%)	112 (21.1%)	116 (17.9%)	
- Bilateral	75 (3.9%)	4 (0.6%)	19 (3.6%)	52 (8.0%)	

Table 2
Groin treatment and outcomes in contralateral groin for patients with unilateral metastatic SN.

	Total	Lateralized tumor	Near- midline tumor	True midline tumor	P-value
Women with unilateral metastatic SN (n = 366)	N = 366	N = 138	N = 112	N = 116	
Groin treatment					0.147
Only SN biopsy	24 (6.6%)	10 (7.2%)	5 (4.5%)	9 (7.8%)	
- Contralateral groin recurrences	0 (0.0%)	0 (0.0%)	0 (0.0%)	0 (0.0%)	
Unilateral IFL	70 (19.1%)	25 (18.1%)	22 (19.6%)	23 (19.8%)	
- Contralateral groin recurrences	2 (2.9%)	2 (8.0%)	0 (0.0%)	0 (0.0%)	
Bilateral IFL	105 (28.7%)	38 (27.5%)	40 (35.7%)	27 (23.3%)	
- Contralateral groin metastases	5 (4.8%)	1 (2.6%)	3 (7.5%)	1 (3.7%)	
Unilateral radiotherapy	45 (12.3%)	25 (18.1%)	8 (7.1%)	12 (10.3%)	
- Contralateral groin recurrences	0 (0.0%)	0 (0.0%)	0 (0.0%)	0 (0.0%)	
Bilateral radiotherapy	122 (33.3%)	40 (29.0%)	37 (33.0%)	45 (38.8%)	
- Contralateral groin recurrences	1 (0.8%)	0 (0.0%)	0 (0.0%)	1 (2.2%)	

Table 3
Tumor and treatment details for patients with contralateral non-SN metastases or groin recurrence.

Patient	Age	Tumor size	Invasion depth	Tumor location	LSG	SN biopsy	Groin treatment	Time till recurrence
Tumor and treatment details for patients with contralateral non-SN metastases								
1	55	30 mm	3 mm	Lateralized	Unilateral	Unilateral	Bilateral IFL	
2	42	35 mm	14 mm	Near-midline	Bilateral	Bilateral	Bilateral IFL	
3	46	30 mm	5 mm	Near-midline	Unilateral	Unilateral	Bilateral IFL	
4	66	6 mm	2 mm	Near-midline	Bilateral	Bilateral	Bilateral IFL	
5	72	39 mm	13 mm	True midline	Bilateral	Bilateral	Bilateral IFL	
Tumor and treatment details for patients with contralateral groin recurrences								
1	68	30 mm	6 mm	Lateralized	Bilateral	Bilateral	Unilateral IFL	10.0 months
2	72	20 mm	6 mm	Lateralized	Bilateral	Bilateral	Unilateral IFL	7.6 months
3	83	23 mm	7 mm	True midline	Bilateral	Bilateral	Bilateral RT	6.6 months

true midline tumor. Table 1 summarizes the patient characteristics, lymph drainage patterns and SN biopsy results. The mean tumor size was 19.5 mm (SD = 10.4) and the mean depth of invasion was 3.5 mm (SD = 4.2). Lymph drainage patterns were significantly different for lateralized, near-midline and true midline tumors ($p \leq 0.001$). Detection of bilateral metastatic SNs was significantly higher in true midline tumors compared to near-midline and lateralized tumors ($p < 0.001$) (Table 1).

Metastatic SNs were found in 441 (23.2%) of 1898 patients, of whom 366 (83.0%) had a unilateral metastatic SN and 75 (17.0%) had bilateral metastatic SNs. Of the 366 patients with a unilateral metastatic SN, 175 (49.5%) underwent IFL (70 (40.0%) unilateral IFL and 105 (60.0%) bilateral IFL). Inguinofemoral radiotherapy (instead of IFL, by protocol of the GROINSS-V II study or by physicians' preference in GROINSS-V I) was administered to 167 (45.6%) patients (45 (26.9%) unilateral and 122 (73.1%) bilateral). In 24

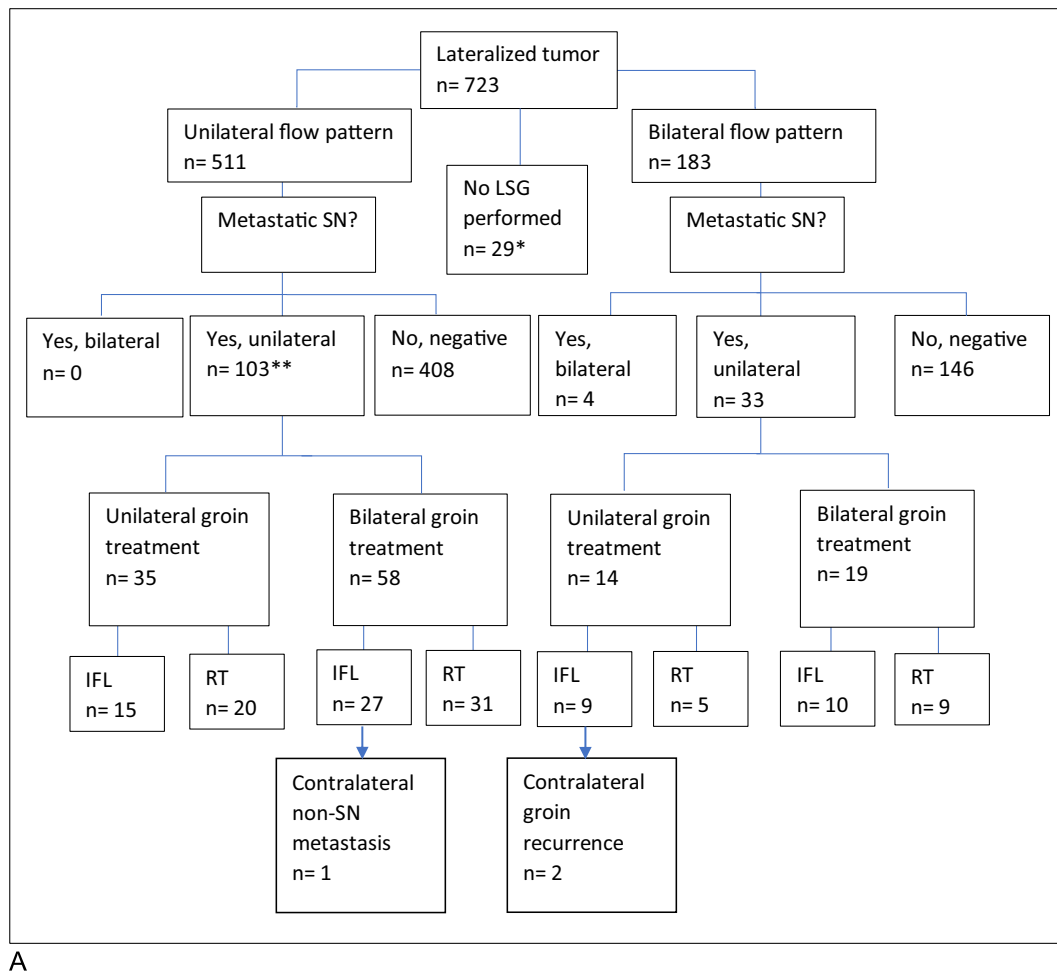
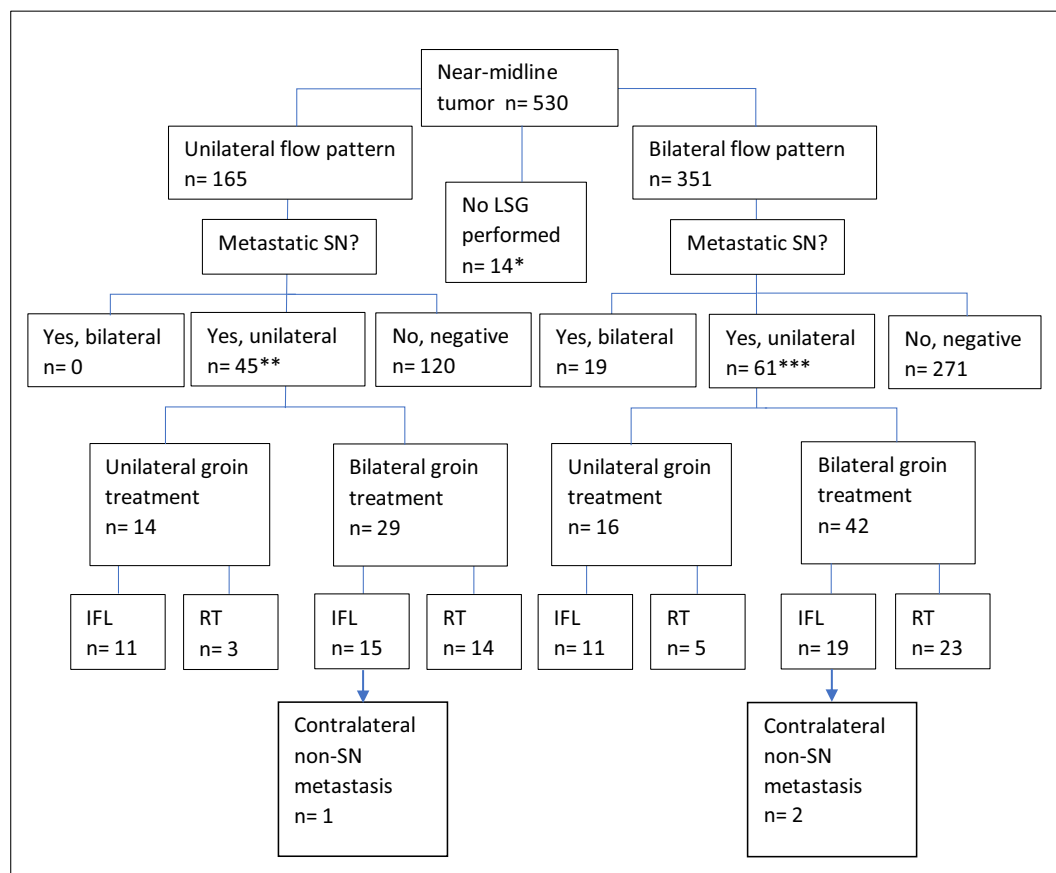


Fig. 1. Overview of treatment and outcome of patients with a: a. Lateralized tumor. *No contralateral groin recurrences were found in this group. **No further treatment in ten patients. b. Near-midline tumor. *No contralateral groin recurrences were found in this group **No further treatment in two patients ***No further treatment in three patients. c. Midline tumor. *No contralateral groin recurrences were found in this group. **SN found at blue dye ***No further treatment in nine patients.



B

Fig. 1 (continued).

(6.6%) patients with a unilateral metastatic SN no additional groin treatment was performed (Table 2).

Of the 105 patients with unilateral SN metastasis who underwent bilateral IFL, five (5/105; 4.8% [95% CI: 2.1%–10.7%]) had a contralateral non-SN metastasis (Table 2). Notably, four of these patients had a primary tumor ≥ 30 mm and two had a depth of invasion ≥ 10 mm. In three patients bilateral IFL was performed, and a metastatic non-SN was found in the contralateral groin where previously the SN was found to be negative (false-negative SN). In two patients a bilateral IFL was performed, and a metastatic node was found in the contralateral groin where no SN was identified (Table 3).

In total, 139 patients with a unilateral metastatic SN and no contralateral groin treatment (unilateral IFL or inguinofemoral radiotherapy, or no further treatment) were available for analysis. Two of these patients (2/139; 1.4% [95% CI: 0.4%–5.1%]) developed a contralateral isolated groin recurrence (time to recurrence 10.0 and 7.6 months) (Table 3). Both of these patients had a lateralized tumor with bilateral flow on the lymphoscintigram, underwent bilateral SN procedure and were treated with unilateral IFL because of unilateral SN-metastasis. Both had a groin recurrence in the SN-negative groin (false-negative SN). One patient had a tumor ≥ 30 mm. No significant differences in frequency of groin recurrences were found between lateralized, near-midline and midline tumors ($p = 0.477$).

Of the 122 patients with a unilateral metastatic SN who underwent bilateral radiotherapy, one patient (1/122; 0.8% [95% CI: 0.1%–4.5%]) had a contralateral groin recurrence (after a negative SN in that groin, time to recurrence 6.6 months) (Table 3).

In total, seven patients (7/244; 2.9% [95% CI: 1.4%–5.8%]) with a successful SN biopsy and a unilateral metastatic SN had a contralateral non-SN metastasis at bilateral IFL, or contralateral groin recurrence when no treatment was given to the contralateral groin (Table 2). Of these patients, three had a lateralized tumor, three had a near-midline tumor and one had a true midline tumor.

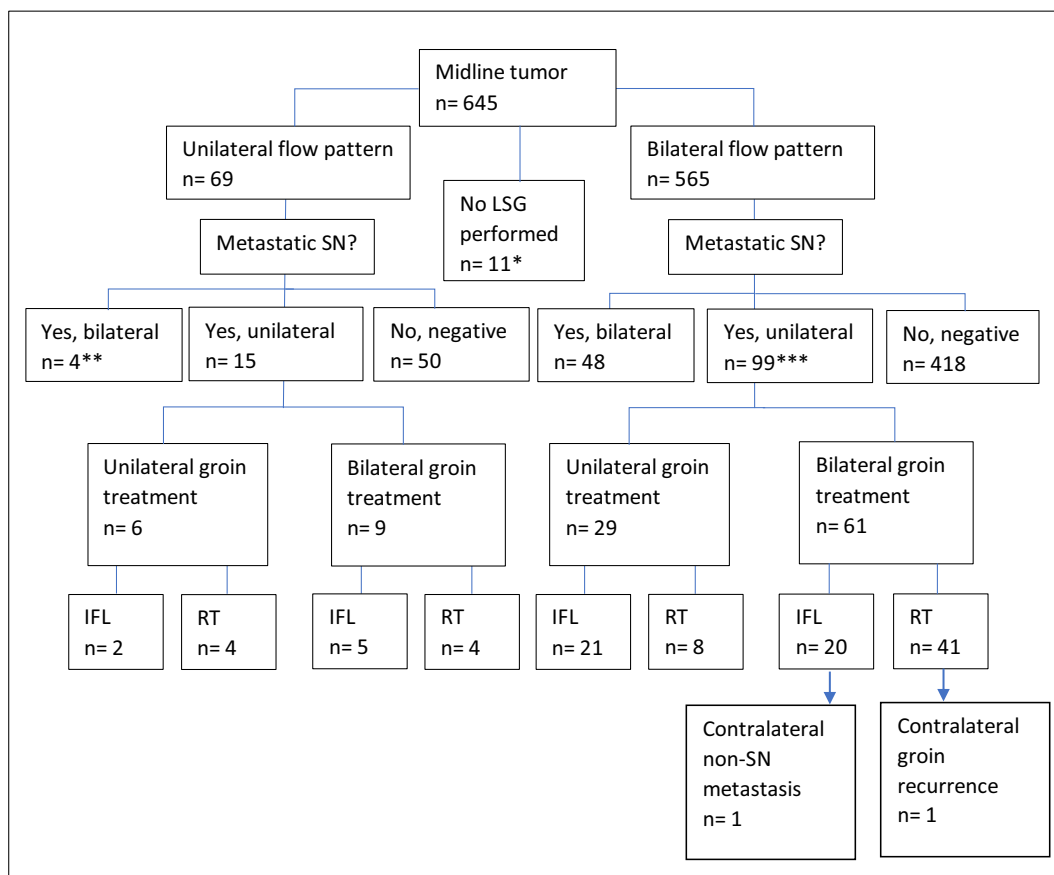
When considering the effect of tumor size, contralateral groin recurrence or non-SN metastasis in patients with tumors ≥ 30 mm and a unilateral metastatic SN was 3.6% (5/140 [95% CI: 1.5%–8.1%]) compared to 1.4% (3/222 [95% CI: 0.5%–3.9%]) for tumors < 30 mm (tumor size missing in 4 patients) ($p=0.11$).

With respect to tumor location, the risk of isolated contralateral groin recurrence or contralateral non-SN metastases amongst patients with a unilateral metastatic SN, was 2.2% (3/138 [95% CI: 0.7%–6.2%]) for those with a lateralized tumor, 2.7% (3/112 [95% CI: 0.9%–7.6%]) for those with a near-midline tumor, and 1.7% (2/116 [95% CI: 0.5%–6.1%]) for those with a true midline tumor (Fig. 1a–c).

For patients with near-midline tumors, it is matter of debate whether only ipsilateral drainage on the lymphoscintigram is sufficient. In this series, 157 patients had a near-midline tumor and underwent only unilateral SN biopsy. Of them, one (0.6% [95% CI: 0.1%–3.5%]) had a contralateral non-SN metastasis in the groin where no SN was identified. No patients had contralateral groin recurrences.

4. Discussion

In all 244 patients with early-stage vulvar cancer with one or more unilateral metastatic SNs treated with uni- or bilateral IFL, unilateral



C

Fig. 1 (continued).

radiotherapy or no further treatment, seven patients (2.9%) with contralateral non-SN metastases or groin recurrences were observed. A risk of 2.9% is comparable to the risk of groin recurrence in patients with negative SNs at SN biopsy (2.7% in GROINSS-V II, $p = 0.78$) [1]. The risk seems higher in patients with vulvar tumors ≥ 30 mm although this did not reach significance, and tumor location on the vulva (lateralized / near-midline / true midline) had no influence. In patients with unilateral metastatic SN subsequently treated with radiotherapy to both groins, the risk of contralateral groin recurrences was 0.8% [95% CI: 0.1%–4.5%]. This lower incidence reflects active treatment of the ‘negative groin’ and highlights that recurrence may still occur after treatment, in this case with radiotherapy.

Our percentages of contralateral non-SN metastases and contralateral groin recurrences are comparable to previously published results from by Woelber et al. (2016), Nica et al. (2019), and Ignatov et al. (2021), who observed 0.0% (0/28), 5.3% (1/19) and 0.0% (0/62) contralateral non-SN metastases respectively [9–11]. In contrast to this low incidence of contralateral metastasis, Winarno et al. (2021) reported four patients (22.2%; 4/18) with contralateral non-SN metastases in whom bilateral lymphadenectomy for a unilateral metastatic SN was performed [12]. All contralateral metastases were found in patients with midline tumors (defined as within 1 cm of the midline).

The strengths of our study are its prospective nature and the large number of patients. With 366 patients with unilateral SN-metastasis, our study is the largest thus far addressing the safety of omitting bilateral groin treatment in patients with a unilateral metastatic SN. Taking our results into consideration together with results from other published studies, we consider performing unilateral IFL or inguinofemoral

radiotherapy alone in patients with a unilateral metastatic SN and a successful SN biopsy safe. We advise caution in patients with larger tumors, as the majority of the contralateral lymph node metastases and groin recurrences were diagnosed in patients with primary tumors ≥ 30 mm. On the basis of our findings, we propose a treatment guideline for patients with a unilateral metastatic SN (Fig. 2).

Lymph drainage patterns were significantly different for lateralized, near-midline and true midline tumors. Iversen et al. demonstrated that midline structures have bilateral drainage [7]. Coleman et al. (2013) showed bilateral drainage in 73/105 (70%) of midline tumors, and in 14/64 (22%) of lateralized tumors. In the lateral ambiguous group (defined in this study as within 2 cm from the midline but not involving the midline) 38/65 (58%) had bilateral drainage [8]. These findings are very similar to our results. Also, Deken et al. documented bilateral drainage in 25% of the patients with a lateralized tumor (defined as not crossing the midline) [13]. In our analysis of patients with near-midline vulvar tumors, only one patient (0.6% [95% CI: 0.1%–3.5%]) had a contralateral non-SN metastasis identified at bilateral IFL after a initial unilateral SN biopsy. Of all patients with near-midline tumors who underwent unilateral SN-procedure, no recurrences occurred in the groins where no SN was identified. Therefore, we conclude ipsilateral drainage is an acceptable finding for near-midline tumors. Furthermore, where the SN is positive in the ipsilateral groin, limiting further treatment to the ipsilateral groin appears safe, with a low risk of contralateral groin recurrence. It is important to appreciate that the results of the lymphoscintigram and the SN procedure are influenced by the exact site of injection of the radio-labeled tracer by the gynecological oncologist. This is subject to inherent bias because it is likely that surgeons will inject this at locations

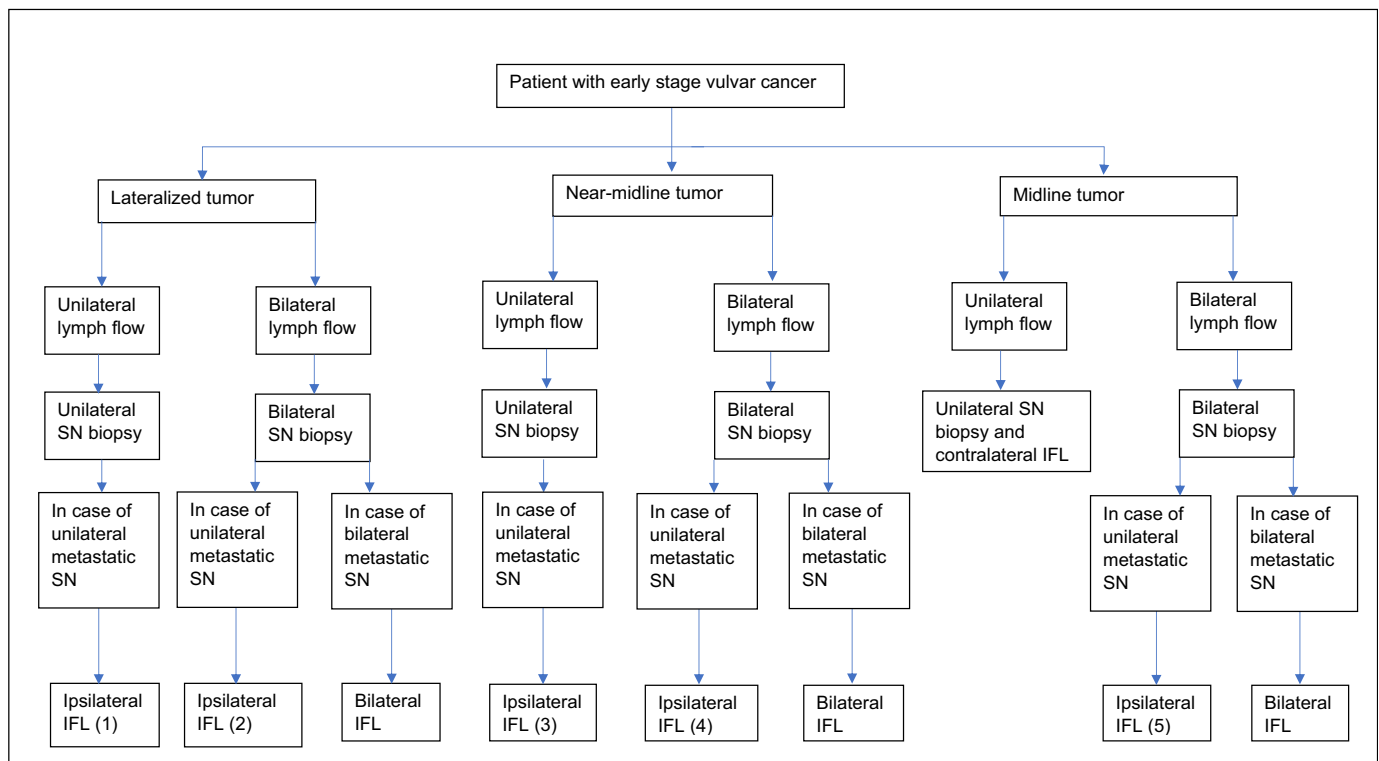


Fig. 2. Proposed treatment guide for early stage vulvar SCC. (1) contralateral groin recurrence risk is 1.0% (2) contralateral groin recurrence risk is 6.1% (3) contralateral groin recurrence risk is 2.2% (4) contralateral groin recurrence risk is 3.3% (5) contralateral groin recurrence risk is 2.0%.

that guarantee bilateral SN identification when dealing with a near-midline tumor. This arises from knowledge of lymphatic drainage patterns in the vulva and the fear of missing contralateral metastasis.

We propose therefore, that contralateral IFL is only indicated in cases of unilateral lymph flow on the LSG when dealing with true midline tumors, and is not indicated when the tumor is near-midline.

For true midline tumors, bilateral lymphatic drainage should be seen. We did not see contralateral recurrence in a small proportion of patients where treatment was limited to one groin on the basis of unilateral drainage with a metastatic SN ($n = 9$). However, we would still regard unilateral drainage on LSG for a true midline tumor to represent method failure. IFL for the groin in which no SLN was identified is recommended.

5. Conclusion

The rate of contralateral non-SN metastases/groin recurrences in patients with unilateral SN-involvement who underwent a successful SN biopsy is low (2.9%), with a relatively narrow confidence interval [95% CI: 1.4%–5.8%]. Accordingly, we consider unilateral groin treatment by either IFL or inguofemoral radiotherapy safe. For lateralized and near-midline tumors this means unilateral groin treatment can be performed when at least an ipsilateral SN is detected. For true midline tumors this means unilateral groin treatment can be performed, on the assumption that the contralateral groin was staged adequately (by a negative SN, or negative IFL). Tumor location had no influence on occurrence of contralateral additional non-SN metastases and contralateral groin recurrences. Overall, these results offer further opportunity to safely reduce the morbidity associated with treatment for early-stage vulvar cancer.

Funding

GROINSS-V II was funded by the Dutch Cancer Society.

References

- [1] A.G.J. van der Zee, M.H. Oonk, J.A. de Hullu, A.C. Ansink, I. Vergote, R.H. Verheijen, et al., Sentinel node dissection is safe in the treatment of early-stage vulvar cancer, *J. Clin. Oncol.* 26 (6) (2008) 884–889.
- [2] C.F. Levenback, S. Ali, R.L. Coleman, M.A. Gold, J.M. Fowler, P.L. Judson, et al., Lymphatic mapping and sentinel lymph node biopsy in women with squamous cell carcinoma of the vulva: A gynecologic oncology group study, *J. Clin. Oncol. [Intern.]* 30 (31) (2012 Nov 1) 3786–3791, [cited 2021 Mar 7]. Available from: <https://pubmed.ncbi.nlm.nih.gov/22753905/>.
- [3] M.H.M. Oonk, M.A. van Os, G.H. de Bock, J.A. de Hullu, A.C. Ansink, Van der Zee AGJ. A comparison of quality of life between vulvar cancer patients after sentinel lymph node procedure only and inguofemoral lymphadenectomy, *Gynecol. Oncol. [Internet]*. 113 (3) (2009) 301–305, <https://doi.org/10.1016/j.ygyno.2008.12.006>.
- [4] L. Brammen, A. Staudenherz, S. Polterauer, P. Dolliner, C. Grimm, A. Reinthaller, et al., Sentinel lymph node detection in vulvar cancer patients: a 20 years analysis, *Hell. J. Nucl. Med. [Internet]*. 17 (3) (2014 Sep 1) 184–189, [cited 2022 Feb 28]. Available from: <https://pubmed.ncbi.nlm.nih.gov/25397623/>.
- [5] ESGO European Society of Gynaecological Oncology, Vulvar Cancer Guidelines, 2017 1–75, Available from: <https://guidelines.esgo.org/media/2016/08/ESGO-Vulvar-cancer-Complete-report-fox2.pdf>.
- [6] M.H.M. Oonk, B. Slomovitz, P.J.W. Baldwin, H.C. van Doorn, J. van der Velden, J.A. de Hullu, et al., Radiotherapy Versus inguofemoral lymphadenectomy as treatment for vulvar cancer patients with micrometastases in the sentinel node: results of GROINSS-V II, *J. Clin. Oncol. [Internet]*. 39 (32) (2021 Nov 10) 3623–3632, [cited 2022 Mar 24]. Available from: <https://pubmed.ncbi.nlm.nih.gov/34432481/>.
- [7] T. Iversen, M. Aas, Lymph drainage from the vulva, *Gynecol. Oncol. [Internet]*. 16 (2) (1983) 179–189, [cited 2021 Mar 7]. Available from: <https://pubmed.ncbi.nlm.nih.gov/6226578/>.
- [8] R.L. Coleman, S. Ali, C.F. Levenback, M.A. Gold, J.M. Fowler, P.L. Judson, et al., Is bilateral lymphadenectomy for midline squamous carcinoma of the vulva always necessary? An analysis from Gynecologic Oncology Group (GOG) 173, *Gynecol. Oncol. [Internet]* 128 (2) (2013 Feb) 155–159, [cited 2021 Jun 30]. Available from: <https://pubmed.ncbi.nlm.nih.gov/23201592/>.
- [9] L. Woelber, C. Eulenburg, D. Grimm, F. Trillsch, I. Bohlmann, E. Burandt, et al., The risk of contralateral non-sentinel metastasis in patients with primary vulvar cancer and unilaterally positive sentinel node, *Ann. Surg. Oncol. [Internet]* 23 (8) (2016 Aug 1) 2508–2514, [cited 2021 Jun 30]. Available from: <https://pubmed.ncbi.nlm.nih.gov/26856721/>.
- [10] A. Nica, A. Covens, D. Vicus, R. Kupets, R. Osborne, M. Cesari, et al., Sentinel lymph nodes in vulvar cancer: management dilemmas in patients with positive nodes and larger tumors, *Gynecol. Oncol.* 152 (1) (2019 Jan 1) 94–100.

- [11] T. Ignatov, J. Gaßner, Mihaela Bozukova, Stylianos Ivros, J. Mészáros, O. Ortmann, et al., Contralateral lymph node metastases in patients with vulvar cancer and unilateral sentinel lymph node metastases of Nordic Federation of Societies of obstetrics and gynecology (NFOG), *Acta Obstet. Gynecol. Scand.* (2021) 1–6.
- [12] A.S. Winarno, A. Mondal, F.C. Martignoni, T.N. Fehm, M. Hampl, The potential risk of contralateral non-sentinel groin node metastasis in women with early primary vulvar cancer following unilateral sentinel node metastasis: a single center evaluation in University Hospital of Düsseldorf, *BMC Women's Health* [Internet] 21 (1) (2021 Dec 1) , [cited 2021 Jun 30]. Available from: <https://pubmed.ncbi.nlm.nih.gov/33435958/>.
- [13] M.M. Deken, H.C. van Doorn, D. Verver, L.S.F. Boogerd, K.S. de Valk, D.D.D. Rietbergen, et al., Near-infrared fluorescence imaging compared to standard sentinel lymph node detection with blue dye in patients with vulvar cancer – a randomized controlled trial, *Gynecol. Oncol.* [Internet] 159 (3) (2020 Dec 1) 672–680 , [cited 2022 May 31]. Available from: <http://www.gynecologiconcology-online.net/article/S0090825820339548/fulltext>.