



Description of human infestations by ticks in Panama and Costa Rica

Authors: Sergio Bermúdez C.^{1,2}, Vicente Greco-Mastelari³, Yamitzel Zaldívar A¹, Michelle Hernández¹, Lillian Domínguez A.¹, Víctor M. Montenegro H.⁵, José M. Venzal⁶

Abstract

Tick bites in humans are associated with the transmission of pathogens, anaphylactic shock, paralysis, and secondary infections. In this work we described six cases of tick bites in patients from Panama and Costa Rica. These bites were provoked for adults of *Ornithodoros puertoricensis*, *Amblyomma* cf. *oblongoguttatum*, *Amblyomma ovale*, and *Ixodes* cf. *boliviensis*, and a nymph of *Amblyomma mixtum*. The relationships of these species of ticks with the environment are explained. Among the reactions observed in the patients there are blisters, maculo-papular rash, granuloma, lymphadenopathy, and erythema migrans-like rash, but none referred symptoms compatible with an infectious disease. In the collected ticks a PCR battery was developed to rule out *Borrelia*, *Rickettsia*, Anaplasmataceae, and *Coxiella* diseases to the ticks from the cases 1, 2, 3 and 4, with negative results. Although no pathogen infections were evidenced, these finding indicate that the tick bites constitute a public health problem what goes unnoticed in many countries.

Key word: tick bites, humans, lymphadenopathy, erythema migrans-like, environments, Panama, Costa Rica.

¹Instituto Conmemorativo Gorgas de Estudios de la Salud, Panamá, Panamá. sbermudez@gorgas.gob.pa

<https://orcid.org/0000-0003-1830-3133>.

²Programa de Desarrollo de las Ciencias Básicas (PEDECIBA), Universidad de la República, Uruguay.

³Hospital Santo Tomás, Ciudad de Panamá, Panamá.

⁴Laboratorio de Investigación en Vectores (LIVE), Centro de Investigación en Enfermedades Tropicales (CIET), Facultad de Microbiología, Universidad de Costa Rica, Costa Rica.

⁵Laboratorio de Parasitología, Universidad Nacional, Costa Rica.

⁶Laboratorio de Vectores y Enfermedades Transmitidas, Departamento de Ciencias Biológicas, CENUR Litoral Norte, Universidad de la República, Salto, Uruguay.

Corresponding author:

Sergio Bermúdez C. (Main Author), Address: Panamá.

E-mail: sbermudez@gorgas.gob.pa
Copyright © 2021 the Author(s)

Submitted: september 20, 2021

Reviewed: september 28, 2021

Approved: november 10, 2021

How to cite: Bermúdez S, Greco-Mastelari V, Zaldívar Y, Hernández M, Domínguez L, Montenegro VM, Venzal JM. Description of human infestations by ticks in Panama and Costa Rica. *Microbes Infect Chemother*. 2021; 1: e1241

Background

In clinical practices, the tick bites are related to the risks to transmission of viral, bacteria or protozoa diseases, according to the country or geographic distribution of the ticks (1,2). In fact, ticks are associated with a greater variety of pathogens than other groups of arthropods, including mosquitoes (3,4). However, in addition to their known vector capacity, the bites can provoke other manifestations that vary to mild or severe, e.g. allergies, toxicosis, paralysis, and a tick-induced red-meat allergy (alpha-gal syndrome) (5-8). These manifestations are produced by different components of tick saliva, that in general, have properties anticoagulant, antiplatelet, vasodilator and vasoconstrictors, anti-inflammatory, lytic, and immunomodulatory (9,10). In fact, the salivome of ticks is composed by a variety of multifunctional proteins, peptides and non-peptidic molecules, prostaglandins, among other components (11-13). As a whole, the saliva of the ticks allows “adapting” and handling the immune response the host for a prolonged feeding, including inhibits pain, itch, haemostasis, modulates angiogenesis and bite-site healing; which causes some of the damages

mentioned above (14,15).

In some cases, tick bites produce reactions that can be confused with infections caused by pathogens (16-18). For example, rash caused by some pathogenic *Rickettsia* and *Borrelia* species are among the symptoms of infection after tick bites; these could be similar to reactions caused by the effect of the saliva of the ticks (6,19,20). In this sense, reactions to tick bites must be differentiated from signs of pathogenic microorganism infection itself, such as exanthematous eruptions, inoculation eschar, erythema migrans and lymphadenopathy, which are common to various tick-borne diseases, such as Lyme Disease (LD), Tick-Borne Lymphadenopathy (TIBOLA), and other rickettsial diseases (17,18,21,22). Moreover, the Southern Tick-Associated Rash Illness (STARI), a condition caused by *Amblyomma americanum* bites and whose etiological agent is unknown, has been confused with LD due to the circular rash similar to that caused by this disease. This condition may be accompanied by symptoms as fatigue, headache, fever, and muscle aches (18). Therefore, in medical practice, it is

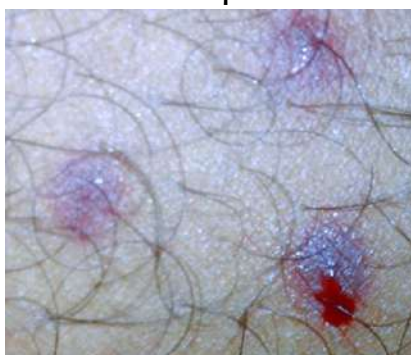
necessary to know the differences between the manifestations caused by the saliva of ticks, and those related to pathogens.

In Central America, tick bites to humans have been linked to the transmission of tick-borne relapsing fever (TBRF), ehrlichiosis, mild rickettsiosis, severe and fatal cases of *Rickettsia rickettsii* spotted fever, as well as allergies, dermal lesions, and paralysis (23-30). Despite the harmful effects caused by ticks, many aspects related to tick bites remain unknown to physicians and patients in this region, which can lead to confusion or misdiagnosis (31). It is possible that in Central America, Panama and Costa Rica are the countries with the most data related to ticks that parasitize humans and tick-borne diseases (TBD) (30); even so, few details are known about the species that parasitize people and even less about the effects they can cause. Therefore, the objective of this paper is to describe tick bites in humans and the related reactions in Panama and Costa Rica.

Case reports

Case 1: On August 2018, a 42 year-old man suffered three tick bites on his thigh while sleeping in a cabin in a rural town, in the province of Colón, Panamá. The three bites turned into blisters within hours (Fig. 1). Even after two days, the blisters emanated blood, and the affected person reported intense itching and slight pain around the blisters. In addition to the blisters and the irritation, he did not refer symptoms, and did not seek medical attention. The blisters diminished over the weeks, and the effect of the bites disappeared after 3-4 months. During a search into the cabin, several engorged (five adults) and non-engorged ticks (three nymphs and two adults) were collected in crevices in the walls and the ground. No other blood-sucking arthropods were found (e.g. bed bugs or kissing bugs) in the cabin. The ticks were preserved in 85% ethanol and sent to the laboratory of Ectoparasites in the Department of Medical Entomology of the Gorgas Memorial Institute for Health Studies, for their identification and analyses. Ticks were identified as *Ornithodoros puertoricensis* using molecular methods previously described (32).

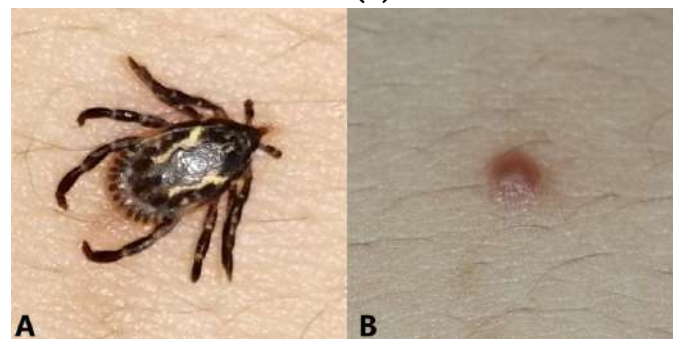
Figure 1: Lesions produced by *Ornithodoros puertoricensis* bites in a patient



Case 2: On February 16th 2021, a 22 year-old woman was working in a forest area of Gamboa, a rural town close to the Soberanía National Park and the east bank of the Panamá Canal basin. This same night, she got itchy and noticed a tick

attached to the left side of her umbilicus (Fig. 2a). The tick was extracted immediately and preserved in 80% ethanol. She did not refer symptoms in the following weeks, and did not need to apply any treatment on the bite site; however, a month later, a granuloma was evidenced in the area of the bite (Fig. 2b). In the same laboratory to the case 1, the tick was identified as *Amblyomma ovale* male, according to Bermúdez et al. (33). During laboratory observation, the mouthparts were found to be complete.

Figure 2: *Amblyomma ovale* male biting a woman (A). The site of the bite one month later (B).



Case 3: On March 9th 2021, a 44 year-old woman went hiking in the afternoon in a forest area of Ancón community, a suburban area in City of Panamá, Panamá. The following morning, she noticed a tick attached to right site of her nape, extracted it, and preserved in 80% ethanol. Afterwards, the woman noticed that a maculo-papular erythema developed at the site of the bite. During the follow 8 days, the lesion gradually expanded to the surrounding area, from 3 cm (2 days after tick removal) to 10 cm (8 days after tick removal) (Fig. 3). Additionally, the woman had pruritus and lymphadenopathy at the anterior cervical single chain lymph node, which was tender on palpation and warm to touch. She did not refer other symptoms in the following days. However, according to the recommendations to prevent tick-borne rickettsiosis in Panama (34), she was treated with doxycycline (100 mg, orally, every 12 hours for 7 days), and topic clotrimazol, neomicina and betametasona for the itch. After 5 days of treatment, the patient reported improvement of the pruritus, a decrease in the maculopapular lesion, and disappearance of the cervical adenopathy. In laboratory, the tick was identified as *Amblyomma cf. oblongoguttatum* female (33), and during the observation, the mouthparts were complete.

Case 4: On May 3rd 2021, a 71 year-old man visited his farm in El Valle de Antón, province of Coclé, Panamá. Five days later, he noted an engorged nymph attached to the inner side of his left ankle. An erythematous and purple plaque was observed at the site of the bite, which diminished within a few weeks (Fig. 4). After removing the tick, the patient only felt a little itching and a slight pain to the touch, so he did not apply any topical treatment, and did not reported additional symptoms or discomfort in the following weeks. In laboratory, the tick was kept alive in a controlled environmental incubator (78% humidity, 26°C), and after 15 days emerged an *Amblyomma mixtum* male (33).

Figure 3: Time-line of the dermal lesion after *Amblyomma cf. oblongoguttatum* bite. Lesion approximately 16 hours after the bite (A); 48 hours after the bite (B); 72 days after the bite (C); 96 days after the bite (D); 120 hours after (E); 144 days after the bite (F)

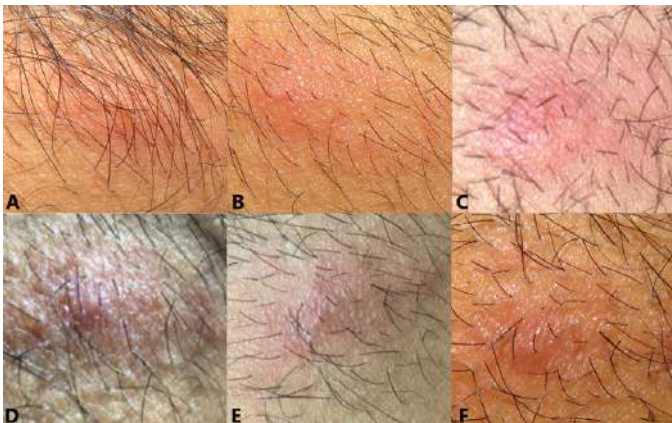
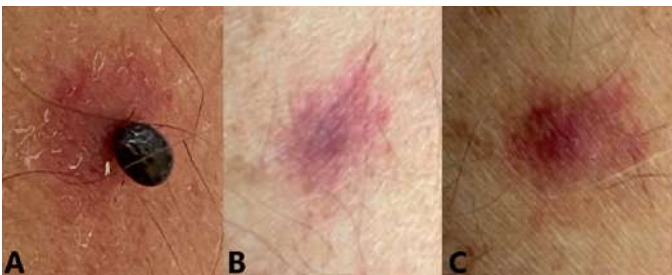
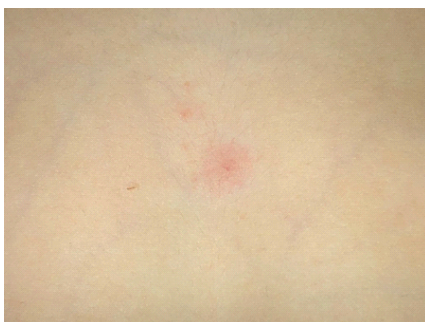

Figure 4: Erythematous lesion provoked by *Amblyomma mixtum* nymph. Parasitism site of the tick (A). Lesion two days after removal of the tick (B). Lesion five days after removal of the tick (C)



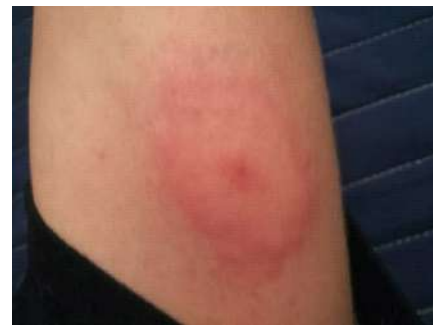Case 5: On August 16th 2020, a 6 year-old girl was walking in a forest area of San Isidro, province of Heredia, a rural town close to the Braulio Carrillo National Park (=1400 meters of high), Costa Rica. This same day, she got itchy and her parents noticed a tick attached to the chest (Fig. 5). The tick was extracted immediately and preserved in 80% ethanol. She did not refer fever or symptoms in the following weeks, therefore, did not need to treatment. The tick was sent to the laboratory of Parasitology Laboratory of the National University of Costa Rica (LP-UN), for their identification, corresponding to an *Ixodes cf. boliviensis* female (33,35). During the identification it was observed that the chelicerae were broken.

Figure 5: Bite provoked by *Ixodes cf. boliviensis*; the time of exposition was approximately 6 Hrs



Case 6: On August 2021 a 16 year old boy, was at the morning in his yard in Rio Segundo, province of Alajuela, near to the International Airport of Costa Rica. At night he felt itch and found the tick on his arm. Afterwards, he noticed a rash similar to erythema migrans-like rash in his arm, around the site of the bite (Fig. 6). The diameter of the rash was 4-5 cm and it took one week to disappear. There was not any fever or rash after the extraction of the tick. No medical treatment was necessary. The tick was sent to the laboratory of Parasitology Laboratory of National University of Costa Rica (LP-UNA), and identified as *A. ovale* male (33).

Figure 6: Erythema migrans-like caused by *Amblyomma ovale* male



Molecular assays in the ticks: To exclude potential TBD, ticks from the cases 1, 2, 3 and 4, were bisected longitudinally using sterile scalpels and washed with distilled water to remove ethanol. DNA was extracted using DNeasy™ tissue extraction kit (Qiagen, Hilden, Germany), following the manufacturer's criteria. Extracted DNA was tested by a battery of PCR protocols targeting bacterial 16S rRNA, *Rickettsia*, *Coxiella*, and *Borrelia* using specific primers and published protocols for each agent (36-39). The primers used for detecting these pathogens, and the corresponding product sizes are listed in Table 1. DNA of the target pathogens was not detected in any of the ticks analyzed.

Table 1. Primers used for amplification of bacterial genes in genomic DNA extracted from ticks

Gene	Organism	Primer	Sequence (5' to 3')	Amplicon size (bp)	Reference
16S rRNA	Most Eubacteria	fD1	AGAGTTTGATCCTG GCTCAG	1500	36
		rP2	ACGGCTACCTGT ACGACTT		
gltA	<i>Rickettsia</i> spp.	CS-78	GCAAGTATCGGTGA GGATGTAAT	401	37
		CS-323	GCTTCCTAAAAATT CAATAAATCAGGAT		
ompA	<i>Rickettsia</i> Spotted Fever Group	Rr190.70p	ATGGCGAATATTTT TCCAAAA	532	37
		Rr190.602n	AGTGCAGCATTCCG TCCCCCT		
IS1111	<i>Coxiella burnettii</i>	CoxP4	GGCTCCGTGGTGAT GG	435	38
		CoxM9	GTCCCCGTTCAACA ATTCG		
flaB	<i>Borrelia</i> sp.	FlaLL	ACATATTCAGATGC AGACAGAGGT GCAATCATAGCCAT TGCAGATTGT	665	39

Discussion

We described six cases of tick bites in people from different urban, rural and wild regions in Panamá and Costa Rica. In both countries, the environmental and anthropic differences of each area influence in the diversity of ticks (40,41). In this sense, in the lowlands of these countries the most of the anthropophilic Ixodidae and Argasidae ticks, correspond to the genera *Amblyomma* and *Ornithodoros*, respectively, and there is less information of *Rhipicephalus* biting human (33). In the highlands (+1400 meters over sea level) there are few reports of ticks biting humans and correspond to *I. cf. boliviensis* and *Ornithodoros kelleyi* (33,42).

Among the manifestations found in the patients were blisters, maculo-papular localized rash, granuloma, lymphadenopathy or erythema migrans-like rash, which are among the most commonly reported reactions to the tick bites (15,43,44). In our group of affected, these manifestations lasted to heal from weeks to several months after the removal of the ticks, but were not accompanied by symptoms consistent with infections; in fact, after months of having contact with the ticks, the patients did not manifest discomfort.

Although dermatoses caused by tick saliva is related with the inflammatory response of the host or with the sensitivity of each person, there are other factors that can exacerbate the reaction, as the number, stage, and the tick species, as well the time of exposure to the bites, and/or constant and repetitive ticks bites (45,46). Furthermore, the biological differences between Argasidae and Ixodidae lead to different reactions in parasitized people.

In general, Argasidae do not penetrate deeply into the skin, and feed during the night when the hosts are sleeping. In this sense, although cases of *Ornithodoros* bites have been registered in people who visit caves or guano areas, most of the reports are related to intradomiciliary conditions (5,24). The ingestion of blood is rapidly (for less than an hour) in nymphs and adults, but the feeding of the larvae can last 2-4 days (47,48). Consequently, *Ornithodoros* may go unnoticed when biting, in particular in human dwellings, and are therefore reported less frequently than hard ticks (46,49). These characteristics are consistent with the anamnesis of case 1, since the affected person did not observe the ticks while they were feeding. The bites showed the characteristic formation of blisters keeps the blood of the hosts flowing. Although these lesions can be considered “benign”, some cases associated with certain species of *Ornithodoros* can be extremely painful and produce severe effects, causing strong allergic reactions, and even anaphylactic shocks (24,43,46,50-52). Moreover, some *Ornithodoros* species (e.g. *O. talaje*, *O. rudis*, among others) are also related to the transmission of TBRF, which is among the most important neglected diseases in the region (26).

The rest of the affected were parasitized by three species of Ixodidae and, as expected, the degree of alteration

was different according to the ticks and the person. With some exceptions related to pets or work activities in farms or veterinary clinics, Ixodidae bites are most related to outdoors activities (53,54). Ixodidae feeding for several days and can penetrate deeply into the dermis or hypodermis, depending on the species of tick and the location on the skin (48). Beside to the damages to the skin, during this prolonged feeding, the amount of saliva inoculate on their host is variable, as well is the variety of its components (55). These “cocktail” of components affect the inflammatory response and are responsible of cutaneous and subcutaneous manifestations, and possibly causes swollen glands (31). Moreover, in the case of vasodilators or other components of the saliva, their persistence produce bruising around the bite, which cause redness and subsequent clearing for would lyse of the blood cells.

Regarding to our observation in the case 2, the patient affected had little exposure to the tick and did not present other symptoms; even so, the lesion at the bite site remained as a granuloma for several weeks. The granulomas associated with tick bites may be caused by the breakdown of the mouthparts (hypostoma and chelicera) within the skin, or for the long-term reaction to the salivary, causing inflammation around them (16,56). In this patient, it is possible that the inflammation was due to a local reaction to the bite, as has been suggested by other authors (31,56). This is similar to case 5, as the time between possible exposure and a removal of the tick was short; but, despite the chelicerae was broken, not granuloma was evidenced in the following days. Regarding to the case 3, since the affected person noticed the tick at least 12 hours after hiking, so it is possible that the parasitism lasted longer, which produced greater effects and symptoms as the lymphadenopathy. In this patient, the absence of fever or malaise could rule out a disease transmitted by the tick; though the norms in Panama recommend the use of doxycycline when suspected of a potential rickettsial infection (34). All these cases, the bites were caused by single adult ticks.

In the case 4, the bite was caused by a nymph that remained attached for almost a week, and there were still no significant symptoms. Because of their small size, immature ticks are more difficult to locate and extract, and several bites could cause an allergic reaction. Granulomatous lesions caused by bites of nymphs of *A. mixtum* (referred to as *A. cajennense*) have been described that took more than 2 years to heal (53). Furthermore, with the case 4, it was possible to confirm that humans are suitable hosts and allow the complete development of *A. mixtum* nymphs, a fact reported also for *tis* species and *A. coelebs* nymphs in Brazil (53,54).

On the other hand, in the case 6, the manifestations in the skin are consistent with erythema migrans-like rash, which could be defined as a skin lesion that expands around the tick bite, and that can remain for a period of days to weeks. Although this type of manifestation was considering as one of the characteristic of LD, the absence of systemic symptoms (e.g. fever, sickness) in following months to the extraction of the tick, indicate a reaction produced by the tick saliva. Until

now, LD has been no confirming in Costa Rica, despite the report of a human suspected case (57), and for the presence of the *Borrelia burgdorferi* complex in *I. cf. boliviensis* from Panama (35). LD is related to the transmission of *Ixodes ricinus* group in North Hemisphere. This is the first report of a erythema migrans-like rash caused by *A. ovale* in Costa Rica. This tick species has been related to a case of paralysis in a U.S. soldier in Panama, and has been implicated to the transmission of *Rickettsia parkeri* (23,58).

Finally, despite the harmful effects of the tick bites, these are generally underestimated by the people affected and by physicians. Even when the bites are not associated with the transmission of pathogens, represent discomfort that can last longer than it should if those affected are not treated in time, or cause severe complications as such anaphylactic shock, paralysis or secondary infections and myiasis, which can further complicate the healing of the affected tissue (23,43,53). In other words, tick bites can affect the quality of life of those who suffer from them, if they are not treated properly (31). Moreover, the presence of cutaneous or subcutaneous manifestations could be confused with TBD, which can cause erroneous reports due to the lack of conclusive diagnoses. All these facts indicate that the tick bites constitute a public health problem what goes unnoticed in many countries.

Acknowledgments

Authors thanks to Alejandro Cabezas-Cruz and Álvaro Faccini-Martínez for their comments and suggestions of the manuscript.

Author Contributions

Conceptualization, SB, VG-M, YZ, JV; Methodology, MH, LD, YZ; Validation, VG-M, YZ, MH, SB; Original Data: SB, LD, VM; Formal Analysis, SB, MH, LD, YZ; Investigation, SB, LD, JV, VM; Writing—Original Draft Preparation, SB, VG; Writing – Review & Editing, SB, JV.

Institutional Review Board Statement

This work was authorized by the Gorgas Memorial Institute's Bioethics Committee of Investigation (GMIBCI) under reference No. 111/CBI/ICGES21.

Informed Consent Statement

All of the people affected for tick-bites were notified and permission to use photos and general information was granted for their inclusion in this paper, according to the regulations of GMIBCI.

Conflicts of Interest

The authors declare no conflict of interest.

References

1. Hoogstraal H. Argasid and Nuttalliellid ticks as parasites and vectors. *Adv Parasitol.* 1985; 24: 135-238.
2. Estrada-Peña A, Jongejan F. Ticks feeding on humans: a review of records on human-biting Ixodoidea with special reference to pathogen transmission. *Exp Appl Acarol.* 1999; 23(9): 685–715.
3. de la Fuente J, Antunes S, Bonnet S, Cabezas-Cruz A, Domingos A, Estrada-Peña A, et al. Tick-pathogen interactions and vector competence: identification of molecular drivers for tick-borne diseases. *Front Cell Infect Microbiol.* 2017; 7: 114.
4. Banović P, Díaz-Sánchez A, Galon C, Simin V, Mijatović D, Obregón D, et al. Humans infested with *Ixodes ricinus* are exposed to a diverse array of tick-borne pathogens in Serbia. *Ticks Tick Borne Dis.* 2021; 12(2): 101609.
5. Haag-Wackernagel D, Bircher A. Ectoparasites from feral pigeons affecting humans. *Dermatol.* 2010; 220(1): 82-92.
6. Cabezas-Cruz A, Valdés J. Are ticks venomous animals? *Front Zool.* 2014; 11: 47.
7. Carter C, Yambem O, Carlson T, Hickling G, Collins K, Jacewicz M, et al. Male tick bite: A rare cause of adult tick paralysis. *Neurol Neuroimmunol Neuroinflamm.* 2016; 3(4): e243.
8. Young I, Prematunge C, Pussegoda K, Corrin T, Waddell L. Tick exposures and alpha-gal syndrome: A systematic review of the evidence. *Ticks Tick Borne Dis.* 2021; 12(3): 101674.
9. Šimo L, Kazimirova M, Richardson J, Bonnet S. The essential role of tick salivary glands and saliva in tick feeding and pathogen transmission. *Front Cell Infect Microbiol.* 2017; 7: 281
10. Yadav N, Upadhyay R. Tick saliva toxins, host immune responses and its biological effects. *Int J Pharm Pharm Sci.* 2021; 13(8): 9-19.
11. Nuttall P. Wonders of tick saliva. *Ticks Tick Borne Dis.* 2019; 10(2): 470-481.
12. Kim T, Tirloni L, Pinto M, Diedrich J, Moresco J, Yates III J, et al. Time-resolved proteomic profile of *Amblyomma americanum* tick saliva during feeding. *PLoS Negl Trop Dis.* 2020; 14(2): e0007758.
13. Mans B. Quantitative visions of reality at the tick-host interface: biochemistry, genomics, proteomics, and transcriptomics as measures of complete inventories of the tick sialome. *Front Cell Infect Microbiol.* 2021; 10: 574405.
14. Mans B, Gothe R, Neitz W. Tick toxins: perspectives on paralysis and other forms of toxicoses caused by ticks. Bowman A, Nuttall P, edited. *Ticks: Biology, Disease and Control*, 1st ed. New York: Cambridge University Press. 2008, p.108-126.
15. Haddad V Jr, Haddad M, Santos M, Cardoso J. Skin manifestations of tick bites in humans. *An Bras Dermatol.* 2018; 93(2): 251-255.
16. Tobias N. Tickbite granuloma. *J Invest Dermatol.* 1949; 12: 255-259
17. Sharma A, Jaimungal S, Basdeo-Maharaj K, Chalapathi A, Teelucksingh S. Erythema migrans-like illness among Caribbean islanders. *Emerg Infect Dis.* 2010; 16(10) 1615-

- 1617.
18. Abdelmaseih R, Ashraf B, Abdelmasih R, Dunn S, Nasser, H. Southern Tick-Associated Rash Illness: Florida's Lyme Disease Variant. *Cureus*. 2021; 13(5): e15306
 19. Billeter S, Blanton H, Little S, Levy M, Breitschwerdt E. Detection of *Rickettsia amblyommii* in association with a tick bite rash. *Vect Born Zoon Dis*. 2007; 7(4): 607-610.
 20. Ito K, Taniguchi H, Ohtaki N, Ando S, Kawabata H. A first case of tick bite by *Amblyomma coelebs* in Japan. *Journal of Dermatol*. 2017; 45(2): 243-244.
 21. Oteo J, Ibarra, V, Blanco J, Martínez de Artola V, Márquez F, Portillo A, et al. Dermacentor-borne necrosis erythema and lymphadenopathy: clinical and epidemiological features of a new tick-borne disease. *Clin Microbiol Infect*. 2004; 10(4):327-31.
 22. Natsuaki M, Takada N, Kawabata H, Ando S, Yamanishi K. Case of tick-associated rash illness caused by *Amblyomma testudinarium*. *J Dermatol*. 2014; 41(9):834-836.
 23. Baeza C. Tick Paralysis-Canal Zone, Panama. *Mort Morb Wkly Rep*. 1979; 28(36):428-433.
 24. Vargas V. Occurrence of the bat tick *Ornithodoros (Alectorobius) kelleyi* Cooley & Kohls (Acari: Argasidae) in Costa Rica and its relation to human bites. *Rev Biol Trop*. 1984; 32(1):103-107.
 25. Bouza-Mora L, Dolz G, Solórzano-Morales A, Romero-Zuñiga J, Salazar-Sánchez L, Labruna M, et al. Novel genotype of *Ehrlichia canis* detected in samples of human blood bank donors in Costa Rica. *Ticks Tick Borne Dis*. 2017; 8(1):36-40.
 26. Lopez, J., Krishnavahjale, A., Garcia, M., Bermudez, S., 2016. Tick-Borne Relapsing Fever Spirochetes in the Americas. *Vet. Sci.*, 3, 16. doi:10.3390/vetsci3030016.
 27. Daza C, Osorio J, Santamaria A, Suárez J, Hurtado A, Bermúdez S. Caracterización del primer caso de infección humana por *Ehrlichia canis* en Panamá. *Rev Med Pan*. 2018; 38(3):63-68.
 28. Bermúdez S, Troyo A. A review of the genus *Rickettsia* in Central America. *Res Rep Trop Med*. 2018; 9:103-112.
 29. Zaldivar Y, Hernández M, Domínguez L, Saénz L, Montilla S, Barnett de Antinori M, Krawczak F, Bermúdez SE. Isolation of *Rickettsia rickettsii* from an outbreak of Rocky Mountain spotted fever in Panama. *Emerg Infect Dis*. 2021; <https://doi.org/10.3201/eid2704.201606>.
 30. Charles R, Bermúdez S, Banović P, Alvarez D, Díaz-Sánchez A, Corona-González B, Etter E., Rodríguez González I, Ghafar A, Jabbar A, Moutailler S, Cabezas-Cruz A. Ticks and Tick-Borne Diseases in Central America and the Caribbean: A One Health Perspective. *Pathogens*. 2021; 10, 1273. <https://doi.org/10.3390/pathogens10101273>
 31. Weber N, Trujillo-Trujillo J, Krücken J, Michl C, Hidalgo M, Apprätz-Ippolito G, et al. Tick-bite-associated chronic pruritic lesions in an Afro-descendant population in the Cauca Department, Colombia. I. Clinical features and impact on health. *Int J Dermatol*. 2020; 59(12):1491-1501.
 32. Mangold A, Bargues M, Mas-Coma S. Mitochondrial 16S rRNA sequences and phylogenetic relationships of *Rhipicephalus* and other tick genera among *Metastrata* (Acari: Ixodidae). *Parasitol Res*. 1998. 84:478-484
 33. Bermúdez S, Apanaskevich D, Domínguez L. Garrapatas Ixodidae de Panamá. Guglielmone A, Editor. ISBN 978-9962-699-25-5. 2018; 129 pp.
 34. Guía para el abordaje Clínico y Epidemiológico de las Rickettsiosis en Panamá, para su utilización en todas las instalaciones del sistema público de salud. https://www.gacetaoficial.gob.pa/pdfTemp/28852/Gaceta_No_28852_20190903.pdf, Accessed 03th sep 2021.
 35. Bermúdez S, Félix M, Domínguez L, Kadoch N, Muñoz-Leal S, Venzal J. Molecular screening for tick-borne bacteria and hematozoa in *Ixodes* cf. *boliviensis* and *Ixodes tapirus* (Ixodida: Ixodidae) from western highlands of Panama. *Cur Res Parasitol Vector-Borne Dis*. 2021; 1:100034
 36. Weisburg W, Barns S, Pelletier D, Lane D. 16S ribosomal DNA amplification for phylogenetic study. *J Bacteriol*. 1991; 173(2): 697-703.
 37. Oteo J, Nava S, Sousa R, Mattar S, Venzal J, Abarca K, et al. Guías Latinoamericanas de la RIICER para el diagnóstico de las rickettsiosis transmitidas por garrapatas. *Rev Chil Infect*. 2014; 31(1): 54-65.
 38. Panning M, Kilwinski J, Greiner-Fischer S, Peters M, Kramme S, Frangoulidis D, et al. High throughput detection of *Coxiella burnetii* by real-time PCR with internal control system and automated DNA preparation. *BMC Microbiol*. 2008; 8: 77.
 39. Barbour A, Maupin G, Teltow G, Carter C, Piesman J. Identification of an uncultivable *Borrelia* species in the hard tick *Amblyomma americanum*: possible agent of a Lyme disease-like illness. *J. Infect. Dis*. 1996; 173(2): 403-409.
 40. Bermúdez S, Castro A, Trejos T, García G, Gabster A, Miranda R, Zaldivar Y, Paternina L. Distribution of Spotted Fever Group *Rickettsiae* in hard ticks (Ixodida: Ixodidae) from Panamanian urban and rural environments. *EcoHealth*. 2016. 13:274-284. <http://link.springer.com/article/10.1007/s10393-016-1118-8>.
 41. Montenegro V, Delgado M, Miranda R, Domínguez L, Vargas-Muñoz M, Bermúdez S. Free-living hard ticks (Ixodida: Ixodidae) from three different natural environments of Costa Rica. *Ticks and Tick-Borne Diseases*. 2021. On-line: <https://doi.org/10.1016/j.ttbdis.2021.101811>
 42. Vargas V. Occurrence of the bat tick *Ornithodoros (Alectorobius) kelleyi* Cooley & Kohls (Acari : Argasidae) in Costa Rica and its relation to human bites. *Rev. Biol. Trop*. 1984. 32, 103-107.
 43. Reck J, Marks F, Guimarães J, Termignoni C, Martins J. Epidemiology of *Ornithodoros brasiliensis* (mouro tick) in the southern Brazilian highlands and the description of human and animal retrospective cases of tick parasitism. *Ticks Tick Borne Dis*. 2013; 4 (1-2):101-109
 44. Kannangara D, Patel P. Report of non-Lyme, erythema migrans rashes from New Jersey with a review of possible role of tick salivary toxins. *Vector Borne Zoonotic Dis*. 2018; 18(12):641-652.
 45. Valls A, Pineda F, Belver M, Caballero T, López M. Anaphylactic shock caused by tick (*Rhipicephalus sanguineus*). *J Investig Allergol Clin Immunol*. 2007; 17(4); 279-280.
 46. Llanos-Soto S, Muñoz-Leal S, Gatica J, Misad C, González-Acuña D. Human toxicosis caused by the tick *Ornithodoros spheniscus* in a Chilean national park. *Travel Med Infect Dis*. 2020; 37:101811.
 47. Venzal J, Estrada-Peña A, de Luco D. Effects produced by

- the feeding of larvae of *Ornithodoros* aff. *puertoricensis* (Acari: Argasidae) on laboratory mice. *Exp Appl Acarol.* 2007;42(3):217-223.
48. Estrada-Peña A. *Garrapatas: Morfología, fisiología y ecología.* 1th ed. Editorial Servet. ISBN9788416315277. 2015; 104 pp.
49. Bermúdez S, Castillo E, Pohlenz T, Kneubehl A, Krishnavajhala A, Domínguez L, et al. New records of *Ornithodoros puertoricensis* Fox 1947 (Ixodida: Argasidae) parasitizing humans in rural and urban dwellings, Panama. *Ticks Tick Borne Dis.* 2017; 8(4): 466-469.
50. Labruna M, Marcili A, Ogrzewalska M, Barros-Battesti D, Dantas-Torres F, Fernandes A, et al. New records and human parasitism by *Ornithodoros mimon* (Acari: Argasidae) in Brazil. *J Med Entomol.* 2014; 51(1), 283-287.
51. de Oliveira S, Bitencourth K, Borsoi A, de Freitas F, Coelho G, Amorim M, et al. Human parasitism and toxicosis by *Ornithodoros rietcorraei* (Acari: Argasidae) in an urban area of Northeastern Brazil. *Ticks Tick Borne Dis.* 2018; 9(6):1494-1498.
52. Muñoz-Leal S, Costa F, Faccini-Martínez Á. Mild toxicosis after the bite of *Ornithodoros rietcorraei*: Images of a brief time-line description. *Travel Med Infect Dis.* 2019; S1477-8939(18)30316-8.
53. Varma R. Ticks (Ixodidae) of British Honduras. *Trans Royal Soc Trop Med Hyg.* 1973; 67(1): 92–102.
54. Garcia M, Matias J, Aguirre A, Csordas B, Szabó M, Andreotti R. Successful feeding of *Amblyomma coelebs* (Acari: Ixodidae) nymphs on humans in Brazil: skin reactions to parasitism. *J. Med. Entomol.* 2015; 52(2): 117–119.
55. Glatz M, Means T, Haas J, Steere A, Müllegger R. Characterization of the early local immune response to *Ixodes ricinus* tick bites in human skin. *Exp Dermatol.* 2017; 26(3):263-269.
56. Hirota K, Kurosawa Y, Goto K, Adachi K, Yoshida Y, Yamamoto O. Tick Bite Granuloma: Recommendations for Surgical Treatment. *Yonago Acta Med.* 2015; 58(1):51-52.
57. Villalobos-Zúñiga M, Somogyi T. Enfermedad de Lyme aguda en Costa Rica. Descripción del primer caso autóctono. *Acta Med. Costarric.* 2012; 54(1): 55-58.
58. da Paixão A, Martins TF, Muñoz-Leal S, Rodrigues AC, Pinter A, Luz HR, Angerami RN, Labruna MB. A human case of spotted fever caused by *Rickettsia parkeri* strain Atlantic rainforest and its association to the tick *Amblyomma ovale*. *Parasit Vectors.* 2019; 12(1): 471. doi: 10.1186/s13071-019-3730-2.