



Surgical Management of Mandibular Odontogenic Myxoma Utilizing CAD/CAM Technology: A Case Report

Orvokki Helinko^{1,2*}; Alexandria L Irace, BA^{1,3}; Anni Suomalainen⁴; Jaana Hagström^{2,5,6}; Karri Mesimäki¹

¹Department of Oral Maxillofacial Disease, Helsinki University Central Hospital.

²Department of Pathology, University of Helsinki and Helsinki University Hospital.

³Columbia University Vagelos College of Physicians and Surgeons.

⁴Department of Radiology, University of Helsinki and HUS Radiology (Medical Imaging Center).

⁵Translational Cancer Research Program Unit, University of Helsinki.

⁶Department of Oral Pathology and Radiology, University of Turku.

*Corresponding Author(s): Orvokki Helinko

Department of Oral Maxillofacial Disease, Helsinki University Central Hospital, Korpraalintie 11b, 02680 Espoo, Finland.
Tel: +358503499049;
Email: orvokki.helinko@gmail.com

Abstract

Background: Odontogenic myxoma (OM) is a benign intraosseous tumour of the jaw usually treated by surgery. Computer-aided design and manufacturing (CAD/CAM) technology may optimize preoperative planning of the resection and jaw reconstruction.

Case Report: A 29-year-old female was diagnosed with mandibular odontogenic myxoma. A large, benign but potentially infiltrating, and locally aggressive tumour required radical surgical treatment. CAD/CAM technology facilitated preoperative planning for block resection and immediate reconstruction of the mandible. CAD/CAM was utilized to determine the resection margins planned according to cone beam computed tomography (CBCT) data and manufacture the reconstruction plate and cutting guides.

Clinical implications: CAD/CAM can be utilized to produce 3D models of OM, cutting guides, and patient-specific implants, making it a valuable tool in the management of this disease. Future investigations should study how operative times and clinical outcomes are affected by this technology.

Received: Feb 15, 2021

Accepted: Mar 15, 2021

Published Online: Mar 17, 2021

Journal: Journal of Case Reports and Medical Images

Publisher: MedDocs Publishers LLC

Online edition: <http://meddocsonline.org/>

Copyright: © Helinko O (2021). *This Article is distributed under the terms of Creative Commons Attribution 4.0 International License*

Keywords: Odontogenic myxoma; Computer-aided design and manufacturing; 3D printing; Additive manufacturing; Mandible reconstruction; Virtual surgical planning.

Introduction

Odontogenic Myxoma (OM) is a rare, benign intraosseous jaw tumour that most commonly occurs in young adults. Its myxoid extracellular matrix is formed by stellate and spindle-shaped neoplastic cells [1-3]. Consistency of the tumour can range from gelatinous to firm, depending on the amount of collagen. When more collagen is present, the term 'Myxofibroma' may be used instead of 'Myxoma' [2]. OM is often asymptomatic, but tooth displacement is a common problem and root resorption may occur [1-4]. Symptoms include swelling, facial asymmetry, pain, and mandibular nerve paresthesia [4].

Odontogenic myxomas are often found incidentally on radiographs as multilocular or unilocular radiolucencies with distinct to poorly defined borders and a "Soap-Bubble", "Honeycomb", or "Tennis Racket" appearance. On CT or MRI imaging, the margins of the tumour are represented more accurately; the actual anatomic limits are often diffuse and a capsule is absent. [2,4] Although OM is considered benign [1], it is often locally aggressive and infiltrating [2,3].

The treatment of choice for OM is conservative or radical surgery. Small lesions (<3 cm) are usually treated conservatively – via enucleation, curettage, or both – whereas larger lesions often require more radical approaches, including resection with continuity or segmental/block resection [3,4]. Recurrence is known to occur in approximately 25% of cases on average [1,2,5,6], but this rate depends on treatment [3,6,7]. After conservative surgery, neoplastic cells may persist in small bone marrow spaces, causing recurrence that typically presents within 2 years of surgery [7-9]. After radical procedures, reconstruction of the jaw is often necessary [10].

Traditionally, reconstructive surgery has required intraoperative planning of osteotomies and bending of reconstruction plates by hand. This requires practice and experience to be effective, and the process can be time-consuming and inaccurate [10]. The main principles of successful reconstruction have persisted until today, but modern technology has given us new methods to obtain more satisfactory clinical outcomes and perform reconstructive procedures more efficiently. In particular, computer-aided design and manufacturing (CAD/CAM) and three-dimensional (3D) printing and / or virtual planning have facilitated reconstructive procedures [10-14]. Using these techniques, osteotomies may be planned preoperatively, and reconstruction plates can be manufactured individually to fit the defect precisely, with no intraoperative changes needed. These strategies may reduce operative time, which increases efficiency [13] and lowers patient morbidity [15].

In the current study, we represent a case of multilocular odontogenic myxoma in a young female patient who underwent block resection and immediate reconstruction. We discuss our utilization of CAD/CAM techniques for preoperative planning and reconstruction and evaluate how these strategies may improve management of odontogenic myxoma.

Case report

Multilocular radiolucency was detected in the left ramus of the mandible on a routine panoramic radiograph in a 29-year-old female (Figure 1). The lesion extended from the neck of the condyle to region d. 37 distally. There were no clinical findings nor symptoms. OM was diagnosed histopathologically based on two biopsies obtained from the lesion.

The treatment planning and operation took place at The Oral and Maxillofacial Surgery Ward of the Eye and Ear Hospital, Hospital District of Helsinki and Uusimaa, Finland. 3D representations (Figure 2), cutting guides, and the patient specific implant (PSI-plate) were designed and manufactured with the assistance of a medical modelling company, Planmeca Ltd, Helsinki, Finland.

Block resection followed by immediate reconstruction using a PSI-plate and iliac free tissue transfer was planned. CAD/CAM technology facilitated preoperative planning for removal of the tumour and reconstruction of the mandible. First, a CBCT scan was performed, and the DICOM data of the CBCT examination was sent to the modelling company. Company provided digital 3D representations and a 3D-printed model of the skull. The surgical margins were able to be determined: The condylar margin was measured as 4 mm to preserve as much of the condyle as possible. The anterior margin was measured as 6-7 mm, with extraction of tooth 37. The reconstruction plate and the cutting guides were designed. The PSI-plate and condylar cutting guide were manufactured out of titanium. The condylar cutting guide needed to be very thin to fit the narrow space of the condyle. Requirements for the thickness of the anterior cutting guide were not as precise, allowing it to be manufactured out of plastic.

The operation was conducted under general anesthesia with nasal intubation. A preauricular incision was made and the surface of the left condyle was exposed. Marginal incisions were made buccal and lingual from region d.36 to d.33. Periosteum was pushed aside and with that the m. masseter was detached from the mandible. The nervus mentalis was cut.

The insertion of the m. temporalis was separated from processus coronoideus, and the coronoideus was cut to visualize the lingual side. Nervus mandibulae was identified and cut. The insertion of the m. pterygoideus medialis and posterior aspect of the m. mylohyoideus were detached from mandible. The cutting guides were each attached with two screws. The resection was completed intraorally with oscillating saws. After the resected bone was lifted out, the PSI-plate was inserted into the defect and attached with 16 mm screws (diameter 2 mm), two for the condyle and five for the anterior mandible. Simultaneously, the free tissue transfer was obtained from left iliac cancellous bone. Two grams of Bio-Oss and blood were added to the bone marrow mass, the implant was filled, and all wounds were sutured.

Due to a previous allergic reaction to penicillin and cephalexin, the choice of postoperative antibiotics was moxifloxacin and metronidazole. For pain management, one dose of oxycodone was given after the operation, and ibuprofen and codeine-paracetamol-combination drug were prescribed to use as necessary.

After the operation, a sharp edge on the alveolar crest was detected. A small operation of planing the crest was performed two days after the main operation. The patient was discharged one day later and was instructed to eat soft, mashed foods for three months. Postoperative panoramic radiograph (Figure 3) and Towne view x-ray were taken one day postoperatively showing good fitting of the PSI-plate.

For histopathological examination, the resected bone block was fixated with formalin and sawed into ten pieces (Figures 4 & 5). Seven of them were treated with Ethylenediaminetetraace-

tic acid and the rest with quick hydrochloric acid decalcification. Myxomatous, infiltrating tissue was found between bone trabeculae. Bone tissue was vital and osteoblastic zones were seen on the outer surface. The original diagnosis was confirmed, and the margins were measured. The condylar margin was 2.2 mm and the anterior margin was 8 mm. Follow-up panoramic radiograph was taken four months postoperatively and CT examination was done nine months postoperatively. The fit of the PSI was satisfactory, and the bone graft was in suitable contact with the resection lines and showed good maturation. The left side condyle was located somewhat latero-caudal in comparison to the contralateral side and secondary arthrosis was detected in the condyle. The patient has remained stable at 10 months of follow-up and she will be followed carefully both clinically and radiologically, given the high recurrence rate of OM.

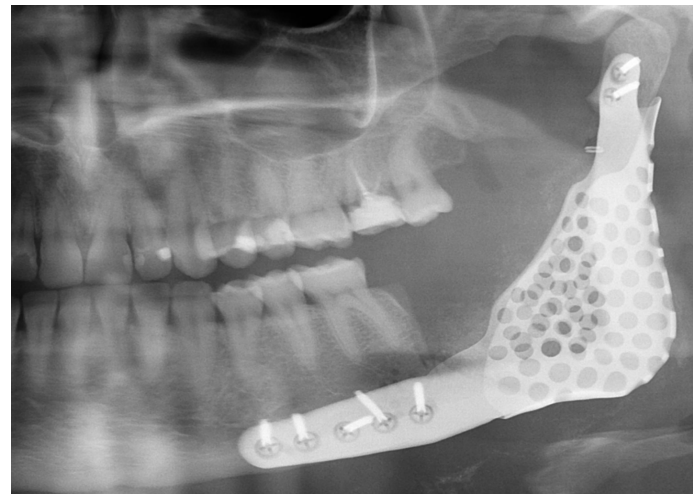


Figure 3: Post-operative panoramic radiograph (cropped) of the reconstructed mandible with the PSI-plate made of titanium.

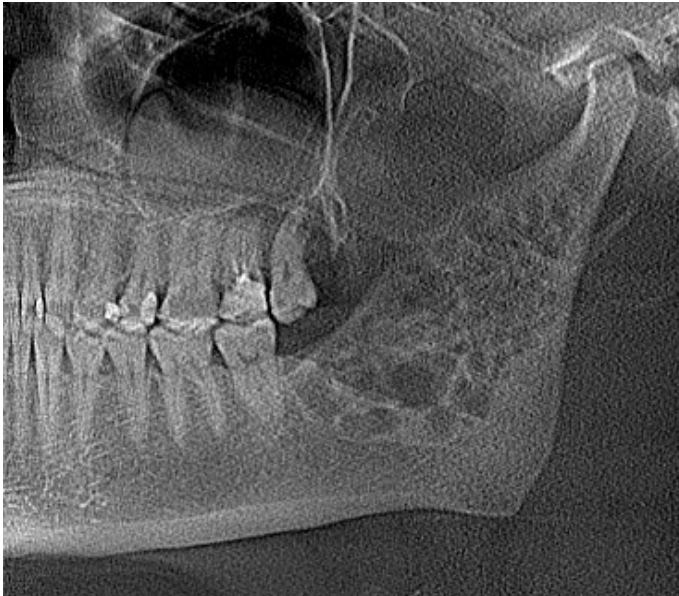


Figure 1: A panoramic radiograph (cropped), which was obtained on a routine examination, showed a multilocular radiolucency in the left ramus of the mandible, extending from the neck of the condyle to region d. 37 distally.

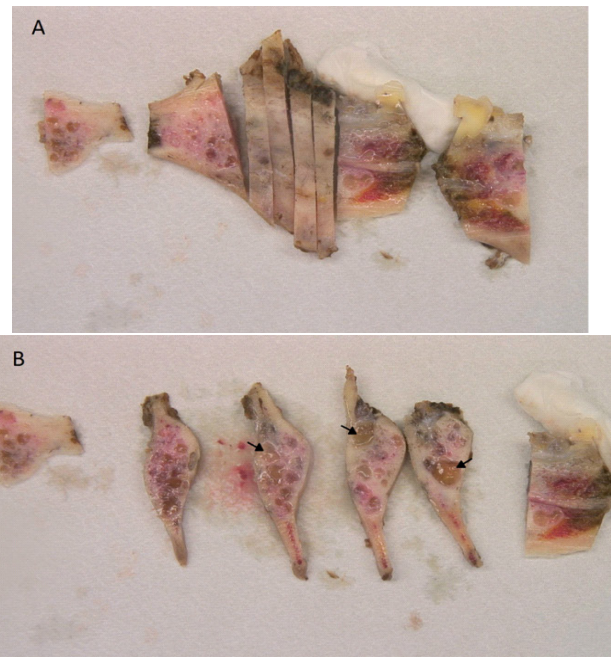


Figure 4: (A) The resected bone block was fixed with formalin and sawed into ten pieces for the histopathological examination. (B) Myxomatotic tissue visible inside the bone tissue (arrows).

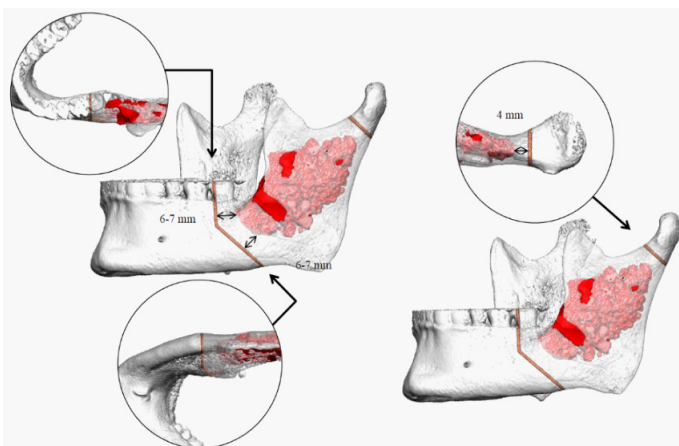


Figure 2: A Computer assisted planning of the osteotomy, according to a CBCT scan. Radiologically the condylar margin of the block resection was measured as 4 mm and the anterior margin as 6-7 mm, with extraction of tooth 37.

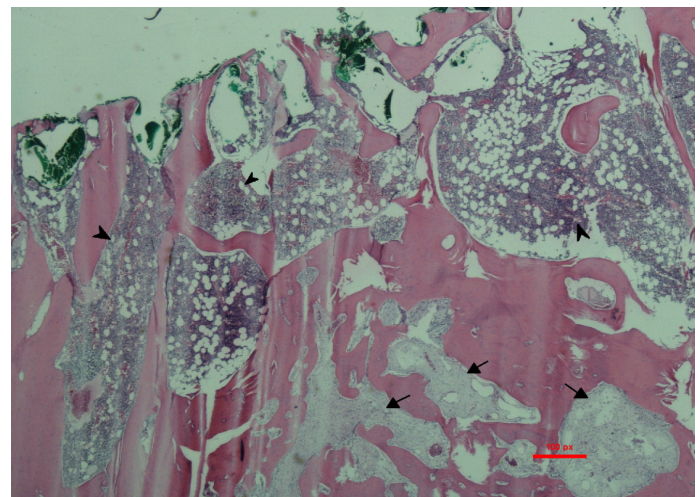


Figure 5: Histological analysis of the bone specimen showed normal bone marrow (arrow heads) and loose myxomatous tumor tissue (arrows) in hematoxylin and eosin stain.

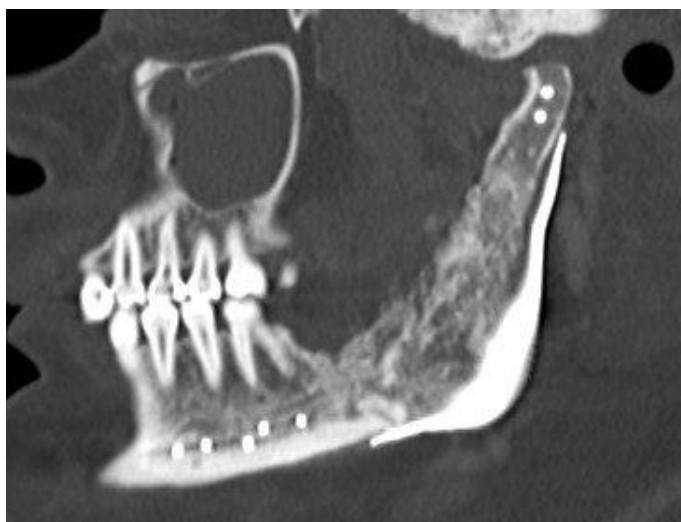

Figure 6: Sagittal view of the CT scan of the mandible 10 months after the operation. The formation of new bone tissue can be seen inside the PSI-plate.

Discussion

Recurrence rate of OM is fairly high (~25%) and seems to depend on treatment [1,3,7]. The treatment of choice for OM is either conservative or radical surgery. To prevent recurrence, the removal of the neoplasm should be complete, but the lack of encapsulation and potential for local invasion in cancellous bone makes complete resection challenging [3,7].

There is a lack of consensus regarding the proper surgical treatment of OM [1,3,7]. The usual protocol is conservative surgery (enucleation and curettage) for lesions less than 3 cm in diameter, and radical surgery (resection with free margins) for larger lesions [2,4]. However, the advantages and disadvantages of different methods must be considered individually case by case. Of note, even larger lesions have been successfully treated with conservative surgery [7,16]. In addition, the greatest diameter does not relate completely to the true three-dimensional size of the tumour, and it is unclear whether diameter is sufficient to predict local aggressiveness and potential recurrence [7]. In a recent review of 426 published OM cases, treatment method was often determined by lesion diameter. Treatment method was the only variable that significantly affected recurrence rate. Other variables, such as tumour location, bone expansion, cortical bone perforation, locularity, tooth root resorption, odontogenic epithelial rests, and angular septa, did not show a significant influence on recurrence rate [3].

Even though radical surgery seems to be the most effective treatment to prevent recurrence, it can cause significant functional and aesthetic issues [4], often with longer hospitalizations and higher costs [16]. Conservative surgery is less invasive, and intraoral access to the lesion avoids causing facial defects [16,17]. There is no interference with facial growth in pediatric patients and harvesting autologous bone might not be necessary [17].

In our case, a block resection was the treatment of choice. Based on the large size of the tumour, conservative surgery would not have been possible. To optimize the surgical margins while preserving healthy tissue, CAD/CAM technology was utilized. Digital 3D representations of the skull and the tumour were created from CBCT scans and a physical model was printed using a 3D-printer. This allowed the margins to be measured preoperatively: 4 mm at the condylar margin and 6-7 mm at

the anterior margin. Postoperatively, the surgical margins were measured as 2.2 mm and 8 mm, respectively. The tumorous growth pattern likely caused the histological margin to be smaller than the preoperative margin. OM may grow between bony trabeculae in a way that cannot be detected by radiological examination.

After radical procedures, reconstruction of the jaw is often necessary [10]. Reconstructive procedures may cause a variety of issues involving the loss of mandibular continuity, such as airway compromise, mastication and swallowing difficulties, speech problems, and aesthetic defects [15]. In our case, despite the large resection, we were able to take into account the functional and aesthetic issues. The functionality of the temporomandibular joint remained intact, and after the uneventful recovery period, there were no difficulties with mastication, swallowing, nor speech at 10 months follow-up. There was no loss of lower facial contour, and preauricular and submental scars were the only remaining aesthetic defects. In our patient immediately after the operation, a sharp edge on the alveolar crest was detected and a small operation of planing the crest was performed. This is in accordance with the previous findings that the resection lines as well as the shape of PSI-plate must be planned carefully. One previously reported complication related to the PSI is the perforation of the lingual mucosa because the lingual foil of the implant scaffold was too high [14].

In conclusion, surgical management of OM can be challenging and often requires jaw reconstruction. CAD/CAM and 3D printing enable preoperative planning of osteotomies. In addition, preoperative manufacturing of PSI-plates to fit the individual defect eliminates the need for intraoperative alterations. The potential for these technologies to reduce operative time and improve clinical outcomes in these operations should be investigated further in large prospective studies.

Acknowledgements

We thank Maarit Sarlomo-Rikala, MD, for their expertise and assistance in clinical management and manuscript writing.

References

1. Vasconcelos ACU, Silveira FM, Gomes APN, Tarquinio SBC, Sobral APV, de Arruda, J A A, et al. **Odontogenic myxoma: A 63-year retrospective multicenter study of 85 cases in a Brazil population and a review of 999 cases from literature.** *J Oral Pathol Med.* 2018; 47: 71-77.
2. El-Naggar A, Chan J, Grandis J, Takata T, Slootweg P, editor. **WHO Classification of Head and Neck Tumours.** 4th ed. Lyon: IARC Press. 2017.
3. Chrcanovic BR, Gomez RS. **Odontogenic myxoma: An updated analysis of 1,692 cases reported in the literature.** *Oral Dis.* 2018.
4. Boffano P, Gallesio C, Barreca A, Bianchi FA, Garzino-Demo P, Rocca F. **Surgical treatment of odontogenic myxoma.** *J Craniofac Surg.* 2011; 22: 982-987.
5. Lo Muzio L, Nocini P, Favia G, Procaccini M, Mignogna MD. **Odontogenic myxoma of the jaws: a clinical, radiologic, immunohistochemical, and ultrastructural study.** *Oral Surg Oral Med Oral Pathol Oral Radiol Endod.* 1996; 82: 426-433.
6. Rocha AC, Gaujac C, Cecchetti MM, Amato-Filho G, Machado GG. **Treatment of recurrent mandibular myxoma by curettage and cryotherapy after thirty years.** *Clinics (Sao Paulo).* 2009; 64: 149-152.

7. Kauke M, Safi AF, Kreppel M, Grandoch A, Nickenig HJ, Zoller JE, et al. Size distribution and clinoradiological signs of aggressiveness in odontogenic myxoma-three-dimensional analysis and systematic review. *Dentomaxillofac Radiol.* 2018; 47: 20170262.
8. Noffke CE, Raubenheimer EJ, Chabikuli NJ, Bouckaert MM. Odontogenic myxoma: review of the literature and report of 30 cases from South Africa. *Oral Surg Oral Med Oral Pathol Oral Radiol Endod.* 2007; 104: 101-9.
9. Barnes L. *Pathology and genetics of head and neck tumours.* Lyon: IARC. 2005.
10. Foley BD, Thayer WP, Honeybrook A, McKenna S, Press S. Mandibular reconstruction using computer-aided design and computer-aided manufacturing: an analysis of surgical results. *J Oral Maxillofac Surg.* 2013; 71: 111.
11. Roser SM, Ramachandra S, Blair H, Grist W, Carlson GW, Christensen AM, et al. The accuracy of virtual surgical planning in free fibula mandibular reconstruction: comparison of planned and final results. *J Oral Maxillofac Surg.* 2010; 68: 2824-2832.
12. Tsai MJ, Wu CT. Study of mandible reconstruction using a fibula flap with application of additive manufacturing technology. *Biomed Eng Online.* 2014; 13: 5-57.
13. Sink J, Hamlar D, Kademani D, Khariwala SS. Computer-aided stereolithography for presurgical planning in fibula free tissue reconstruction of the mandible. *J Reconstr Microsurg.* 2012; 28: 395-403.
14. Stoor P, Suomalainen A, Mesimaki K, Kontio R. Rapid prototyped patient specific guiding implants in critical mandibular reconstruction. *J Craniomaxillofac Surg.* 2017; 45: 63-70.
15. Kakarala K, Shnyder Y, Tsue TT, Girod DA. Mandibular reconstruction. *Oral Oncol.* 2018; 77: 111-117.
16. Kawase-Koga Y, Saijo H, Hoshi K, Takato T, Mori Y. Surgical management of odontogenic myxoma: A case report and review of the literature. *BMC Res Notes.* 2014; 7: 21-214.
17. Albanese M, Nocini PF, Fior A, Rizzato A, Cristofaro MG, Sancasani G, et al. Mandibular reconstruction using fresh frozen bone allograft after conservative enucleation of a mandibular odontogenic myxoma. *J Craniofac Surg.* 2012; 23: 831-835.