

# STING pathway expression in low-grade serous carcinoma of the ovary: an unexpected therapeutic opportunity?

Jutta Huvila<sup>1,2\*</sup>, Dawn R Cochrane<sup>2</sup>, Monica Ta<sup>3</sup>, Christine Chow<sup>3</sup>, Kendall Greening<sup>4</sup>, Samuel Leung<sup>2</sup>, Anthony N Kamezis<sup>5</sup>, Analisa DiFeo<sup>6</sup> and David G Huntsman<sup>2,3,4</sup>

<sup>1</sup>Department of Biomedicine, University of Turku, Turku, Finland

<sup>2</sup>Department of Molecular Oncology, BC Cancer Research Center, Vancouver, BC, Canada

<sup>3</sup>Genetic Pathology Evaluation Centre, Vancouver General Hospital, Vancouver, BC, Canada

<sup>4</sup>Department of Pathology and Laboratory Medicine, University of British Columbia, Vancouver, BC, Canada

<sup>5</sup>Department of Pathology and Laboratory Medicine, University of California Davis Medical Center, Sacramento, CA, USA

<sup>6</sup>Department of Pathology, University of Michigan Medical School, Ann Arbor, MI, USA

\*Correspondence to: Jutta Huvila, Department of Biomedicine, University of Turku, Medisiina D, Kiinamyllynkatu 10, FIN-20520 Turku, Finland.  
E-mail: jutta.huvila@utu.fi

## Abstract

Ovarian carcinoma histotypes are distinct diseases with variable clinical outcomes and response to treatment. There is a need for new subtype-specific treatment modalities, especially for women with widespread and chemo-resistant disease. Stimulator of interferon genes (STING) is a part of the cGAS–STING pathway that mediates innate immune defence against infectious DNA-containing pathogens and also detects tumour-derived DNA and generates intrinsic antitumour immunity. The STING signalling pathway is suppressed by several mechanisms in a variety of malignant diseases and, in some cancers that may be a requirement for cellular transformation. The aim of this study was to use immunohistochemistry to evaluate STING protein expression across normal tissue, paratubal and ovarian cysts, and ovarian tumour histotypes including ovarian carcinomas. Herein, we show that the fallopian tube ciliated cells express STING protein, whereas the secretory cells are negative. STING expression differs among ovarian cancer histotypes; low-grade serous ovarian carcinomas and serous borderline tumours have uniform high STING expression, while high-grade serous and endometrioid carcinomas have heterogeneous expression, and clear cell and mucinous carcinomas show low expression. As low-grade serous carcinomas are known to be genomically stable and typically lack a prominent host immune response, the consistently high STING expression is unexpected. High STING expression may reflect pathway activation or histogenesis and the mechanisms may be different in different ovarian carcinoma histotypes. Further studies are needed to determine whether the STING signalling pathway is active and whether these tumours would be candidates for therapeutic interventions that trigger innate immunity activation.

**Keywords:** STING; innate immunity; low-grade serous ovarian carcinoma

Received 7 April 2021; Revised 17 May 2021; Accepted 24 May 2021

Conflict of interest statement: DGH is an Associate Editor of The Journal of Pathology. No other conflicts of interests were declared.

## Introduction

Ovarian cancer is the eighth most common cancer in females worldwide, with 295,414 new cases diagnosed in 2018 [1,2]. In the United States, ovarian cancer is the most common cause of death from gynaecological disease, with an estimated 21,750 new cases of ovarian cancer and 13,940 deaths in 2020 [3]. Despite intensive research efforts and accumulating knowledge on the pathogenesis, precursor lesions, as well as

prevention strategies and treatment options, these advantages have not significantly improved the prognosis of this lethal malignancy, and further understanding of the pathogenesis and potential therapeutic targets is needed.

Stimulator of interferon genes (STING), also known as transmembrane protein 173 (TMEM173), is part of the cyclic GMP-AMP synthase (cGAS)–STING pathway that mediates protective immune defence against infection, detects tumour-derived DNA, and generates

intrinsic antitumour immunity [4]. cGAS functions to directly detect cytosolic DNA, which then signals STING to induce transcription of type I interferon genes and inflammatory cytokines, essential for successful pathogen elimination [4]. STING signalling protects the cell against various pathogens, as well as from cancer development by promoting antitumour immune responses [5,6]. In cancer, self-DNA from dying tumour cells has been suggested to be an important danger signal that triggers the cGAS–STING pathway to induce interferon [7]. STING signalling can be suppressed through epigenetic silencing or loss-of-function mutations [8]. Additionally, some missense mutants fail to generate cytokines in response to cytosolic DNA or chemotherapy, indicating that suppression of STING signalling may enable precancerous cells to avoid antitumour immune responses [8].

The essential role of STING in immune defence in cancer has raised interest in the cGAS–STING pathway. The development of novel anti-inflammatory and antitumour compounds that specifically target this key signalling pathway has been a research focus during recent years [9]. STING agonists have been developed to function as novel cancer therapeutics, and early phase clinical trials are promising both for STING agonists alone and in combination with checkpoint blockade (reviewed by Flood *et al* [10]).

Decreased STING expression has been associated with adverse prognosis in colorectal cancer, hepatocellular cancer, gastric cancer, and melanoma [11–15]. In ovarian cell lines and tumour-derived cancer tissue, the STING pathway is suppressed in a majority of cases, either by loss of STING or cGAS expression, epigenetic suppression, or defects in STING translocation [16]. Studies focusing on high-grade serous ovarian carcinoma (HGSC) therapeutics have shown the potential benefit of adding a STING agonist and immune checkpoint blockade to carboplatin chemotherapy to improved survival [17]. In mouse and cell line models, treating *BRCA*-deficient HGSC with poly ADP ribose polymerase (PARP) inhibitors triggered local and systemic antitumour immunity and activation of the cGAS–STING pathway [18], which was further augmented when combined with PD-1 blockade [18,19]. Furthermore, in an ovarian cancer model, combining oncolytic herpes simplex virus with cisplatin in platinum-resistant ovarian cancer cells resulted in the activation of cGAS–STING pathway and induction of an innate immunity [20].

The aim of this study was to evaluate STING protein expression, assessed by immunohistochemistry (IHC), in normal gynaecological tissue, benign ovarian cysts, cancer precursor lesions in the fallopian tube as

well as ovarian tumours. Furthermore, we aimed to evaluate whether STING expression could aid diagnosis or function as a prognostic marker and whether STING pathway could be targeted and STING expression used as a predictive marker for targeted therapy in ovarian cancer. To our knowledge, this is the first time STING protein expression has been assessed across different ovarian tumour histotypes and benign ovarian lesions.

## Materials and methods

The expression of STING in normal tissue was evaluated using The Human Protein Atlas [21,22].

These studies have received institutional REB approval.

### Cortical inclusion cysts and paratubal cysts

A tissue microarray (TMA) consisting of cortical inclusion cysts (CICs) and paratubal cysts (PTCs) was constructed from formalin-fixed paraffin-embedded (FFPE) ovarian tissue. The TMA consisted of 64 × 2 mm single cores from 29 ovaries with CIC and/or PTC lesions. Cores from fallopian tubes removed as a part of hysterectomy for benign condition were also included.

### Ovarian tumour TMAs

We obtained ovarian and endometrial tumours from the OVCARE Tissue Biobank Repository, Vancouver BC, Canada. This study was performed on previously constructed TMAs with duplicate 0.6 mm cores from FFPE tissues. TMAs comprised 566 cases, also including cores from benign proliferative endometrium, fallopian tube, and ovary. One of the two cohorts in this study has been previously described [23]. To evaluate the expression of STING in ovarian tumours, we stained for TMEM173/STING on both TMAs. After removing duplicate cases ( $n = 45$ ), cases of endometrial carcinoma ( $n = 21$ ), and cases where tissue cores were lost or staining was uninterpretable ( $n = 18$ ), 503 cases were included in this study (see supplementary material, Table S1).

### Immunohistochemistry

Sections were cut at 4 µm thickness, deparaffinised in xylene, rehydrated through a graded series of ethanol, and briefly rinsed in Tris-buffered saline. TMEM173/STING IHC (antibody HPA038116, dilution 1:100, Sigma, St Louis, MO, USA) was performed using the

Ventana Discovery Ultra automated stainer (Ventana Medical Systems Inc., Tucson, AZ, USA). Calretinin IHC (antibody DAK-Calret-1, IR627, ready-to-use, Dako, Glostrup, Denmark) was performed using the Dako Omnis automated IHC instrument (Agilent Technologies, Santa Clara, CA, USA).

### Scoring

The intensity of STING immunostaining was scored negative (0), weak (1), moderate (2), and strong (3), and the frequency of positive tumour cells was assessed as a continuous variable at 0–100%. Scoring was performed blinded to the clinical data. An H-score ( $(1 \times \% \text{ score } 1) + (2 \times \% \text{ score } 2) + (3 \times \% \text{ score } 3)$ ), giving a range of 0–300) was calculated for statistical analysis. Calretinin immunostaining percentage was scored semiquantitatively into four categories (0 = 0, 1 = 1–25%, 2 = 25–50%, 3 = 50–75%, and 4 = 75–100%) and intensity into four categories (negative = 0, weak = 1, moderate = 2, and strong = 3); a calretinin score was calculated as intensity  $\times$  percentage (0–12). Cases with no staining were considered negative. In this study, cases were considered either positive or negative.

### Data analysis

All statistical analyses were done using R project for statistical computing (R version 4.0.3) and survival package was used for survival analysis. Cases with missing values were removed from analyses and only cases with complete data were considered. For exploratory analysis of STING H-score, quartiles and median were used as cut-off points. We considered the univariable association between TMEM173/STING (IHC) expression using chi-square (or Fisher's exact, when appropriate) test for categorical biomarker data and Kruskal–Wallis/Wilcoxon rank-sum test for continuous biomarker data. Kaplan–Meier plots and Cox regression models were used to assess correlation with survival and observations were randomly censored on 31 December of the fifth year following the year in which they had their surgery. The

median H-score of STING expression (H-score 40) was used as a cut-off for survival analysis in histological groups where cases were sufficient. Statistical significance was set at  $p = 0.05$  and no attempts were made to adjust for multiple comparisons.

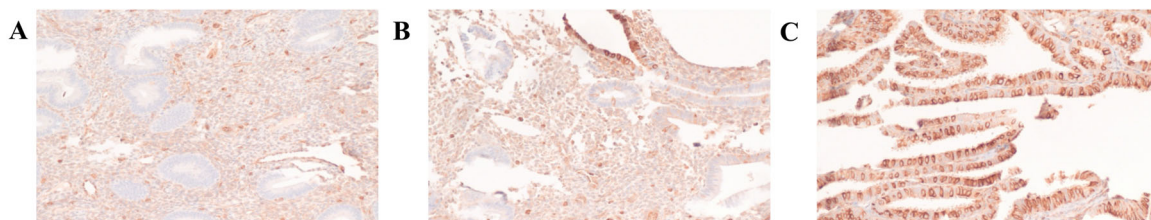
## Results

### STING expression in non-malignant tissues

A publicly available database, Human Protein Atlas, was used to evaluate STING expression in normal tissue. STING was expressed in ciliated cells of respiratory epithelium, ciliated cells of the fallopian tube, Leydig cells of testis, squamous epithelia in tonsil, basal layer of squamous epithelia (e.g. in cervix and oesophagus), basal cell layer of prostate glands, a proportion of lymphatic cells, and endothelia. Most normal tissues were negative for STING.

In our study, STING was highly expressed in the ciliated cells of normal fallopian tube epithelium. The endothelial lining of lymphatic and blood vessels expressed STING in all tissues examined, as did a subset of lymphocytes. Endometrial glands were mostly STING negative; however, small foci of ciliated metaplasia stained positive (Figure 1).

STING expression in cysts was variable (see supplementary material, Figure S1). STING expression was lower in CICs (H-score median 150, interquartile range [IQR] 165) than in PTCs (H-score median 300, IQR 150). Some cysts (both PTC and CIC) had a similar staining pattern as the fallopian tube, with staining of ciliated cells. Most of the PTCs had a thin, strongly STING-positive epithelium lining the cyst. In CTCs, STING expression varied from negative to strongly positive. There was a strong association between low STING expression and calretinin positivity (H-score median 190 in calretinin-positive epithelial lining versus H-score median 60 in calretinin-negative epithelium,  $p = 0.014$ , Mann–Whitney  $U$ -test; see supplementary material, Figure S2), suggesting



**Figure 1.** Photomicrographs of STING IHC in (A) endometrial glands, (B) endometrial glands with focal of ciliated metaplasia, and (C) fallopian tube.

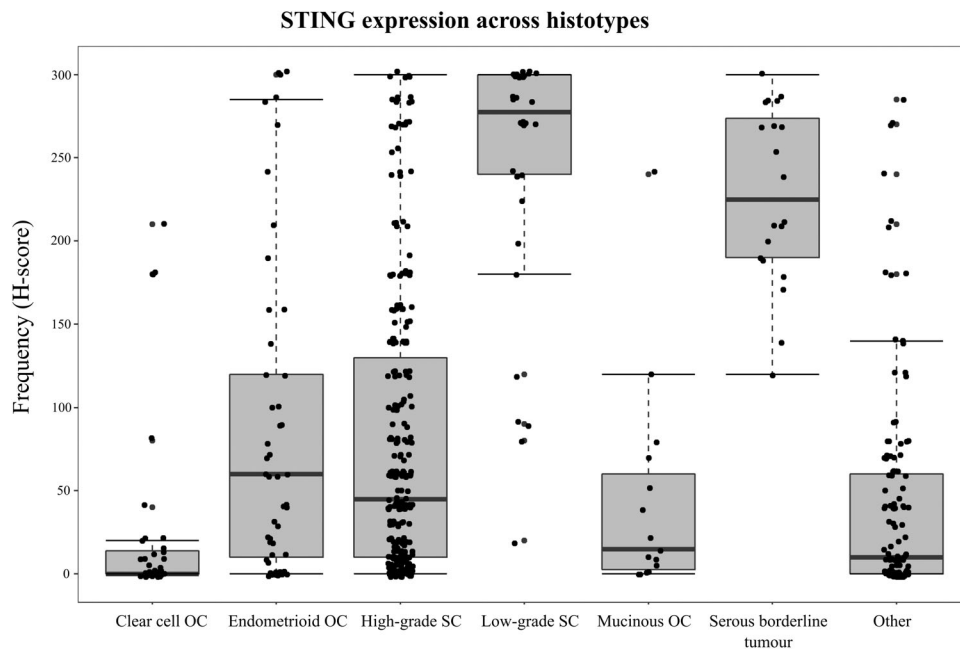


Figure 2. Boxplots of H-scores of STING expression across different tumours ( $p < 0.001$ , Kruskal–Wallis test). OC, ovarian carcinoma; SC, serous carcinoma.

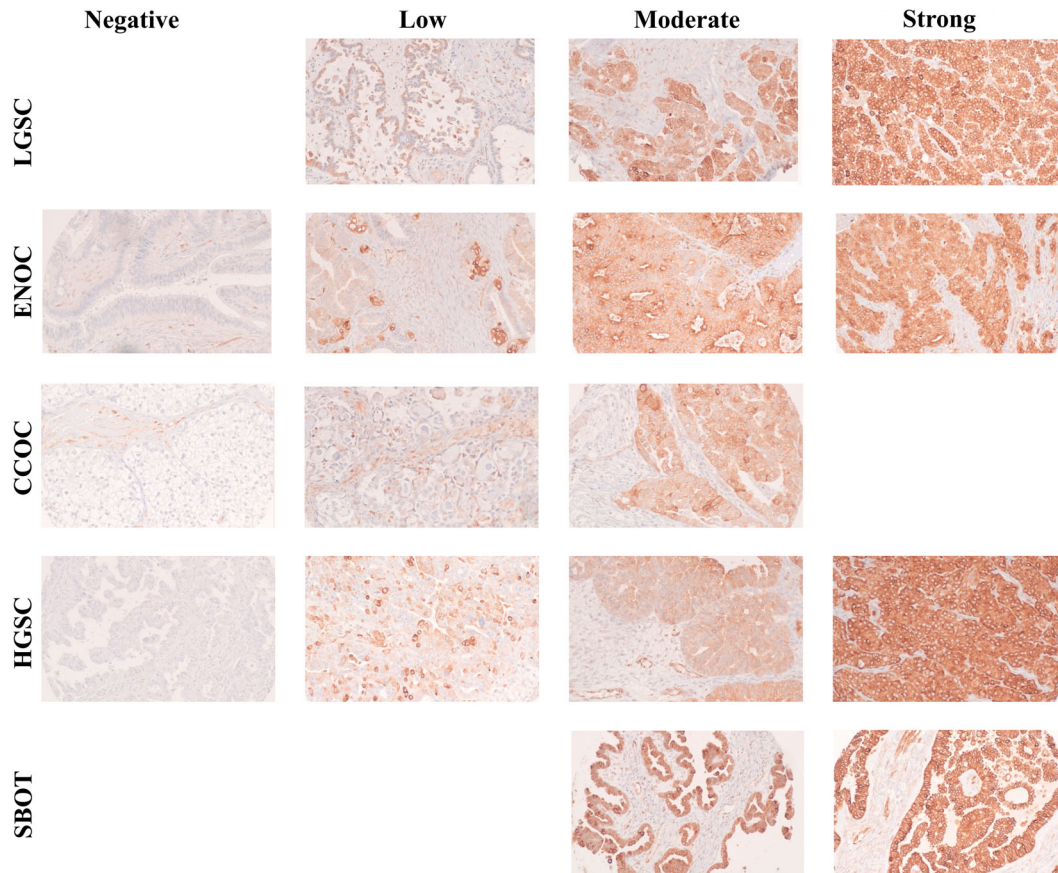


Figure 3. Photomicrographs of different levels of STING expression in LGSC, ENOC, CCOC, HGSC, and SBOT, when present.

that STING expression was low in those cysts with mesothelial lining.

### STING expression in ovarian carcinomas

STING expression was evaluated in 503 specimens of which 378 cases were ovarian carcinomas: 55 endometrioid ovarian carcinomas (ENOC), 235 HGSC, 34 low-grade serous ovarian carcinomas (LGSCs), 39 clear cell ovarian carcinomas (CCOC), and 16 mucinous ovarian tumours (see supplementary material, Table S1). There were significant differences in the expression of STING across the different ovarian tumour histotypes. The H-score boxplots are presented in Figure 2 and photomicrographs of STING IHC in different histotypes in Figure 3. The overall highest expression was observed in LGSC ( $p < 0.001$ ) and lowest in CCOC ( $p < 0.001$ ) when compared to other histotypes (Wilcoxon rank-sum test). Additionally, serous borderline ovarian tumours (SBOT) showed high-level STING expression and low expression was observed in mucinous ovarian tumours. HGSC tumours showed varied expression across all samples and no correlation with clinical outcomes.

We observed a significant association between high STING expression and WT1 positivity (H-score:  $p < 0.001$ ). Within the CCOC histotype, higher STING expression was associated with an adverse prognosis, whereas, in the other subtypes, STING expression was not associated with survival. *BRCA1* status was available from previous work [24] for 36 HGSC cancers in this study, of which 9 were *BRCA1* mutated (see supplementary material, Figure S3). There was a trend towards higher STING expression in the *BRCA1*-mutated HGSCs compared with wild-type HGSC, but this did not reach statistical significance ( $p = 0.081$ ).

## Discussion

In this study, we show that STING protein expression, assessed by IHC, is higher in LGSC and SBOT when compared to most other epithelial ovarian carcinomas. HGSC showed a broad spectrum of staining intensity, whereas ciliated cells, in both normal tissue and ovarian cysts, were positive.

LGSC is a rare ovarian tumour and accounts for 2–4% of all epithelial ovarian cancers and 5–10% of serous ovarian cancer [25,26]. It affects relatively young women, and the disease is often diagnosed at advanced stage when it is associated with poor prognosis. Primary cytoreductive treatment remains the optimal treatment

modality [26]. The response to chemotherapeutic agents is modest and there is a need to better understand potential vulnerabilities in the tumour cells that could be targetable.

The mechanism for high STING expression in LGSC remains to be clarified. LGSC is associated with a less immunosuppressive landscape and reduced innate immune suppression when compared to high-grade ovarian carcinomas [27]. LGSCs have fewer tumour-infiltrating lymphocytes [28,29] and the expression of B7-H4 (regulating T-cell immunity) has been described to be significantly reduced [30] when compared to HGSC. Yet, the activation of STING-dependent pathway in cancer cells is the result of tumour infiltration by immune cells and modulation of the anticancer immune response. This raises the question of whether high STING expression in LGSC reflects the activation of STING-dependent pathway or could it reflect a disruption in the degradation process, i.e. a non-functioning pathway. If not bound to cyclic dinucleotide, STING is usually rapidly degraded. Thus, its presence has been considered a good surrogate for STING activation [31]. Whether a potential disruption in the degradation process affects the potential for downstream STING pathway activation is uncertain, but germane to potential therapeutic approaches.

Several antitumoural roles have been described for the cGAS–STING pathway and acute activation of the pathway provides an antitumour effect; however, chronic inflammation by persistent and spontaneous activation of STING has also been speculated to promote tumour growth and metastasis [32] and could explain the high STING expression. However, we note that LGSCs have less impressive immune infiltrates than other histotypes and therefore proximity to inflammation cannot explain the relatively high STING expression in normal ciliated cells, SBOT, or LGSC.

One possibility is that high STING expression reflects the histogenesis of LGSC, i.e. a cell lineage marker. The precursor lesion(s) of LGSC remain debated but recent evidence suggests that they originate from ovarian cortical cysts, benign ovarian serous neoplasms, and SBOT, although a tubal origin has also been suggested [33–35]. Thus, the STING expression of LGSC could reflect origin from ciliated epithelial cells or cells from that lineage. Supporting this is our observation that, in the inclusion cyst epithelium with a more mesothelial-like immunophenotype, with expression of calretinin, there is reduced STING expression. In this scenario, high STING expression could merely reflect the cell of origin and not activation of the STING pathway [32].

HGSCs are known to arise from the fallopian tube in most cases, and the evolution from secretory cell expansion and loss of ciliated cells [36] through p53 signature lesions and serous tubal intraepithelial lesions to HGSC is a well-described process; however, molecular drivers of these phenomena are incompletely understood. STING signalling may exert a tumour-suppressive effect and trigger cytokine production and attract immunosurveillance, and thus suppression of STING could be a requirement for precancerous cells to avoid antitumour immune response and for the cellular transformation process to proceed. Most recently, it has been shown that STING does have tumour-suppressive activity and the STING pathway is activated in response to cytosolic tumour DNA. Thus, the expression of STING in a subset of HGSCs could reflect some level of ciliated cell differentiation [37]. In HGSC, a transcriptomic signature characteristic for fallopian tube ciliated cells has been identified and STING was amongst the markers defining ciliated cells, indicating an ability of serous ovarian carcinomas to differentiate into cells that molecularly resemble fallopian tube ciliated cells [38]. The ciliated tumour subtype was highly enriched in the low-grade tumours compared with the high-grade ones. Furthermore, single-cell RNA sequencing and IHC of ovarian and endometrial tumours has demonstrated the presence of tumour cells expressing ciliated cell markers [39].

In our study, CCOC had significantly lower STING expression compared to other histotypes, while ENOC showed a similar STING expression profile to HGSC. Both ENOC and CCOC develop from endometriosis via alterations affecting different genetic pathways [40]. It has been suggested, in the context of endometriosis, that ENOCs are derived from endometriosis cells of the secretory cell lineage, whereas CCOCs could be derived from, or have similarities to, cells of the ciliated cell lineage [41]. This challenges the hypothesis that tumours that have high STING expression would purely reflect ciliated cell of origin. In the context of endometriosis and adenomyosis, chronic inflammation and upregulated STING expression have been speculated to play a role in eliminating nascent neoplastic cells and the decrease of STING expression potentially leading to the emergence of precancerous cells [42]. Therefore, if the STING pathway plays a role in pathogenesis of these cancers, its role is distinct in ENOC and CCOC.

CCOCs are associated with low numbers of tumour-infiltrating lymphocytes and the low expression of STING may be evidence of inactivation of the STING pathway. Interestingly, similar to our finding, in which ovarian CCOCs are associated with adverse survival,

high STING expression is also associated with adverse survival (Human Protein Atlas [21]) in the morphologically similar renal clear cell carcinoma. The mechanism remains unclear.

Overall, it seems likely that STING expression has different roles in different ovarian cancer subtypes and in different contexts. Functional experiments are needed to clarify the role of STING in ovarian carcinomas and to assess the integrity of the cGAS–STING pathway.

In chemoresistant ovarian carcinomas, there is a great need for novel therapeutic strategies, and a dysfunctioning STING pathway could provide a unique opportunity for therapeutic intervention. It has been postulated that STING and cGAS could provide an assay that could help predict the outcome of oncoviral therapy in ovarian cancer [43]. Xia *et al* hypothesised that, as suppression of STING signalling might be a key requirement for the development of malignant disease, these same defects in STING signalling may render cancer cells highly susceptible to oncolytic viral infections [14,15]. Resistance mechanisms to oncolytic viral therapy often include activation of the STING pathway [14]; therefore, tumours, such as LGSC, that may be defective in STING signalling, could be particularly susceptible to this type of therapeutic intervention.

A dysfunctioning STING pathway can also be targeted with a STING agonist and this has been tested in early clinical trials in HGSC. Our results show that a proportion of HGSCs have low STING expression and STING expression could be used as a predictive marker for STING agonist treatment in HGSC. Additionally, miR-181a targeting of STING has been presented as a therapeutic opportunity [37]. In cells stably overexpressing mature miR-181a, knockdown of STING was sufficient to increase cell proliferation and clonogenic survival. Loss of STING increased the transformation of fallopian tube secretory epithelial cells and miR-181a inhibited this process [37].

In summary, STING expression may reflect different mechanisms in different ovarian carcinoma histotypes. There is variable expression in HGSC and ENOC, while CCOC and MOC show much less expression. As this correlates with the more frequent association of a host immune response in the former than the latter histotypes, expression of STING may reflect pathway activation as part of the host response. LGSCs are distinct in that STING is highly expressed in precursor lesions such as SBOT and CICs, and also in tumour cells, yet there is little evidence of a host immune response and the tumour cells are diploid/near diploid with low mutation burdens. In this setting, STING

expression may reflect ciliated cell lineage rather than pathway activation. If true, this has potential therapeutic implications as the lack of intact STING signaling in LGSC, for example, could render the cells more susceptible to viral oncolytic therapy. The response to chemotherapeutic agents is modest and there is a need to better understand potential vulnerabilities in the tumour cells that could be targetable.

## Acknowledgements

This study is supported by the Canadian Institutes of Health Research Foundation Grant #154290 to DGH, the BC Cancer Foundation, and the Vancouver General Hospital (VGH) & University of British Columbia (UBC) Hospital Foundation. DGH is supported by the Dr. Chew Wei Memorial Professorship in Gynecologic Oncology and the Canada Research Chairs Program (Research Chair in Molecular and Genomic Pathology).

## Author contributions statement

JH, DRC, AD and DGH conceived the experiments. Optimisation and immunostaining of STING were performed by MT and CC. Pathology review and scoring of tumour TMAs were performed by JH. KG and ANK provided TMAs. Statistical analysis was performed by SL. The manuscript was prepared by JH. All authors read and reviewed the manuscript.

## References

- Bray F, Ferlay J, Soerjomataram I, *et al.* Global cancer statistics 2018: GLOBOCAN estimates of incidence and mortality worldwide for 36 cancers in 185 countries. *CA Cancer J Clin* 2018; **68**: 394–424.
- Ferlay J, Colombet M, Soerjomataram I, *et al.* Estimating the global cancer incidence and mortality in 2018: GLOBOCAN sources and methods. *Int J Cancer* 2019; **144**: 1941–1953.
- Key Statistics for Ovarian Cancer [Internet]. [Accessed 24 June 2020]. Available from: <https://www.cancer.org/cancer/ovarian-cancer/about/key-statistics.html>
- Chen Q, Sun L, Chen ZJ. Regulation and function of the cGAS-STING pathway of cytosolic DNA sensing. *Nat Immunol* 2016; **17**: 1142–1149.
- Woo SR, Corrales L, Gajewski TF. The STING pathway and the T cell-inflamed tumor microenvironment. *Trends Immunol* 2015; **36**: 250–256.
- Barber GN. STING-dependent cytosolic DNA sensing pathways. *Trends Immunol* 2014; **35**: 88–93.
- Corrales L, Gajewski TF. Endogenous and pharmacologic targeting of the STING pathway in cancer immunotherapy. *Cytokine* 2016; **77**: 245–247.
- Konno H, Yamauchi S, Berglund A, *et al.* Suppression of STING signaling through epigenetic silencing and missense mutation impedes DNA damage mediated cytokine production. *Oncogene* 2018; **37**: 2037–2051.
- Barber GN. STING: infection, inflammation and cancer. *Nat Rev Immunol* 2015; **15**: 760–770.
- Flood BA, Higgs EF, Li S, *et al.* STING pathway agonism as a cancer therapeutic. *Immunol Rev* 2019; **290**: 24–38.
- Song S, Peng P, Tang Z, *et al.* Decreased expression of STING predicts poor prognosis in patients with gastric cancer. *Sci Rep* 2017; **7**: 39858.
- Chon HJ, Kim H, Noh JH, *et al.* STING signaling is a potential immunotherapeutic target in colorectal cancer. *J Cancer* 2019; **10**: 4932–4938.
- Bu Y, Liu F, Jia QA, *et al.* Decreased expression of TMEM173 predicts poor prognosis in patients with hepatocellular carcinoma. *PLoS One* 2016; **11**: e0165681.
- Xia T, Konno H, Ahn J, *et al.* Deregulation of STING signaling in colorectal carcinoma constrains DNA damage responses and correlates with tumorigenesis. *Cell Rep* 2016; **14**: 282–297.
- Xia T, Konno H, Barber GN. Recurrent loss of STING signaling in melanoma correlates with susceptibility to viral oncolysis. *Cancer Res* 2016; **76**: 6747–6759.
- de Queiroz NMGP, Xia T, Konno H, *et al.* Ovarian cancer cells commonly exhibit defective STING signaling which affects sensitivity to viral oncolysis. *Mol Cancer Res* 2019; **17**: 974–986.
- Ghaffari A, Peterson N, Khalaj K, *et al.* STING agonist therapy in combination with PD-1 immune checkpoint blockade enhances response to carboplatin chemotherapy in high-grade serous ovarian cancer. *Br J Cancer* 2018; **119**: 440–449.
- Reisländer T, Lombardi EP, Groelly FJ, *et al.* BRCA2 abrogation triggers innate immune responses potentiated by treatment with PARP inhibitors. *Nat Commun* 2019; **10**: 31–43.
- Ding L, Kim HJ, Wang Q, *et al.* PARP inhibition elicits STING-dependent antitumor immunity in Brca1-deficient ovarian cancer. *Cell Rep* 2018; **25**: 2972–2980.e5.
- Hong B, Chapa V, Saini U, *et al.* Oncolytic HSV therapy modulates vesicular trafficking inducing cisplatin sensitivity and antitumor immunity. *Clin Cancer Res* 2021; **27**: 542–553.
- Human Protein Atlas [Internet]. [Accessed 11 January 2021]. Available from: [proteinatlas.org](http://proteinatlas.org)
- Uhlén M, Fagerberg L, Hallström BM, *et al.* Proteomics. Tissue-based map of the human proteome. *Science* 2015; **347**: 1260419.
- Köbel M, Kalloger SE, Boyd N, *et al.* Ovarian carcinoma subtypes are different diseases: implications for biomarker studies. *PLoS Med* 2008; **5**: e232.
- Wang YK, Bashashati A, Anglesio MS, *et al.* Genomic consequences of aberrant DNA repair mechanisms stratify ovarian cancer histotypes. *Nat Genet* 2017; **49**: 856–865.
- Matsuo K, Machida H, Grubbs BH, *et al.* Trends of low-grade serous ovarian carcinoma in the United States. *J Gynecol Oncol* 2018; **29**: e15.

26. Grabowski JP, Harter P, Heitz F, et al. Operability and chemotherapy responsiveness in advanced low-grade serous ovarian cancer. An analysis of the AGO Study Group metadatabase. *Gynecol Oncol* 2016; **140**: 457–462.
27. Vankerckhoven A, Wouters R, Mathivet T, et al. Opposite macrophage polarization in different subsets of ovarian cancer: observation from a pilot study. *Cells* 2020; **9**: 305.
28. Martins FC, Couturier DL, Paterson A, et al. Clinical and pathological associations of PTEN expression in ovarian cancer: a multi-centre study from the Ovarian Tumour Tissue Analysis Consortium. *Br J Cancer* 2020; **123**: 793–802.
29. Wong K-K, Gershenson DM. Abstract 135: immunosuppressive microenvironment in low-grade serous ovarian carcinoma. *Tumor Biol* 2018; **78 (Suppl)**: 135.
30. Liang L, Jiang Y, Chen JS, et al. B7-H4 expression in ovarian serous carcinoma: a study of 306 cases. *Hum Pathol* 2016; **57**: 1–6.
31. Konno H, Konno K, Barber GN. Cyclic dinucleotides trigger ULK1 (ATG1) phosphorylation of STING to prevent sustained innate immune signaling. *Cell* 2013; **155**: 688–698.
32. Yum S, Li M, Chen ZJ. Old dogs, new trick: classic cancer therapies activate cGAS. *Cell Res* 2020; **30**: 639–648.
33. Kurman RJ, Vang R, Junge J, et al. Papillary tubal hyperplasia: the putative precursor of ovarian atypical proliferative (borderline) serous tumors, noninvasive implants, and endosalpingiosis. *Am J Surg Pathol* 2011; **35**: 1605–1614.
34. Laury AR, Ning G, Quick CM, et al. Fallopian tube correlates of ovarian serous borderline tumors. *Am J Surg Pathol* 2011; **35**: 1759–1765.
35. Li J, Abushahin N, Pang S, et al. Tubal origin of ‘ovarian’ low-grade serous carcinoma. *Mod Pathol* 2011; **24**: 1488–1499.
36. Wang Y, Li L, Wang Y, et al. Fallopian tube secretory cell expansion: a sensitive biomarker for ovarian serous carcinogenesis. *Am J Transl Res* 2015; **7**: 2082–2090.
37. Knarr M, Avelar RA, Sekhar SC, et al. miR-181a initiates and perpetuates oncogenic transformation through the regulation of innate immune signaling. *Nat Commun* 2020; **11**: 3231.
38. Hu Z, Artibani M, Alsaadi A, et al. The repertoire of serous ovarian cancer non-genetic heterogeneity revealed by single-cell sequencing of normal fallopian tube epithelial cells. *Cancer Cell* 2020; **37**: 226–242.e7.
39. Cochrane DR, Campbell KR, Greening K, et al. Single cell transcriptomes of normal endometrial derived organoids uncover novel cell type markers and cryptic differentiation of primary tumours. *J Pathol* 2020; **252**: 201–214.
40. Lim D, Oliva E. Precursors and pathogenesis of ovarian carcinoma. *Pathology* 2013; **45**: 229–242.
41. Cochrane DR, Tessier-Cloutier B, Lawrence KM, et al. Clear cell and endometrioid carcinomas: are their differences attributable to distinct cells of origin? *J Pathol* 2017; **243**: 26–36.
42. Qu H, Li L, Wang TL, et al. Epithelial cells in endometriosis and adenomyosis upregulate STING expression. *Reprod Sci* 2020; **27**: 1276–1284.
43. Lee J, Ghonime MG, Wang R, et al. The antiviral apparatus: STING and oncolytic virus restriction. *Mol Ther Oncolytics* 2019; **13**: 7–13.

## SUPPLEMENTARY MATERIAL ONLINE

**Figure S1.** STING expression in ovarian CICs and PTCs

**Figure S2.** STING H-scores in calretinin-negative and -positive ovarian CICs and PTCs

**Figure S3.** H-scores of STING expression in *BRCA1*-mutated and wildtype HGSC

**Table S1.** Histotype distribution of cases on the ovarian tumour TMAs