



King Saud University

Saudi Journal of Biological Sciences

www.ksu.edu.sa
www.sciencedirect.com



الجمعية السعودية لعلم الحياتة
SAUDI BIOLOGICAL SOCIETY

ORIGINAL ARTICLE

Influence of premolar extraction or non-extraction orthodontic therapy on the angular changes of mandibular third molars



Bangalore H. Durgesh^{a,*}, Kiran H. Komari Gowda^b, Obaid A. AlShahrani^a, Ahmad D. Almalki^c, Waleed D. Almalki^c, Manea Mohammed S. Balharith^d, Nada Yahya H. Motashesh^e, Abdulaziz A. Alkheraif^a, Mohamed I. Hashem^{a,f}

^a Dental Health Department, Dental Biomaterials Research Chair, College of Applied Medical Sciences, King Saud University, Riyadh, Saudi Arabia

^b Department of Orthodontics, KVG Dental College and Hospital, Sullia, Karnataka, India

^c Ministry of Health and Al Farabi College for Medicine, Dentistry and Nursing, Saudi Arabia

^d Ministry of Health, North Health Sector of Riyadh, Saudi Arabia

^e Al Farabi College for Medicine, Dentistry and Nursing, Riyadh, Saudi Arabia

^f Dental Biomaterials Department, College of Dentistry, Al Azhar University, Egypt

Received 8 December 2015; revised 3 February 2016; accepted 4 February 2016

Available online 10 February 2016

KEYWORDS

Premolar extraction;
Third molar angulation;
Unerrupted molar

Abstract *Aim:* To compare the angular changes of the third molars relative to the occlusal plane and to the second molar long axis in extraction group and compare these changes with a non extraction group.

Materials and methods: The study included pre and post treatment panoramic radiograph records of 90 subjects treated by first premolar extractions and 90 subjects who had been treated with non extraction orthodontic therapy ($n = 90$). Two angular variables were measured. Firstly, the angle between the long axis of the third molar and the occlusal plane (M3–OP) and secondly, the angle between the long axis of the third molar and the long axis of the second molar (M3–M2). Data were analyzed by paired and student's *t*-test.

Result: The analyzed data to assess the changes in the third molar angulation from pretreatment to post treatment did not vary significantly in both the groups ($p < 0.05$). Both the groups showed decreased angular values. The M3–OP angular difference was (-7.3 ± 2.45) in extraction group as compared to (-5.85 ± 1.77) in non extraction group. The M3–M2 angular difference of (-4.26 ± 3.11) in extraction group and (-2.98 ± 1.74) in non-extraction group was observed.

* Corresponding author at: Dental Health Department, Dental Biomaterials Research Chair, College of Applied Medical Sciences, King Saud University, P.O. Box 10219, Riyadh 11433, Saudi Arabia. Tel.: +966 537135611.

E-mail address: drdurgesh19@gmail.com (B.H. Durgesh).

Peer review under responsibility of King Saud University.



Production and hosting by Elsevier

<http://dx.doi.org/10.1016/j.sjbs.2016.02.006>

1319-562X © 2016 The Authors. Production and hosting by Elsevier B.V. on behalf of King Saud University.

This is an open access article under the CC BY-NC-ND license (<http://creativecommons.org/licenses/by-nc-nd/4.0/>).

Conclusion: Extraction of premolars did not demonstrate considerable changes on the angulation of the third molars. The factors other than premolar extractions may influence the angulation of the third molars.

© 2016 The Authors. Production and hosting by Elsevier B.V. on behalf of King Saud University. This is an open access article under the CC BY-NC-ND license (<http://creativecommons.org/licenses/by-nc-nd/4.0/>).

1. Introduction

The eruption of the mandibular third molar (M3) and their influence on the dental arch has long been a subject of controversy that interests various specialties of dentistry (Tarazona et al., 2010). The development of mandibular third molar starts within the mandibular ramus between the ages of 7–15 years and erupts into the oral cavity at around 18–24 years of age (Richardson and Dent, 1974; Kim et al., 2003; Artun et al., 2005). From clinical point of view, its eruption is uncertain and very difficult to predict if there will be enough space in the arch for it to take its acceptable final position (Tarazona et al., 2010). The impaction rate of the third molars (mandible > maxilla) is high compared to any other teeth and could vary from 9.5% to 39% (Else and Rock, 2000; Yavuz et al., 2006). These high impaction rates could be due to the lack of space that occurs due to biological factors such as alteration in the longitudinal growth of the mandible, distal eruption pattern of teeth, delays in the development of facial structure, limited resorption at the anterior aspect of the mandibular ramus, and greater size of mandibular third molar crown (Tarazona et al., 2010). Previous studies on mandibular third molar have concentrated about the influence that the third molars have on the rest of the dentition, rather than the control that the rest of the dentition has on the third molars (Staggers et al., 1992).

The impact that mandibular third molars have on the relapse of lower incisor crowding following the conclusion of orthodontic treatment has been a subject of many theories (Jain and Valiathan, 2009). Some authors advocate extraction of the first premolar to accommodate the third molars (Faubion, 1968; Silling, 1973) whereas others believe that the third molars may still remain impacted in spite of premolar extraction (Björk et al., 1956; Dierkes, 1975), although few studies have found very little difference between extraction and non extraction cases (Hattab, 1997). The extraction therapy is associated with mesial movement of the mandibular molars (Kim et al., 2003) and each millimeter of forward movement by the other lower molars improves the chances of eruption of a third molar by 10% (Else and Rock, 2000).

It is challenging to predict the fate of the third molars, since the second molars of an average 12-year old orthodontic subject have not yet erupted and the third molars have a limited amount of calcification at that time. This period is best considered for treating most of the malocclusions and thus it is very crucial for the orthodontist to determine the course of the third molars and draw an appropriate treatment plan (Richardson, 1980).

Previous studies have found improved angulation of developing third molar in patients treated with extraction (Else and Rock, 2000; Jain and Valiathan, 2009; Saisel et al., 2005). Richardson (1970) found an average change of

11.2° by mandibular third molar between 10 and 15 years with respect to the mandibular plane. This indicates a tendency for the tooth to become straighter and likely to decrease the M3–OP angle. If these changes fail to occur, impactions are inevitable. It has also been reiterated that anchorage conditions and type of mechanics used during treatment have a greater effect on the third molar angulation rather than the actual extraction of first premolars (Staggers et al., 1992).

Considering the above aspects, the current study aimed at determining the changes in the third molar angulation relative to the occlusal plane and to the second molar long axis in extraction group and comparing these changes with a non extraction group.

2. Materials and methods

The study included the pre-treatment (T1) and post-treatment (T2) panoramic radiograph records of 180 subjects (90 males and 90 females) who had undergone fixed orthodontic treatment at various orthodontic clinics in different cities of Saudi Arabia. A total of 360 panoramic radiographs (2 per patient, pre treatment and post treatment) were evaluated. 90 subjects (45 males and 45 females) had been treated with first premolar extraction and 90 subjects (45 males and 45 females) had been treated with non extraction therapy. The mean age at the start of the treatment was 13.67 in the extraction group and 13.41 in the non extraction group. The average duration of the treatment was 2.7 years. The ethical guidance for the study was in accordance with World Medical Association declaration of Helsinki, 1975, as revised in 2000.

The criteria used for inclusion and exclusion of the subjects are:

Inclusion:

- Class I skeletal and dental relationships;
- Bilaterally unerupted mandibular third molars that could be seen on panoramic radiographs in mesioangular positions. Root development of the third molars was no more than 2nd/3rd;
- Second premolars (P2) fully erupted into the mouth;
- High-quality pretreatment (T1) and post treatment (T2) panoramic radiographs without any distortion errors or magnifications;
- The average duration of treatment in both the groups should not be less than 2 years.

Exclusion:

- Patients with Class II malocclusion requiring extraction of the second premolars and mandibular molar protraction.
- Class I maxillomandibular protrusion cases requiring anchorage preparation.

The pre-treatment radiographs were taken approximately 2 weeks before the start of treatment and the post-treatment radiographs were taken during the retention phase. The panoramic radiographs (T1 and T2) were evaluated by standardized technique of tracing the outline of the teeth (premolars and molars) on the matte acetate paper. Two angular measurements were measured as described below:

- (a) The angle between the long axis of the third molar (M3) (line bisecting the line connecting the mesial and distal outlines of the cervical areas), and the line connecting the mesiobuccal cusps of the first molar with the buccal cusps of the second premolar defined the occlusal plane (OP): (M3–OP) (Fig. 1(1)).
- (b) The angle between the long axis of the second molar (M2) (midocclusal point through the midpoint of the root bifurcation and the midpoint between the mesial and distal root tips) and the long axis of the third molar: (M3–M2) (Fig. 1(2)).

To check the reproducibility of the measurements, 25 randomly selected panoramic radiographs from each group were retraced by the same examiner 1 week apart and the method error was calculated using reliability test. The data collected were analyzed by paired and student's *t*-test, using SPSS v. 22 statistical analysis program. The values of ($p < 0.05$) were considered as statistically significant.

The change in angular measurements was determined by calculating the differences between the post treatment and the pretreatment values ($T2 - T1$) for each subject in both the groups.

3. Results

Table 1 lists the comparison of age and duration of treatment between the extraction and non extraction groups and showed no significant differences. The reliability test evaluating the reproducibility of the measurements showed an average error value of 0.67° . To have a favorable third molar angulation, a decrease in M3–OP and M3–M2 was anticipated. The

analyzed data to assess the changes in the third molar angulation from pretreatment to post treatment showed decreased angular values from pretreatment to post treatment indicating a favorable development of the third molar angulation in both the groups. ($p < 0.05$) (Table 2)

There was no significant difference between the extraction and non extraction groups. The mean M3–OP angular difference was (-7.3 ± 2.45) in the extraction group as compared to (-5.85 ± 1.77) in the non extraction group. The M3–M2 angular difference of (-4.26 ± 3.11) in the extraction group and (-2.98 ± 1.74) in the non-extraction group was observed (Table 3). The extraction group showed a slightly improved angulation as compared to the extraction group.

Table 1 Mean age and treatment time for extraction and non extraction groups.

	Extraction group	Non-extraction group	Significance*
Age	13.67 \pm 1.67 (range 11–17)	13.41 \pm 1.41 (range 11–19)	NS
Treatment time	2.5 \pm 0.4	2.2 \pm 0.2	NS

* NS denotes non-significant values.

Table 2 Angular changes (mean \pm SD) observed in the extraction and non extraction groups.

Group	Pre treatment	Post treatment	' <i>p</i> ' value*
<i>Extraction</i>			
M3–OP	133.4 \pm 8.15	126.1 \pm 7.71	S
M3–M2	29.85 \pm 9.30	25.59 \pm 6.24	S
<i>Non extraction</i>			
M3–OP	132.55 \pm 3.7	126.7 \pm 6.8	S
M3–M2	27.19 \pm 9.30	24.21 \pm 3.7	S

S denotes significant values.

* $p < 0.05$.

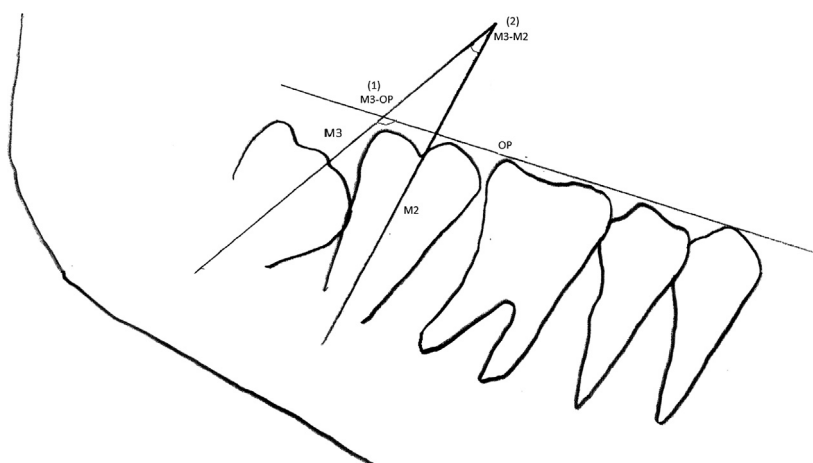


Figure 1 (1) The angle between the long axis of mandibular third molar and occlusal plane (M3–OP), (2) the angle between long axis of mandibular third and the second molar (M3–M2).

Table 3 Difference in angular changes (mean \pm SD) of extraction and non-extraction group.

Measurement (post treatment-pre treatment)	Extraction	Non-extraction	'p' value*
M3-OP	-7.3 \pm 2.45	-5.85 \pm 1.77	0.377, NS
M3-M2	-4.26 \pm 3.11	-2.98 \pm 1.74	0.259, NS

NS denotes non-significant values.

* $p < 0.05$.

4. Discussion

The use of panoramic radiographs to evaluate the changes of M3 has been conclusive (Björk et al., 1956; Silling, 1973) as compared to the inconclusive cephalometric methods (Artun et al., 2005) and hence was used in the current study. The presence, angulation and eruptive movements of the third molar largely influence the orthodontic treatment plan during and after treatment (Al Kuwari et al., 2013). Previous studies have found that premolar extraction increases the available space in molar area, improving the angulation of the third molar (Jain and Valiathan, 2009; Richardson, 1980). Some studies link the significant increase in the frequency of the third molar impaction to the non-extraction therapy (Kim et al., 2003). According to these studies, extraction therapy initiates the mesial movement of the molars and a concomitant increase in eruption space is seen thereby reducing the frequency of the third molar impaction. The mesial movement of the molars during closure of the extraction site could have a larger effect on mandibular third molar impaction (Saysel et al., 2005). Haavikko et al. concluded that premolar extraction improves the chances but not favor the eruption of the third molar (Haavikko et al., 1978).

The mean age of the subjects in this study was 13.5 years and during this time, the third molar bud is developing and undergoes extensive pre eruptive movements. This age group is ideal to evaluate the effect of extraction or non extraction orthodontic therapy on the third molar angulation. This study compared the angular changes of M3 in subjects who had undergone orthodontic therapy with or without extraction of the first premolars; the final clinical eruption or impaction of the third molar could not be fully appraised due to the fact that the mean age of the subjects at the end of the treatment was 16.4 and the eruption period of the third molar was between 18 and 24 years.

To have a favorable development in the angulation of the third molar, an increase in M3-OP angle and a decrease in M3-M2 angle are necessary in maxillary arch and a decrease in the M3-OP and M3-M2 angles is necessary in the mandibular arch (Mihai et al., 2013). In the present study, both the groups showed a decreased M3-OP and M3-M2 angle indicating a favorable development of 3M angulation. The M3-OP angle difference between the groups was 1.45° and the M3-M2 angle difference was 1.28°. These values suggest that regardless of the extraction or non extraction orthodontic treatment, the positions of the M3 improved. This said; extraction therapy did not improve the M3 angulation significantly.

The findings of this study contradict with other studies, which have reported improved third molar angulation in premolar extraction cases (Jain and Valiathan, 2009; Elsey and Rock, 2000; Mihai et al., 2013; Saysel et al., 2005). Saysel et al. has reported that the third molar angulation worsened

in non extraction subjects which was very much contradictory with the findings of our study (Saysel et al., 2005). The third molars may still remain impacted, even with an improvement in angulations (Richardson, 1980). The present study was well in agreement with the findings of other studies (Hattab, 1997; Staggers et al., 1992; Tarazona et al., 2010; Russell et al., 2013). The factors other than premolar extraction could influence the angulation of M3. It is reasonable to brief the patient that premolar extractions may not rule out the need for the third molar extractions in future.

5. Conclusion

Extraction of premolars did not demonstrate considerable changes on the angulation of the third molars. The factors other than premolar extractions may influence the angulation of the third molars.

Acknowledgement

The project was financially supported by Vice Deanship of Research Chairs, King Saud University.

References

- Al kuwari, H.M., Talakey, A.A., Al-sahli, R.M., Albadr, A.H., 2013. Influence of orthodontic treatment with first premolar extraction on the angulation of the mandibular third molar. *Saudi Med. J.* 34, 639–643.
- Artun, J., Thalib, L., Little, R.M., 2005. Third molar angulation during and after treatment of adolescent orthodontic patients. *Eur. J. Orthod.* 27, 590–596.
- Björk, A., Jensen, E., Palling, M., 1956. Mandibular growth and third molar impaction. *Acta Odontol. Scand.* 14, 231–272.
- Dierkes, D.D., 1975. An investigation of the mandibular third molars in orthodontic cases. *Angle Orthod.* 45, 207–212.
- Elsay, M.J., Rock, W.P., 2000. Influence of orthodontic treatment on development of third molars. *Br. J. Oral Maxillofac. Surg.* 38, 350–353.
- Faubion, B.H., 1968. Effect of extraction of premolars on eruption of mandibular third molars. *J. Am. Dent. A* 76, 316–320.
- Haavikko, K., Altonen, M., Mattila, K., 1978. Predicting angulation development and eruption of the lower third molar. *Angle Orthod.* 48, 39–48.
- Hattab, F.N., 1997. Positional changes and eruption of impacted mandibular third molars in young adults. A radiographic 4-year follow-up study. *Oral Surg. Oral Med. Oral Pathol. Oral Radiol. Endod.* 84, 604–608.
- Jain, S., Valiathan, A., 2009. Influence of first premolar extraction on mandibular third molar angulation. *Angle Orthod.* 79, 1143–1148.
- Kim, T.W., Artun, J., Behbehani, F., Artese, F., 2003. Prevalence of third molar impaction in orthodontic patients treated nonextraction and with extraction of 4 premolars. *Am. J. Orthod. Dentofacial Orthop.* 123, 138–145.

- Mihai, A.M., Lulache, I.R., Grigore, R., Sanabil, A.S., Boiangiu, S., Ionescu, E., 2013. Positional changes of the third molar in orthodontically treated patients. *J. Med. Life* 6, 171–175.
- Richardson, M.E., 1970. The early developmental position of the lower third molar relative to certain jaw dimensions. *Angle Orthod.* 40, 226–230.
- Richardson, M., 1980. Late third molar genesis: its significance in orthodontic treatment. *Angle Orthod.* 50, 121–128.
- Richardson, M.E., Dent, M., 1974. Some aspects of lower third molar eruption. *Angle Orthod.* 44, 141–145.
- Russell, B., Skvara, M., Draper, E., Proffit, W.R., Philips, C., White Jr., R.P., 2013. The association between orthodontic treatment with removal of premolars and the angulation of developing mandibular third molars over time. *Angle Orthod.* 83, 376–380.
- Saysel, M.Y., Meral, G.D., Kocadereli, I., Tasar, F., 2005. The effects of first premolar extractions on third molar angulations. *Angle Orthod.* 75, 719–722.
- Silling, G., 1973. Development and eruption of the mandibular third molar and its response to orthodontic therapy. *Angle Orthod.* 43, 271–278.
- Staggers, J.A., Germane, N., Fortson, W.M., 1992. A comparison of the effects of first premolar extractions on third molar angulation. *Angle Orthod.* 62, 135–138.
- Tarazona, B., Paredes, V., Llamas, J.M., Cibrian, R., Gandia, J.L., 2010. Influence of first and second premolar extraction or non-extraction treatments on mandibular third molar angulation and position. A comparative study. *Med. Oral Patol. Oral Cir. Bucal* 15, e760–e766.
- Yavuz, I., Baydas, B., Ikbali, A., Dagsuyu, I.M., Ceylan, I., 2006. Effects of early loss of permanent first molars on the development of third molars. *Am. J. Orthod. Dentofacial Orthop.* 130, 634–638.