



Identifying brain changes related to cognitive aging using VBM and visual rating scales

Valentina Pergher^{a,*}, Philippe Demaerel^b, Olivier Soenen^b, Carina Saarela^{c,d}, Jos Tournoye^e, Birgitte Schoenmakers^f, Mira Karrasch^c, Marc M. Van Hulle^a

^a KU Leuven - University of Leuven, Department of Neurosciences, Laboratory for Neuro- & Psychophysiology, Leuven, Belgium

^b Department of Radiology, University Hospitals Leuven, Department of Imaging and Pathology, KU Leuven, Belgium

^c Department of Psychology, Åbo Akademi University, Turku, Finland

^d Department of Psychology, University of Turku, Turku, Finland

^e Department of Chronic Diseases, Metabolism and Ageing, University Hospitals Leuven, KU Leuven, Belgium

^f Academic Centre of General Practice, KU Leuven - University of Leuven, Leuven, Belgium

ARTICLE INFO

Keywords:

MRI
Voxel-based morphometry
Visual rating scales
Atrophy level
Grey matter volume
Cognitive tests
Elderly

ABSTRACT

Aging is often associated with changes in brain structures as well as in cognitive functions. Structural changes can be visualized with Magnetic Resonance Imaging (MRI) using voxel-based grey matter morphometry (VBM) and visual rating scales to assess atrophy level. Several MRI studies have shown that possible neural correlates of cognitive changes can be seen in normal aging. It is still not fully understood how cognitive function as measured by tests and demographic factors are related to brain changes in the MRI. We recruited 55 healthy elderly subjects aged 50–79 years. A battery of cognitive tests was administered to all subjects prior to MRI scanning. Our aim was to assess correlations between age, sex, education, cognitive test performance, and the said two MRI-based measures. Our results show significant differences in VBM grey matter volume for education level (≤ 12 vs. > 12 years), with a smaller amount of grey matter volume in subjects with lower educational levels, and for age in interaction with education, indicating larger grey matter volume for young, higher educated adults. Also, grey matter volume was found to be correlated with working memory function (Digit Span Backward). Furthermore, significant positive correlations were found between visual ratings and both age and education, showing larger atrophy levels with increasing age and decreasing level of education. These findings provide supportive evidence that MRI-VBM detects structural differences for education level, and correlates with educational level and age, and working memory task performance.

1. Introduction

Along with the increase in life expectancy, the group of elderly at risk of developing neurodegenerative pathologies such as Mild Cognitive Impairment (MCI) and Alzheimer's Disease (AD) has been steadily increasing, creating a burgeoning health problem that threatens to overwhelm our health care organizations in the coming decades. Although there is no cure or remedy, it is important to detect signs of pathological cognitive decline in its earliest possible stage so that a coordinated care plan can be developed aimed at postponing further decline and eventually institutionalization (Dubois et al., 2016). Clinical tools, such as Magnetic Resonance Imaging (MRI), Positron Emission Tomography (PET), and neuropsychological tests are routinely used to diagnose neurodegenerative pathologies in elderly people. However,

despite the impressive body of research on characterizing different neurological conditions using these clinical tools (Fox et al., 1999; Frisoni et al., 2010; Chan et al., 2003; Nordberg et al., 2010; Verhoeff et al., 2004; McKhann et al., 1984), studies on structural brain correlates of cognitive test performance and demographic characteristics in healthy middle-aged and older adults are still scarce. Understanding this relationship would imply a significant stride in delineating the neurocognitive profile of normal aging.

The effect of age-related cognitive decline on the aging brain has been evidenced with both structural and functional Magnetic Resonance Imaging (MRI). Additionally, the technique enables the detection of non-diseased brain aging and facilitates the study of anatomical changes that can lead to cognitive symptoms that accompany pathologies such as MCI and AD. MRI studies of the healthy aging brain

* Corresponding author at: Department of Neurosciences, Laboratory for Neuro- & Psychophysiology, Herestraat 49, 3000 Leuven, Belgium.
E-mail address: valentina.pergher@kuleuven.be (V. Pergher).

have identified age-related grey matter volume decreases (Allen et al., 2005; Jernigan et al., 2001; Sowell et al., 2003; Walhovd et al., 2005) that are mainly located in the frontal lobe (Coffey, 1994; Tisserand et al., 2002; Rypma et al., 2001; Van Petten et al., 2004). This supports the frontal theory of cognitive aging suggesting that changes in frontal brain structures are responsible for the decline in memory, attention, and cognitive flexibility that accompany healthy aging (Phillips and Della Sala, 1998). In contrast, only few studies have demonstrated age-related changes in other substructures, such as temporal and parietal regions (Hutton et al., 2009; Giorgio et al., 2010; Grieve et al., 2005; Terribilli et al., 2011). Additionally, some studies suggest that not only aging affects grey matter volume in healthy older adults (Tisserand et al., 2004), but that it can also be sex-related as Raz et al. (1997) and Good et al. (2001) showed differences in whole brain volume of men and women, with a steeper aging trend in men. Witte et al. (2010) found a difference in grey matter volume of male and female brains that was already discernable in young healthy adults. Furthermore, also educational level has been related to changes in grey matter volume. Arenaza-Urquijo et al. (2013) showed that more educated individuals had greater grey matter volume in the superior temporal gyrus, insula and anterior cingulate cortex. Boller et al. (2017), by using a VBM approach, showed a positive correlation between years of education and cortical grey matter volume in the right medial and middle frontal gyri, in the middle and posterior cingulate gyri, and in the right inferior parietal lobule. Moreover, they found that grey matter volume loss in older adults was larger for lower educated individuals in the left middle frontal gyrus and in the right medial cingulate gyrus. Similarly, Steffener et al. (2014) found that although grey matter volume is affected by age-related decline, educational level can curb the effect on cognition. In particular, they showed a stronger positive relationship between brain measures and fluid intelligence in more educated older adults. It has been suggested that cognitive reserve, defined as the brain's ability to perform demanding task more effectively or with the same accuracy by involving additional networks or by adopting alternative cognitive strategies, allows some people to cope better with cognitive decline than their age-matched peers (Stern, 2012).

Using voxel-based grey matter morphometry (VBM) and visual rating scales to assess atrophy level, MRI studies have shown that one can detect atrophy level changes in aging. The VBM method has been used to assess brain volume on a voxel-by-voxel basis. It has been applied across the brain in both healthy older adults (Good et al., 2001; Raz et al., 1997) and MCI, AD, and Parkinson's Disease (PD) patients (McDonald et al., 2009; Frisoni et al., 2008; Crowley et al., 2018). VBM is an automated, unbiased method for voxel-wise comparison of grey or white matter between groups of individuals from high-resolution MRI scans (Ashburner and Friston, 2000). This method generally matches the MR images in a common space, correcting for non-uniformities and estimating the value of each voxel by representing the proportion of a specific tissue in that voxel. After smoothing the grey matter to create a normally distributed field of grey matter quantity, a voxel-by-voxel comparison can be computed over the whole brain by using a linear regression model. Altogether many studies used region of interest (ROI) to assess atrophy level, recently, it has been shown that a whole brain analysis is more sensitive compared to a ROI analysis as the latter may not be sensitive enough to detect small and more diffuse changes, also in a short period of time (Chetelat and Baron, 2003). Additionally, the ROI method implies a prior hypothesis regarding the structure to assess, which could detect only partially grey matter volume reduction (Chetelat and Baron, 2003). Using a statistical approach known as Statistical Parametric Mapping (SPM), the VBM method can be used to compare the grey matter volume on a voxel by voxel basis of a group of patients with that of a control group. The results are a 3D map of significant regional differences of grey matter volume reduction, associated with grey matter atrophy, typically in the hippocampal region, posterior cingulate and intraparietal sulcus.

Another method that has been used to assess atrophy levels is visual

inspection of structural MR imaging. It is routinely used also in a clinical settings to assess cognitive pathologies such as Mild Cognitive Impairment (MCI) and Alzheimer's disease (AD). The first brain areas that exhibit an increase in atrophy level in normal aging, which exacerbates in MCI and AD, are the medial temporal lobe and the hippocampal pathway (entorhinal cortex, hippocampus and posterior cingulate cortex) and linked to memory deficits (Dubois et al., 2007; Scheltens et al., 1995; Scheltens, 2001). Only at a later stage in healthy aging, the temporal, parietal and frontal neocortices also exhibit atrophy as measured by visual ratings scales, which has been associated with visuospatial, behavioral and language impairments (Lehrner et al., 2005; Scheltens et al., 1995). Although visual rating scales are commonly used in clinical settings to differentiate healthy adults from MCI and AD patients (Fox et al., 1999; Scheltens et al., 1995), it has been shown that visual scales can also detect normal brain changes in healthy old adults at different ages (Coffey et al., 1992). In contrast, no studies are available that correlated visual rating scales and education or sex. One of the most common visual rating scales is the medial temporal atrophy (MTA) developed by Scheltens et al. (1995), while more recently another visual rating scale, validated for differentiating between healthy adults and AD patients, is the posterior atrophy developed by Koedam et al. (2011). A third one is the global cortical atrophy scale (GCA) and it has been shown to yield greater sensitivity in detecting global atrophy for distinguishing between healthy adults and patients with MCI and AD (Fox et al., 1999). In general, visual rating scales are applied to brain regions where atrophy could be present such as the medial temporal lobe atrophy (MTA) to correlate with cognitive decline in healthy adults or a progression of decline in MCI patients (Scheltens and van de Pol, 2012; Korf et al., 2004; Scheltens et al., 1995; Duara et al., 2008).

Besides neuroimaging, also neuropsychological tests have been used to detect changes over adult lifespan (Christensen, 2001), and to differentiate between normal age-related cognitive performance and pathological, as they gauge several cognitive functions, such as memory, problems solving, general cognitive functioning, attention, reasoning, executive functions, and spatial abilities (Drag and Bieliasukas, 2010; Chao and Knight, 1997; MacPherson et al., 2002). Several studies relied on these tests to assess cognitive decline during normal aging (Greenwood, 2000; Proust-Lima et al., 2006; Hester et al., 2004) and as an indication of (preclinical) Alzheimer's disease (AD) or risk of developing dementia (Gainotti et al., 2014; Tabert et al., 2006; Baddeley et al., 1991; Spieler et al., 1996). While sustained attention is relatively unaffected by normal aging, inhibition and selective attention change with age, affecting the ability to focus on relevant information. The Stroop Interference test is one of the most common tests used to measure selective attention and inhibition of distractor stimuli (Greenwood, 2000). Decrease in inhibitory control and attention have been associated with alteration of prefrontal functioning where the first structural changes have been shown in subjects at risk of developing dementia or at early stage of Alzheimer's disease (AD) (Greenwood, 2000). Also, Proust-Lima et al. (2006) and Hester et al. (2004) reported sensitivity to normal aging for MMSE and Digit Span Forward and Backward tests, suggesting an age-related decline in central executive performance. Moreover, other cognitive tests have been shown to distinguish cognitive functioning of normal elderly from AD patients. For instance, Tierney et al. (2005) reported results from a large longitudinal epidemiologic sample, providing supporting evidence that specific neuropsychological tests, such as verbal recall, fluency, memory, etc., are sensitive to normal aging and can accurately predict the probability of conversion to incident AD after 5 or 10 years in healthy non-demented participants. Furthermore, Baddeley et al. (1991) showed that by using the Digit Span Backward test, which relies on working memory ability, significant differences were obtained for AD patients compared to healthy controls in terms of accuracy and speed of performance. Also, when using an attention and interference task, named Stroop test, Spieler et al. (1996) found similar results when comparing healthy

young and older adults, and patients with AD. They observed that the interference effect of the Stroop test was much stronger for AD patients compared to healthy individuals. Interestingly, relationships between grey matter volume and cognitive tests have been shown by Gunning-Dixon and Raz (2003) who identified a link between MRI-prefrontal grey matter volume and executive function test performance when comparing middle-aged and older adults. Raz et al. (1998) showed also a correlation between grey matter volume for visual processing brain area and working memory tasks in aging. Also, the study of Van Der Werf et al. (2001) found a significant association between thalamic volume and impairments in cognitive speed test of healthy older adults. While several studies found correlations between grey matter volume and cognitive tests, in contrast other studies failed to find evidence for a relationship between brain volume and cognitive functions in aging (Tisserand et al., 2000; Ylikoski et al., 2000).

In our study, 55 healthy old participants underwent an MRI scan and cognitive tests. The aim of our study was to assess correlations between age, sex, education, cognitive test performance and MRI correlates of grey matter volume and atrophy level based on voxel based morphometry (VBM) and visual rating scales. In this way, we wanted to assess the structural brain changes in relation to the decline in cognitive abilities that occur with normal aging.

2. Material and methods

Two samples were combined for the purpose of the present study, in total comprising 55 healthy older adults. Potential participants were reached using flyers, social network posts, and advertisements in a local newspaper. Forty-six participants were native Finnish-speakers and nine participants native Flemish-Dutch-speakers. We included in the present study participants between 50 and 79 years old who had a Mini Mental State Examination (MMSE; Folstein et al., 1975) score above 25, no history of neurological or psychiatric disorders, or traumatic brain injury involving loss of consciousness, concussion, and/or post-traumatic cognitive dysfunction, and normal or corrected-to-normal vision. For all participants the procedure consisted of an anatomical MRI scan and a battery of neuropsychological tests: MMSE, Digit Span Forward and Backward of the Wechsler Adult Intelligence Scale (WAIS; Wechsler, 1945), and Stroop Color-Word Test (Stroop, 1935) (for a more detailed account of the method involving the 46 Finnish-speakers, see Saarela et al., 2017). MR imaging was performed within 22 weeks (14.5 ± 5.8) of neuropsychological assessment. MR imaging was conducted at the Radiology Departments of the Hospital District of Southwest Finland in Turku (Finland) and the Gasthuisberg University Hospital in Leuven (Belgium), and the cognitive tests in the Department of Psychology at Åbo Akademi University (Finland) and the Laboratory of Neuro- and Psychophysiology of KU Leuven (Belgium), for the corresponding participant groups. Written informed consent was obtained from all participants in accordance with the Declaration of Helsinki and its later amendments.

2.1. Structural MRI

MR imaging was performed using a 3.0 T scanner (Philips, The Netherlands) at the Radiology Department in Gasthuisberg Hospital in Leuven (Belgium) and a 1.5 T scanner (Verio, Siemens Medical Imaging, Erlangen, Germany) at the Hospital District of Southwest (Finland), respectively. All subjects were examined according to a standard dementia MRI protocol: axial T2-weighted images, 3D fluid-attenuated inversion recovery (FLAIR), coronal T2-weighted images with perpendicular hippocampus orientation, axial diffusion weighted imaging, T2-weighted images, and gradient-echo T1-weighted 3D images. On the 1.5 T MR, the imaging parameters of the 3D gradient-echo T1 weighted images were: TR/TE 1900/2.67 ms, flip angle 15°, field of view 256 × 256, slice thickness 1 mm and 192 slices. On the 3.0 T MR, the imaging parameters of the 3D gradient-echo T1 weighted

images were: TR/TE 2300/3 ms, flip angle 9°, field of view 256 × 240, slice thickness 1 mm and 160 slices.

Based on MR imaging, we used two different approaches: VBM and visual inspection based on three visual rating scales. Both methods were based on a linear regression analysis:

$$y_j = x_{j1} b_1 + \dots + x_{jp} b_p + e_j$$

where:

- y_j is the estimated dependent variable (the data from the scan),
- x_{jp} the independent variable (covariate),
- b_p the regression slope (fixed effect), and
- e_j the residual error.

2.2. Voxel-based morphometry (VBM) and statistical analysis

Voxel-based morphometry (VBM) maps grey matter loss on a voxel-by-voxel basis after anatomical standardization analogous to functional neuroimaging. MR scans were analyzed with SPM12 (Statistical Parametric Mapping, www.fil.ion.ucl.ac.uk/spm) and Matlab version R2016a (nl.mathworks.com/products/matlab/). Processing included MRI scan segmentation (T1 images) to identify different tissue types for each subject, the creation of a template of the whole brain for all subjects using Dartel toolbox (Ashburner, 2007), the modeling of the shape of each brain using three parameters for each voxel (to increase the accuracy of subject grey matter alignment), normalization to Montreal Neurological Institute (MNI) Space of the original images to the template, the generation of smoothed (with

a 5-mm isotropic Gaussian kernel), spatially normalized and Jacobian-scaled grey matter images in MNI space (Ashburner, 2009; Kurth et al., 2015; Mechelli et al., 2005;) and, finally, the statistical analysis using a linear model to fit the processed data and to make inferences about any differences in the data.

The correlations between demographic variables or cognitive test performance and whole brain VBM were determined using a linear regression analysis (mentioned above). Total Intracranial Volume (TIV), age, sex, level of education (in years), and cognitive tests (Digit Span Forward, Digit Span Backward and Stroop test for interference) were used as covariates. We considered the absolute span (maximum number of items in a string) for both the Digit Span Forward and Backward tests, while for the Stroop test for interference we calculated the simplified formula of (Word × Color)/(Word + Color) for the number of predicted Color-Word items completed in 45 s (Golden and Freshwater, 1978). Statistical significance was set using cluster-based Family Wise Error correction (cFWE, $p = .05$) combined with a voxel-level peak detection threshold of $p = .001$ uncorrected for multiple comparisons (Roiser et al., 2016). Anatomical regions were defined using the Automated Anatomical Labeling (AAL) toolbox (<http://www.gin.cnrs.fr/AAL>) (Tzourio-Mazoyer et al., 2002). The peak coordinates are presented in MNI standard space. The results were visualized using SPM12. Furthermore, a t -test analysis was performed to investigate the relationship between grey matter volume and age, sex, education, and cognitive tests (Digit Span Forward, Digit Span Backward, and Stroop test for interference).

2.3. Visual rating scales and statistical analysis

The second method refers to a qualitative evaluation of atrophy level. MRI's were assessed in native space by two different raters: a neuroradiologist and an assistant-neuroradiologist in Gasthuisberg Hospital in Leuven (Belgium). They evaluated GCA (van de Pol et al., 2006a,b) and Koedam (Koedam et al., 2011) using a 4-point rating scale (0–3), and MTA (Scheltens and van de Pol, 2012; Korf et al., 2004; Scheltens et al., 1995; Duara et al., 2008) using a 5-point rating scale (Fig. 1). For our statistical analysis, we used averaged scores of the left

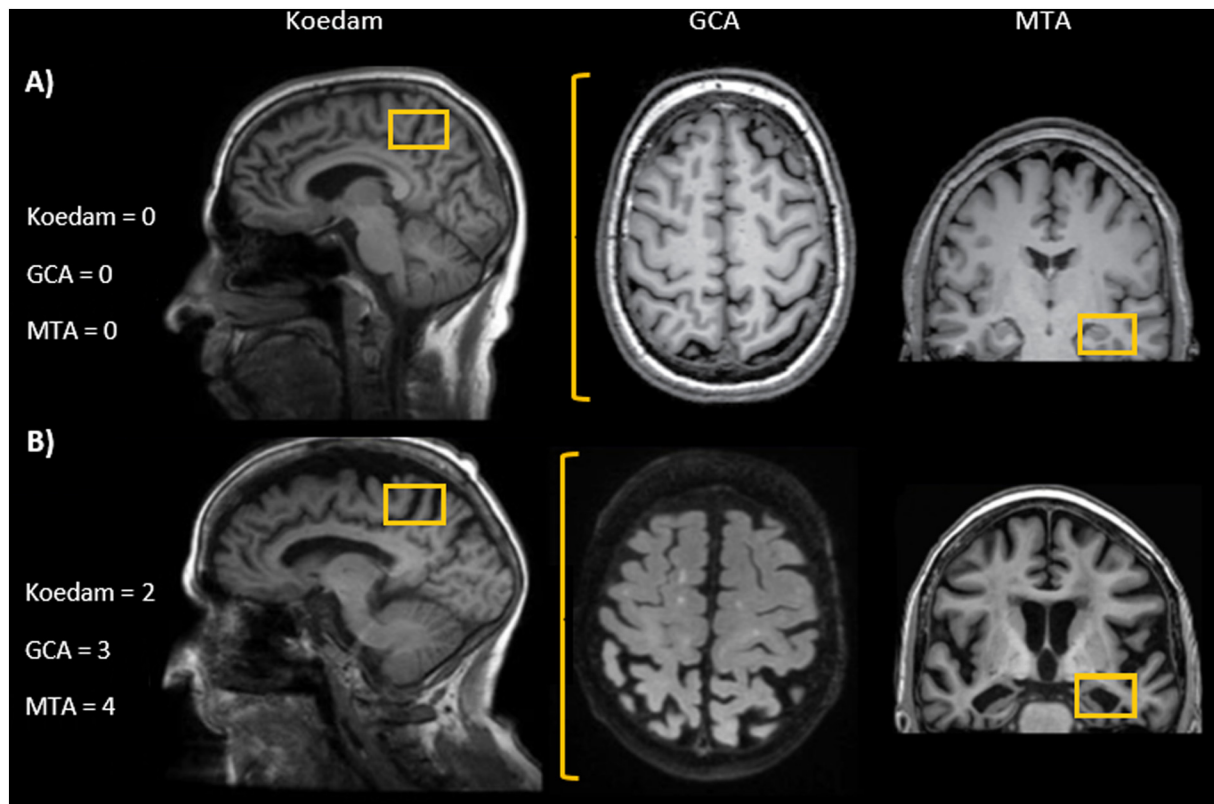


Fig. 1. Differences in visual rating scales scores (Koedam, MTA, and GCA) for (A) a healthy older adult and (B) a patient with AD. Patient images were adapted from ‘Neuroimaging in Dementia’ by Barkhof et al. (2011).

and right hemispheres for the GTA, Koedam, and MTA scales. The relationship between the visual rating scales (GCA, Koedam and MTA) and age, sex, education, and cognitive test performance (Digit Span Forward, Digit Span Backward, and Stroop test for interference) was investigated using a *t*-test.

The GCA scale evaluates cerebral atrophy (van de Pol et al., 2006a, 2006b) in 13 brain regions separately in each hemisphere (sulcal dilatation: frontal, parieto-occipital, temporal; ventricular dilatation: frontal, parieto-occipital, temporal, third ventricle). A 4-point rating scale is adopted: 0 = normal volume/no ventricular enlargement, 1 = opening of sulci/mild ventricular enlargement, 2 = volume loss of gyri/moderate ventricular enlargement, 3 = ‘knife blade’ atrophy/severe ventricular enlargement.

The posterior atrophy precuneus (Koedam) scale has been developed to enable visual assessment of posterior atrophy on MRI (Koedam et al., 2011). The score takes three planes into consideration: sagittal plane (posterior cingulate sulcus, parieto-occipital sulcus, precuneus gyrus); coronal plane (posterior cingulate sulcus, parietal gyrus); axial plane (posterior cingulate sulcus, parietal lobes). A 3-point scale is adopted: grade 0 = closed sulci, no gyral atrophy; grade 1 = mild sulcal widening, mild gyral atrophy; grade 2 = substantial sulcal widening, substantial gyral atrophy; grade 3 = marked sulcal widening, knife-blade gyral atrophy).

The MTA scale is based on a visual score of the hippocampus, at the level of the anterior pons, according to three features: width of the choroid fissure, width of the temporal horn of the lateral ventricle, height of the hippocampus (Scheltens and van de Pol, 2012; Korf et al., 2004). The MTA uses a 5-point rating scale interpreted in relation to age (< 75 years: ≥ 1.5 is abnormal, > 75 years: ≥ 2 is abnormal) (Schoonenboom et al., 2008): 0 = no CSF is visible around the hippocampus, 1 = choroid fissure is slightly widened, 2 = moderate widening of the choroid fissure, mild enlargement of the temporal horn and mild loss of hippocampal height, 3 = marked widening of the

choroid fissure, moderate enlargement of the temporal horn, and moderate loss of hippocampal height, 4 = marked widening of the choroid fissure, marked enlargement of the temporal horn, and markedly atrophied hippocampus with lost internal structure (Scheltens et al., 1995; Duara et al., 2008).

2.4. Correlation between VBM and visual rating scales

The use of both VBM and visual rating scales of atrophy was motivated by the study of Harper et al. (2016) who showed a negative partial correlation between VBM for grey matter volume and each one of six visual rating scales for atrophy level (i.e., for anterior cingulate, orbito-frontal, anterior temporal, fronto-insula, medial temporal and posterior regions). When applied to our case, Fig. 2 illustrates the correlations between MRI grey matter volume and two of the visual rating scales of atrophy level we used (i.e., MTA and Koedam).

3. Results

3.1. Participant characteristics

Demographical data, MMSE, cognitive test performance, and scores of GCA, Koedam and MTA visual rating scales of the 55 participants are summarized in Table 1. Age, education, sex, and MMSE were equally distributed among participants. Given the age-range in our subject database, we distinguished two almost equal-sized age-groups: young-old adults ($n = 31$), between 50 and 62 years, and old adults ($n = 24$), between 63 and 79 years. In the same vein, given our subjects' years of education, we distinguished two educational levels (low: ≤ 12 years) and high: > 12 years). Significant differences between age sub-groups were found, using a *t*-test, for age ($p < .001$) and MTA ($p < .05$), and between educational level sub-groups for education ($p < .001$).

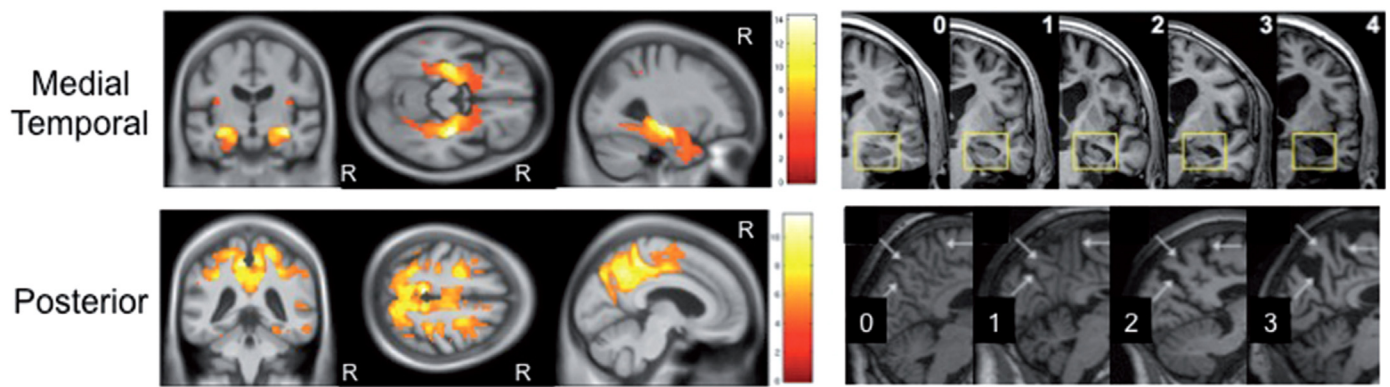


Fig. 2. Correlation between grey matter volume and two visual rating scales (MTA and Koedam (posterior)). VBM demonstrated a negative partial correlation between grey matter volume (left) and each visual rating scale (right). In all images statistical significance of correlations was corrected for multiple comparisons (family wise error rate $p < .05$). R indicates right hemisphere. Images were adapted from the study of Harper et al. (2016).

3.2. Statistical analysis between grey matter volume (VBM) and demographic and cognitive variables

The anatomical labeling of the clusters is listed in Table 2. Grey matter volume, calculated using VBM, was tested for age and educational level, controlling for sex. Linear regression-based analysis showed statistically significant positive correlations between level of education and regional grey matter volume, in a cluster in the right caudate nucleus (MNI coordinates: 11.6–1.1 20; cluster size $k = 19$ voxels; peak size $T = 4.03$; Z score = 3.70; P peak level uncorrected, $P = .846$; P cluster level uncorrected, $P = .000$), in a cluster in the right midcingulate cortex (MNI coordinates: 12.2–38.3 44, 7.6–37 46; cluster size $k = 24$, $k = 22$ voxels; peak size $T = 3.70$, $T = 3.63$; Z score = 3.43, Z score = 3.38; P peak level uncorrected, $P = .822$, $P = .831$; P cluster level uncorrected, $P = .000$, $P = .000$), in a cluster in the left precuneus (MNI coordinates: -5.4 -60.5 28; cluster size $k = 38$ voxels; peak size $T = 3.04$; Z score = 2.88; P peak level uncorrected, $P = .766$; P cluster level uncorrected, $P = .001$) and in a cluster in the right precuneus (MNI coordinates: 7.1–57.9 48, 6.6–55.8 20; cluster size $k = 18$, $k = 12$ voxels; peak size $T = 2.99$, $T = 2.83$; Z score = 2.84, Z score = 2.70; P peak level uncorrected, $P = .851$, $P = .884$; P cluster level uncorrected, $P = .001$, $P = .001$) (Fig. 3; Table 2). No significant correlations were found for age. Furthermore, we tested whether regional grey matter volume was correlated with performance accuracy of Digit Span Forward, Digit Span Backward, and Stroop interference. Considered the small variability of Digit Span test, we transformed the values in z-scores and calculated the normal distribution using K-test (one-simple Kolmogorov-Smirnov test, significant for $p < .01$). Our p -value was equal to 0.03 that allowed us to correlate

z-scores with cognitive test scores. Higher scores on Digit Span Backward was significantly associated with larger regional grey matter volume in a cluster in the right mid-cingulate cortex (MNI coordinates: 1.7–35.4 45; cluster size $k = 42$ voxels; peak size $T = 3.76$; Z score = 3.48; P peak level uncorrected, $P = .752$; P cluster level uncorrected, $P = .000$) and in a cluster in the right posterior cingulate cortex (MNI coordinates: 7.9–45.8 26; cluster size $k = 17$ voxels; peak size $T = 3.38$; Z score = 3.17; P peak level uncorrected, $P = .856$; P cluster level uncorrected, $P = .001$) (Fig. 3; Table 2). No significant correlations were found for Digit Span Forward and Stroop tests.

Furthermore, using a linear regression analyses, we assessed the influence of age, educational level and sex on regional grey matter volume. In particular, we ran our analyses on age with the interaction of educational level and sex. Our results showed a larger grey matter volume for younger adults, when their educational level was high, specifically the most significant peak and cluster were located in the Right Caudate Nucleus (MNI coordinates: 11.6–1.1 20; cluster size $k = 19$ voxels; peak size $T = 4.94$; Z score = 4.44; P peak level uncorrected, $P = .000$; P cluster level uncorrected, $P = .777$) and in the Right Mid-Cingulate Cortex (68%: Area 5 Ci (SPL); MNI coordinates: 12.1–38.2 43; cluster size $k = 13$ voxels; peak size $T = 3.86$; Z score = 3.60; P peak level uncorrected, $P = .000$; P cluster level uncorrected, $P = .822$). We did not find a significant influence of age on grey matter volume when considering sex interaction. Based on these results, we used three factorial analysis (ANOVA) to examine possible differences between groups as classified by age (young-old vs old), education (high/low) and sex (male/female) in the correlation between VBM and cognitive test performance. In contrast, we did not find any significant differences in brain (grey matter volume) -cognition (Digit

Table 1

Participants' characteristics for age and educational level sub-groups.

Variables	Total (N = 55)		Young-old (n = 31)		Old (n = 24)		High educat. (n = 25)		Low educat. (n = 30)	
	Mean	SD	Mean	SD	Mean	SD	Mean	SD	Mean	SD
Age	62.2	7.6	56.83**	3.7**	69.33**	5.03**	63.32	7.86	61.33	1.33
Education	12.9	3.35	12.79	3.15	12.95	3.65	15.49**	1.31**	10.3**	2.12**
Sex (23 M)	–	–	(13 M)	–	(10 M)	–	(13 M)	–	(10 M)	–
MMSE	28.8	1.2	28.55	1.34	29.04	0.86	28.52	1.36	28.97	0.96
Digit Forward	6.18	1.49	6.16	1.42	6.21	1.61	6.08	1.25	6.27	1.68
Digit Backward	4.89	1.15	5.03	1.33	4.71	0.86	4.84	0.85	4.93	1.36
Stroop	99.67	0.67	99.64	0.8	99.71	0.46	99.72	0.46	99.63	0.81
GCA (0–3)	1.24	0.6	1.08	0.47	1.48	0.68	1.32	0.5	1.03	0.72
Koedam (0–3)	1.17	0.66	0.95	0.62	1.48	0.6	1.32	0.56	1.17	0.67
MTA (0–4)	1.39	0.65	1.27*	0.66*	1.56*	0.61*	1.44	0.55	1.34	0.73

GCA = global cerebral atrophy, Koedam = Koedam posterior atrophy precuneus, MTA = medial temporal atrophy.

* $p < .05$.

** $p < .001$.

Table 2
Peak and cluster level of significant (individual characteristics, cognitive tests scores and scan location using cluster-based Family Wise Error correction (cFWE, $p = .05$) combined with a voxel-level peak detection threshold of $p = .001$ uncorrected for multiple comparisons) clusters of grey matter volume in 55 healthy old subjects.

	T value			P (uncorrected peak level)			MNI coordinates (mm)			K value (voxels)			Labels	%	P (uncorrected cluster level)
	Z	Z	Z	X	Y	Z	X	Y	Z	X	Y	Z			
Education	4.03	3.70	0.000	11.6	-1.1	20	19			Right Caudate Nucleus	-	0.846			
	3.70	3.43	0.000	12.2	-38.3	44	24			Right Mid-Cingulate Cortex	71%: Area 5Ci (SPL)	0.822			
	3.63	3.38	0.000	7.6	-37.0	46	22			Right Mid-Cingulate Cortex	61%: Area 5Ci (SPL) 31%: Area 5M (SPL)	0.831			
Digit span backward	3.04	2.88	0.001	-5.4	-60.5	28	38			Left Precuneus	-	0.766			
	2.99	2.84	0.001	7.1	-57.9	48	18			Right Precuneus	-	0.851			
	2.83	2.70	0.001	6.6	-55.8	20	12			Right Precuneus	-	0.884			
	3.76	3.48	0.000	1.7	-35.4	45	42			Right Mid-Cingulate Cortex	25%: Area 5M (SPL) 21%: Area 5Ci (SPL)	0.752			
	3.38	3.17	0.001	7.9	-45.8	26	17			Right Posterior Cingulate Cortex	9%: Area 4a	0.856			

Span Backward, Forward and Stroop tests) correlations in any of the three group-wise comparison (high vs. low educational level group, male vs. female group and young-old vs. old group).

3.3. Correlations between Visual Rating Scales and cognitive variables

We repeated the linear regression analysis but now for visual rating scales, for MTA, GCA, and Koedam. The time spent to perform and record all three visual rating scales, based on two raters, for our population ($N = 55$) was 3.5 ± 1 min per patient. We correlated each visual rating scale with age, sex, and educational level in 55 subjects (Fig. 4). Moreover, we assessed correlations between visual rating scales and performance accuracy of Digit Span Forward, Digit Span Backward, and Stroop interference, added as covariates to our general linear model. Given the small variability in the three visual rating scales scores, we transformed them into z-scores and tested the latter for normality using the K-test (one-sample Kolmogorov-Smirnov test, significant for $p < .01$). As the p -value turned out to be equal to 0.019 for MTA scale, 0.012 for GCA scale and 0.014 for Koedam scale, the z-scores can be correlated with individual characteristics and cognitive test scores. Significant correlations were found between GCA and age ($r^2 = 0.1317$, $p = .0065$, < 0.01), and between Koedam and age ($r^2 = 0.1626$, $p = .0023$, < 0.01), between Koedam and education ($r^2 = 0.0703$, $p = .049$, $p < .05$), indicating that the older the participants were, the higher their level of global cerebral atrophy and posterior atrophy, and that higher the level of education, the smaller their level of global cerebral atrophy and posterior atrophy. In contrast, no significant correlations were found for other demographic variables and for cognitive tests performance. Finally, we paired all the visual rating scales and correlated them with both demographic variables and cognitive test performance. Also in this case, significant correlations were found between age and Koedam and GCA ($r^2 = 0.1468$, $p = .00036$, $p < .001$), Koedam and MTA ($r^2 = 0.0943$, $p = .0011$, $p < .01$), and GCA and MTA ($r^2 = 0.0824$, $p = .0024$, $p < .01$), and between Koedam and GCA and education ($r^2 = 0.0616$, $p = .0089$, $p < .01$).

To further investigate aging, and how MTA, Koedam and GCA scales can signal it, we investigated the significance of paired visual rating scales for our two groups of old adults separately (Table 3). We dichotomized the scores for MTA, Koedam and GCA, with an average score of > 1 considered abnormal for all three scales. Most of the young-old adults had normal scores (≤ 1) for MTA and Koedam (51.61%), and for MTA and GCA (51.61%). For the old adults group we found normal scores for MTA and Koedam (16.66%) and for MTA and GCA (25%), but higher values, indicating abnormal scores, were found for MTA and Koedam (41.66%), and for MTA and GCA (50%).

In sum, using regression-based analyses, only level of education (in years) and Digit Span Backward ($p < .05$) showed statistically significant associations with regional grey matter volume as measured by whole brain VBM, whereas using group-level analyses, statistically significant differences in grey matter volume were found for all three demographic variables: age, sex, and educational level ($p < .05$). In contrast, only age ($p < .01$) showed significant correlations with atrophy level as measured by GCA and Koedam visual rating scales, and as measured using combinations of Koedam and GCA, Koedam and MTA, and GCA and MTA visual rating scales.

4. Discussion

The aim of our study was to investigate correlations between age, sex, education, cognitive test performance and MRI grey matter volume and atrophy level by using the VBM approach. We included 55 healthy old participants that underwent an MRI scan and a battery of cognitive tests. We correlated the outcome of VBM, a rather novel technique in clinical settings, of healthy adults, differentiated by age, sex and level of education, with visual rating scales applied to whole brain MRI data,

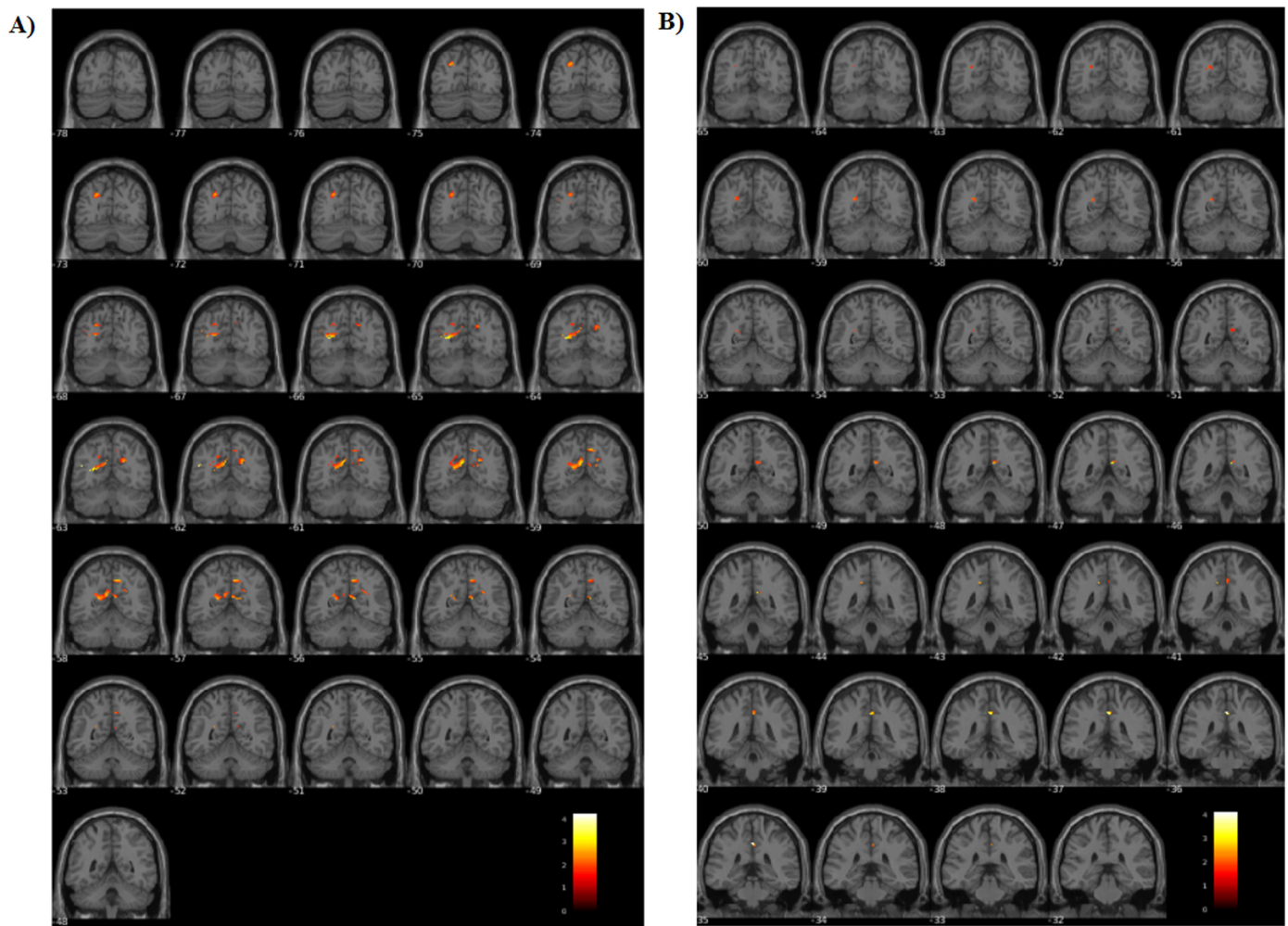


Fig. 3. Location in terms of MNI coordinates of significant grey matter peaks and clusters for Digit Span Backward test (A) and education (B) reported in Table 2.

instead of ROIs, and with their demographics and cognitive test results. To the best of our knowledge such studies have not been reported before. Our use of both visual rate scale and VBM analysis was motivated by the study of Harper et al. (2016) who correlated 6 visual rating scales of atrophy level and whole brain VBM grey matter volume in (post-mortem) dementia patients, but different from those studies where the brain volume analysis was confined to the ROIs considered for visual rating of atrophy level (Davies et al., 2009; Möller et al., 2014; Shen et al., 2011). Compared to the ROI approach, it has been shown that a whole brain analysis is more sensitive in discriminating between MCI, AD and healthy adults (Chetelat and Baron, 2003). Additionally, the ROI method assess only partially the entire cortex and may not be sensitive enough to detect small and more diffuse changes over time. However, using a ROI method implies prior hypothesis regarding the structure to evaluate, which could detect only partially grey matter volume reduction (Chetelat and Baron, 2003).

Although we did find significant correlations between grey matter volume and both level of education and Digit Span Backward with normal aging by considering our 55 participants all together, and more specifically, between the two age-groups we defined, when we added 6 different sub-categories separately to our general regression model, based on age (young-old vs old), level of education (high level educated vs low level educated) and sex (males vs females), we found significant differences between sub-categories of the same age-group and educational level interaction in terms of grey matter volume, but we did not find correlations with cognitive test performance. These results are in line with two other studies that used the VBM method to investigate the

relation between grey matter volume and demographic characteristics. Arenaza-Urquijo et al. (2013) showed that more educated individuals have larger grey matter volume in the superior temporal gyrus, insula, and anterior cingulate cortex, and Boller et al. (2017) reported larger grey matter volume loss in older adults with lower educational level in the left middle frontal gyrus and in the right medial cingulate gyrus. In contrast, the brain regions in our findings differ from the ones implicated in these studies, as we observed significant areas of interest in the right caudate nucleus and right mid-cingulate cortex when considering the interaction between age and educational level. Also, Boller et al. (2017) showed significant correlations between activation of specific brain areas and increasing load during an N-Back task, using a ROIs approach and functional MRI (not structural). Furthermore, one should note that the tasks used in their study, N-Back, and in our study, Digit Back Forward and Backward and Stroop, involve different cognitive abilities: in the first case working memory (WM) while in the second case short-term memory (STM) and attention and interference.

For both correlations of VBM grey matter volume and visual rating scales atrophy level based on MRI data with cognitive test outcomes, we used grey matter volume as dependent variable ('y') and the different cognitive variables as covariates (independent variables, 'x'), from a quantitative point of view. Our findings suggested significant positive correlations between VBM grey matter volume and education considering both age groups, between grey matter volume and age considering the interaction with educational level, and between grey matter volume and Digit Span Backward. Furthermore, testing for demographic variables (age and level of education, controlling for sex)

	Koedam	GCA	MTA	Koedam + GCA	Koedam + MTA	GCA + MTA
Age	<0.01*	<0.01*	-	<0.001*	<0.01*	<0.05**
Education	<0.05**	-	-	<0.01*	-	-

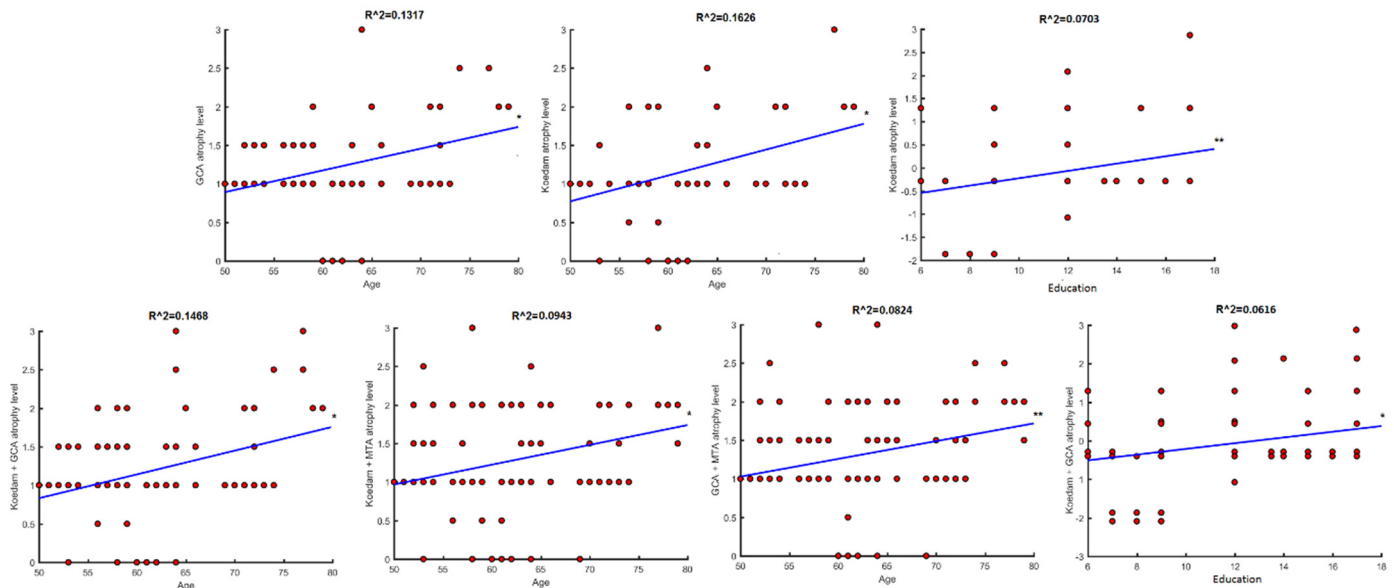


Fig. 4. Linear regression analysis between visual rating scales (Koedam, GCA and MTA) and age and education in 55 subjects.

Table 3

Distribution of grey matter atrophy for Koedam, GCA and MTA scales in young-old (age range 52–62 years) and old (age range 63–79 years) adults.

	MTA	Koedam		GCA	
		Normal	Abnormal	Normal	Abnormal
Young-old (N = 31)	Normal	16 (51.61%)	4 (12.9%)	16 (51.61%)	4 (12.9%)
	Abnormal	9 (29.03%)	2 (6.45%)	6 (19.35%)	5 (16.13%)
Old (N = 24)	Normal	4 (16.66%)	2 (8.33%)	6 (25%)	-
	Abnormal	8 (33.33%)	10 (41.66%)	6 (25%)	12 (50%)

showed independently that a smaller amount of grey matter volume corresponds to subjects with lower educational levels. From a qualitative point of view, we fitted in our model the same covariates, changing the dependent variable ('y') to visual rating scale scores. Our results showed a significant positive correlation between atrophy level and both age and age-group (young-old vs old adults) and educational level. Comparing the two methods, we can conclude that education, age and education interaction and working memory performance are predictive of grey matter volume, while age is predictive of atrophy level for Koedam and GCA scales separately or Koedam and GCA, Koedam and MTA, and MTA and GCA, and educational level for Koedam and GCA.

In conclusion, this study provides supportive evidence that age and education are important factors to consider when addressing both cognitive test results as well as brain structure, as well as the association between the two. Admittedly, several other factors could be considered for evaluation as well, such as nutritional, substance abuse, etc.

Acknowledgments

The authors gratefully acknowledge Professor Riitta Parkkola for heading the MRI scanning part of the project involving the Finnish-speaking participants. VP was supported by research grant from the Belgian Fund for Scientific Research-Flanders (G088314N), MMVH by the Financing Program (PFV/10/008), the Interdisciplinary Research

Fund (IDO/12/007), the Industrial Research Fund (IOF/HB/12/021), the Special Research Fund of the KU Leuven (C24/18/098), the Belgian Fund for Scientific Research – Flanders (G088314N, GOA0914N, GOA4118N), the Interuniversity Attraction Poles Programme – Belgian Science Policy (IUAP P7/11), the Flemish Regional Ministry of Education (Belgium) (GOA 10/019), and the Hercules Foundation (AKUL 043). CS was supported by grants from the Victoria Foundation, the Swedish Cultural Foundation in Finland, Professor Jan-Magnus Jansson's Foundation for Geriatric Research, the Abo Akademi University Endowment, the former Department of Psychology and Logopedics at Abo Akademi University, the Margaretha Foundation, the Päivikki and Sakari Sohlberg Foundation, the Miina Sillanpää Foundation, and the Sigrid Jusélius Foundation.

References

Allen, J.S., Bruss, J., Brown, C.K., Damasio, H., 2005. Normal neuroanatomical variation due to age: the major lobes and a parcellation of the temporal region. *Neurobiol. Aging* 26 (9), 1245–1260.

Arenaza-Urquijo, E.M., Landeau, B., La Joie, R., Mevel, K., Mézence, F., Perrotin, A., Desgranges, B., Beartres-Faz, D., Eustache, F., Chételat, G., 2013. Relationships between years of education and gray matter volume, metabolism and functional connectivity in healthy elders. *NeuroImage* 83, 450–457.

Ashburner, J., 2007. A fast diffeomorphic image registration algorithm. *NeuroImage* 38 (1), 95–113.

Ashburner, J., 2009. Computational anatomy with the SPM software. *Magn. Reson.*

- Imaging 27 (8), 1163–1174.
- Ashburner, J., Friston, K.J., 2000. Voxel-based morphometry—the methods. *NeuroImage* 6 (Pt 1), 805–821.
- Baddeley, A.D., Bressi, S., DELLA SALA, S., LOGIE, R., Spinnler, H., 1991. The decline of working memory in Alzheimer's disease: a longitudinal study. *Brain* 114 (6), 2521–2542.
- Boller, B., Mellah, S., Ducharme-Laliberté, G., Belleville, S., 2017. Relationships between years of education, regional grey matter volumes, and working memory-related brain activity in healthy older adults. *Brain Imaging Behav.* 11 (2), 304–317.
- Chan, D., Janssen, J.C., Whitwell, J.L., Watt, H.C., Jenkins, R., Frost, C., Rossor, M.N., Fox, N.C., 2003. Change in rates of cerebral atrophy over time in early-onset Alzheimer's disease: longitudinal MRI study. *Lancet* 362 (9390), 1121–1122.
- Chao, L.L., Knight, R.T., 1997. Prefrontal deficits in attention and inhibitory control with aging. *Cerebral cortex* (New York, NY: 1991) 7 (1), 63–69.
- Chetelat, G., Baron, J.C., 2003. Early diagnosis of Alzheimer's disease: contribution of structural neuroimaging. *NeuroImage* 18 (2), 525–541.
- Christensen, H., 2001. What cognitive changes can be expected with normal ageing? *Aust. N. Z. J. Psychiatry* 35 (6), 768–775.
- Coffey, C.E., 1994. Anatomic imaging of the aging human brain: computed tomography and magnetic resonance imaging. In: *Textbook of Geriatric Neuropsychiatry. 1, Washington, DC*, pp. 159–194.
- Coffey, C.E., Wilkinson, W.E., Parashos, L.A., Soady, S.A.R., Sullivan, R.J., Patterson, L.J., Figiel, G.S., Webb, M.C., Spritzer, C.E., Djang, W.T., 1992. Quantitative cerebral anatomy of the aging human brain a cross-sectional study using magnetic resonance imaging. *Neurology* 42 (3), 527.
- Crowley, S., Huang, H., Tanner, J., Zhao, Q., Schwab, N.A., Hixel, L., ... Price, C.C., 2018. Considering total intracranial volume and other nuisance variables in brain voxel based morphometry in idiopathic PD. *Brain Imaging Behav.* 12 (1), 1–12.
- Davies, R.R., Scallan, V.L., Graham, A., Williams, G.B., Graham, K.S., Hodges, J.R., 2009. Development of an MRI rating scale for multiple brain regions: comparison with volumetrics and with voxel-based morphometry. *Neuroradiology* 51 (8), 491–503.
- Drag, L.L., Bieliauskas, L.A., 2010. Contemporary review 2009: cognitive aging. *J. Geriatr. Psychiatry Neurol.* 23 (2), 75–93.
- Duara, R., Loewenstein, D.A., Potter, E., et al., 2008. Medial temporal lobe atrophy on MRI scans and the diagnosis of Alzheimer disease. *Neurology* 71 (24), 1986–1992.
- Dubois, B., Feldman, H.H., Jacova, C., et al., 2007. Research criteria for the diagnosis of Alzheimer's disease: revising the NINCDS-ADRDA criteria. *Lancet Neurol.* 6, 734–746.
- Dubois, B., Padovani, A., Scheltens, P., Rossi, A., Dell'Agnello, G., 2016. Timely diagnosis for Alzheimer's disease: a literature review on benefits and challenges. *J. Alzheimers Dis.* 49 (3), 617–631.
- Folstein, M.F., Folstein, S.E., McHugh, P.R., 1975. Mini-mental state. A practical method for grading the cognitive state of patients for the clinician. *J. Psychiatr. Res.* 12 (3), 189–198.
- Fox, N.C., Scallan, R.I., Crum, W.R., Rossor, M.N., 1999. Correlation between rates of brain atrophy and cognitive decline in AD. *Neurology* 52 (8), 1687.
- Frisoni, G.B., Henneman, W.J., Weiner, M.W., Scheltens, P., Vellas, B., Reynish, E., Hudecova, J., Hampel, H., Burger, K., Blennow, K., Waldemar, G., Johannsen, P., Wahlund, L.-O., Zito, G., Rossini, P.M., Winbald, B., Barkhof, F., 2008. The pilot European Alzheimer's disease neuroimaging initiative of the European Alzheimer's disease consortium. *Alzheimer's Dementia* 4 (4), 255–264.
- Frisoni, G.B., Fox, N.C., Jack Jr., C.R., Scheltens, P., Thompson, P.M., 2010. The clinical use of structural MRI in Alzheimer disease. *Nat. Rev. Neurol.* 6 (2), 67.
- Gainotti, G., Quaranta, D., Vita, M.G., Marra, C., 2014. Neuropsychological predictors of conversion from mild cognitive impairment to Alzheimer's disease. *J. Alzheimers Dis.* 38 (3), 481–495.
- Giorgio, A., Santelli, L., Tomassini, V., Bosnell, R., Smith, S., De Stefano, N., Johansen-Berg, H., 2010. Age-related changes in grey and white matter structure throughout adulthood. *NeuroImage* 51, 943–951.
- Golden, C.J., Freshwater, S.M., 1978. Stroop Color and Word Test.
- Good, C.D., Johnsrude, I., Ashburner, J., Henson, R.N., Friston, K.J., Frackowiak, R.S., 2001. Cerebral asymmetry and the effects of sex and handedness on brain structure: a voxel-based morphometric analysis of 465 normal adult human brains. *NeuroImage* 14 (3), 685–700.
- Greenwood, P.M., 2000. The frontal aging hypothesis evaluated. *J. Int. Neuropsychol. Soc.* 6 (6), 705–726.
- Grieve, S.M., Clark, C.R., Williams, L.M., Peduto, A.J., Gordon, E., 2005. Preservation of limbic and paralimbic structures in aging. *Hum. Brain Mapp.* 25, 391–401.
- Gunning-Dixon, F.M., Raz, N., 2003. Neuroanatomical correlates of selected executive functions in middle-aged and older adults: a prospective MRI study. *Neuropsychologia* 41 (14), 1929–1941.
- Harper, L., Fumagalli, G.G., Barkhof, F., Scheltens, P., O'Brien, J.T., Bouwman, F., Burton, E.J., Rohrer, J.D., Fox, N.C., Ridgway, G.R., Schott, J.M., 2016. MRI visual rating scales in the diagnosis of dementia: evaluation in 184 post-mortem confirmed cases. *Brain* 139 (4), 1211–1225.
- Hester, R.L., Kinsella, G.J., Ong, B.E.N., 2004. Effect of age on forward and backward span tasks. *J. Int. Neuropsychol. Soc.* 10 (4), 475–481.
- Hutton, C., Draganski, B., Ashburner, J., Weiskopf, N., 2009. A comparison between voxel-based cortical thickness and voxel-based morphometry in normal aging. *NeuroImage* 48, 371–380.
- Jernigan, T.L., Archibald, S.L., Fennema-Notestine, C., Gamst, A.C., Stout, J.C., Bonner, J., Hesselink, J.R., 2001. Effects of age on tissues and regions of the cerebrum and cerebellum. *Neurobiol. Aging* 22 (4), 581–594.
- Koedam, E.L., Lehmann, M., van der Flier, W.M., Scheltens, P., Pijnenburg, Y.A.L., Fox, N., Barkhof, F., Wattjes, M.P., 2011. Visual assessment of posterior atrophy development of a MRI rating scale. *Eur. Radiol.* 21 (12), 2618–2625.
- Korf, E.S., Wahlund, L.O., Visser, P.J., Scheltens, P., 2004. Medial temporal lobe atrophy on MRI predicts dementia in patients with mild cognitive impairment. *Neurology* 63, 94–100.
- Kurth, F., Gaser, C., Luders, E., 2015. A 12-step user guide for analyzing voxel-wise gray matter asymmetries in statistical parametric mapping (SPM). *Nat. Protoc.* 10 (2), 293–304. <https://doi.org/10.1038/nprot.2015.014>.
- Lehner, J., Guér, R., Guttmann, G., Maly, J., Gleiß, A., Auff, E., Dal-Bianco, P., 2005. Annual conversion to Alzheimer disease among patients with memory complaints attending an outpatient memory clinic: the influence of amnesic mild cognitive impairment and the predictive value of neuropsychological testing. *Wien. Klin. Wochenschr.* 117, 629–635.
- MacPherson, S.E., Phillips, L.H., Della Sala, S., 2002. Age, executive function and social decision making: a dorsolateral prefrontal theory of cognitive aging. *Psychol. Aging* 17 (4), 598.
- McDonald, C.R., McEvoy, L.K., Gharapetian, L., Fennema-Notestine, C., Hagler, D.J., Holland, D., Koyama, A., Brewer, J.B., Dale, A.M., Alzheimer's Disease Neuroimaging Initiative, 2009. Regional rates of neocortical atrophy from normal aging to early Alzheimer disease. *Neurology* 73 (6), 457–465.
- McKhann, G., Drachman, D., Folstein, M., Katzman, R., Price, D., Stadlan, E.M., 1984. Clinical diagnosis of Alzheimer's disease Report of the NINCDS-ADRDA Work Group* under the auspices of Department of Health and Human Services Task Force on Alzheimer's Disease. *Neurology* 34 (7), 939.
- Mechelli, A., Price, C.J., Friston, K.J., Ashburner, J., 2005. Voxel-based morphometry of the human brain: methods and applications. *Curr. Med. Imaging Rev.* 1 (2), 105–113.
- Möller, C., van der Flier, W.M., Versteeg, A., Benedictus, M.R., Wattjes, M.P., Koedam, E.L., Scheltens, P., Barkhof, F., Vrenken, H., 2014. Quantitative regional validation of the visual rating scale for posterior cortical atrophy. *Eur. Radiol.* 24 (2), 397–404.
- Nordberg, A., Rinne, J.O., Kadir, A., Långström, B., 2010. The use of PET in Alzheimer disease. *Nat. Rev. Neurol.* 6 (2), 78.
- Phillips, L.H., Della Sala, S., 1998. Aging, intelligence, and anatomical segregation in the frontal lobes. *Learn. Individ. Differ.* 10 (3), 217–243.
- Proust-Lima, C., Amieva, H., Dartigues, J.F., Jacqmin-Gadda, H., 2006. Sensitivity of four psychometric tests to measure cognitive changes in brain aging-population-based studies. *Am. J. Epidemiol.* 165 (3), 344–350.
- Raz, N., Gunning, F.M., Head, D., Dupuis, J.H., McQuain, J., Briggs, S.D., Loken, W.J., Thornton, A.E., Acker, J.D., 1997. Selective aging of the human cerebral cortex observed in vivo: differential vulnerability of the prefrontal gray matter. *Cerebral Cortex* (New York, NY: 1991) 7 (3), 268–282.
- Raz, N., Gunning-Dixon, F.M., Head, D., Dupuis, J.H., Acker, J.D., 1998. Neuroanatomical correlates of cognitive aging: evidence from structural magnetic resonance imaging. *Neuropsychology* 12 (1), 95.
- Roiser, J.P., Linden, D.E., Gorno-Tempini, M.L., Moran, R.J., Dickerson, B.C., Grafton, S.T., 2016. Minimum statistical standards for submissions to NeuroImage: Clinical. *NeuroImage Clin.* 12, 1045–1047.
- Rypma, B., Prabhakaran, V., Desmond, J.E., Gabrieli, J.D., 2001. Age differences in prefrontal cortical activity in working memory. *Psychol. Aging* 16 (3), 371.
- Saarela, C., Jouts, J., Laine, M., Parkkola, R., Rinne, J.O., Karrasch, M., 2017. Regional gray matter correlates of memory for emotion-laden words in middle-aged and older adults: a voxel-based morphometry study. *PLoS One* 12 (8), e0182541.
- Scheltens, P.H., 2001. Structural neuroimaging of Alzheimer's disease and other dementias. *Aging (Milano)* 13, 203–209.
- Scheltens, P.H., van de Pol, L.A., 2012. Impact commentaries. Atrophy of medial temporal lobes on MRI in “probable” Alzheimer's disease and normal ageing: diagnostic value and neuropsychological correlates. *J. Neurol. Neurosurg. Psychiatry* 83, 1038–1040.
- Scheltens, P., Launer, L., Barkhof, F., Weinstein, H.C., van Gool, W.A., 1995. Visual assessment of medial temporal lobe atrophy on magnetic resonance imaging: Interobserver reliability. *J. Neurol.* 242 (9), 557–560.
- Schoonenboom, N.S., van der Flier, W.M., Blankensteijn, M.A., Bouwman, F.H., Van Kamp, G.J., Barkhof, F., Scheltens, P., 2008. CSF and MRI markers independently contribute to the diagnosis of Alzheimer's disease. *Neurobiol. Aging* 29 (5), 669–675.
- Shen, Q., Loewenstein, D.A., Potter, E., Zhao, W., Appel, J., Greig, M.T., Raj, A., Acevedo, A., Schofield, E., Barker, W., Wu, Y., Potter, H., Duara, R., 2011. Volumetric and visual rating of magnetic resonance imaging scans in the diagnosis of amnesic mild cognitive impairment and Alzheimer's disease. *Alzheimer's Dementia* 7 (4), e101–e108.
- Sowell, E.R., Peterson, B.S., Thompson, P.M., Welcome, S.E., Henkenius, A.L., Toga, A.W., 2003. Mapping cortical change across the human life span. *Nat. Neurosci.* 6 (3), 309.
- Spieler, D.H., Balota, D.A., Faust, M.E., 1996. Stroop performance in healthy younger and older adults and in individuals with dementia of the Alzheimer's type. *J. Exp. Psychol. Hum. Percept. Perform.* 22 (2), 461.
- Steffener, J., Barulli, D., Habeck, C., O'Shea, D., Razlighi, Q., Stern, Y., 2014. The role of education and verbal abilities in altering the effect of age-related gray matter differences on cognition. *PLoS One* 9 (3), e91196.
- Stern, Y., 2012. Cognitive reserve in ageing and Alzheimer's disease. *Lancet Neurol.* 11 (11), 1006–1012.
- Stroop, J.R., 1935. Studies of interference in serial verbal reactions. *J. Exp. Psychol.* 18, 643–662.
- Tabert, M.H., Manly, J.J., Liu, X., Pelton, G.H., Rosenblum, S., Jacobs, M., Zamora, D., Goodkind, M., Bell, K., Stern, Y., Devanand, D.P., 2006. Neuropsychological prediction of conversion to Alzheimer disease in patients with mild cognitive impairment. *Arch. Gen. Psychiatry* 63 (8), 916–924.
- Terribili, D., Schaufelberger, M.S., Duran, F.L., Zanetti, M.V., Curiati, P.K., Menezes, P.R., Scazufca, M., Amaro, Jr.E., Leite, C.C., Busatto, G.F., 2011. Age-related gray matter volume changes in the brain during non-elderly adulthood. *Neurobiol. Aging* 32, 354–368.
- Tierney, M.C., Yao, C., Kiss, A., McDowell, I., 2005. Neuropsychological tests accurately

- predict incident Alzheimer disease after 5 and 10 years. *Neurology* 64 (11), 1853–1859.
- Tisserand, D.J., Visser, P.J., Van Boxtel, M.P.J., Jolles, J., 2000. The relation between global and limbic brain volumes on MRI and cognitive performance in healthy individuals across the age range. *Neurobiol. Aging* 21 (4), 569–576.
- Tisserand, D.J., Pruessner, J.C., Arigita, E.J.S., van Boxtel, M.P., Evans, A.C., Jolles, J., Uylings, H.B., 2002. Regional frontal cortical volumes decrease differentially in aging: an MRI study to compare volumetric approaches and voxel-based morphometry. *NeuroImage* 17 (2), 657–669.
- Tisserand, D.J., Van Boxtel, M.P., Pruessner, J.C., Hofman, P., Evans, A.C., Jolles, J., 2004. A voxel-based morphometric study to determine individual differences in gray matter density associated with age and cognitive change over time. *Cereb. Cortex* 14 (9), 966–973.
- Tzourio-Mazoyer, N., Landeau, B., Papathanassiou, D., Crivello, F., Etard, O., Delcroix, N., Mazoyer, B., Joliet, M., 2002. Automated anatomical labeling of activations in SPM using a macroscopic anatomical parcellation of the MNI MRI single-subject brain. *Neuroimage* 15, 273–289.
- van de Pol, L.A., Hensel, A., Barkhof, F., Gertz, H.J., Scheltens, P., van der Flier, W.M., 2006a. Hippocampal atrophy in Alzheimer disease: age matters. *Neurology* 66, 236–238.
- van de Pol, L.A., Hensel, A., van der Flier, W.M., Visser, P.J., Pijnenburg, Y.A., Barkhof, F., Scheltens, P., 2006b. Hippocampal atrophy on MRI in frontotemporal lobar degeneration and Alzheimer's disease. *J. Neurol. Neurosurg. Psychiatry* 77 (4), 439–442.
- Van Der Werf, Y.D., Tisserand, D.J., Visser, P.J., Hofman, P.A., Vuurman, E., Uylings, H.B., Jolles, J., 2001. Thalamic volume predicts performance on tests of cognitive speed and decreases in healthy aging: a magnetic resonance imaging-based volumetric analysis. *Cogn. Brain Res.* 11 (3), 377–385.
- Van Petten, C., Plante, E., Davidson, P.S., Kuo, T.Y., Bajuscak, L., Glisky, E.L., 2004. Memory and executive function in older adults: relationships with temporal and prefrontal gray matter volumes and white matter hyperintensities. *Neuropsychologia* 42 (10), 1313–1335.
- Verhoeff, N.P., Wilson, A.A., Takeshita, S., Trop, L., 2004. In-vivo imaging of Alzheimer disease B-amyloid with [¹¹C] SB-13 PET. *Am. J. Geriatr. Psychiatry* 12 (6), 584.
- Walhovd, K.B., Fjell, A.M., Reinvang, I., Lundervold, A., Dale, A.M., Eilertsen, D.E., Quinn, B.T., Salat, D., Makris, N., Fischl, B., 2005. Effects of age on volumes of cortex, white matter and subcortical structures. *Neurobiol. Aging* 26 (9), 1261–1270.
- Wechsler, D., 1945. A standardized memory scale for clinical use. *J. Psychol.* 19 (1), 87–95.
- Witte, A.V., Savli, M., Holik, A., Kasper, S., Lanzenberger, R., 2010. Regional sex differences in grey matter volume are associated with sex hormones in the young adult human brain. *NeuroImage* 49 (2), 1205–1212.
- Ylikoski, R., Salonen, O., Mäntylä, R., Ylikoski, A., Keskivaara, P., Leskelä, M., Erkinjuntti, T., 2000. Hippocampal and temporal lobe atrophy and age-related decline in memory. *Acta Neurol. Scand.* 101 (4), 273–278.