

Contents lists available at [ScienceDirect](https://www.sciencedirect.com)

International Journal of Surgery Case Reports

journal homepage: www.casereports.com

Penile ring entrapment and strangulation: A case report at Kampala International University Teaching Hospital in Western Uganda

Lauben Amagara Kyomukama^{a,*}, Robinson Ssebuufu^a, Shaban Abdullah Wani^a,
Musa Abbas Waziri^{a,b}, Herman Lule^a

^a Department of Surgery, Kampala International University Teaching Hospital, P.O. Box 71, Bushenyi, Uganda

^b Department of Surgery, Muhammad Shuwa Memorial Hospital, Maiduguri, Nigeria

ARTICLE INFO

Article history:

Received 27 July 2020

Received in revised form

10 September 2020

Accepted 10 September 2020

Available online 19 September 2020

Keywords:

Penile ring-entrapment

Penile-strangulation

Erectile-dysfunction

Masturbation

Case-report

ABSTRACT

INTRODUCTION: Penile ring entrapment during self-sexual satisfaction is one of the rare cases in general and urologic surgery. When the penile shaft is entrapped in a metal ring, one risks possible complete loss of distal penis to strangulation and gangrene. We present management of a case of entrapped penile ring with penile strangulation in resource limited set up amidst absence of management guidelines. The case has been reported in line with SCARE criteria (1).

PRESENTATION OF CASE: A 43-year-old male presented after 72 h of pilot ball bearing ring penile insertion for sustainability of an erection, with 24 -h history of painful penile swelling and acute urine retention. The patient had history of using recreational drugs and erectile dysfunction with evidence of high-grade penile injuries at presentation. The ring was cut using electrically powered angled grinder, with full penile recovery on conservative management in eight months of follow up.

DISCUSSION: Entrapped penile ring is clinically diagnosed but establishing incentive of insertion is difficult just like identifying a correct technique to remove it. Entrapped ring obstructs blood and lymphatic flow leading to oedema and ischaemia with associated penile tissue injuries. High grade penile injuries or penile amputation are sequels of delayed ring removal and good outcomes are tangible through timely multidisciplinary approach.

CONCLUSION: Eroticism and erectile dysfunctions are known incentive to using penile rings to sustain erection. Delayed ring removal results in its entrapment and penile strangulation and related complications. Timely removal of ring requires multidisciplinary approach and local management protocols.

© 2020 The Author(s). Published by Elsevier Ltd on behalf of IJS Publishing Group Ltd. This is an open access article under the CC BY-NC-ND license (<http://creativecommons.org/licenses/by-nc-nd/4.0/>).

1. Introduction

Penile ring entrapment is when a ring previously inserted onto penis is left for extended period of recommended time resulting in oedema, urethra fistula, gangrene and complete loss of distal penis leading to penile strangulation. Penile strangulation by a constricting entrapped ring is a rare urological emergence that present immerse challenges to a general surgeon in resource limited centres globally [2]. The motivation of inserting a ring or any object on a penis in adult males has been erotically associated in management of erectile dysfunction [3].

Non-metallic or metallic object are used as rings and the duration of insertion seem directly proportional to the complications irrespective of location of the ring on penis [3]. Since the first

reported case in 1755, the management of entrapped penile ring is challenging [4].

We present a case of penile ring entrapment with strangulation using ball bearing pilot rings and how it was managed in a resource limited hospital after 8 months of follow up and has been reported in line with SCARE criteria [1].

2. Presentation of case

A 43-year-old male presented at casualty unit with swollen penis for 72 h and failure to pass urine for 24 h, following insertion of the metallic ring and failure to remove it. The patient was a married addict to pornography and recreation drugs (kharth), smoked 30 pack years of cigarette and drank 60 units of crude alcohol weekly. He denied use of erectile enhancing drugs or sexual intercourse with spouse in 4 days prior to incident and had no comorbidities of diabetes mellitus, hypertension or mental illness.

On physical Examination, he had normal vital signs and graded his pain as unbearable. Locally, had a circumcised penis with an entrapped copper like ring distal to the scrotum, grossly oedema-

* Corresponding author at: Department of Surgery, Kampala International University Teaching Hospital, P.O. Box 71, Bushenyi, Uganda.

E-mail addresses: kyomukamaamagaralauben@kiu.ac.ug (L.A. Kyomukama), rsebuufu@gmail.com (R. Ssebuufu), abdallah.shaban@kiu.ac.ug (S.A. Wani), abbas.waziri@studwc.kiu.ac.ug (M.A. Waziri), lule.herman@kiu.ac.ug (H. Lule).

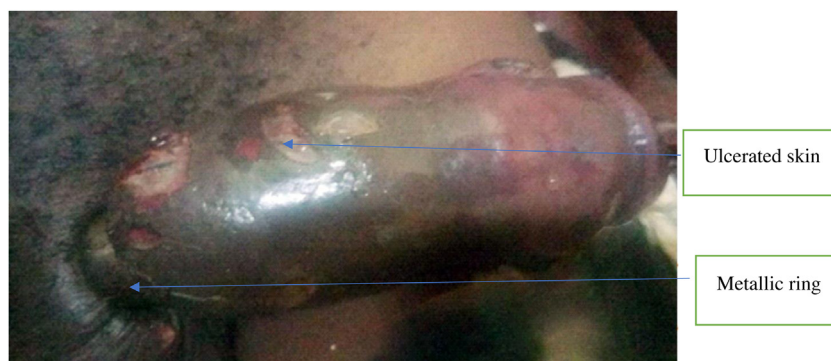

Fig. 1. Showing penile ring entrapment.

Attachment Images of Penile ring entrapment and strangulation case.



Fig. 2. Showing the angle grinder metal cutter with its accessories.

tous penile shaft with serosanguinous fluid discharge from mottled penile shaft skin lesions with areas of necrosis (Fig. 1). Self-inflicted needle pricks and cuts to relieve the swelling were noted. The glans penis was cold, erythematous with reduced distal sensation and capillary refill of more than two seconds. There was severe tenderness proximal to the ring and a deepening discharging cut wound around the ring. The hypogastrum was distended, tender and dull to percussion.

The patient was clinically diagnosed of penile ring entrapment with strangulation, high-grade penile shaft skin injuries and acute urine retention. The pus swab culture and sensitivity showed mixed bacterial infection sensitive to cephalosporin antibiotics. The patient was blood group O rhesus positive with normal glycaemic levels and hemogram on admission. Our facility did not have flexible cystoscopy to evaluate for urethral injuries.

The patient received emergence care within 20 min and definitive intervention in 12 h of arrival to the facility. In order to relieve the acute urine retention, we performed supra-pubic cystostomy under local anaesthesia and sterile conditions inserting a two-way F20 Foleys catheter and drained 2500 mL of clear urine instantly. We attempted to slide the ring off with continuous compression and lubrication while protecting the underlying skin with a tongue blade but the ring was tight to penile shaft. Finally, we cut the ring using an electrically powered angle grinder saw of Einhell 2015/10/EB050252 brand [5] and expander circlip angled pliers

from the hospital's engineering department (Fig. 2). The patient was counselled and consented to the procedure and asked to report any heat generated during cutting of the ring. The procedure was kept clean with a moist saline gauze pad under the penis, an elastic rubber was firmly wrapped over penile shaft and a tongue depressor was pushed under the ring to protect the tissue from cut and excessive heat. Saline irrigation was used to cool the machine and avoid thermal injuries to the penile tissue. Whenever the patient reported heat, the procedure was interrupted and cold damp gauze applied to the penile shaft to cool before resuming. Two interruptions were made and no anaesthetic drugs were used. The ring was cut at 180° and used internal circlip expander pliers to separate it off the penile shaft. The parts of the ring were reassembled to obtain the internal diameter, width and its thickness (Fig. 3). The ring was 2 mm thick with internal diameter of 2.5 cm and made of hard metal. Fasciotomy (Corporotomy) was performed through bilateral penile shaft longitudinal incisions distal to the ring-mark up to the corona (Fig. 4) to prevent further tissue ischaemia and necrosis to avert the pending penile amputation.

The patient had prolonged hospital stay of 90 days for local wound care as he could not afford cost of plastic surgery and was followed up in surgical outpatient clinic for eight months. We did serial surgical debridement, regular dressing and broad spectral antibiotic guided by pus swab culture and sensitivity. Nutritional, psychological and physiotherapeutic care was provided through




Fig. 3. Showing the ring piece after it was cut and reassembled to estimate diameter.

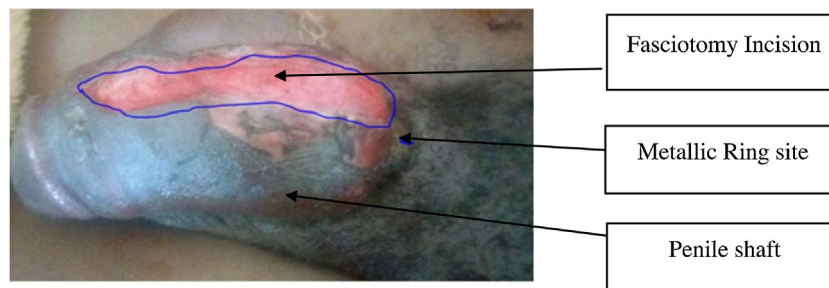


Fig. 4. showing skin release incision 12 h after it was made.

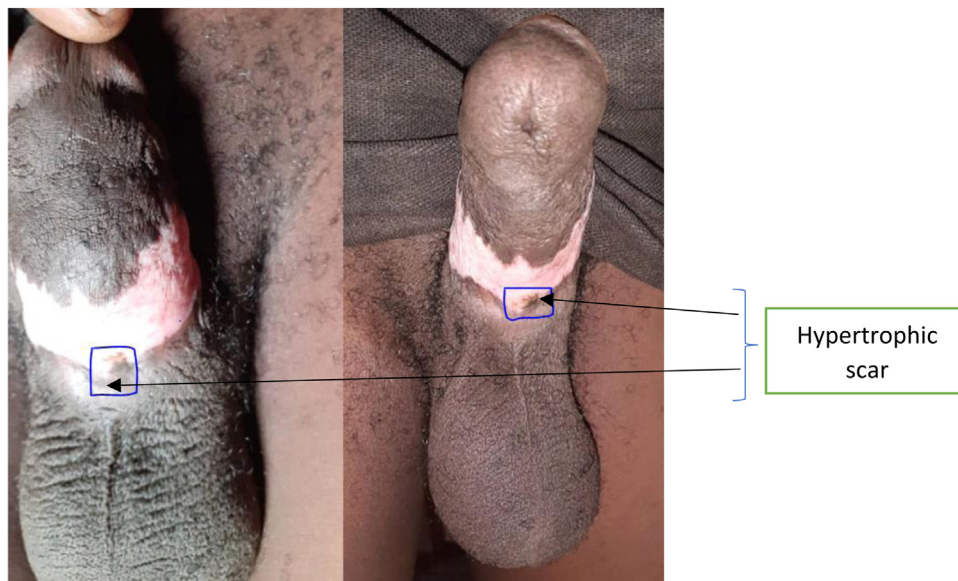


Fig. 5. Showing uneventful recovery with minimal ventral penile shaft scar after 8 months.

consultations. He developed early morning painful erections in the second week and local wound sepsis but recovered fully with minimal ventral phallus hypertrophic scarring (Fig. 5).

3. Case discussion

Penile ring entrapment is a rare urological emergency that can complicate with edema, strangulation, ischemia, gangrene, urethral fistula and distal penile amputation [6], particularly when it stays for more than 30 min [3]. Whilst our case presented late after 72 h of failed self-attempts to remove the ring, evidence show

that the stigma associated with erectile dysfunction and masturbation result in delayed presentation in up to 92.3 % of cases [7]. Our patient presented with gloss penile oedema, mottling of penile shaft skin and impaired penile sensation, typically a grade II injury of the Bhat et al. classification [8] but a high grade injury as per the Silberstein et al. [7] modification; since the patient required serial debridement although there was no clinical evidence of urethral fistula.

Whereas the main motive of inserting a penile ring has been linked to eroticism and addressing erectile dysfunction to sustain an erection by impairing venous return [3,9,7]; on the other hand,

male psychiatric patients use penile constrictors due to mental disorders. Although males younger than 50 years, like for this case, carry only 12 % risk of erectile dysfunction; low self-esteem, use of recreational drugs and delayed hospital consultation increases their risk of penile ring entrapment [10] when used.

To date, there seems to be no consensus guidelines on removing entrapped penile constrictors, but rather a variable approach depending on the material, duration and availability of resources [11,12]. Different materials such as rubber bands, hard metals and bottlenecks have been used [3], however the use of non-metallic objects is twice metallic [11]. In addition, 78 % of those who use non-metallic rings sustain high grade injuries as opposed to 22 % of those who use metallic constrictors [7,13], even though overall, most resulting injuries are low grade. Whereas previous authors have documented success of compression, lubrication and fasciotomies or both in extrication of penile rings [11,14], these can fail in presence of excessive penile oedema as was for our patient, yet failure to execute other novel approaches [15] has led to penile amputation [14]. Trivedi et al. [16] emphasises the diversity in clinical presentation and management approach resulting from penile constriction devices. Thus judgement on case-by-case basis has improved the surgical outcome of these patients [11,17].

The primary goal is to restore early arterial inflow, venous and lymphatic drainage to prevent further tissue damage. In keeping with existing literature [7,10,13,18], we used a powered electric gadget to remove the entrapped metal ring. Because we worked on already friable tissue, our patient developed minimal fibrotic scarring but had normal voiding at 2 weeks and 8 months follow up with no urethra cutaneous fistulae. Whether the reduced penile erection at 8 months preceded or followed trauma could not be validated due to social desirability bias associated with verbal autopsies.

4. Conclusion

In a nutshell, penile ring entrapment presents treatment challenges in absence of a local treatment protocol and designated instruments in resource limited setting. Use of electrically powered angled grinder to cut hard metal rings is a viable option in our experience and we recommend its availability in hospital theatres. For guidelines, we propose a ring removal approach based on the tightness of the ring and distal damage by cutting and fasciotomy should be performed whenever distal penile tissue oedema is present to prevent ischaemia as you mobilise resources and skilled expert to remove.

Long-term follow up with clear erectile dysfunction assessment tools, cognitive assessment, psychological counselling on recreational drug use are key for complication while community engagement and health education in this case are important preventive measures. The urological surgical societies should customise equipment and draft a penile ring entrapment management protocol for inclusion in standard text books as a chapter.

Conflicts of interest

All authors declare no conflict of interest.

Funding

This case report received no specific grant from any funding agency in the public, commercial or not-for-profit sectors.

Ethical approval

This case report was approved by the Kampala International University Teaching Hospital research committee for publication.

Consent

Content of the case and intention to publish them was explained to the patient and in presence of his spouse on his request. The use of images and pictures with their significance was explained and informed consent was obtained, so long as the identity was kept confidential and anonymous. The signed consent is available on request.

Author contribution

Lauben Amagara Kyomukama, Corresponding Author, Guarantor, Conceptualisation, Methodology, Software, Data Curation, writing-original draft preparation, administration, Resources, & Investigation.

Ssebuufu Robinson; Guarantor, Visualization, Validation, software, writing Reviewing and editing, **Shaban Wani Abdullah**; Supervision & Validation, **Lule Herman**; Writing Reviewing and editing, Software & Validation, **Musa Abbas Waziri**; Data curation & Visualization.

Other contributors are;

Husnain Haider, David Wachaya, Jorge Soria Lao and Christian Oppong for the technical support in care of the case and Supervision of the author.

Registration of research studies

- 1 Name of the registry: **Not applicable**
- 2 Unique identifying number or registration ID: **Not applicable**
- 3 Hyperlink to your specific registration (must be publicly accessible and will be checked):

Guarantor

- 1 Lauben Amagara Kyomukama
- 2 Ssebuufu Robinson

Acknowledgements

We are grateful to staff in department of Surgery, Kampala International University Teaching Hospital who participated in care of this patient to mention but not limited to; Husnain Haider¹, David Wachaya¹, Jorge Soria Lao¹ and Christian oppong³ for the surgical expertise in managing this case.

References

- [1] R.A. Agha, M.R. Borrelli, R. Farwana, K. Koshy, A.J. Fowler, D.P. Orgill, et al., The SCARE 2018 statement: updating consensus Surgical Case Report (SCARE) guidelines, *Int. J. Surg.* 60 (October) (2018) 132–136, <http://dx.doi.org/10.1016/j.ijsu.2018.10.028> [Internet], Available from: .
- [2] I. Singh, M.K. Joshi, M.S. Jaura, Strangulation of Penis by a Ball Bearing Device, 2010, pp. 3793–3797.
- [3] Omar Dawood, Seena Tabibi, Julia Fiuk, A.E.-Z. Neil Patel, Penile ring entrapment – a true urologic emergency: grading, approach, and management, *Urol. Ann.* 12 (2020) 15–18 [Internet], Available from: <http://ovidsp.ovid.com/ovidweb.cgi?T=JS&PAGE=reference&D=emex&NEWS=N&AN=613823925>.
- [4] O. Ivanovski, O. Stankov, M. Kuzmanoski, S. Saidi, S. Banev, V. Filipovski, et al., Penile Strangulation: Two Case Reports and Review of, 2007, pp. 1775–1780.
- [5] Tools HP, Power Tools 2020, 2020.
- [6] N.S. Williams, in: N.S. Williams (Ed.), *Bailey & Love's Short Practice of Surgery*, 27th ed., 2020.

- [7] J. Silberstein, J. Grabowski, C. Lakin, I. Goldstein, Penile Constriction Devices: Case Report, Review of the Literature, and Recommendations for Extrication, 2008, pp. 1747–1757.
- [8] G. Bhat, Penile entrapment: a case where innovation is the need of the hour, *Acta Med. Int.* 5 (2) (2018) 90.
- [9] A. Chennamsetty, D. Wenzler, M. Fischer, Removal of a penile constriction device with a large orthopedic pin cutter, *Case Rep. Urol.* 2014 (2014) 1–3.
- [10] Iraklis C. Mitsogiannis, Nikolaos Kostakopoulos, E.K. Lazaros Lazarou, Case report: a case of penile strangulation after placement of metallic rings, *Urol. Ann.* 30 (2018), A106. [Internet], Available from: www.urologyannals.com.
- [11] L. Koifman, D. Hampl, M.I. Silva, P.G.A. Pessoa, A.A. Ornellas, R. Barros, Treatment options and outcomes of penile constriction devices, *Int. Braz. J. Urol.* 45 (2) (2019) 384–391.
- [12] A. Fhima, N. Lahouel, IN PRACTICE Successful Removal of a Penile Constriction Wedding Ring in a Rural Area, 106, 2016, pp. 1088–1089 (11).
- [13] D. Sarkar, S. Gupta, K. Maiti, P. Jain, D.K. Pal, Penile Strangulation by Different Objects and Its Removal by the Modified String Method: Management of Four Cases With Review of Literature, 2019, pp. 1–5.
- [14] J.K. Saroj, A. Ahmad, A. Sachan, G. Yadav, Penile strangulation due to metallic ring: a surgical emergency, *Int. Surg. J.* 6 (11) (2019) 4160.
- [15] D.J. Katz, W. Chin, S. Appu, M. Harper, F. Vukasin, Y.K. Tay, et al., Novel extraction technique to remove a penile constriction device, *J. Sex Med.* 9 (3) (2012) 937–940.
- [16] S. Trivedi, A. Attam, A. Kerketa, N. Daruka, B. Behre, A. Agrawal, et al., Penile incarceration with metallic foreign bodies: management and review of literature, *Curr. Urol.* 7 (1) (2013) 45–50.
- [17] P.K. Saha, S.M. Alam, A.N. Amin, K.C. Ghosh, H. Al-Asad, Surgical outcome for treating penile strangulation by heavy metallic ring, *J. Surg. Sci.* 17 (2) (2019) 96–98.
- [18] N.H. Patel, A. Schulman, J. Bloom, N. Uppaluri, M. Iorga, S. Parikh, et al., Penile and Scrotal Strangulation Due to Metal Rings: Case Reports and a Case Report Penile and Scrotal Strangulation Due to Metal Rings: Case Reports and a Review of the Literature, 2019 (January).

Open Access

This article is published Open Access at [sciencedirect.com](https://www.sciencedirect.com). It is distributed under the [IJSCR Supplemental terms and conditions](#), which permits unrestricted non commercial use, distribution, and reproduction in any medium, provided the original authors and source are credited.