



Antizyme inhibitor 2 (AZIN2) associates with better prognosis of head and neck minor salivary gland adenoid cystic carcinoma

HANNA HÄMETOJA,^{1,2} LEIF C. ANDERSSON,¹ ANTTI MÄKITIE,^{3,4,5} LEIF BÄCK,³
JAANA HAGSTRÖM^{1,2,6*} and CAJ HAGLUND^{6,7*}

¹Department of Pathology, Helsinki, Finland; ²Department of Oral Pathology and Radiology, University of Turku, and Turku University Hospital, Turku, Finland; ³Department of Otorhinolaryngology – Head and Neck Surgery, University of Helsinki and Helsinki University Hospital, Helsinki, Finland; ⁴Division of Ear, Nose and Throat Diseases, Department of Clinical Sciences, Intervention and Technology, Karolinska Institutet and Karolinska University Hospital, Stockholm, Sweden; ⁵Research Program in Systems Oncology, Faculty of Medicine, University of Helsinki, Helsinki, Finland; ⁶Research Programs Unit, Translational Cancer Biology Program, University of Helsinki, Helsinki, Finland; and ⁷Department of Surgery, University of Helsinki and Helsinki University Hospital, Helsinki, Finland

Hämetoja H, Andersson LC, Mäkitie A, Bäck L, Hagström JK, Haglund C. Antizyme inhibitor 2 (AZIN2) associates with better prognosis of head and neck minor salivary gland adenoid cystic carcinoma. *APMIS*. 2021; 129: 503–511.

The key regulator of the polyamine biosynthetic pathway is ornithine decarboxylase (ODC). ODC is activated by antizyme inhibitor 1 (AZIN1) and 2 (AZIN2). AZIN1 and recently AZIN2 have been related to cancer; however, their functions in adenoid cystic carcinoma (ACC) have not been studied. We performed immunohistochemical study on minor salivary and mucous gland ACC tissue samples of patients treated at the Helsinki University Hospital (Helsinki, Finland) during 1974–2012. We scored AZIN1 and 2 immunoexpression in 42 and 45 tumor tissue samples, respectively, and correlated them with clinicopathological factors and survival. Enhanced AZIN2 expression was associated with better survival. In addition, both AZINs were seen more commonly in cribriform and tubular than in solid growth patterns. AZIN1 expression did not correlate with the studied clinicopathological factors. It seems that AZIN2 expression is higher in cancer tissue with secretory functions. In ACC tissue, high AZIN2 expression could be related to well-differentiated histological type which still has a functioning vesicle transportation system. Thus, AZIN2 could be a prognostic factor for better survival of ACC patients.

Key words: Adenoid cystic carcinoma; ornithine decarboxylase; antizyme inhibitor; prognosis; histopathology; pathology of tumours; prognostic markers.

Hanna Hämetoja, Department of Pathology, Haartmaninkatu 3A, 00290 HUS, Helsinki, Finland. e-mail: hanna.haemetoja@helsinki.fi

*Equal contribution.

Among salivary gland malignancies, adenoid cystic carcinoma (ACC) is a common type according to the World Health Organization (WHO) [1]. Sixty percent of ACCs occur in salivary glands although ACC could occur in glandular structures containing areas such as nose, sinonasal cavities, and ear (10%), breast (13%), skin (5%), lung and bronchus (4%), trachea (2%), female genital system (2%), eye (2%), and larynx (1%) [2].

Unfortunately, the long-term prognosis of salivary gland ACC has remained poor despite treatment by radical surgical resection and post-operative radiotherapy [1]. ACC has polymorphic histological growth patterns—cribriform, tubular, solid, and their combinations [1]. Tumors with more than 30% solid pattern are histologically considered as high-grade tumors with more aggressive behavior [1]. Many immunohistochemical studies have sought to reveal immunomarkers to better understand ACC and to predict its behavior. Well-

Received 28 January 2020. Accepted 17 May 2021

known immunomarkers of ACC are CD117 which usually stains inner epithelial tumor cells, and p63 and SMA which stain outer myoepithelial tumor cells [1, 3, 4]. ACC tissue remains histologically interesting due to the presentation of various morphologies, and the same immunomarkers may be differently expressed in ACC tissue. The recently discovered ACC-specific MYB-NFIB fusion gene aids in the diagnosis of the otherwise challenging ACC cases by MYB1-immunohistochemistry [1]. For example, small samples which do not demonstrate typical histology could now be verified by immunohistochemistry [5–7].

Polyamines are organic cations that are essential for cell functions, such as cell growth, proliferation, differentiation, apoptosis, and gating of ion channels [8–10]. Dysregulation of polyamines in the cell has been related to cancer and neurological disorders [8, 10, 11]. The key regulator of the polyamine biosynthetic pathway is ornithine decarboxylase (ODC), the activity of which is mediated by transcriptional, post-transcriptional, translational, and post-translational mechanisms [10]. ODC is down-regulated post-translationally by antizymes (AZs) and up-regulated by antizyme inhibitors (AZINs) [10]. Interaction of AZ1 with ODC prevents the formation of active ODC homodimers and directs ODC to proteosomal degradation independently of ubiquitination [10]. In addition, AZs inhibit the polyamine transporter system at the cell membrane by an unknown mechanism [10]. Activation of ODC is maintained by antizyme inhibitors (AZINs), which are antizyme antagonist proteins that bind AZs with stronger affinity than ODC [9, 10].

In mammals, there are two forms of AZINs, namely AZIN1 [12] and 2 [13]. All cell types express AZIN1, and it is essential for cell survival. Overexpression of AZIN1 stimulates cell proliferation with oncogenic potential in both tumor and non-tumor cells [10, 14–17]. Overexpression of AZIN1 is detected in various malignancies, such as lung and colorectal cancer [18, 19]. Furthermore, AZIN1 may induce cell proliferation by preventing degradation of cell-cycle regulator cyclin D1 by a mechanism that does not include binding to AZ1 [15]. Contrary to the ubiquitous AZIN1, a high amount of AZIN2 expression is seen in terminally differentiated cells, such as type-2 pneumocytes in the lungs, adipocytes, neurons, mast cells, megakaryocytes in normal bone marrow, and acinar cells of sweat glands [20]. AZIN2 has been shown to regulate intracellular vesicle transport and the mast cell degranulation process [9, 21]. Elevated expression of AZIN2 has been detected in neurons affected by Alzheimer's disease [22]. Although the AZIN2 gene is not usually up-regulated in cancer

[10], we have recently shown AZIN2 to act as a prognostic predictor in colorectal cancer [23]. AZINs have not been investigated previously in salivary gland tissue or salivary gland cancer.

The aim of our study was to evaluate the immunexpression of AZIN1 and 2 in a series of head and neck ACCs of minor salivary and mucous gland tissue and to compare the immunexpression with clinical and clinicopathological features and patient survival.

MATERIALS AND METHODS

Patients

The study population consisted of 68 patients with ACC of the minor salivary gland treated at the Helsinki University Hospital (Helsinki, Finland) between the years 1974 and 2012. Our previous study shows the clinical data of this series [24], and Table 1 shows the main patient and tumor characteristics of the current study. To this study, we have included all the patient cases with tumor tissue available. For AZIN1 immunohistochemical staining, we obtained samples from 42 patients including 35 primary tumors and 7 recurrent tumors. For AZIN2 immunohistochemical staining, we obtained samples from 45 patients including 37 primary tumors and 8 recurrent tumors. Tumor staging was performed according to the WHO 2005 and 2017 criteria [1, 25]. The institutional Research Ethics Board approved the study concept (Dnro 31/13/03/02/2010, 01 February 2010).

Immunohistochemistry

For immunohistochemistry, formalin-fixed and paraffin-embedded blocks were freshly cut into 4 µm thick sections. Deparaffinization was performed in xylene and rehydration in graded ethanol and distilled water. The slides were heated in a PreTreatment module (Agilent Dako, Santa Clara, CA, USA) in antibody-specific buffer, pH = 9, for 20 min at 98°C for antigen retrieval. Endogenous peroxidase activity was blocked by incubation of the slides with EnVision Flex peroxidase-blocking reagent for 15 min. The primary antibody was diluted in Dako REAL Antibody Diluent. The primary antibodies used were rabbit polyclonal AZIN1 antibody (1:500) (Biorbyt Ltd, Cambridge, UK) and K3 antibody (1:600) [23]. The incubation times were overnight at +4°C and one hour at room temperature, respectively, followed by detection with Dako REAL Detection System (Peroxidase/DAB+, Rabbit/Mouse, Dako, Glostrup, Denmark). Finally, slides were visualized by Dako REAL DAB+ Chromogen for 10 min and counterstained with hematoxylin (Mayer's Hematoxylin Dako, Glostrup, Denmark). As a positive control, we used skin tissue for AZIN1 and gastric tissue for AZIN2. A slide without primary antibody served as the negative control.

Immunoscore

Two independent researchers (HH and LCA) performed scoring of the slides blinded to the clinical data. We

AZIN2 IN ADENOID CYSTIC CARCINOMA

Table 1. Patient and tumor characterization of the 45 (AZIN2) and 42 (AZIN1) patients with an adenoid cystic carcinoma of minor salivary and mucous glands

| Tumor site | Oral cavity | Oropharynx | Nasopharynx | Paranasal cavities | Larynx | Trachea | Esophagus | Ear |
|----------------------------|-------------|------------|-------------|--------------------|----------|-----------|-----------|----------|
| AZIN2 | | | | | | | | |
| Number of cases (n = 45) | 23 (51.1%) | 3 (6.7%) | 4 (8.9%) | 3 (6.7%) | 2 (4.4%) | 5 (11.1%) | 1 (2.2%) | 4 (8.9%) |
| Age | | | | | | | | |
| <65 years | 16 (35.6%) | 2 (4.4%) | | 3 (6.7%) | 1 (2.2%) | 5 (11.1%) | 1 (2.2%) | 3 (6.7%) |
| >65 years | 7 (15.6%) | 1 (2.2%) | 4 (8.9%) | | 1 (2.2%) | | | 1 (2.2%) |
| Gender | | | | | | | | |
| Male | 12 (26.7%) | | 1 (2.2%) | 2 (4.4%) | | | 1 (2.2%) | 1 (2.2%) |
| Female | 11 (24.4%) | 3 (6.7%) | 3 (6.7%) | 1 (2.2%) | 2 (4.4%) | 5 (11.1%) | | 3 (6.7%) |
| T class | | | | | | | | |
| T1 | 7 (15.6%) | 3 (6.7%) | | | 1 (2.2%) | | | 2 (4.4%) |
| T2 | 4 (8.9%) | | | | | | | |
| T3 | 1 (2.2%) | | 2 (4.4%) | | | | 1 (2.2%) | 1 (2.2%) |
| T4 | 9 (20%) | | 1 (2.2%) | 3 (6.7%) | 1 (2.2%) | | | 1 (2.2%) |
| N/D | 2 (4.4%) | | 1 (2.2%) | | | | | |
| N class | | | | | | | | |
| N0 | 19 (42.2%) | 3 (6.7%) | 3 (6.7%) | 3 (6.7%) | 2 (4.4%) | | | 4 (8.9%) |
| N1 | 1 (2.2%) | | | | | | | |
| N2 | 1 (2.2%) | | | | | | 1 (2.2%) | |
| N/D | 2 (4.4%) | | 1 (2.2%) | | | | | |
| M class | | | | | | | | |
| M0 | 19 (42.2%) | 3 (6.7%) | 3 (6.7%) | 3 (6.7%) | 2 (4.4%) | | 1 (2.2%) | 4 (8.9%) |
| M1 | 2 (4.4%) | | | | | | | |
| N/D | 2 (4.4%) | | 1 (2.2%) | | | | | |
| Stage | | | | | | | | |
| I | 5 (11.1%) | 3 (6.7%) | | | 1 (2.2%) | | | 2 (4.4%) |
| II | 5 (11.1%) | | | | | | | |
| III | 2 (4.4%) | | 2 (4.4%) | | | | 1 (2.2%) | 1 (2.2%) |
| IV | 9 (20%) | | 1 (2.2%) | 3 (6.7%) | 1 (2.2%) | | | 1 (2.2%) |
| N/D | 2 (4.4%) | | 1 (2.2%) | | | | | |
| Neural invasion | | | | | | | | |
| No | 4 (8.9%) | 1 (2.2%) | | | 1 (2.2%) | 3 (6.7%) | 1 (2.2%) | |
| Yes | 16 (35.6%) | 2 (4.4%) | 1 (2.2%) | 2 (4.4%) | | 1 (2.2%) | | 4 (8.9%) |
| N/D | 3 (6.7%) | | 3 (6.7%) | 1 (2.2%) | 1 (2.2%) | 1 (2.2%) | | |
| Primary recurrence | | | | | | | | |
| No | 17 (37.8%) | 3 (6.7%) | 2 (4.4%) | 2 (4.4%) | 2 (4.4%) | 4 (8.9%) | | 2 (4.4%) |
| Yes | 6 (13.3%) | | 2 (4.4%) | 1 (2.2%) | | 1 (2.2%) | | 2 (4.4%) |
| N/D | | | | | | | 1 (2.2%) | |
| Regional recurrence | | | | | | | | |
| No | 20 (44.4%) | 3 (6.7%) | 4 (8.9%) | 3 (6.7%) | 2 (4.4%) | 4 (8.9%) | | 4 (8.9%) |
| Yes | 3 (6.7%) | | | | | 1 (2.2%) | | |
| N/D | | | | | | | 1 (2.2%) | |
| Distant recurrence | | | | | | | | |
| No | 9 (20%) | 2 (4.4%) | 3 (6.7%) | 3 (6.7%) | 1 (2.2%) | 4 (8.9%) | | 4 (8.9%) |
| Yes | 14 (31.1%) | 1 (2.2%) | 1 (2.2%) | | 1 (2.2%) | 1 (2.2%) | 1 (2.2%) | |
| N/D | | | | | | | | |
| IHC | | | | | | | | |
| 0 | 1 (2.2%) | | | 1 (2.2%) | | | | |
| 1 | 4 (8.9%) | | 2 (4.4%) | 2 (4.4%) | 1 (2.2%) | 1 (2.2%) | | 1 (2.2%) |
| 2 | 14 (31.1%) | 2 (4.4%) | 2 (4.4%) | | 1 (2.2%) | 2 (4.4%) | | 3 (6.7%) |
| 3 | 4 (8.9%) | 1 (2.2%) | | | | 2 (4.4%) | 1 (2.2%) | |
| AZIN1 | | | | | | | | |
| Number of cases (n = 42) | 23 (54.8%) | 3 (7.1%) | 2 (4.8%) | 2 (4.8%) | 2 (4.8%) | 5 (11.9%) | 1 (2.4%) | 4 (9.5%) |
| Age | | | | | | | | |
| <65 years | 16 (38.1%) | 2 (4.8%) | 2 (4.8%) | 2 (4.8%) | 1 (2.4%) | 5 (11.9%) | 1 (2.4%) | 3 (7.1%) |
| >65 years | 7 (16.7%) | 1 (2.4%) | | | 1 (2.4%) | | | 1 (2.4%) |
| Gender | | | | | | | | |
| Male | 13 (31%) | | | 2 (4.8%) | | | 1 (2.4%) | 1 (2.4%) |
| Female | 10 (23.8%) | 3 (7.1%) | 2 (4.8%) | | 2 (4.8%) | 5 (11.9%) | | 3 (7.1%) |
| T class | | | | | | | | |
| T1 | 7 (16.7%) | 3 (7.1%) | | | 1 (2.4%) | | | 2 (4.8%) |
| T2 | 4 (9.5%) | | | | | | | |
| T3 | 1 (2.4%) | | 1 (2.4%) | | | | 1 (2.4%) | 1 (2.4%) |
| T4 | 10 (23.8%) | | | 2 (4.8%) | 1 (2.4%) | | | 1 (2.4%) |
| N/D | 1 (2.4%) | | 1 (2.4%) | | | | | |

Table 1 (continued)

| Tumor site | Oral cavity | Oropharynx | Nasopharynx | Paranasal cavities | Larynx | Trachea | Esophagus | Ear |
|---------------------|-------------|------------|-------------|--------------------|----------|----------|-----------|----------|
| N class | | | | | | | | |
| N0 | 20 (47.6%) | 3 (7.1%) | 1 (2.4%) | 2 (4.8%) | 2 (4.8%) | | | 4 (9.5%) |
| N1 | 1 (2.4%) | | | | | | | |
| N2 | 1 (2.4%) | | | | | | 1 (2.4%) | |
| N/D | 1 (2.4%) | | 1 (2.4%) | | | | | |
| M class | | | | | | | | |
| M0 | 20 (47.6%) | 3 (7.1%) | 1 (2.4%) | 2 (4.8%) | 2 (4.8%) | | 1 (2.4%) | 4 (9.5%) |
| M1 | 2 (4.8%) | | | | | | | |
| N/D | 1 (2.4%) | | 1 (2.4%) | | | | | |
| Stage | | | | | | | | |
| I | 5 (11.9%) | 3 (7.1%) | | | 1 (2.4%) | | | 2 (4.8%) |
| II | 5 (11.9%) | | | | | | | |
| III | 2 (4.8%) | | 1 (2.4%) | | | | 1 (2.4%) | 1 (2.4%) |
| IV | 10 (23.8%) | | | 2 (4.8%) | 1 (2.4%) | | | 1 (2.4%) |
| N/D | 1 (2.4%) | | 1 (2.4%) | | | | | |
| Neural invasion | | | | | | | | |
| No | 4 (9.5%) | 1 (2.4%) | | | 1 (2.4%) | 3 (7.1%) | 1 (2.4%) | |
| Yes | 17 (40.5%) | 2 (4.8%) | | 1 (2.4%) | | 1 (2.4%) | | 4 (9.5%) |
| N/D | 2 (4.8%) | | 2 (4.8%) | 1 (2.4%) | 1 (2.4%) | 1 (2.4%) | | |
| Primary recurrence | | | | | | | | |
| No | 17 (40.5%) | 3 (7.1%) | 1 (2.4%) | 1 (2.4%) | 2 (4.8%) | 4 (9.5%) | | 2 (4.8%) |
| Yes | 6 (14.3%) | | 1 (2.4%) | 1 (2.4%) | | 1 (2.4%) | | 2 (4.8%) |
| N/D | | | | | | | 1 (2.4%) | |
| Regional recurrence | | | | | | | | |
| No | 20 (47.6%) | 3 (7.1%) | 2 (4.8%) | 2 (4.8%) | 2 (4.8%) | 4 (9.5%) | | 4 (9.5%) |
| Yes | 3 (7.1%) | | | | | 1 (2.4%) | | |
| N/D | | | | | | | 1 (2.4%) | |
| Distant recurrence | | | | | | | | |
| No | 15 (35.7%) | 2 (4.8%) | 1 (2.4%) | 2 (4.8%) | 1 (2.4%) | 4 (9.5%) | | 4 (9.5%) |
| Yes | 8 (19.0%) | 1 (2.4%) | 1 (2.4%) | | 1 (2.4%) | 1 (2.4%) | 1 (2.4%) | |
| N/D | | | | | | | | |
| IHC | | | | | | | | |
| 0 | 8 (19.0%) | | | 1 (2.4%) | | 3 (7.1%) | | 1 (2.4%) |
| 1 | 10 (23.8%) | 2 (4.8%) | 1 (2.4%) | 1 (2.4%) | 1 (2.4%) | 2 (4.4%) | 1 (2.4%) | |
| 2 | 4 (9.5%) | 1 (2.4%) | 1 (2.4%) | | | | | 3 (7.1%) |
| 3 | 1 (2.4%) | | | | 1 (2.4%) | | | |

Five (11.1%) tracheal tumors were excluded from the TNM classification.

IHC, immunohistochemistry; M, metastasis; N, node; N/D, not done; T, tumor; 0, Negative or very mild; 1, Mild; 2, Moderate; 3, Strong.

analyzed the location of immunoexpression on the different growth patterns (tubular, cribriform, and solid) and estimated the percentage of positively stained tumor cells. For statistical analysis, we grouped the immunoscores as follows: 0 for 0–10% (negative or very mild), 1 for 11–40% (mild), 2 for 41–70% (moderate), and 3 for 71–100% (strong). Grouping was modified from an earlier publication [26]. We immunoscored the normal salivary gland and apocrine gland tissue outside the tumor to validate expression in normal-appearing tissues.

Statistical analysis

For statistical analysis, staining results were grouped into three categories: 0 (negative or very mild), 1 (mild), and 2–3 (moderate to strong). The associations of AZIN1 and 2 immunoexpression with clinicopathological factors were evaluated by chi-square test and Fisher's exact test. Overall survival (OS), disease-specific survival (DSS), and disease-free survival (DFS) between AZIN1 and 2 were analyzed by Kaplan–Meier method and log-rank test. *p*-values below 0.05 were considered statistically significant, and no adjustments were made for multiple testing. Statistical analyses were performed with IBM SPSS Statistics

for Windows, version 25 (IBM Corp., Armonk, NY, USA).

RESULTS

Immunohistochemistry

AZIN2 immunopositivity was cytoplasmic and strongest in the tumors with a tubular growth pattern, followed by cribriform and solid morphology. It seemed that the histologically poorly differentiated tumors (solid growth pattern) showed less immunoexpression. In the normal structures, positivity was seen in mast cells, type-2 pneumocytes, neural structures, acinar structures of the sweat gland, and ductal components of the minor salivary glands. We evaluated AZIN2 immunostaining in 45 tumors; two were scored as negative or very mild, 11 as mild, 24 as moderate, and 8 as strong (Fig. 1).

AZIN1 immunostaining showed cytoplasmic immunopositivity in tumor cells, which was

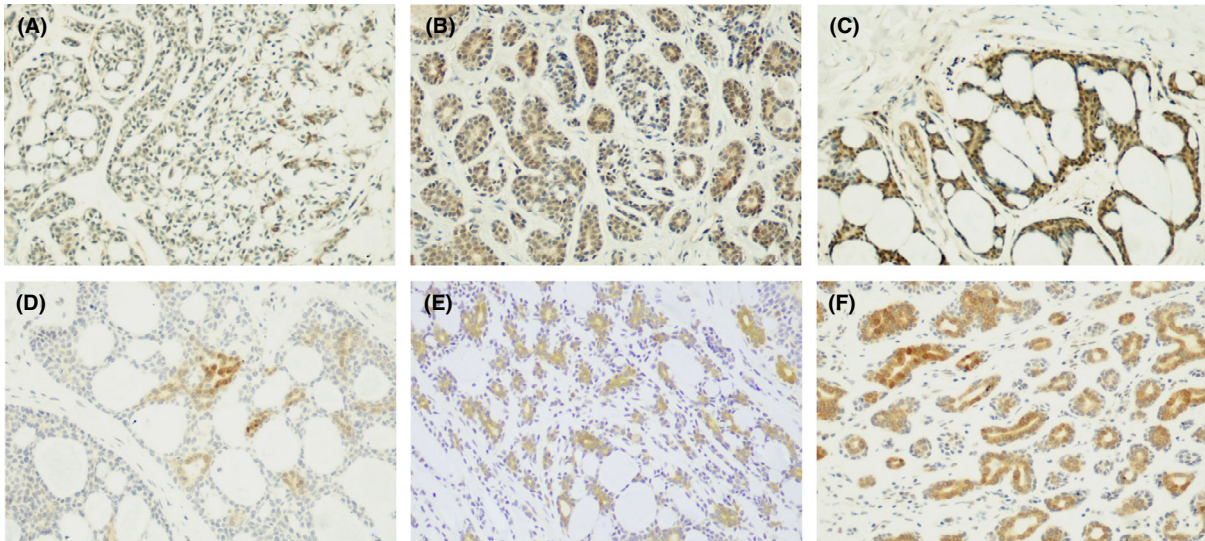


Fig. 1. (A–C) Immunoexpression of AZIN1. (A) Mild immunoexpression of cribriform ACC of the oral cavity; (B) Moderate immunoexpression of tubular ACC of the oral cavity; (C) Strong immunoexpression of cribriform ACC of the ear. (D and E) Immunoexpression of AZIN2. (D) Mild immunoexpression of cribriform ACC of the larynx; (E) Moderate immunoexpression of cribriform ACC of the trachea; (F) Strong immunoexpression of tubular ACC of the trachea. Magnification A–F 200 \times . ACC, Adenoid cystic carcinoma; AZIN, Antizyme inhibitor.

strongest in the cribriform growth pattern, followed by tubular and solid patterns, but with lower rate of total immunopositivity compared to the AZIN2 staining. Similarity to AZIN2 immunostaining, the poorly differentiated tumors (solid growth pattern) showed less immunoexpression. In the normal tissues, AZIN1 immunopositivity was seen in acinar structures of apocrine glands and in myoepithelial cells, in the tubular structures of the sweat gland, in skeletal muscle cells, in hair follicles, and in the germinal centers of lymphoid tissue. We evaluated AZIN1 immunostaining in 42 tumors; 13 were scored as negative or with very mild expression, 18 as mild, 9 as moderate, and two as strong (Fig. 1).

Clinicopathological parameters and survival analysis

In statistical analysis, stronger immunoexpression of AZIN2 was associated with better OS and DSS in Crosstabs and with better DSS and DFS in Kaplan–Meier (Table 2, Figs 2 and 3). In addition, AZIN2 reached significant correlation with T class when we separated T4a and T4b into subclasses ($p = 0.018$), although due to the low number of T4b cases we did not include this to Table 2. AZIN1 immunostaining showed no statistically significant association with clinicopathological parameters (Table 2). Age, gender, T class, N class, M class, tumor stage, neural invasion, or recurrent

tumors did not associate significantly with the immunoexpression of AZIN1 and 2 (Table 2).

DISCUSSION

In this pilot study on AZINs in ACC, we found AZIN2 immunoexpression to associate with better prognosis of patients with minor salivary and mucous gland ACC in the head and neck region.

In the seminal work of AZIN2 in colorectal cancer tissue, Kaprio et al. [23] linked high AZIN2 expression to poor prognosis of colorectal cancer patients. However, the specific molecular events remained unclear. In their study, higher expression of AZIN2 was detected in cancers that originated from proximal colon which have more secreting mucinous histology [23]. AZIN2 may be especially important in secreting cancer tissue due to its role in intracellular vesicle transport [9, 20].

ACC originates from glandular tissues such as salivary, mucous, lacrimal, and mammary glands that mainly function to produce secretion [7, 27]. In our study, the histological samples of ACC consisted mostly of cribriform and tubular types. The cribriform growth pattern presents nests of tumor cells and round spaces filled with basophilic myxoid matrix, whereas tubular form is characterized by bilayered tubules with true lumina [1]. Cribriform

Table 2. The evaluation of the association of antizyme inhibitor (AZIN) 1 and 2 immunoexpression with clinicopathological factors by chi-square test or Fisher's exact test

| | AZIN2 expression (n (%)) | | | | AZIN1 expression (n (%)) | | | |
|---------------------|--------------------------|-----------|--------------------|---------|--------------------------|-----------|--------------------|---------|
| | Negative | Mild | Moderate to Strong | p-Value | Negative | Mild | Moderate to Strong | p-Value |
| Age | | | | | | | | |
| <65 | 2 (100.0) | 9 (81.8) | 24 (75.0) | 1.000 | 12 (92.3) | 14 (77.8) | 6 (54.5) | 0.108 |
| >65 | 0 (0.0) | 2 (18.2) | 8 (25.0) | | 1 (7.7) | 4 (22.2) | 5 (45.5) | |
| Gender | | | | | | | | |
| Male | 2 (100.0) | 4 (36.4) | 11 (34.4) | 0.229 | 6 (46.2) | 7 (38.9) | 4 (36.4) | 0.874 |
| Female | 0 (0.0) | 7 (63.6) | 21 (65.6) | | 7 (53.8) | 11 (61.1) | 7 (63.6) | |
| T class | | | | | | | | |
| T1 | 0 (0.0) | 0 (0.0) | 13 (48.1) | 0.055 | 2 (22.2) | 5 (33.3) | 6 (54.5) | 0.447 |
| T2 | 0 (0.0) | 1 (12.5) | 3 (11.1) | | 2 (22.2) | 2 (13.3) | 0 (0.0) | |
| T3 | 0 (0.0) | 2 (25.0) | 3 (11.1) | | 0 (0.0) | 2 (13.3) | 2 (18.2) | |
| T4 | 2 (100.0) | 5 (62.5) | 8 (29.6) | | 5 (55.6) | 6 (40.0) | 3 (27.3) | |
| N class | | | | | | | | |
| N0 | 2 (100.0) | 8 (100.0) | 24 (88.9) | 1.000 | 9 (100.0) | 13 (86.7) | 10 (90.9) | 0.773 |
| N+ | 0 (0.0) | 0 (0.0) | 3 (11.1) | | 0 (0.0) | 2 (13.3) | 1 (9.1) | |
| M class | | | | | | | | |
| M0 | 2 (100.0) | 8 (100.0) | 25 (92.6) | 1.000 | 9 (100.0) | 14 (93.3) | 10 (90.9) | 1.000 |
| M+ | 0 (0.0) | 0 (0.0) | 2 (7.4) | | 0 (0.0) | 1 (6.7) | 1 (9.1) | |
| Stage | | | | | | | | |
| I | 0 (0.0) | 0 (0.0) | 11 (40.7) | 0.126 | 2 (25.0) | 4 (26.7) | 5 (45.5) | 0.766 |
| II | 0 (0.0) | 1 (12.5) | 4 (14.8) | | 2 (25.0) | 2 (13.3) | 1 (9.1) | |
| III | 0 (0.0) | 2 (25.0) | 4 (14.8) | | 0 (0.0) | 3 (20.0) | 2 (18.2) | |
| IV | 2 (100.0) | 5 (62.5) | 8 (29.6) | | 4 (50.0) | 6 (40.0) | 3 (27.3) | |
| Neural invasion | | | | | | | | |
| No | 0 (0.0) | 2 (22.2) | 8 (30.8) | 1.000 | 3 (25.0) | 6 (37.5) | 1 (14.3) | 0.628 |
| Yes | 1 (100.0) | 7 (77.8) | 18 (69.2) | | 9 (75.0) | 10 (62.5) | 6 (85.7) | |
| Primary recurrence | | | | | | | | |
| No | 1 (50.0) | 6 (54.5) | 24 (77.4) | 0.249 | 10 (76.9) | 12 (70.6) | 8 (72.7) | 1.000 |
| Yes | 1 (50.0) | 5 (45.5) | 7 (22.6) | | 3 (23.1) | 5 (29.4) | 3 (27.3) | |
| Regional recurrence | | | | | | | | |
| No | 2 (100.0) | 10 (90.9) | 28 (90.3) | 1.000 | 11 (84.6) | 15 (88.2) | 11 (100.0) | 0.544 |
| Yes | 0 (0.0) | 1 (9.1) | 3 (9.7) | | 2 (15.4) | 2 (11.8) | 0 (0.0) | |
| Distant recurrence | | | | | | | | |
| No | 1 (50.0) | 5 (45.5) | 23 (71.9) | 0.220 | 8 (61.5) | 13 (72.2) | 8 (72.7) | 0.835 |
| Yes | 1 (50.0) | 6 (54.5) | 9 (28.1) | | 5 (38.5) | 5 (27.8) | 3 (27.3) | |
| OS | | | | | | | | |
| Alive | 0 (0.0) | 2 (18.2) | 21 (65.6) | 0.006 | 6 (46.2) | 10 (55.6) | 7 (63.6) | 0.690 |
| Dead | 2 (100.0) | 9 (81.8) | 11 (34.4) | | 7 (53.8) | 8 (44.4) | 4 (36.4) | |
| DSS | | | | | | | | |
| Alive | 0 (0.0) | 3 (27.3) | 24 (75.0) | 0.004 | 8 (61.5) | 11 (61.1) | 9 (81.8) | 0.500 |
| Dead | 2 (100.0) | 8 (72.7) | 8 (25.0) | | 5 (38.5) | 7 (38.9) | 2 (18.2) | |
| DFS | | | | | | | | |
| No | 0 (0.0) | 3 (27.3) | 17 (53.1) | 0.151 | 7 (53.8) | 8 (44.4) | 6 (54.5) | 0.823 |
| Yes | 2 (100.0) | 8 (72.7) | 15 (46.9) | | 6 (46.2) | 10 (55.6) | 5 (45.5) | |

Total number of cases submitted to immunohistochemistry (IHC) for AZIN2 is 45. Age, gender, distant recurrence, OS, DSS, DFS: IHC = 45/45; TNM and stage: IHC = 37/45, N/D = 8; Neural invasion: IHC = 36/45, N/D = 9; Primary and regional recurrence: IHC = 44/45, N/D = 1. Total number of cases submitted to immunohistochemistry (IHC) for AZIN1 is 42: Age, gender, distant recurrence, OS, DSS, DFS: IHC = 42/42; TNM and stage: IHC = 35/42, N/D = 7; Neural invasion: IHC = 35/45, N/D = 10; Primary and regional recurrence IHC = 41/45, N/D = 4.

DFS, disease-free survival; DSS, disease-specific survival; M, metastasis; N, node; OS, overall survival; T, tumor.

and tubular ACC tissues are reported as highly differentiated as they have secretory functions. In our material, cribriform and tubular tumor tissue showed high expression of AZIN2, which could be related to active vesicle transport in tumor cells. On the other hand, solid ACC consists of sheets of tumor cells without lumen formation and is graded

as poorly differentiated tumor with more aggressive behavior [1]. The solid ACC samples showed no or modest immunoexpression of AZIN2, and it seems that the tumor tissue might have lost the main function of the originating tissue. Overall, histologically it seems that a high amount of AZIN2 expression is beneficial for patients since high

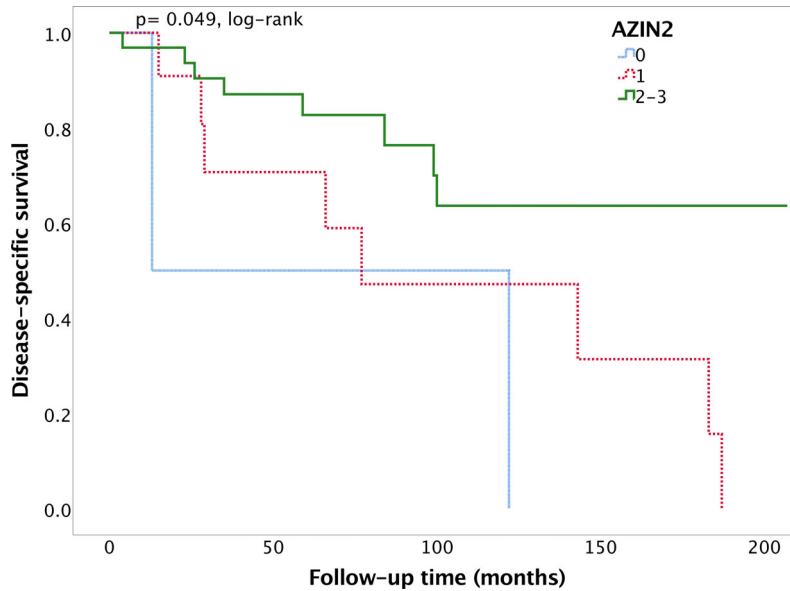


Fig. 2. Disease-specific survival for adenoid cystic carcinoma patients. Kaplan–Meier plot showing better prognosis for tumors with moderate to strong AZIN2 immunopositivity. Total number of cases is 45. 0 as negative or very mild = 2/45; 1 as mild = 11/45; 2–3 as moderate to strong = 32/45.

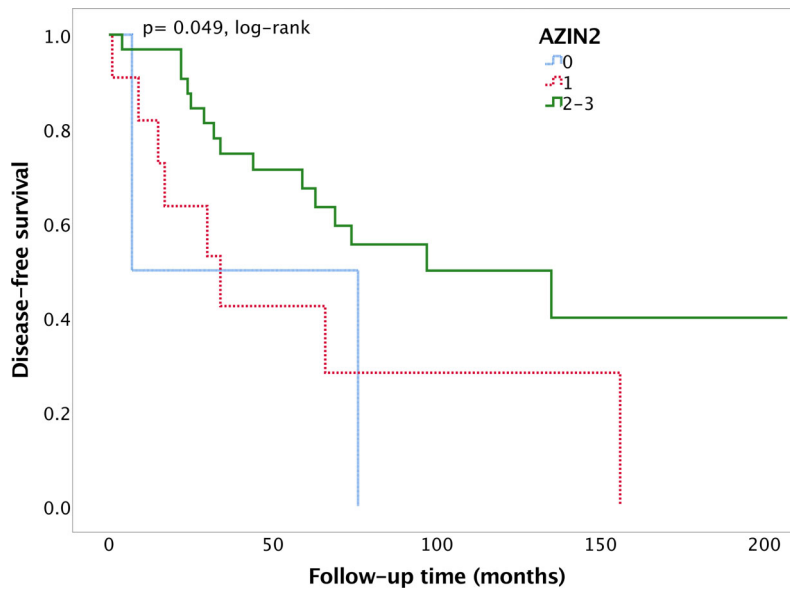


Fig. 3. Disease-free survival for adenoid cystic carcinoma patients. Kaplan–Meier plot showing better prognosis for tumors with moderate to strong AZIN2 immunopositivity. Total number of cases is 45. 0 as negative or very mild = 2/45; 1 as mild = 11/45; 2–3 as moderate to strong = 32/45.

immunoexpression of AZIN2 was related to smaller tumor size and better survival. Nonetheless, further studies are needed to reveal the ultimate functions of AZIN2 in ACC.

Disturbance in RNA editing has been shown to take part in carcinogenesis [28]. In normal cells, AZIN1 regulates the cell cycle and stimulates cell proliferation and edited gene levels of AZIN1 have

been detected in cancer tissue [28]. Thus, disturbances in the AZIN1 gene may induce cell proliferation and enhance tumorigenesis [10, 18, 28]. Upregulation of AZIN1 has been shown in various cancers such as gastric, ovarian, breast, prostate, lung, and colorectal cancers [17-19]. Lung cancer study demonstrated that both *in vitro* and *in vivo* AZIN1 RNA editing induced proliferation, invasion, and migration [18]. In addition, colorectal cancer tissue showed higher levels of edited AZIN1 RNA compared with normal tissue, which might contribute to poorer patient survival [19]. Further, dysregulation of edited AZIN1 seemed to predict lymph node metastasis, hepatic metastasis, and distant metastasis in colorectal cancer [19].

In our study, AZIN1 showed no association with clinical parameters or survival of ACC. Like most salivary gland tumors, ACC is a slow-growing tumor and has several histological growth patterns. High mitotic activity has been linked to unfavorable prognosis in ACC patients [29]. Cell proliferation in solid-type tumors has been shown to be higher, and behavior more aggressive, compared with cribriform and tubular types that might partly explain our results [30]. Only a small number of solid tumors (8.8%) were present in the present ACC series, and the growth pattern did not affect patient survival in our previous report [24]. Although we expected to find the opposite behavior of AZIN1 compared to AZIN2, the expression of AZIN1 was not associated with clinical parameters or patient survival. In the vicinity of ACC tissue, the normal-appearing salivary gland tissue did not immunexpress AZINs. However, we did not study any salivary gland tissue samples which would have been totally free of any carcinomatous signs.

Among the genes related to the development of cancer, the *MYC* gene family (*c-MYC*, *MYCN*, and *MYCL*) is one of the most studied, and their oncogenic functions correlate with tumor growth and poor prognosis [31]. In addition, the C-myc signaling pathway drives carcinogenesis of ACC, and a recent study has shown promising therapeutic results by controlling this pathway [32]. *MYC* upregulates ODC activity and polyamine levels and *MYC* oncogenes may contribute to tumor hyperproliferation, especially of *MYC*-driven cancers [31]. It seems that AZ2 may control the proteasomal degradation of *MYC* and ODC, which is connected to tumor formation [31].

LIMITATIONS AND STRENGTHS

One limitation of the current study is that the tissue material is partly old and it has been used a lot. The study comprises all minor salivary and mucous

gland ACC of 38-year period in the Helsinki University Hospital district which we consider as a strength of the study.

CONCLUSIONS

Although AZIN1 has been shown to have a role in several cancers, our present study adds knowledge to the behavior of AZIN2 in ACC tissue. AZs and AZINs may have therapeutic potential in the future as these enzymes are linked to tumorigenesis. It seems that AZIN2 expression is higher in cancer tissue with secretory functions. In ACC tissue, high AZIN2 expression could be related to a well-differentiated histological type which still has a functioning vesicle transportation system. Thus, AZIN2 could be a prognostic factor for better survival of ACC patients.

We thank Pia Saarinen for excellent laboratory work and Tero Vahlberg for statistical help. This study was supported by the Helsinki University Hospital Research Fund and the Cancer Foundation Finland.

CONFLICT OF INTEREST

None.

REFERENCES

1. El-Naggar AK, Chan JKC, Grandis JR, Takata T, Slootweg PJ, editors. Tumours of salivary glands. In: El-Naggar AK, editors. WHO Classification of Head and Neck Tumours. Lyon: IARC Press, 2017;160: 164-165.
2. Li N, Xu L, Zhao H, El-Naggar AK, Sturgis EM. A comparison of the demographics, clinical features, and survival of patients with adenoid cystic carcinoma of major and minor salivary glands versus less common sites within the surveillance, epidemiology, and end results registry. *Cancer* 2012;118:3945-53.
3. Raman S, Sherlin HJ. Utility of smooth muscle actin and CD117 as reliable markers in the diagnosis of salivary gland neoplasms. *J Oral Maxillofac Pathol* 2019;23:218-23.
4. Ettl T, Schwarz S, Kleinsasser N, Hartmann A, Reichert TE, Driemel O. Overexpression of EGFR and absence of C-KIT expression correlate with poor prognosis in salivary gland carcinomas. *Histopathology* 2008;53:567-77.
5. Thierauf J, Ramamurthy N, Jo VY, Robinson H, Frazier RP, Gonzalez J, et al. Clinically integrated molecular diagnostics in adenoid cystic carcinoma. *Oncologist* 2019;24:1356-67.
6. Xu B, Drill E, Ho A, Ho A, Dunn L, Prieto-Granada CN, et al. Predictors of outcome in adenoid cystic carcinoma of salivary glands: a clinicopathologic study with correlation between MYB fusion and protein expression. *Am J Surg Pathol* 2017;41:1422-32.

7. Poling JS, Yonescu R, Subhawong AP, Sharma R, Argani P, Ning YI, et al. MYB labeling by immunohistochemistry is more sensitive and specific for breast adenoid cystic carcinoma than MYB labeling by FISH. *Am J Surg Pathol* 2017;41:973–9.
8. Thomas T, Thomas TJ. Polyamines in cell growth and cell death: molecular mechanisms and therapeutic applications. *Cell Mol Life Sci* 2001;58:244–58.
9. Kanerva K, Makitie LT, Back N, Andersson LC. Ornithine decarboxylase antizyme inhibitor 2 regulates intracellular vesicle trafficking. *Exp Cell Res* 2010;316:1896–906.
10. Ramos-Molina B, Lambertos A, Penafiel R. Antizyme inhibitors in polyamine metabolism and beyond: physiopathological implications. *Med Sci* 2018;6:89.
11. Auvinen M, Paasinen A, Andersson LC, Hölttä E. Ornithine decarboxylase activity is critical for cell transformation. *Nature* 1992;360:355–8.
12. Koguchi K, Kobayashi S, Hayashi T, Matsufuji S, Murakami Y, Hayashi S. Cloning and sequencing of a human cDNA encoding ornithine decarboxylase antizyme inhibitor. *Biochim Biophys Acta* 1997;1353:209–16.
13. Pitkänen LT, Heiskala M, Andersson LC. Expression of a novel human ornithine decarboxylase-like protein in the central nervous system and testes. *Biochem Biophys Res Commun* 2001;287:1051–7.
14. Keren-Paz A, Bercovich Z, Porat Z, Erez O, Brener O, Kahana C. Overexpression of antizyme-inhibitor in NIH3T3 fibroblasts provides growth advantage through neutralization of antizyme functions. *Oncogene* 2006;25:5163–72.
15. Kim SW, Mangold U, Waghorne C, Mobascher A, Shantz L, Banyard J, et al. Regulation of cell proliferation by the antizyme inhibitor: evidence for an antizyme-independent mechanism. *J Cell Sci* 2006;119:2583–91.
16. Silva TM, Cirenajwis H, Wallace HM, Oredsson S, Persson L. A role for antizyme inhibitor in cell proliferation. *Amino Acids* 2015;47:1341–52.
17. Olsen RR, Zetter BR. Evidence of a role for antizyme and antizyme inhibitor as regulators of human cancer. *Mol Cancer Res* 2011;9:1285–93.
18. Hu X, Chen J, Shi X, Feng F, Lau KW, Chen Y, et al. RNA editing of AZIN1 induces the malignant progression of non-small-cell lung cancers. *Tumour Biol* 2017;39:1010428317700001.
19. Shigeyasu K, Okugawa Y, Toden S, Miyoshi J, Toiyama Y, Nagasaka T, et al. AZIN1 RNA editing confers cancer stemness and enhances oncogenic potential in colorectal cancer. *JCI Insight* 2018;3:99976.
20. Rasila T, Lehtonen A, Kanerva K, Makitie LT, Haglund C, Andersson LC. Expression of ODC antizyme inhibitor 2 (AZIN2) in human secretory cells and tissues. *PLoS One* 2016;11:e0151175.
21. Kanerva K, Lappalainen J, Makitie LT, Virolainen S, Kovanen PT, Andersson LC. Expression of antizyme inhibitor 2 in mast cells and role of polyamines as selective regulators of serotonin secretion. *PLoS One* 2009;4:e6858.
22. Makitie LT, Kanerva K, Polvikoski T, Paetau A, Andersson LC. Brain neurons express ornithine decarboxylase-activating antizyme inhibitor 2 with accumulation in Alzheimer's disease. *Brain Pathol* 2010;20:571–80.
23. Kaprio T, Rasila T, Hagström J, Mustonen H, Lanikila P, Haglund C, et al. Ornithine decarboxylase antizyme inhibitor 2 (AZIN2) is a signature of secretory phenotype and independent predictor of adverse prognosis in colorectal cancer. *PLoS One* 2019;14:e0211564.
24. Hämetoja H, Hirvonen K, Hagström J, Leivo I, Saari-lahti K, Apajalahti S, et al. Early stage minor salivary gland adenoid cystic carcinoma has favourable prognosis. *Virchows Arch* 2017;471:785–92.
25. Barnes L, Eveson WJ, Reichart P, Sidransky D, editors. *Tumours of the salivary glands*. In: Eveson WJ, editor. *WHO Classification of Head and Neck Tumours*. Pathology and Genetics of Head and Neck Tumours. Lyon: IARC Press, 2005;210:221–222.
26. Mäkinen LK, Häyry V, Hagström J, Sorsa T, Passador-Santos F, Keski-Säntti H, et al. Matrix metalloproteinase-7 and matrix metalloproteinase-25 in oral tongue squamous cell carcinoma. *Head Neck* 2014;36:1783–8.
27. Ellington CL, Goodman M, Kono SA, Grist W, Wadsworth T, Chen AY, et al. Adenoid cystic carcinoma of the head and neck: incidence and survival trends based on 1973–2007 Surveillance, Epidemiology, and End Results data. *Cancer* 2012;118:4444–51.
28. Qi L, Chan TH, Tenen DG, Chen L. RNA editome imbalance in hepatocellular carcinoma. *Cancer Res* 2014;74:1301–6.
29. Luukka H, Klemi P, Leivo I, Vahlberg T, Grenman R. Prognostic significance of Ki-67 and p53 as tumor markers in salivary gland malignancies in Finland: an evaluation of 212 cases. *Acta Oncol* 2006;45:669–75.
30. Tang Q-L, Fan S, Li H-G, Chen W-L, Shen X-M, Yuan X-P, et al. Expression of Cyr61 in primary salivary adenoid cystic carcinoma and its relation to Ki-67 and prognosis. *Oral Oncol* 2011;47:365–70.
31. Bachmann AS, Geerts D. Polyamine synthesis as a target of MYC oncogenes. *J Biol Chem* 2018;293:18757–69.
32. Liu X, Wu H, Huang P, Zhang F. JQ1 and PI3K inhibition synergistically reduce salivary adenoid cystic carcinoma malignancy by targeting the c-Myc and EGFR signaling pathways. *J Oral Pathol Med* 2019;48:43–51.