

Emotional Processing in the First 2 Years of Life: A Review of Near-Infrared Spectroscopy Studies

Ambika Maria, Shashank Shekhar, Ilkka Nissilä, Kalle Kotilahti, Minna Huotilainen, Linnea Karlsson, Hasse Karlsson, Jetro J. Tuulari

From the FinnBrain Birth Cohort Study, Turku Brain and Mind Center, University of Turku, Turku, Finland (AM, SS, IN, KK, MH, LK, HK, JJT); Department of Psychiatry, Turku University Hospital and University of Turku, Turku, Finland (AM, HK, JJT); Department of Neurology, University of Mississippi Medical Center, Jackson, MS (SS); Department of Neuroscience and Biomedical Engineering, Aalto University, School of Science, Espoo, Finland (IN, KK); Cognitive Brain Research Unit and Faculty of Educational Sciences, University of Helsinki, Helsinki, Finland (MH); and Department of Child Psychiatry, Turku University Hospital and University of Turku, Turku, Finland (LK).

ABSTRACT

Emotional stimuli processing during childhood helps us to detect salient cues in our environment and prepares us for our social life. In early childhood, the emotional valences of auditory and visual input are salient and relevant cues of social aspects of the environment, and it is of special interest to understand how exactly the processing of emotional stimuli develops. Near-infrared spectroscopy (NIRS) is a noninvasive neuroimaging tool that has proven valuable in studying emotional processing in children. After conducting a systematic search of PubMed, Web of Science, and Embase databases, we examined 50 NIRS studies performed to study emotional stimuli processing in children in the first 2 years of age. We found that the majority of these studies are done in infants and the most commonly used stimuli are visual and auditory. Many of the reviewed studies suggest the involvement of bilateral temporal areas in emotional processing of visual and auditory stimuli. It is unclear which neural activation patterns reflect maturation and at what age the emotional encoding reaches those typically seen in adults. Our review provides an overview of the database on emotional processing in children up to 2 years of age. Furthermore, it demonstrates the need to include the less-studied age range of 1 to 2 years, and suggests the use of combined audio-visual stimuli and longitudinal studies for future research on emotional processing in children. Thus, NIRS might be a vital tool to study the associations between the early pattern of neural responses and socioemotional development later in life.

Keywords: NIRS, Near-infrared spectroscopy, children, emotion, brain.

Acceptance: Received April 24, 2018. Accepted for publication May 21, 2018.

Correspondence: Ambika Maria, Department of Psychiatry, Faculty of Medicine, University of Turku, Turku 20500, Finland. E-mail: ambika.maria@utu.fi

Acknowledgments and Disclosure: We are thankful to Tricia Latimer for proofreading the manuscript. We thank the University of Turku Graduate School, Center for International Mobility, and Maire Taposen Säätiö for financial support to AM during the preparation of this review. This work was also supported by Academy of Finland projects 269282 (to IN), 273451 and 303937 (to IN and KK), 134950 (to HK), 253270 (to HK), 308176 (to LK); Jane and Aatos Erkkö Foundation (to HK), Signe and Ane Gyllenberg Foundation (to HK, LK); State Research Grant (EVO) (to HK, LK, JJT); Yrjö Jahnesson Foundation (to LK); Brain and Behavioral Foundation (NARSAD) YI Grant #19056 (to LK); The National Graduate School of Clinical Investigation (VKTK) grant (SS); and The Finnish Society of Science and Letters (SS). The authors declare no conflicts of interest.

J Neuroimaging 2018;28:441-454.

DOI: 10.1111/jon.12529

Introduction

Emotions direct our attention and motivate behavior and can be activated by internal or external stimuli.¹ In addition to the primary sensory areas such as the occipital cortex² and the auditory cortex,³ key brain areas involved in processing of emotional stimuli in adults include bilateral cortical structures, such as the orbitofrontal cortex,⁴⁻⁶ cingulate cortex, inferolateral parietal cortex, temporal cortex, amygdala and (para) hippocampus,⁷ and the prefrontal cortex.^{8,9} Additionally, key subcortical structures involved in the processing of emotional stimuli include the thalamus, hypothalamus, fornix, mammillary bodies, olfactory bulbs, hypothalamus, and basal ganglia.⁷ Emotional processing thus engages wide brain circuits in the adult brain but how they emerge during development is far from established.

Brain volume increases rapidly during the early years of life, reaching almost 75% of adult brain volume during the first 2 years of age.^{10,11} This process is coupled with rapid white matter development, mainly observed first through tissue growth

and the progression of myelination that continues throughout childhood.¹² The core of emotional brain circuits are likely formed during the early years of life, and this time of neuronal growth enables the crucial first steps of neural development that prepare an individual for social life. These processes are influenced by prenatal development and genetic factors as well as the postnatal environment.¹ The emotion processing network is crucial in determining the significance of external stimuli and providing cues on how to respond in social situations,¹³ which has far-reaching implications for later development and health.

Emotional processing has been studied with various functional neuroimaging modalities such as electroencephalography (EEG), magnetoencephalography (MEG), functional magnetic resonance imaging (fMRI), and near-infrared spectroscopy (NIRS). NIRS is an imaging method that uses the absorption of red and near-infrared light (630 to 950 nm) by specific chromophores to measure the hemodynamics of a tissue of interest.¹⁴ The measurements done with NIRS are based on neurovascular coupling. In response to a local increase in

This is an open access article under the terms of the Creative Commons Attribution-NonCommercial-NoDerivs License, which permits use and distribution in any medium, provided the original work is properly cited, the use is non-commercial and no modifications or adaptations are made.

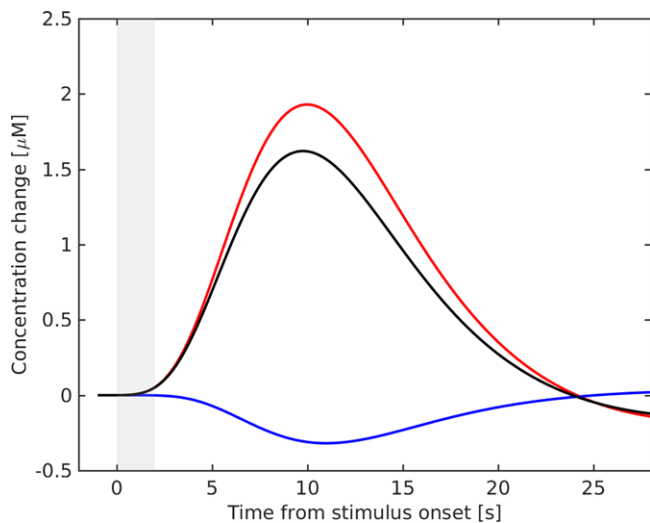


Fig 1. Illustration of a typical oxygenated hemoglobin (red), deoxygenated hemoglobin (blue), and total hemoglobin (black) time courses to a 2-second slow brushing stimulus in 2-month-old infants.

neuronal activation, a temporally and spatially coincident increase in oxygen metabolism is thought to exist, causing an initial decrease in oxygenated hemoglobin (HbO_2) and an increase in deoxygenated hemoglobin (HbR). Following this, arterial dilation ensues as well as a local increase in cerebral blood flow (CBF) and cerebral blood volume (CBV). As oxygen-rich arterial blood flows into the region, total hemoglobin (HbT) and HbO_2 concentrations typically increase and HbR decreases within several seconds. Changes in the concentration of HbO_2 and HbR result in changes in the intensity of the reflected NIR light. Thus, HbO_2 , HbR , and HbT are the most often used NIRS metrics (Fig 1).

At the practical level, during an NIRS measurement, the light is projected into the scalp at the source position, after which

the photons migrate through the tissue in random trajectories due to multiple scattering and photons change their direction of propagation as a result of interacting with tissues. During absorption, the energy of a photon is absorbed by the tissue and converted into a small amount of thermal energy. After interacting with the tissue components in the vicinity of the NIR light source, the photons that are not absorbed in the process exit the tissue.¹⁵ Light detectors that are at a distance of a few centimeters from the source position detect part of this light. The surface of the scalp that is not directly under sources or detectors should be covered by black absorptive material to avoid influence from external light and to prevent direct transmission of light between source and detector.

NIRS does not require restriction of movements of the child and the mother can hold the child during the measurement (Fig 2), which is advantageous in pediatric neuroimaging. NIRS has a relatively good temporal resolution and most systems can measure several samples per second, which makes it possible to observe changes in the time course of the hemodynamic response as well as differences in response latency between brain regions (Fig 3). However, a few of the disadvantages of NIRS include a temporal delay in hemodynamic response, limited depth resolution, and interference from hair (that is more pronounced with participants having dark hair color). Table 1 provides a comparison of NIRS with fMRI, EEG, and MEG for studies in children.

In this paper, we report a critical review of current literature on emotional processing studies using NIRS in infants and children up to 2 years of age. We discuss the implications of these studies, methodological limitations, and future prospects of research on emotional processing using NIRS.

The Systematic Review (Methods)

We conducted a systematic search across the databases PUBMED, WEB of SCIENCE, and EMBASE (from inception

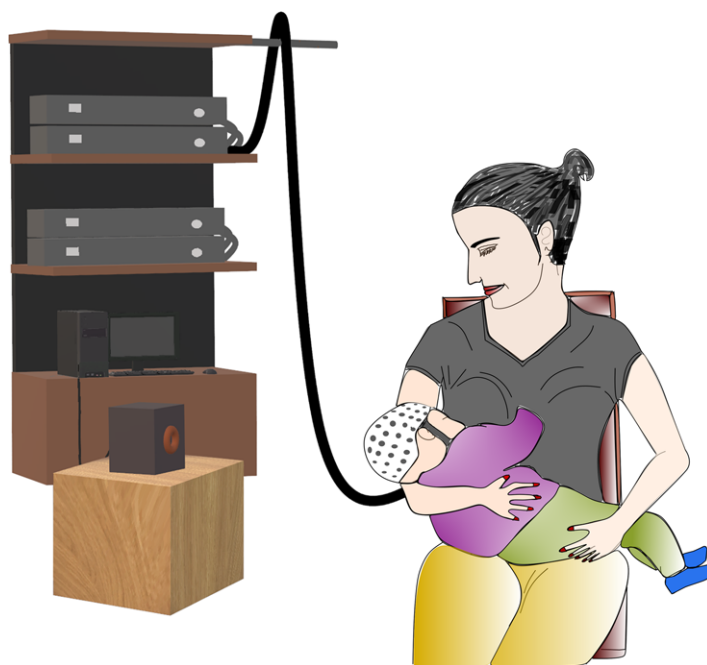

Fig 2. Schematic illustration of near-infrared spectroscopy experimental setup. The parent can hold the baby on her lap during the measurement.

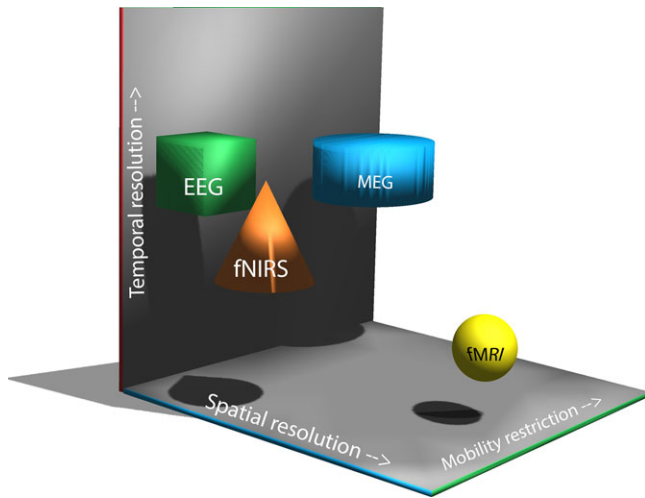


Fig 3. Schematic comparison of the temporal and spatial resolutions and requirement for mobility restriction in major brain imaging methods. NIRS = near-infrared spectroscopy; EEG = electroencephalography; fMRI = functional magnetic resonance imaging; MEG = magnetoencephalography.

through January 8, 2018) to identify all the NIRS studies using emotional stimuli as external sensory stimuli in infants and children up to 2 years of age. The search strategy combined the following medical subject headings (MeSH) terms and keywords: (NIRS OR fNIRS) AND (infants OR newborns OR children) AND (brain OR neuroimaging). This resulted in 708

articles in PUBMED, 699 articles in the WEB OF SCIENCE, and 1,099 articles in EMBASE.

After screening for duplicates, the remaining studies ($n = 836$) were filtered by reading the titles and abstracts to search for the studies that addressed emotional processing using emotionally relevant sensory stimuli. The exclusion criteria were: (1) written in languages other than English; (2) carried out in nonhuman species; (3) subjects were adults or children older than 2 years of age; and (4) did not address emotional processing. This resulted in the exclusion of 758 articles. Additionally, we included articles that were identified from reference lists of the relevant articles ($n = 22$).

Next, we went through the full text of the 100 articles and specifically included only those publications that addressed emotional processing by using emotionally relevant sensory stimuli, as emotional responses can be induced by external sensory stimuli.¹⁶ Publications were excluded if they did not include original data (eg, reviews, commentaries) or if they were not published as a full-length article in a peer-reviewed journal (eg, abstracts for presentations, case reports). This resulted in 50 articles for this review. The selected articles were then reviewed in detail, and the relevant data were extracted, and the main findings were reported. Figure 4 shows the preferred reporting items for systematic reviews and meta-analyses (PRISMA) flow diagram for summarizing this review process.

We did not focus on experimental design considerations in between the studies, which has been covered elsewhere.¹⁷ After conducting the review, we planned to carry out a meta-analysis on each of the topics, but we found out that it was not plausible

Table 1. Comparison of NIRS with Other Functional Neuroimaging Modalities in Studying Children

	NIRS	EEG	fMRI	MEG
Underlying principle	Changes in blood oxygenation based on hemodynamic changes, as reflected by HbO ₂ , HbT, and HbR	Electromagnetic activations in the cortical parts of the brain	Changes in deoxygenated hemoglobin content of the blood, BOLD signal	Electromagnetic activity resulting from activations in the cortical regions
Long distance interactions	Able to analyze activations and deactivations (changes in HbT)	Postsynaptic potentials	Able to analyze changes associated with cerebral blood flow	Postsynaptic potentials
Cost	Moderate	Low	Expensive	Expensive
Mobility of Instrument	Mobile	Mobile	Immobile	Immobile
Noise	Silent	Silent	Noisy	Silent
Restriction of movement	No	No	Yes, but little movement can be handled with software	No, but little to no movement is preferred to get good data
Sensitivity to movement	Moderate	Moderate	High	High
Use with magnetic implants	Yes	Yes	No	No
Temporal resolution	~100 milliseconds	Milliseconds	1-5 seconds	Milliseconds
Mother can hold the baby	Yes	Yes	No	No
Spatial resolution	Centimeters	Centimeters	Millimeters	Millimeters
Interference from hair	Yes	Some	No	No
Radial/depth source detection	Limited depth penetration around 3 cm, Children > adults	Somewhat limited depth penetration, Children > adults	Yes	Limited depth penetration
Source localization limitation	Variable with optical properties of head tissues	Variable with electric properties of head tissues	Not dependent on tissue properties	Not dependent on tissue properties

NIRS = Near-infrared spectroscopy; EEG = electroencephalography; fMRI = functional magnetic resonance imaging; MEG = magnetoencephalography; HbO₂ = oxygenated hemoglobin; HbR = deoxygenated hemoglobin; HbT = total hemoglobin; BOLD signal = blood oxygen-level dependent signal.

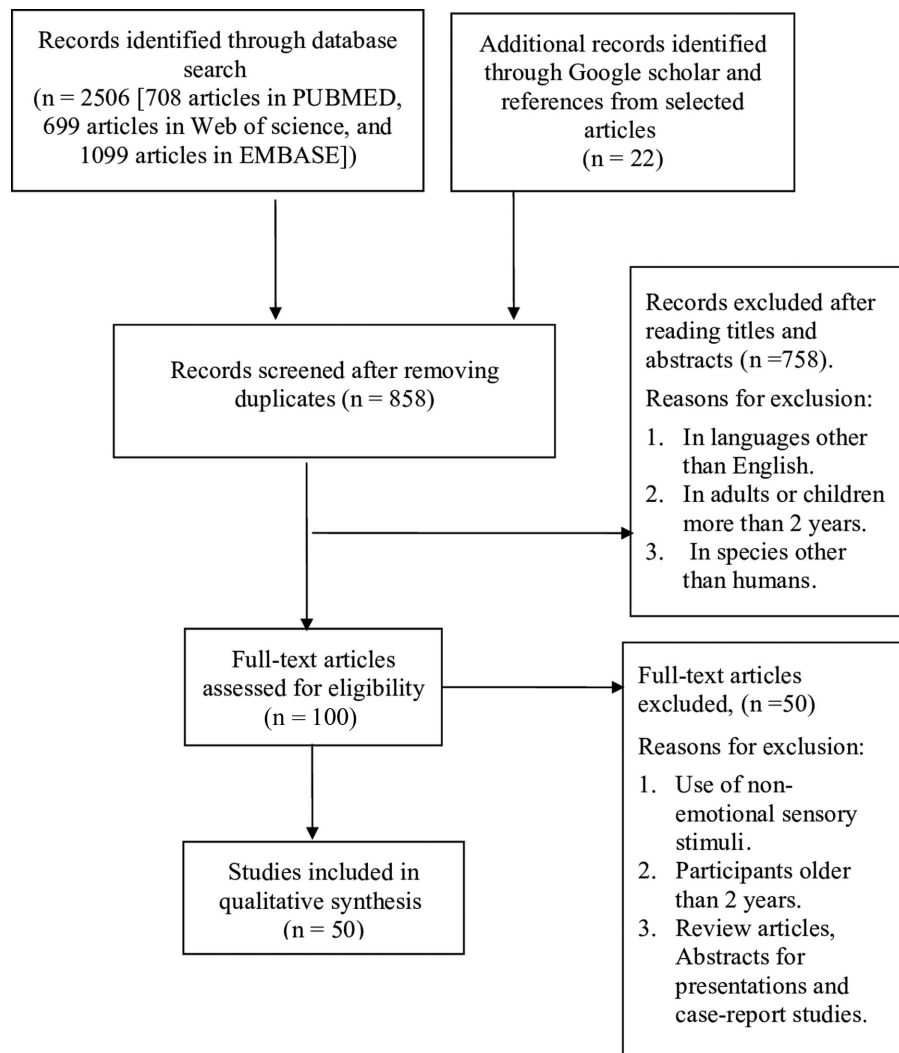


Fig 4. Preferred reporting items for systematic reviews and meta-analyses (PRISMA) flow diagram for summarizing the review process. EMBASE = Excerpta Medica database.

due to the differences in the equipment used, measurement areas, and experimental design.

Overview of NIRS Studies on Emotional Processing in Children up to 2 Years of Age

Emotionally Relevant Visual Stimuli

Infants likely start to recognize the identity of a face, irrespective of its orientation, at a developmental period between 5 and 8 months of age.^{18,19} The right temporal cortex has been implicated in face detection during infancy.²⁰⁻²³ Left temporal cortical activation has also been reported for processing of face-like objects in 7- to 8-month-old infants.²⁴ Kobayashi et al additionally reported a neural adaptation effect (observed by attenuation in brain responses) for the repeated measurement of the same face as compared to different faces in infancy.^{23,25} Furthermore, there appears to be an increased sensitivity toward adult faces in infancy.²⁶ Right temporal areas are seen to be activated in infants in response to adult faces (and not infant faces).²⁷

The caretaker's face is one of the most frequently occurring visual stimuli during infancy and thus most likely carries early

social and emotional valence. Right frontotemporal cortex activation has been observed in 6-9-month-old infants in response to their mothers' faces as compared to unknown faces.²⁸ Their mothers' faces (in contrast to unfamiliar faces) have been determined to cause left temporal activation in 7- to 8-month-old infants.²⁹ Right frontal (most likely orbitofrontal cortex) activation has been noted in 7-month-old infants in response to smiling soundless videos of their mothers (as compared to neutral expression).³⁰ Infants can discriminate between the smiles of their own mothers and the smiles of unfamiliar mothers. Medial prefrontal activation (around the anterior orbitofrontal cortex) has been observed in 9-13-month-old infants on viewing movies of their own mothers' smiles (as compared to viewing unfamiliar mothers' smiles).³¹ Thus, the frontal cortex likely plays a significant role in the recognition of social positive affect in infancy.

Happy faces are seen to cause activation in the left temporal areas (as compared to baseline), while angry faces seem to activate right temporal areas in 7- to 8-month-old infants.³² Bilateral temporal cortices have been implicated in the processing of social dynamic stimuli (as compared to nonsocial dynamic stimuli) in infants.^{33,34} Additionally, infant temperament traits appear to

modulate how infants respond to emotional visual stimuli. The right posterior temporal region activation has been reported by Kant et al in response to social compared to the nonsocial dynamic stimuli in 5-month-old infants. Furthermore, this differential activation was smaller in infants who show higher negative affect. These results suggest that decreased cortical sensitivity to social stimuli in infants showing high negative affect may be an early biomarker for later difficulties in social interaction.³⁵ Increased left prefrontal cortex activation has been reported in response to happy faces in 7-month-old infants with low negative emotionality temperament (as compared to infants with high negative emotionality temperament).³⁶ As temperament is one of the earliest observable features of personality and among the major determinants of interaction between the children and their caretakers,³⁷ early brain responses to emotional cues in the environment may be interesting biomarkers for later development, which makes studies combining these metrics especially valuable.

Thus, bilateral temporal cortices and the frontal cortex are implicated in processing emotional visual stimuli in children up to 2 years of age. However, the probe position limits the brain region that can be studied, and the neural circuits of visual recognition are still developing in infancy. It is evident that the developmental pathways and possible shifts in lateralization patterns can only be delineated in future longitudinal studies. Table 2 provides a detailed summary of the reviewed NIRS studies on visual emotional processing in children up to 2 years of age.

Emotionally Relevant Auditory Stimuli

Processing of emotional auditory cues seems to be already present at birth. Emotional prosody refers to communicating feelings using different elements of speech such as syllable length, loudness, and voice pitch.³⁸ Zhang et al reported right temporal cortex (mainly the middle temporal gyrus and superior temporal gyrus) activation in response to emotional, relative to neutral, prosody in neonates as early as 2–8 days after birth. Furthermore, the researchers observed a right parietal area (approximately located in the supramarginal gyrus) that showed a heightened sensitivity to fearful, relative to happy and neutral, prosody.³⁹

Native language is usually the predominant way in which caregivers communicate with infants. Sato et al reported left temporal-parietal activation in response to forward maternal language in contrast to backward maternal language or forward speech in a foreign language.⁴⁰ Minagawa-Kawai et al observed left-lateralized responses to native speech (as compared to non-native speech) in 4-month-old infants. Furthermore, they observed significant activation in response to emotional voices, ie, human vocalizations with no linguistic content, either with a positive (eg, admiration and laughing) or negative emotional valence (eg, crying and sigh) in right temporal areas of infants.⁴¹ Human voice (as compared to nonvoice sounds) causes activation in the voice-selective regions of the bilateral temporal cortices in infants between 4 and 7 months of age.⁴²

Infant-directed speech (IDS) might be one of the first sounds to elicit emotional responses in infants. Bilateral frontotemporal, frontal, temporal, and temporoparietal regions are seen to be activated by IDS (as compared to reverse speech or silence) in infants.^{43–46} IDSs from infants' own mothers (rather than

from unfamiliar mothers) are seen to cause frontal activation in infants.⁴⁵ Dorsal medial prefrontal cortex activation has been observed in 6-month-old infants in response to hearing their own names (as compared to other names), especially when spoken by their mother, as compared to a stranger's voice.⁴⁷ While the infants' mothers' voices activated the left frontal area (more than right), their female nurse's voice activated the right frontal area (more than left).⁴⁸ Thus, talker familiarity seems to affect speech processing and activates putative future brain regions of emotional processing in infants.

Emotions differentially modulate voice processing in infants. Grossmann et al reported activation in the bilateral superior temporal cortex in response to human voices as compared to nonvocal sounds in 7-month-old (but not 4-month-old infants), thereby, suggesting that voice-sensitive brain encoding appears between 4 and 7 months of age. Furthermore, hearing emotional prosody words (happy and angry), but not neutral prosody, caused activation in the right temporal cortex, and hearing angry prosody caused more activation in the right temporal cortex than happy prosody. Such a neural mechanism is thought to prioritize threat-related emotional stimuli and act as a protective mechanism. Listening to happy speech (but not angry or neutral) caused activation in the right inferior frontal cortex of 7-month-old infants.⁴⁹ Thus, right temporal cortex seems to be involved in processing angry and happy (angry > happy) words, while right inferior frontal cortex is implicated in processing happy words.

Overall, bilateral frontotemporal, frontal, temporal, temporoparietal, and parietal regions have been implicated in processing emotional auditory stimuli in children up to 2 years of age. Table 3 provides a detailed summary of the reviewed NIRS studies on auditory emotional processing in children up to 2 years of age.

Emotionally Relevant Audiovisual Stimuli

Audiovisual emotional stimuli expectedly engage brain regions implicated in studies using either auditory or visual emotional stimuli. Occipital and bilateral temporal activation has been reported by Bortfeld et al in response to audiovisual stimuli (IDS with positive affective tone and animated objects). Whereas occipital activation has been noted in response to visual-only stimuli (animated objects such as spirals, circles, and rectangles) in infants.⁵⁰ Using the same stimuli, greater activation was observed in the left temporal cortex (as compared to the right temporal cortex) in response to audiovisual stimuli as compared to visual-only stimuli in infants.⁵¹ Dorsomedial prefrontal cortex activation has been observed in response to the socially interactive game, "peek-a-boo," in which both visual (direct gaze) and auditory (IDS) stimuli were presented with an adult's direct gaze compared to an averted gaze.⁵² These studies highlight the role of bilateral temporal cortices, prefrontal cortex, and occipital areas in processing audiovisual stimuli in children.

Cortical responses to social cues were reported by Lloyd-Fox et al across participants ranging in age from newborn to toddlerhood. The researchers reported that infants at 0–2 months of age exhibited nonsocial auditory selectivity, an effect that persists until 4–8 months when there is a transition to greater social stimulus selectivity. Thereafter, 9- to 24-months of age infants showed socially selective brain responses to both the visual and auditory stimuli.^{53,54} Fava et al reported that younger infants (3-6-month old) showed a greater overall response to

Table 2. Summary of NIRS Studies Done in Infants and Children up to the Age of 2 Years to Study Visual Emotional Processing

Year, Author, Journal	Age of Participants	Number of Participants	Stimuli	Comparison/ Contrast	Probe Location	Activated Brain Area (Increase in HbO ₂ and/or HbT/ Decrease in HbR)
2018, Kant et al, <i>Developmental Cognitive Neuroscience</i>	5-8 m	27	Videos displaying either hand and facial movements of female actors (social dynamic condition)	Videos of moving toys and machinery (nonsocial dynamic condition)	Bilateral temporal cortices	Right posterior-temporal region in the social compared to the nonsocial condition. Furthermore, this differential activation was smaller in infants showing higher negative effect
2017, Powell et al, <i>Developmental Science</i>	3-12 m	16	Face and scene video clips	Scrambled scene video clips	Junction of the temporal, occipital, and parietal lobes in right hemisphere	Cortical regions with preferential responses to faces versus scenes, and to scenes versus faces
2017, Lloyd-Fox et al, <i>European Journal of Neuroscience</i>	4-6 m	36	Social videos of people (ie, peek-a-boo)	Nonsocial images (vehicles)	Frontal and temporal areas	At 4-6 months, infants who went on to develop autism spectrum disorder at 3 years evidenced-reduced activation to visual social stimuli relative to low-risk infants across inferior frontal and posterior temporal regions
2016, Kobayashi et al, <i>Developmental Science</i>	3 and 9 m	24 (3 m) and 24 (9 m)	Adult neutral faces	Infant neutral faces	Bilateral temporal areas	Right temporal areas in response to adult faces and not infant faces in 9 m (and not 3 m)
2015, Ravicz et al, <i>Frontiers in Psychology</i>	7 m	24	Happy, fearful, or angry female faces	Baseline	Prefrontal cortex	Left prefrontal cortex in infants with low negative emotionality temperament
2014, Kobayashi et al, <i>BMC Neuroscience</i>	5-6 m and 7-8 m	12 (5-6 m) and 12 (7-8 m)	Different neutral faces	Identical neutral faces	Bilateral temporal areas	Bilateral temporal areas in response to different faces only in 7-8 m (and not 5-6 m)
2013, Farroni et al, <i>Scientific Reports</i>	1-5 d	17	Dynamic human action videos	Mechanical action videos	Bilateral temporal areas	Activation over bilateral posterior temporal cortex selective to a dynamic face stimulus, but no activation in response to a moving human arm
2013, Fox et al, <i>Frontiers in Human Neuroscience</i>	7 m	10 (High-risk autism) and 10 (Low-risk controls)	Soundless video recordings of infants' mothers with smiling or neutral expression	Soundless video recordings of strangers with smiling or neutral expression	Frontal and right lateral portions of the head	<ol style="list-style-type: none"> 1. Right frontal cortex in response to smiling as compared to neutral expression 2. Both frontal and lateral regions in response to mother's face over stranger's face across in infants with high risk for autism spectrum disorders
2012, Kobayashi et al, <i>Journal of Experimental Child Psychology</i>	5-6 m and 7-8 m	24 (5-6 m) and 24 (7-8 m)	Upright Arcimboldo images	Inverted Arcimboldo images	Bilateral temporal areas	Left temporal areas in response to upright Arcimboldo images only in 7-8 m (and not 5-6 m)
2012, Kobayashi et al, <i>NeuroReport</i>	5-8 m	15	Photographs of five female faces in frontal view with neutral expression	Photos of vegetables	Bilateral temporal areas	Bilateral temporal areas in response to different faces as compared to same faces

(Continued)

Table 2. Continued

Year, Author, Journal	Age of Participants	Number of Participants	Stimuli	Comparison/ Contrast	Probe Location	Activated Brain Area (Increase in HbO ₂ and/or HbT/ Decrease in HbR)
2011, Kobayashi et al, <i>Frontiers in Human Neuroscience</i>	5-6 m and 7-8 m	12 (5-6 m) and 12 (7-8 m)	Different faces	Same faces and different objects	Bilateral temporal areas	Right temporal areas in response to different neutral faces
2011, Nakato et al, <i>Early Human Development</i>	7-8 m	15	Photo images of either infant's own mother's face or unfamiliar female faces	Images of vegetables	Bilateral temporal cortices	1. Right temporal cortex in response to mother's face and unfamiliar faces (as compared to baseline) 2. Left temporal cortex activation only when the mother's face was present
2011, Nakato et al, <i>Neuroimage</i>	6-7 m	12	Faces with happy, angry, and neutral expression	Images of vegetables	Bilateral temporal cortices	Left temporal areas in response to happy faces and right temporal areas in response to angry faces (as compared to baseline)
2010, Honda et al, <i>Brain Research</i>	7-8 m	13	Canonical	Scrambled faces	Bilateral temporal cortices	Right visual cortex in response to canonical faces (as compared to scrambled faces)
2009, Nakato et al, <i>Human Brain Mapping</i>	5 and 8 m	10 (5 m) and 10 (8 m)	Female faces with frontal and profile views	Images of vegetables	Bilateral temporal cortices	Right temporal areas in response to faces with frontal view in 5 m, whereas in 8 m right temporal areas in response to faces with both frontal and profile views
2009, Minagawa-Kawai et al, <i>Cerebral Cortex</i>	11 m	15	Video recordings of infants' mothers with smiling and neutral expression	Video recordings of unfamiliar mothers with smiling and neutral expression	Prefrontal cortex	Medial prefrontal areas around the anterior orbitofrontal cortex in response to viewing own mothers' smiles as compared to unfamiliar mothers' smiles
2009, Lloyd-Fox et al, <i>Child Development</i>	5 m	36	Life-size social video clips of female actors who either moved their eyes left or right, their mouth in silent vowel movements, or performed hand games	Video clips of machine cogs and pistons and moving mechanical toys	Bilateral temporal lobes	Two posterior temporal sites bilaterally in response to dynamic social stimuli as compared to dynamic nonsocial stimuli
2008, Nakato et al, <i>Journal of Vision</i>	6-8 m	7	Images of mothers and unfamiliar faces	Images of vegetables	Bilateral temporal cortices	Right temporal areas in response to both mothers' and unfamiliar faces as compared to vegetables
2008, Carlsson et al, <i>Acta Paediatrica</i>	6-9 m	19	Mothers' faces	Unknown faces	Right frontotemporal cortex	Right frontotemporal cortex in response to mothers' faces as compared to unknown faces
2007, Otsuka et al, <i>Neuroimage</i>	5-8 m	10	Upright neutral faces	Inverted neutral faces	Bilateral lateral areas	Right lateral areas in response to upright faces as compared to neutral faces

HbO₂ = oxygenated hemoglobin; HbR = deoxygenated hemoglobin; HbT = total hemoglobin; m = months; d = days.

Table 3. Summary of NIRS Studies Done in Infants and Children up to the Age of 2 Years to Study Auditory Emotional Processing

Author, Year, Journal	Age of Participants	Number of Participants	Stimuli	Comparison / Contrast	Probe Location	Activated Brain Area (Increase in HbO ₂ and/or HbT/Decrease in HbR)
2017, Zhang et al, <i>Neuroscience Letters</i>	Neonates (2-6 d)	18	Pseudosentences of fearful, angry, and happy prosodies	Neutral prosodies	Bilateral frontal and temporal cortices	<ol style="list-style-type: none"> 1. Right temporal cortex (mainly located in the middle temporal gyrus and superior temporal gyrus) in response to emotional, relative to neutral, prosody 2. Right parietal area (approximately located in the supramarginal gyrus) in response to fearful, relative to happy and neutral, prosody
2014, Imafuku et al, <i>Neuroimage</i>	6 m infants and their mothers	17 (6 m)	Audio recordings of the infants' first names and other names spoken by their mothers	Audio recordings of the infants' first names and other names spoken by strangers	Frontal cortical areas	Dorsal medial prefrontal cortex activation in infants in response to hearing their own names, especially, when spoken by their mothers
2013, Naoi et al, <i>Frontiers in Psychology</i>	Full-term and preterm infants	25 (full-term infants) and 25 (preterm infants)	Infant-directed and adult-directed speech	Nonspeech auditory stimuli	Bilateral frontotemporal, temporal, and temporoparietal regions	Bilateral frontotemporal, temporal, and temporoparietal regions, both in full-term and preterm infants in response to infant-directed speech as compared to adult-directed speech
2012, Naoi et al, <i>Neuroimage</i>	4-13 m	48	Infant-directed speech from own mothers	Infant-directed speech from unfamiliar mothers	Bilateral frontal and temporal areas	Frontal cortex in response to infant-directed speech from their own mothers as compared to unfamiliar mothers
2012, Sato et al, <i>Human Brain Mapping</i>	Newborns	17	Forward speech in maternal language	Backward speech in maternal language and forward speech in foreign language	Whole-head	<ol style="list-style-type: none"> 1. All sound stimuli showed significant activation in the bilateral temporal regions and the frontal region 2. Left temporal-parietal region was significantly more active for forward maternal language
2011, Minagawa-Kawai et al, <i>Cerebral Cortex</i>	4 m	12	Native and nonnative speech sentences	Emotional voices, monkey calls, phase scrambled sounds	Bilateral temporal cortices	<ol style="list-style-type: none"> 1. Left-lateralized activation to native > nonnative speech 2. Emotional voices caused significant activation in right temporal areas
2010, Grossmann et al, <i>Neuron</i>	4 and 7 m	16 (4 m) and 16 (7 m)	Human voices and words spoken with neutral, happy, or angry prosody	Nonvocal sounds	Bilateral temporal and inferior frontal cortices	<ol style="list-style-type: none"> 1. Bilateral superior temporal cortex in response to voices in 7 m (and not 4 m) 2. Right inferior frontal cortex in response to words with happy prosody in 7 m
2009, Saito et al, <i>Early Human Development</i>	Premature infants in the age from 18 to 81 days	26	Mother's voice and female nurse's voice	Computer-generated white noise	Bilateral frontal areas	Mother's voice activated the left frontal area more than it did the right, whereas the nurse's voice activated the right frontal area more than it did the left
2007, Saito et al, <i>Archives of Disease in Childhood. Fetal and Neonatal Edition.</i>	2-9 d	20	Infant-directed speech (IDS)	Adult-directed speech (ADS)	Left and right sides of forehead over the eyebrows	Frontal areas in response to IDS rather than ADS

(Continued)

Table 3. Continued

Author, Year, Journal	Age of Participants	Number of Participants	Stimuli	Comparison / Contrast	Probe Location	Activated Brain Area (Increase in HbO ₂ and/or HbT/Decrease in HbR)
2003, Peña et al, <i>Proceedings of the National Academy of Sciences of the United States of America</i>	2-5 d	12	Normal IDS	Reverse speech and silence	Bilateral temporal areas	Left temporal areas in response to normal speech than reverse speech or silence

HbO₂ = oxygenated hemoglobin; HbR: deoxygenated hemoglobin; HbT: total hemoglobin; m = months; d = days.

audiovisual infant-directed style speech in nonnative as compared to native speech in right anterior areas as compared to older infants (7-10-month old and 11-14-month old). This is possibly because they focus more on the spectral components of the talking face (prosodic components and emotional information) that typically engage right hemispheric processing.⁵⁵ Right superior temporal sulcus–temporoparietal junction (STS-TPJ) activation has been reported in 12-14-month-old infants in response to live social stimuli (adults reading a picture book vs. singing nursery rhymes with gestures) as compared to baseline (adults showing infants a toy without eye contact or speech).⁵⁶ Thus, it seems that STS-TPJ area is already specialized in children older than 1 year of age for processing social cues from the environment. Table 4 provides a detailed summary of the reviewed NIRS studies on emotional processing using audiovisual stimuli in children up to 2 years of age.

Emotionally Relevant Olfactory, Tactile, and Noxious Stimuli

Maternal breast milk odor has been noted to cause activation in the orbitofrontal cortex and left prefrontal cortex in newborns.⁵⁷⁻⁶⁰ Jönsson et al reported that touch with emotional valence (affective touch) causes temporal cortex and insular cortex activation as compared to nonaffective touch in 2-month-old infants.⁶¹ Affective touch is seen to cause activation in the bilateral anterior prefrontal cortices in 10-month-old infants, but not in 3- or 6-month-old infants.⁶² Interestingly, Miguel et al observed somatosensory activation to both affective and discriminative touch, but no activation to these stimuli in temporal regions/pSTS in 7-month-old infants. Therefore, the authors suggest that 7-month-old infants do not yet recruit socioemotional brain areas in response to affective touch.⁶³

Somatosensory cortices activation has been noted in response to painful stimuli such as venipuncture or heel lance in infants.⁶⁴⁻⁶⁶ Although, some studies report no significant differences in cortical responses during painful stimuli in neonates by prior breastfeeding and sucrose administration.^{67,68} However, recent studies show that skin-to-skin contact with their mothers reduces contralateral somatosensory activation during venipuncture in premature infants. This implies that skin-to-skin contact is an easy method by which parents can also get more involved in their infants' care and pain management.⁶⁹ Recent studies link aberrant emotional processing has been linked to developmental disorders with impairments in social interaction and communication such as autism spectrum disorder (ASD).⁷⁰⁻⁷³ Table 4 provides a detailed summary of the reviewed NIRS studies using the olfactory, tactile, and noxious

stimuli for investigating emotional processing in children up to 2 years of age.

Methodological Considerations and Limitations

Most of the NIRS studies on emotional processing in children have been done in infants, and visual and auditory stimuli are the most commonly used stimuli. However, there are few studies done in children 1 to 2 years of age. This challenging age group can provide an interesting window to study how emotional circuits are formed in the early years of life and enable us to be social entities later on. Thus, there is a need for further studies on emotional processing in toddlers, and NIRS can prove to be an important tool in this pursuit. Future studies should consider the possibility of combining auditory and visual stimuli and the inclusion of the less-studied stimuli (such as touch, pain, and olfactory). This might prove fruitful because, in the real world, we are usually exposed to stimuli from two or more sensory modalities simultaneously.

However, like any other method, there are several limitations with NIRS as well. The NIRS signal integrates a volume of tissue that is not precisely known, given the uncertainties in the optical properties of the underlying tissue. Other difficulties with functional NIRS studies include the effect of background physiology,⁷⁴ sleep stage,^{75,76} and artifacts due to motion and hair (especially with dark hair). NIRS outcome is variable due to its sensitivity to movement, limited sensitivity to deeper areas of the brain, and difficulties in dealing with the effects of scalp circulation. Additionally, in terms of studying task-related responses, the background physiology can be considered an artifact, which makes the analysis more complicated. Due to thin scalps and relatively high partial volume of the brain in fNIRS measurements of infants and small children, the proportion of unwanted baseline physiology originating in nonbrain tissue in the signal is smaller than in the adult fNIRS studies.⁷⁴ Motion artifacts are common in 3-12-month-old infants, but in newborns, the child typically sleeps most of the time and motion artifacts leading to data exclusion are less common.⁷⁷

When doing task-related hemodynamic studies, the resting state hemodynamics can confound the results, and a few precautions are needed to get accurate task-related responses. First, the timing of the stimulus presentation should be randomized to avoid the subject anticipating the stimulus and to avoid possible phase-locking of the resting state hemodynamics to the stimulus presentation. Second, the number of repetitions of the stimulus should be large enough to obtain statistical significance for the difference between stimulus conditions.

Table 4. Summary of NIRS Studies Done in Infants and Children UP TO THE Age of 2 Years to Audiovisual, Tactile, Olfactory, and Noxious Processing

Type of Stimuli	Author, Year, Journal	Age of Participants	Number of Participants	Stimuli	Comparison/ Contrast	Probe Location	Activated Brain area (Increase in HbO ₂ and/or HbT/Decrease in HbR)
Audiovisual	2018, Hakuno et al, <i>Neurophotomics</i>	12-14 m	30	Two social scenarios (ie, reading a picture book vs. singing nursery rhymes with gestures)	Baseline (ie, showing infants a toy without eye contact or speech)	Right temporal lobe	Right superior temporal sulcus-temporoparietal junction (STS-TPJ) in response to live social stimuli as compared to baseline
	2017, Lloyd-Fox et al, <i>Developmental Cognitive Neuroscience</i>	0-2 m, 4-8 m, 9-13 m, 12-16 m, and 18-24 m	18 (0-2 m), 24 (4-8 m), 25 (9-13 m), 19 (12-16 m), 16 (18-24 m)	Social visual and auditory stimuli	Nonsocial visual and auditory stimuli	Right hemisphere	0-2 months of age infants exhibit nonsocial auditory selectivity, an effect that persists until 4-8 months when there is a transition to greater social stimulus selectivity. Socially selective brain responses from 9 to 24 months of life to both the visual and auditory stimuli
	2015, Urakawa et al, <i>Brain Topography</i>	7 m	11	Visual (direct gaze) with auditory (recorded infant-directed speech) during social interactive play	Visual (averted gaze) with auditory (recorded infant-directed speech)	Prefrontal cortex	Dorsomedial prefrontal cortex in response to social play with a partner's direct gaze compared to an averted gaze
	2014, Lloyd-Fox et al, <i>Scientific Reports</i>	4-8 m	24	Videos of adults performing social movements. Three conditions: visual-social (silent) auditory vocal and auditory nonvocal	Baseline	Right hemisphere	Posterior superior temporal and inferior frontal cortex to the visual and auditory social stimuli
	2014, Fava et al, <i>Brain Sciences</i>	3-6 m, 7-10 m, and 11-14 m	35	Audiovisual infant-directed style speech in both native and unfamiliar language	Visual-only (animated shapes) and alternate speech type	Bilateral temporal cortices	<ol style="list-style-type: none"> 3-6 m infants produced a greater overall response in right anterior areas (nonnative > native) 7-10 m infants showed significant activation in left posterior area (native > nonnative) 11-14 m infants showed a left lateralized response in both anterior and posterior regions of left hemisphere (native > nonnative)
	2009, Bortfeld et al, <i>Developmental Neuropsychology</i>	6-9 m	21	Speech coupled with visual stimuli (audiovisual condition)	Visual stimuli alone (visual only condition)	Bilateral temporal regions	Left temporal cortex in response to audiovisual as compared to only visual

(Continued)

Table 4. Continued

Type of Stimuli	Author, Year, Journal	Age of Participants	Number of Participants	Stimuli	Comparison/ Contrast	Probe Location	Activated Brain area (Increase in HbO ₂ and/or HbT/Decrease in HbR)
	2007, Bortfeld et al, <i>Neuroimage</i>	6-9 m	35	Linguistic stimuli paired with visual stimuli	Visual stimuli	Bilateral temporal and occipital regions	Both occipital and temporal regions in response to audiovisual as compared to only occipital in response to visual stimuli
Tactile	2018, Jönsson et al, <i>Neuroimage</i>	2 m	16	Slow stroking	Fast stroking	Left Temporal cortex	Left temporal cortex and insular cortex
	2017, Miguel et al, <i>Developmental Cognitive Neuroscience</i>	7 m	35	Slow stroking	Fast stroking	Somatosensory and temporal cortex	Somatosensory cortex
	2013, Kida and Shinohara, <i>Neuroscience Letters</i>	3, 6, and 10 m	32	Velvet touch	Wood	Bilateral prefrontal cortex	Bilateral anterior prefrontal cortex in 10 m (and not 3 and 6 m)
Olfactory	2017, Frie et al, <i>Cerebral Cortex</i>	Newborns	44	Odor from pure hand cleaner and adhesive remover (and after oral glucose administration)	Odor of water	Olfactory, frontal, and somatosensory cortices	1. Olfactory, frontal, and somatosensory cortices activation beginning from 31 weeks of gestation 2. Oral glucose significantly decreases cortical activation in full-term and very-preterm newborns
	2014, Frie et al, <i>Archives of Disease in Childhood</i>	Newborns	14	Maternal breast odor (cotton cloth worn by mother in her bra preceding 12 hours)	Control smell (clean cotton cloth)	Orbitofrontal gyri, prefrontal, and primary somatosensory cortices	Bilateral Orbitofrontal gyri and left prefrontal cortex
	2000, Bartocci et al, <i>Pediatric Research</i>	Neonates	23	Smell of mothers' colostrum and vanilla	Smell of distilled water	Left anterior orbito-frontal gyri	Left orbitofrontal areas
	2000, Aoyama et al, <i>Early Human Development</i>	Neonates	26	Maternal breast milk	Formula milk odor	Bilateral orbitofrontal regions	Orbitofrontal region in response to breast milk
	2016, Verriotis et al, <i>eNeuro</i>	newborns	30	Heel lance	Innocuous tactile stimulation	Primary somatosensory cortex	Contralateral somatosensory cortex
Noxious	2016, Olsson et al, <i>Acta Paediatrica</i>	Neonates (26-35 weeks of gestation)	10	Venepuncture when infants were in skin-to-skin contact with their mothers	Venepuncture when infants were lying in their incubator or crib and sham procedure	Bilateral somatosensory cortices	Significantly smaller activation in the contralateral somatosensory cortex during venepuncture when the infants were held skin-to-skin with their mothers, compared to when they were laying in their crib or incubator

(Continued)

Table 4. Continued

Type of Stimuli	Author, Year, Journal	Age of Participants	Number of Participants	Stimuli	Comparison/Contrast	Probe Location	Activated Brain area (Increase in HbO ₂ and/or HbT/Decrease in HbR)
	2014, Roué et al, <i>Archives of Disease in Childhood</i>	Newborns	113	Breastfeeding during venepuncture	Sucrose administration during venepuncture	Bilateral somatosensory cortices	No differences were found between sucrose and breastfeeding on specific-pain brain activity during venepuncture
	2013, Bembich et al, <i>Neonatology</i>	Newborns	10	Heel prick	Baseline	Bilateral parietal, temporal, and frontal cortices	Bilateral posterior regions of parietal cortex and right frontal cortex
	2006, Slater et al, <i>The Journal of Neuroscience</i>	Neonates	18	Heel lance	Innocuous tactile stimulation	Bilateral somatosensory cortices	Contralateral somatosensory cortex
	2006, Bartocci et al, <i>Pain</i>	Preterm neonates	40	Venepuncture	Innocuous tactile stimulation	Bilateral somatosensory cortices	Contralateral somatosensory cortex

HbO₂ = Oxygenated hemoglobin; HbR = deoxygenated hemoglobin; HbT = total hemoglobin; m = months; d = days.

Moreover, several recent studies have shown certain problematic aspects with NIRS measurements, such as systemic artifacts^{78,79} or the differential pathlength factors (DPFs).⁸⁰ DPF can be measured using time- or frequency-domain instrumentation, but continuous wave NIRS users have to rely on the literature values for this parameter. On the other hand, the unknown partial volume fraction of the activated tissue causes greater uncertainties in the response magnitude than the DPF, and some researchers choose to report their results in units of μmm instead of μM . The systemic responses can be estimated if detectors with short source-detector separations are available and regressed out using, eg, superficial signal regression (SSR).⁸¹ Alternatively, if diffuse optical tomography (DOT) instrumentation, permitting the recording of a large range of source-detector separations, is used, it is possible to reduce the effects of superficial physiology on brain responses by using 3-dimensional image reconstruction and analyzing the brain voxel data for activations.⁶¹ This approach can also extend the field of view (FOV) to most of the cerebral cortex in 0–2 month infants with potentially numerous applications. By using a suitable experimental design, which avoids the subject's heart rate being elevated due to stress, stimulus-coupled systemic effects can be minimized. Furthermore, HbR concentration changes in infants may not follow the typical pattern and may depend on the subject's age, the region studied, and sleep and/or sedation state, among other factors.^{82–85} Reporting all three parameters (HbO₂, HbT, and HbR) is useful to provide a reference of the response patterns in different situations to aid interpretability and enable later meta-analysis.

Conclusions

Bilateral temporal areas are implicated in most emotional processing studies in children, independent of the stimuli used. Currently, it remains unknown which neural activation patterns reflect maturation and at what age the emotional encoding reaches those typically seen in adults. Longitudinal studies

are currently scarce and are clearly needed to answer these questions better. Most NIRS studies on emotional processing in children have been done in infants, while there are limited studies carried out in children 1 to 2 years of age (6/50 studies reviewed). Variance in typical emotional processing may have far-reaching implications for the later development of emotional, social, and cognitive skills in children. In addition to longitudinal repeated measures, functional neuroimaging might prove an important tool to study the associations between the early pattern of neural responses and socio-emotional development later in life.

References

1. Etkin A, Buechel C, Gross JJ. The neural bases of emotion regulation. *Nat Rev Neurosci* 2015;16:693-700.
2. Herrmann MJ, Huter T, Plichta MM, et al. Enhancement of activity of the primary visual cortex during processing of emotional stimuli as measured with event-related functional near infrared spectroscopy and event-related potentials. *Hum Brain Mapp* 2008;29:28-35.
3. Plichta M, Gerdes A, Alpers G, et al. Auditory cortex activation is modulated by emotion: a functional near-infrared spectroscopy (fNIRS) study. *Neuroimage* 2011;55:1200-7.
4. Berridge KC, Kringelbach ML. Neuroscience of pleasure and displeasure. *Curr Opin Neurobiol* 2013;23:294-303.
5. Kringelbach M, O' Doherty J, Rolls ET, et al. Activation of the human orbitofrontal cortex to a liquid food stimulus is correlated with its subjective pleasantness. *Cereb Cortex* 2003;13:1064-71.
6. Kringelbach M, Rolls ET. The functional neuroanatomy of the human orbitofrontal cortex: evidence from neuroimaging and neuropsychology. *Prog Neurobiol* 2004;72:341-72.
7. Hirayama K. Thalamus and emotion. *Brain Nerve* 2015;67:1499-508.
8. Herrmann M, Ehls A, Fallgatter A. Prefrontal activation through task requirements of emotional induction measured with NIRS. *Biol Psychol* 2003;64:255-63.
9. Tupak SV, Dresler T, Guhn A, et al. Implicit emotion regulation in the presence of threat: neural and autonomic correlates. *Neuroimage* 2014;85:372-9.

10. Knickmeyer RC, Gouttard S, Kang C, et al. A structural MRI study of human brain development from birth to 2 years. *J Neurosci* 2008;28:12176-82.
11. Kretschmann HJ, Kammradt G, Krauthausen I, et al. Brain growth in man. *Bibl Anat* 1986;28:1-26.
12. Deoni SCL, Mercure E, Blasi A, et al. Mapping infant brain myelination with magnetic resonance imaging. *J Neurosci* 2011;31:784-91.
13. Grossmann T, Striano T, Friederici AD. Developmental changes in infants' processing of happy and angry facial expressions: a neurobehavioral study. *Brain Cogn* 2007;64:30-41.
14. Torricelli A, Contini D, Pifferi A, et al. Time domain functional NIRS imaging for human brain mapping. *Neuroimage* 2014;85:28-50.
15. Reich G. Near-infrared spectroscopy and imaging: basic principles and pharmaceutical applications. *Adv Drug Deliv Rev* 2005;57:1109-43.
16. Moghimi S, Kushki A, Power S, et al. Automatic detection of a prefrontal cortical response to emotionally rated music using multi-channel near-infrared spectroscopy. *J Neural Eng* 2012;9:1-8.
17. Bendall RC, Eachus P, Thompson C. A brief review of research using near-infrared spectroscopy to measure activation of the prefrontal cortex during emotional processing: the importance of experimental design. *Front Hum Neurosci* 2016;10:529.
18. Nakato E, Otsuka Y, Kanazawa S, et al. When do infants differentiate profile face from frontal face? A near-infrared spectroscopic study. *Hum Brain Mapp* 2009;30:462-72.
19. Otsuka Y, Nakato E, Kanazawa S, et al. Neural activation to upright and inverted faces in infants measured by near infrared spectroscopy. *Neuroimage* 2007;34:399-406.
20. Nakato E, Otsuka Y, Yamaguchi M, et al. Perception of mother's face using near infrared spectroscopy. *J Vis* 2008;8:186.
21. Honda Y, Nakato E, Otsuka Y, et al. How do infants perceive scrambled face? A near infrared spectroscopic study. *Brain Res* 2010;1308:137-46.
22. Kobayashi M, Otsuka Y, Kanazawa S, et al. Size-invariant representation of face in infant brain. *Neuroreport* 2012;23:984-8.
23. Kobayashi M, Otsuka Y, Kanazawa S, et al. The processing of faces across non-rigid facial transformation develops at 7 month of age: a fNIRS-adaptation study. *BMC Neurosci* 2014;15:81.
24. Kobayashi M, Otsuka Y, Nakato E, et al. Do infants recognize the Arcimboldo images as faces? Behavioral and near-infrared spectroscopic study. *J Exp Child Psychol* 2012;111:22-36.
25. Kobayashi M, Otsuka Y, Nakato E, et al. Do infants represent the face in a viewpoint-invariant manner? Neural adaptation study as measured by near-infrared spectroscopy. *Front Hum Neurosci* 2011;5:153.
26. Powell LJ, Deen B, Saxe R. Using individual functional channels of interest to study cortical development with fNIRS. *Dev Sci* 2017;e12595.
27. Kobayashi M, Macchi Cassia V, Kanazawa S, et al. Perceptual narrowing towards adult faces is a cross-cultural phenomenon in infancy: a behavioral and near-infrared spectroscopy study with Japanese infants. *Dev Sci* 2016;21:e12498.
28. Carlsson J, Lagercrantz H, Olson L, et al. Activation of the right fronto temporal cortex during maternal facial recognition in young infants. *Acta Paediatr* 2008;97:1221-5.
29. Nakato E, Otsuka Y, Kanazawa S, et al. Distinct differences in the pattern of hemodynamic response to happy and angry facial expressions in infants: a near infrared spectroscopic study. *Neuroimage* 2011;54:1600-6.
30. Fox SE, Wagner JB, Shrock CL, et al. Neural processing of facial identity and emotion in infants at high-risk for autism spectrum disorders. *Front Hum Neurosci* 2013;7:89.
31. Minagawa-Kawai Y, Matsuoka S, Dan I, et al. Prefrontal activation associated with social attachment: facial-emotion recognition in mothers and infants. *Cereb Cortex* 2009;19:284-92.
32. Nakato E, Otsuka Y, Kanazawa S, et al. I know this face: neural activity during mother's face perception in 7- to 8-month-old infants as investigated by near-infrared spectroscopy. *Early Hum Dev* 2011;87:1-7.
33. Lloyd-Fox S, Blasi A, Volein A, et al. Social perception in infancy: a near infrared spectroscopy study. *Child Dev* 2009;80:986-99.
34. Farroni T, Chiarelli AM, Lloyd-Fox S, et al. Infant cortex responds to other humans from shortly after birth. *Sci Rep* 2013;3:2851.
35. Kant AV, Biro S, Levelt C, et al. Negative affect is related to reduced differential neural responses to social and non-social stimuli in 5-to-8-month-old infants: a functional near-infrared spectroscopy-study. *Dev Cogn Neurosci* 2018;30:23-30.
36. Ravicz MM, Perdue KL, Westerlund A, et al. Infants' neural responses to facial emotion in the prefrontal cortex are correlated with temperament: a functional near-infrared spectroscopy study. *Front Psychol* 2015;6:922.
37. Leve LD, Kim HK, Pears KC. Childhood temperament and family environment as predictors of internalizing and externalizing trajectories from ages 5 to 17. *J Abnorm Child Psychol* 2005;33:505-20.
38. Köchel A, Schöngäßner F, Feierl-Gsodam S, et al. Processing of affective prosody in boys suffering from attention deficit hyperactivity disorder: a near-infrared spectroscopy study. *Soc Neurosci* 2015;10:583-91.
39. Zhang D, Zhou Y, Hou X, et al. Discrimination of emotional prosodies in human neonates: A pilot fNIRS study. *Neurosci Lett* 2017;658:62-6.
40. Sato H, Hirabayashi Y, Tsubokura H, et al. Cerebral hemodynamics in newborn infants exposed to speech sounds: a whole-head optical topography study. *Hum Brain Mapp* 2012;33:2092-103.
41. Minagawa-Kawai Y, van der Lely H, Ramus F, et al. Optical brain imaging reveals general auditory and language-specific processing in early infant development. *Cereb Cortex* 2011;21:254-61.
42. Lloyd-Fox S, Blasi A, Mercure E, et al. The emergence of cerebral specialization for the human voice over the first months of life. *Soc Neurosci* 2012;7:317-30.
43. Peña M, Maki A, Kovacic D, et al. Sounds and silence: an optical topography study of language recognition at birth. *Proc Natl Acad Sci USA* 2003;100:11702-5.
44. Saito Y, Aoyama S, Kondo T, et al. Frontal cerebral blood flow change associated with infant-directed speech. *Arch Dis Child Fetal Neonatal Ed* 2007;92:F113-6.
45. Naoi N, Minagawa-Kawai Y, Kobayashi A, et al. Cerebral responses to infant-directed speech and the effect of talker familiarity. *Neuroimage* 2012;59:1735-44.
46. Naoi N, Fuchino Y, Shibata M, et al. Decreased right temporal activation and increased interhemispheric connectivity in response to speech in preterm infants at term-equivalent age. *Front Psychol* 2013;4:94.
47. Imafuku M, Hakuno Y, Uchida-Ota M, et al. "Mom called me!" Behavioral and prefrontal responses of infants to self-names spoken by their mothers. *Neuroimage* 2014;103:476-84.
48. Saito Y, Fukuhara R, Aoyama S, et al. Frontal brain activation in premature infants in response to auditory stimuli in neonatal intensive care unit. *Early Hum Dev* 2009;85:471-4.
49. Grossmann T, Oberecker R, Koch SP, et al. The developmental origins of voice processing in the human brain. *Neuron* 2010;65:852-8.
50. Bortfeld H, Wruck E, Boas DA. Assessing infants' cortical response to speech using near-infrared spectroscopy. *Neuroimage* 2007;34:407-15.
51. Bortfeld H, Fava E, Boas DA. Identifying cortical lateralization of speech processing in infants using near-infrared spectroscopy. *Dev Neuropsychol* 2009;34:52-65.
52. Urakawa S, Takamoto K, Ishikawa A, et al. Selective medial prefrontal cortex responses during live mutual gaze interactions in human infants: an fNIRS study. *Brain Topogr* 2015;28:691-701.
53. Lloyd-Fox S, Begus K, Halliday D, et al. Cortical specialisation to social stimuli from the first days to the second year of life: a rural Gambian cohort. *Dev Cogn Neurosci* 2017;25:92-104.

54. Lloyd-Fox S, Papademetriou M, Darboe MK, et al. Functional near infrared spectroscopy (fNIRS) to assess cognitive function in infants in rural Africa. *Sci Rep* 2014;4:4740.
55. Fava E, Hull R, Bortfeld H. Dissociating cortical activity during processing of native and non-native audiovisual speech from early to late infancy. *Brain Sci* 2014;4:471-87.
56. Hakuno Y, Pirazzoli L, Blasi A, et al. Optical imaging during toddlerhood: brain responses during naturalistic social interactions. *Neurophotonic* 2018;5:1.
57. Aoyama S, Toshima T, Saito Y, et al. Maternal breast milk odour induces frontal lobe activation in neonates: a NIRS study. *Early Hum Dev* 2010;86:541-5.
58. Bartocci M, Winberg J, Ruggiero C, et al. Activation of olfactory cortex in newborn infants after odor stimulation: a functional near-infrared spectroscopy study. *Pediatr Res* 2000;48:18-23.
59. Frie J, Kuhn P, Bartocci M, et al. Full-term newborns detect maternal breast odours at a cortical level: a multichannel Nirs study. *Arch Dis Child* 2014;99:A395.
60. Frie J, Bartocci M, Lagercrantz H, et al. Cortical responses to alien odors in newborns: an fNIRS study. *Cereb Cortex* 2017;1:1-12.
61. Jönsson EH, Kotilahti K, Heiskala J, et al. Affective and non-affective touch evoke differential brain responses in 2-month-old infants. *Neuroimage* 2018;169:162-71.
62. Kida T, Shinohara K. Gentle touch activates the prefrontal cortex in infancy: an NIRS study. *Neurosci Lett* 2013;541:63-6.
63. Miguel HO, Lisboa IC, Gonçalves ÓF, et al. Brain mechanisms for processing discriminative and affective touch in 7-month-old infants. *Dev Cogn Neurosci* 2017 [Epub ahead of print].
64. Bartocci M, Bergqvist LL, Lagercrantz H, et al. Pain activates cortical areas in the preterm newborn brain. *Pain* 2006;122:109-17.
65. Slater R, Cantarella A, Gallella S, et al. Cortical pain responses in human infants. *J Neurosci* 2006;26:3662-6.
66. Verriotis M, Fabrizi L, Lee A, et al. Mapping cortical responses to somatosensory stimuli in human infants with simultaneous near-infrared spectroscopy and event-related potential recording. *eNeuro* 2016;3:ENEURO.0026.16.2016.
67. Bembich S, Davanzo R, Brovedani P, et al. Functional neuroimaging of breastfeeding analgesia by multichannel near-infrared spectroscopy. *Neonatology* 2013;104:255-9.
68. Roué J, Rioualen S, Nowak E, et al. Sucrose versus breastfeeding for venipuncture in term infants. A randomised, prospective, controlled study with analysis of the specific cortical response. *Arch Dis Childhood* 2014;99:A183.
69. Olsson E, Ahlsén G, Eriksson M. Skin-to-skin contact reduces near-infrared spectroscopy pain responses in premature infants during blood sampling. *Acta Paediatr* 2016;105:376-80.
70. American Psychiatric Association. *Diagnostic and Statistical Manual of Mental Disorders*. 5th ed. Washington, DC: American Psychiatric Publishing; 2013.
71. Keehn B, Wagner JB, Tager-Flusberg H, et al. Functional connectivity in the first year of life in infants at-risk for autism: a preliminary near-infrared spectroscopy study. *Front Hum Neurosci* 2013;7:444.
72. Lloyd-Fox S, Blasi A, Elwell CE, et al. Reduced neural sensitivity to social stimuli in infants at risk for autism. *Proc R Soc Lond B Biol Sci* 2013;280:20123026.
73. Lloyd-Fox S, Blasi A, Pasco G, et al. Cortical responses before 6 months of life associate with later autism. *Eur J Neurosci* 2017;47:736-49.
74. White BR, Culver JP. Quantitative evaluation of high-density diffuse optical tomography: in vivo resolution and mapping performance. *J Biomed Opt* 2010;15:026006.
75. Näsi T, Virtanen J, Nojonen T, et al. Spontaneous hemodynamic oscillations during human sleep and sleep stage transitions characterized with near-infrared spectroscopy. *PLoS One* 2011;6:e25415.
76. Kotilahti K, Nissilä I, Huotilainen M, et al. Bilateral hemodynamic responses to auditory stimulation in newborn infants. *Neuroreport* 2005;16:1373-7.
77. Cristia A, Dupoux E, Hakuno Y, et al. An online database of infant functional near infrared spectroscopy studies: a community-augmented systematic review. *PLoS One* 2013;8:e58906.
78. Bauernfeind G, Böck C, Wriessnegger S, et al. Physiological noise removal from fNIRS signals. *Biomed Tech (Berl)* 2013;58:1-2.
79. Näsi T, Mäki H, Hiltunen P, et al. Effect of task-related extracerebral circulation on diffuse optical tomography: experimental data and simulations on the forehead. *Biomed Opt Express* 2013;4:412-26.
80. Schroeter ML, Zysset S, Kruggel F, et al. Age dependency of the hemodynamic response as measured by functional near-infrared spectroscopy. *Neuroimage* 2003;19:555-64.
81. Gregg NM, White BR, Zeff BW, et al. Brain specificity of diffuse optical imaging: improvements from superficial signal regression and tomography. *Front Neuroenergetics* 2010;2:14.
82. Martin E, Joeri P, Loenneker T, et al. Visual processing in infants and children studied using functional MRI. *Pediatr Res* 1999;46:135-40.
83. Marcar VL, Straessle A, Girard F, et al. When more means less: a paradox BOLD response in human visual cortex. *Magn Reson Imaging* 2004;22:441-50.
84. Marcar VL, Schwarz U, Martin E, et al. How depth of anesthesia influences the blood oxygenation level-dependent signal from the visual cortex of children. *AJNR Am J Neuroradiol* 2006;27:799-805.
85. Meek J. Basic principles of optical imaging and application to the study of infant development. *Dev Sci* 2002;5:371-80.