


BMJ Open Casting versus flexible intramedullary nailing in displaced forearm shaft fractures in children aged 7–12 years: a study protocol for a randomised controlled trial

Petra Grahn ,¹ Juha-Jaakko Sinikumpu,² Yrjänä Nietosvaara,^{1,3} Johanna Syvänen,⁴ Anne Salonen,⁵ Matti Ahonen,¹ Ilkka Helenius⁶

To cite: Grahn P, Sinikumpu J-J, Nietosvaara Y, *et al.* Casting versus flexible intramedullary nailing in displaced forearm shaft fractures in children aged 7–12 years: a study protocol for a randomised controlled trial. *BMJ Open* 2021;**11**:e048248. doi:10.1136/bmjopen-2020-048248

► Prepublication history for this paper is available online. To view these files, please visit the journal online (<http://dx.doi.org/10.1136/bmjopen-2020-048248>).

Received 20 December 2020
Accepted 03 August 2021



© Author(s) (or their employer(s)) 2021. Re-use permitted under CC BY-NC. No commercial re-use. See rights and permissions. Published by BMJ.

For numbered affiliations see end of article.

Correspondence to

Dr Petra Grahn;
petra.grahn@hus.fi

ABSTRACT

Introduction The forearm is the most common fracture location in children, with an increasing incidence. Displaced forearm shaft fractures have traditionally been treated with closed reduction and cast immobilisation. Diaphyseal fractures in children have poor remodelling capacity. Malunion can cause permanent cosmetic and functional disability. Internal fixation with flexible intramedullary nails has gained increasing popularity, without evidence of a better outcome compared with closed reduction and cast immobilisation.

Method and analysis This is a multicentre, randomised superiority trial comparing closed reduction and cast immobilisation to flexible intramedullary nails in children aged 7–12 years with >10° of angulation and/or >10 mm of shortening in displaced both bone forearm shaft fractures (AO-paediatric classification: 22D/2.1–5.2). A total of 78 patients with minimum 2 years of expected growth left are randomised in 1:1 ratio to either treatment group. The study has a parallel non-randomised patient preference arm. Both treatments are performed under general anaesthesia. In the cast group a long arm cast is applied for 6 weeks. The flexible intramedullary nail group is immobilised in a collar and cuff sling for 4 weeks. Data are collected at baseline and at each follow-up until 1 year.

Primary outcome is (1) PROMIS paediatric upper extremity and (2) forearm pronation-supination range of motion at 1-year follow-up. Secondary outcomes are Quick DASH, Paediatric Pain Questionnaire, Cosmetic Visual Analogue Scale, wrist and elbow range of motion as well as any complications and costs of treatment.

We hypothesise that flexible intramedullary nailing results in a superior outcome.

Ethics and dissemination We have received ethical board approval (number: 78/1801/2020) and permissions to conduct the study from all five participating university hospitals. Informed consent is obtained from the parent(s). Results will be disseminated in peer-reviewed publications.

Trial registration number NCT04664517.

Strengths and limitations of this study

- First randomised controlled trial (RCT) to examine the treatment and outcome of displaced both bone forearm paediatric fractures.
- Multicentre RCT with blinded outcome assessors and recruiters.
- Use of several patient-reported outcome measures as well as active and passive upper limb range of motion.
- Bone age to determine remodelling capacity.
- Patient and treating surgeons not blinded.

INTRODUCTION

The incidence of paediatric forearm fractures is increasing, and almost half of all fractures in the growing skeleton are located in the forearm.^{1–3} Angular malunion exceeding 10° can result in limited forearm rotation.^{4–6} The remodelling capacity of shaft fractures in children is poorer and less predictable than in metaphyseal and physeal fractures. More correction can be expected in children younger than 9 years and in children with fractures close to the distal physes.^{7 8} The reported angular correction rate in the diaphysis is only 1°–2° per year until the end of growth, in malrotation probably even less.^{9–11}

Active forearm rotation is restored during the first year after the fracture, after which regardless of remodelling very little change can be expected.¹² Minimal total forearm rotation for performing activities of daily living in children and adolescents is considered to be 110° (50° of supination, 65° of pronation) and in adults (50°–60° of supination and 40°–50° of pronation).^{13 14} Loss of ≤60° goes unnoticed in many patients.¹⁵

Table 1 Pros and cons of the two treatment modalities

	Pros	Cons
Cast treatment	Non-invasive Cast wedging Inexpensive	Cast complications Loss of reduction Frequent FU visits Joint stiffness
FIN treatment	Loss of reduction rare Low need for immobilisation Less FU visits Less affected ROM	Invasive Implant removal Infection Risk for tendon/nerve injury

Modified from Mehlman and Wall.¹⁶

FIN, flexible intramedullary nail; FU, follow-up; ROM, range of motion.

Good forearm function has been documented in patients with $\leq 50^\circ$ of loss in pro-supination.^{7,9}

Non-operative treatment (reduction and casting) is the golden standard in closed paediatric forearm shaft fractures, especially in children younger than 12 years of age.¹⁶ There is abundant evidence, that non-operative treatment of most forearm fractures gives satisfactory long-term cosmetic and functional outcomes.^{7, 16–19} Completely displaced both bone forearm fractures in older children and adolescents tend to be treated surgically, although evidence of successful outcome with cast treatment exists.^{20, 21} Failure of reduction after closed treatment is higher in children >10 years of age and with fractures exceeding 15° of angulation.^{22, 23}

Flexible intramedullary nailing (FIN) has become the most popular method of internal fixation of paediatric forearm shaft fractures. FIN when applied correctly is minimally invasive surgery, with low complication rates compared with open reduction and internal fixation.^{20, 24} Reported risk of iatrogenic complications varies between 9% and 31%^{7, 25–30} with local wound infections and tendon injuries being the most common. Surgical management of paediatric forearm fractures has increased $>250\%$ during the last two decades.^{31, 32} The two treatment modalities of displaced both bone forearm fractures have different benefits (table 1). Level I evidence regarding optimal treatment is missing.^{1, 20} Different patient-reported outcome measures have been used, but only few are validated.³³ The Patient-Reported Outcomes Measurement Information System (PROMIS) Paediatric Item Bank V.2.0³⁴ -Upper Extremity is validated and has been used in prior paediatric upper extremity fracture studies.³⁵

The aim of this study is to compare outcome of closed reduction and casting under general anaesthesia to internal fixation with FIN in paediatric displaced both bone forearm fractures. We hypothesise, that internal fixation of the fractures with FIN provides better functional outcome than closed reduction and cast treatment

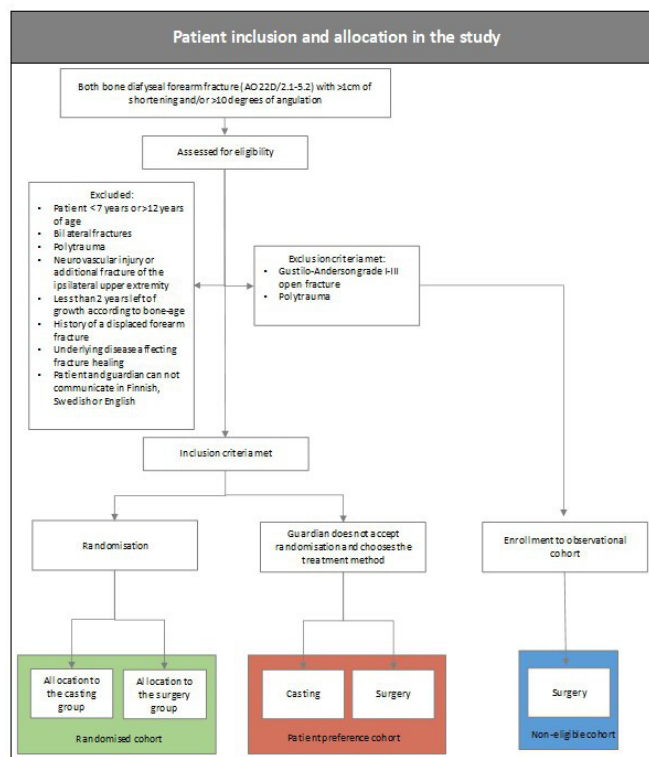


Figure 1 Eligibility screening, inclusion and exclusion criteria and patient allocation the study.

METHODS AND ANALYSIS

Study design

This is a multicentre parallel-group superiority randomised controlled trial (RCT) that complies with the Standard Protocol Items: Recommendations for Interventional Trials statement. The trial offers a patient choice arm (figure 1). The study is coordinated by Helsinki University Central Hospital, Children's Hospital unit for paediatric orthopaedics. Recruitment is done at all five Finnish university hospitals (Helsinki, Kuopio, Oulu, Tampere, Turku). The study is overseen by an external monitor provided by HUCH Clinical Research Institute (Clinical Research Institute HUCH, Helsinki, Finland, <https://hyksinstituutti.fi/services/monitoring-services/?lang=en>).

Any changes in study protocol will be uploaded to the trial registry.

Patient recruitment

A specialist of either hand surgery, paediatric surgery, paediatric orthopaedics or orthopaedics screens all patients fitting the inclusion criteria for eligibility. If inclusion criteria are met, written consent is asked from the guardian. Patients and parents are given a written informed consent regarding the trial. The patient version is age adjusted for easier understanding according to the Finnish Investigators Network for Pediatric Medicines (www.finpedmed.fi).

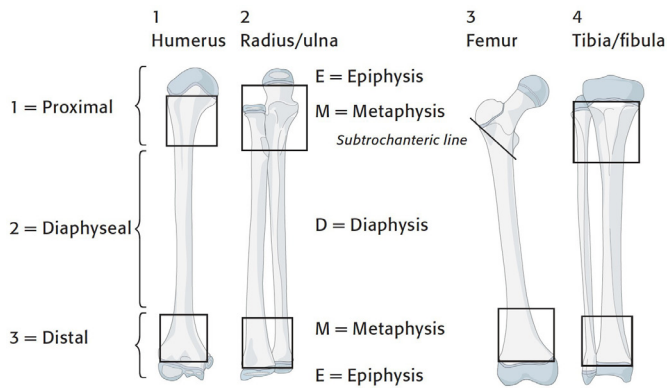


Figure 2 AO definition of the diaphyseal part of the forearm bones. Image copyright by AO Foundation, Switzerland. Figure reprinted with permission from the AO Foundation. Figure source: AO Surgery Reference (<https://surgeryreference.aofoundation.org>).

Eligibility criteria

We will include all children aged 7–12 years with open distal radial physis presenting with a both bone forearm shaft (diaphysis) fractures (AO-paediatric classification: 22D/2.1–5.2)³⁶ >10° of angulation with or without >10 mm of shortening (figures 1–3). Patients with bilateral forearm fractures, Gustilo-Anderson grade I–III open fracture,³⁷ ipsilateral upper limb fractures, neurovascular deficit, compartment syndrome, pathological fracture or patient not able to give a written informed consent will be excluded from the study (figure 1).

After agreeing to participation in the trial participants bone age is calculated from hand radiograph by the

method described by Greulich and Pyle³⁸ by an experienced paediatric radiologist.

Randomisation

Included patients receive a temporary long arm cast supporting the fracture. Randomisation is done at treatment day 1 with patient under general anaesthesia in the operating theatre with the treating surgeon opening the assigned envelope. Prior to trial recruitment randomisation is performed at the main study for the expected trial population using a computer generated list. Assigned allocation (FIN or Cast) is sealed in individual coded envelopes. Randomisation ratio is 1:1, block size 10. Each trial centre is sent one block of envelopes at a time. Allocation sequence is kept at the main study centre and is not available to recruiting specialists.

Patient's choice arm

Patients who meet inclusion criteria, but refuse participation in the RCT are offered to choose the treatment method (reduction and casting or FIN). They continue through the trial in a prospective parallel patient preference arm, following the same treatment and follow-up (FU) protocol as the randomised patients (figure 4).

Baseline

Fracture displacement, angulation and patient bone age is calculated by an experienced paediatric radiologist unrelated to the trial from the lateral and anteroposterior (AP) radiographs of the forearm and AP radiograph of the hand. Date of injury, method of injury, patient's age at time of injury, sex, injured side, hand dominance and main sport or musical instrument as well as level are documented. Motor and sensory function of the injured side as well as range of motion (ROM) of uninjured arm (pronation, elbow and wrist extension and flexion) are assessed.

Intervention

Time from injury to intervention (days), length of procedure (minutes) and surgeon's level of training (consultant, registrar) is documented.

Cast group

Fractures are reduced under general anaesthesia within 3 days from injury and a synthetic circular above elbow cast in neutral pro-supination is applied for 6 weeks.³⁹ Final fracture alignment is documented with standard AP and lateral radiographs after cast application. If failure of reduction is observed at 10 days cast is wedged in the outpatient clinic followed by control radiographs (AP and lateral) of the forearm. Transfer to FIN group is recommended to all children, whose fracture alignment is not satisfactory after wedging (figure 4). Failure of reduction is defined as >10° of angulation on one or both bones in either AP and/or lateral radiograph, with or without >10 mm of shortening as well as >10 mm shortening in one or both bones alone.

22-D Diaphyseal fractures

Simple Multifragmentary Simple Multifragmentary

Fractures of both bones

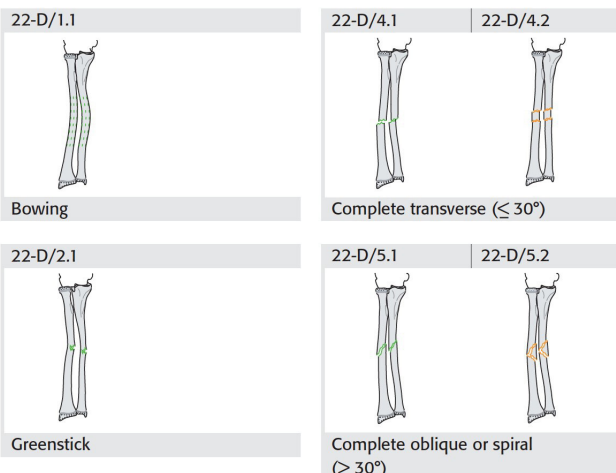


Figure 3 AO forearm diaphysis fracture classification. Image copyright by AO Foundation, Switzerland. Figure reprinted with permission from the AO Foundation. Figure source: AO Surgery Reference (<https://surgeryreference.aofoundation.org>).

Table 2 Diagram showing the data collection time points for all treatment groups; long arm cast and flexible intramedullary nail

	Data collection time points						
	Baseline	Treatment	1. Check-up 10 days	2. Check-up 6 weeks	3. Check-up 3 months	4. Check-up 6 months	5. Check-up 12 months
Long arm cast treatment							
Diagnosis, eligibility	x						
Enrolment	x						
Physical examination	x			x	x	x	x
Bone age radiograph		x					
Standard radiograph (AP and lateral)	x	x*	x	x	x	x	x
PedsQL pain	x		x	x	x	x	x
PROMIS†	x			x	x	x	x
Flexible intramedullary nail treatment							
Diagnosis, eligibility	x						
Randomisation	x						
Physical examination	x			x	x	x	x
Bone age radiograph		x					
Standard radiograph (AP and lateral)	x	x*		x	x	x	x
PedsQL pain	x		x	x	x	x	x
PROMIS	x			x	x	x	x

*Standard lateral and AP radiograph taken after fracture fixation.

†PROMIS Paediatric Upper Extremity, PedsQL Main, QuickDASH. AP, anteroposterior; PedsQL, Paediatric Quality of Life Inventory; PROM, patient-reported outcome measure.

2. Difference (%) in forearm pronation-supination ROM at 1-year FU in comparison to uninjured side.

Secondary outcome

At all FU time points; Quick DASH, PROMIS Paediatric Item Bank V.2.0-Upper Extremity PedsQL, PEDS QL Pain module, Cosmetic VAS, difference in elbow and wrist extension/flexion and forearm pronation-supination in comparison to uninjured side. Malunion, delayed union (defined as nonunion at 3 months or later), pseudoarthrosis (defined as three cortices out of four not united at 6 months or later), need for reintervention other than wedging during 1-year FU, any adverse effects (wound infection, nerve and/or tendon damage). Level of practised sport or musical instrument before and at end of trial, as well as time from injury to return to hobby is registered.

Statistical power calculation

With two primary outcomes groups size was calculated for both, and then using the one requiring a larger cohort. We aim to collect 39 patients per group, taking into account a 10% drop-out rate.

PROMIS Paediatric Item Bank V.2.0-Upper Extremity

We aim to confirm that 75% of FIN patients have a better PROMIS UE score than what the mean score of the cast patients will be assuming both groups have the same SD and scores for both groups are normally distributed.

We will need at a minimum of 35 patients per group to achieve 80% power with significance level set at 0.05 for testing superiority of the FIN patients.

To account for potential drop-outs (10%), we will collect an additional four patients per group. While this sample size calculation might not be optimal, due to assuming a normal distribution for the score, it is perhaps the only way we could estimate a required sample size in this case as we failed to find other analytical solutions for sample size estimation, and we did not have access to a similar data set to perform power simulations on.

Difference (10%) in forearm pronation-supination ROM

For difference in prosupination, we aim for a 10% difference in the forearm prosupination in benefit for FIN group. Assuming SD 10% and 80% power the required amount of patients per group would be 16.

Statistical analyses

We will perform all analyses using the intention-to-principle. In case of significant cross-over a per-protocol analysis will be added. Randomisation will even the confounding factors, but if not, these will be adjusted using the multiple regression analyses. Our null hypothesis is that with FIN fixation superior outcome with is obtained.

After the final data set is formed from the primary data, data set access will be limited to the statistician and the



authors of the final publication. The codes of the RCT arms will be known only to the research assistants until the blinded data interpretation has taken place.

If the study fails to collect the needed amount of patients as defined by the RCT protocol, patients from the 'patient preference arm' will be included in the final analysis, thus changing the status of the study from RCT to prospective.

Patient and public involvement

Patients, caregivers or public were neither involved in the development of the research questions nor the planning of the study design. They are neither involved in the recruitment nor conduct of the study. Results of the study are published only in peer-reviewed journals, no other information of the results of the study are provided to the patients or caregivers. Patients or caregivers will not take part in assessment regarding possible burden of the interventions of this study.

Time schedule

Patient enrolment started May 2021. We expect to have all patients enrolled by the end of the year 2022. The clinical part of the study will end with last FU visit of the last enrolled patient at the end of 2023.

Ethics and dissemination

We have obtained national Ethical committee approval (number: 78/1801/2020) for the study from the ethics committee of Southwest Finlands Hospital District (Hospital District of Southwest Finland Administrative Central, Kiinamyllynkatu 4-8, PO Box 52, FIN-20521 Turku, Finland). All five University hospitals (Helsinki, Kuopio, Tampere, Turku and Oulu) will apply for local institutional permission for taking part in this RCT. The study is run by Helsinki University Hospital, New Children's Hospital department of Pediatric Orthopedics and Traumatology. All patients and their guardians sign a written Informed consent before randomisation. Children with displaced forearm fractures will receive appropriate treatment. We will obtain all research data during the standard orthopaedic care of these children. Trial data will be maintained in secure storage at the research centre for 15 years after completion of study.

If at any point an imminent problem in healing is observed, warranting a change in the treatment regimen, this will be done at the discretion of the treating physician regardless of the initial treatment allocation. Trial will be ended at this time if following criteria will be met:

1. Conversion from either group will be over 25%.
2. Serious adverse effects will be observed in more than 10% of each group.

The participants will be treated according to our best knowledge during and after the trial. Patients will not receive any compensation for participation. The Finnish Patient Insurance Centre will provide compensation for treatment injuries.

The findings of this study will be disseminated through peer-reviewed publications and conference presentations. Authorship will follow the International Committee of Medical Journal Editors (ICMJE)⁴³ recommendations.

Author affiliations

- ¹Department of Pediatric Orthopedics and Traumatology, Helsinki Children's Hospital, Helsinki University Hospital and University of Helsinki, Helsinki, Finland
- ²Department of Children and Adolescents, PEDEGO unit, University of Oulu and Oulu University Hospital, Oulu, Finland
- ³Department of Pediatric Surgery, Kuopio University Hospital, Kuopio, Pohjois-Savo, Finland
- ⁴Department of Pediatric Orthopedic Surgery, Turku University Hospital, Turku, Finland
- ⁵Department of Pediatric Surgery, Tampere University Hospital, Tampere, Finland
- ⁶Department of Orthopedics and Traumatology, University of Helsinki and HUS Helsinki University Hospital, Helsinki, Finland

Collaborators Arimatas Raitio, Turku University Hospital, Department of Pediatric Orthopedic Surgery (Turku, Finland) Jenni Jalkanen, Kuopio University Hospital, Department of Pediatric Surgery (Kuopio, Finland) Jussi Korhonen, Oulu University Hospital, Department of Children and Adolescents (Oulu, Finland).

Contributors PG, J-JS, YN, MA and IH have conceived and designed the study, performed the analysis and written the paper. JS and AS have participated in writing the paper.

Funding This research did not receive grants from any funding agency in the public, commercial or not-for-profit sectors. No direct or indirect funding will be acquired from industry related to this study. The authors have not declared a specific grant for this research from any funding agency in the public, commercial or not-for-profit sectors.

Competing interests IH reports grants from Medtronic and Stryker. IH is consulting surgeon at Medtronic. JS is consulting surgeon at Bioretec. None of the other authors report any conflict of interest.

Patient consent for publication Not required.

Provenance and peer review Not commissioned; externally peer reviewed.

Open access This is an open access article distributed in accordance with the Creative Commons Attribution Non Commercial (CC BY-NC 4.0) license, which permits others to distribute, remix, adapt, build upon this work non-commercially, and license their derivative works on different terms, provided the original work is properly cited, appropriate credit is given, any changes made indicated, and the use is non-commercial. See: <http://creativecommons.org/licenses/by-nc/4.0/>.

ORCID iD

Petra Grahn <http://orcid.org/0000-0003-3018-8270>

REFERENCES

- 1 Sinikumpu J-J, Serlo W. The shaft fractures of the radius and ulna in children: current concepts. *J Pediatr Orthop B* 2015;24:200-6.
- 2 Kapila R, Sharma R, Chugh A, *et al*. Evaluation of clinical outcomes of management of paediatric bone forearm fractures using titanium elastic nailing system: a prospective study of 50 cases. *J Clin Diagn Res* 2016;10:RC12-15.
- 3 Mäyränpää MK, Mäkitie O, Kallio PE. Decreasing incidence and changing pattern of childhood fractures: a population-based study. *J Bone Miner Res* 2010;25:2752-9.
- 4 Tarr RR, Garfinkel AI, Sarmiento A. The effects of angular and rotational deformities of both bones of the forearm. An in vitro study. *J Bone Joint Surg Am* 1984;66:65-70.
- 5 Matthews LS, Kaufer H, Garver DF, *et al*. The effect on supination-pronation of angular malalignment of fractures of both bones of the forearm. *J Bone Joint Surg Am* 1982;64:14-17.
- 6 Thomas EM, Tuson KW, Browne PS. Fractures of the radius and ulna in children. *Injury* 1975;7:120-4.
- 7 Price CT, Scott DS, Kurzner ME, *et al*. Malunited forearm fractures in children. *J Pediatr Orthop* 1990;10:705-12.
- 8 Price CT. Acceptable alignment of forearm fractures in children: open reduction indications. *J Pediatr Orthop* 2010;30:S82-4.

- 9 Fuller DJ, McCullough CJ. Malunited fractures of the forearm in children. *J Bone Joint Surg Br* 1982;64:364–7.
- 10 Daruwalla JS. A study of radioulnar movements following fractures of the forearm in children. *Clin Orthop Relat Res* 1979;139:114–20.
- 11 Hughston JC. Fractures of the forearm in children. *J Bone & Joint Surg Am* 1962;44:1678–93.
- 12 Trousdale RT, Linscheid RL. Operative treatment of malunited fractures of the forearm. *J Bone Joint Surg Am* 1995;77:894–902.
- 13 Valone LC, Waites C, Tartarilla AB, et al. Functional elbow range of motion in children and adolescents. *J Pediatr Orthop* 2020;40:304–9.
- 14 Morrey BF, Askew LJ, Chao EY. A biomechanical study of normal functional elbow motion. *J Bone Joint Surg Am* 1981;63:872–7.
- 15 Högström H, Nilsson BE, Willner S. Correction with growth following diaphyseal forearm fracture. *Acta Orthop Scand* 1976;47:299–303.
- 16 Mehlman CT, Wall EJ. Diaphyseal radius and ulna fractures. In: *Rockwood and Wilkins' Fractures in Children*. Philadelphia: Wolters Kluwer Health, 2015: 413–72.
- 17 Sinikumpu J-J, Victorzon S, Antila E, et al. Nonoperatively treated forearm shaft fractures in children show good long-term recovery. *Acta Orthop* 2014;85:620–5.
- 18 Jones K, Weiner DS. The management of forearm fractures in children: a plea for conservatism. *J Pediatr Orthop* 1999;19:811–5.
- 19 Blount WP. Forearm fractures in children. 1967. *Clin Orthop Relat Res* 2005;432:4–7.
- 20 Pace JL. Pediatric and adolescent forearm fractures. *J Am Acad Orthop Surg* 2016;24:780–8.
- 21 Zions LE, Zalavras CG, Gerhardt MB. Closed treatment of displaced diaphyseal both-bone forearm fractures in older children and adolescents. *J Pediatr Orthop* 2005;25:507–12.
- 22 Bowman EN, Mehlman CT, Lindsell CJ, et al. Nonoperative treatment of both-bone forearm shaft fractures in children. *J Pediatr Orthop* 2011;31:23–32.
- 23 Kay S, Smith C, Oppenheim WL. Both-bone midshaft forearm fractures in children. *J Pediatr Orthop* 1986;6:306–10.
- 24 Shah AS, Lesniak BP, Wolter TD, et al. Stabilization of adolescent both-bone forearm fractures: a comparison of intramedullary nailing versus open reduction and internal fixation. *J Orthop Trauma* 2010;24:440–7.
- 25 Kruppa C, Bunge P, Schildhauer TA, et al. Low complication rate of elastic stable intramedullary nailing (ESIN) of pediatric forearm fractures. *Medicine* 2017;96:e6669.
- 26 Kang S-N, Mangwani J, Ramachandran M, et al. Elastic intramedullary nailing of paediatric fractures of the forearm. *J Bone Joint Surg Br* 2011;93-B:262–5.
- 27 Fernandez FF, Langendörfer M, Wirth T, et al. Failures and complications in intramedullary nailing of children's forearm fractures. *J Child Orthop* 2010;4:159–67.
- 28 Smith VA, Goodman HJ, Strongwater A, et al. Treatment of pediatric both-bone forearm fractures. *J Pediatr Orthop* 2005;25:309–13.
- 29 Salonen A, Salonen H, Pajulo O. A critical analysis of postoperative complications of antebraechium ten-nailing in 35 children. *Scand J Surg* 2012;101:216–21.
- 30 Antabak A, Luetic T, Ivo S, et al. Treatment outcomes of both-bone diaphyseal paediatric forearm fractures. *Injury* 2013;44 Suppl 3:S11–15.
- 31 Helenius I, Lamberg TS, Kääriäinen S, et al. Operative treatment of fractures in children is increasing. *J Bone Joint Surg Am* 2009;91:2612–6.
- 32 Sinikumpu J-J, Lautamo A, Pokka T, et al. The increasing incidence of paediatric diaphyseal both-bone forearm fractures and their internal fixation during the last decade. *Injury* 2012;43:362–6.
- 33 Marson BA, Craxford S, Deshmukh SR, et al. Quality of patient-reported outcomes used for quality of life, physical function, and functional capacity in trials of childhood fractures. *Bone Joint J* 2020;102-B:1599–607.
- 34 Irwin DE, Gross HE, Stucky BD, et al. Development of six PROMIS pediatrics proxy-report item banks. *Health Qual Life Outcomes* 2012;10:10–22.
- 35 Gerull WD, Okoroafor UC, Guattery J, et al. Performance of pediatric PROMIS cats in children with upper extremity fractures. *Hand* 2020;15:194–200.
- 36 AO pediatric comprehensive classification of long bone fractures (PCCF). *J Orthop Trauma* 2018;32 Suppl 1:S117–40.
- 37 Gustilo RB, Anderson JT. Prevention of infection in the treatment of one thousand and twenty-five open fractures of long bones: retrospective and prospective analyses. *J Bone Joint Surg Am* 1976;58:453–8.
- 38 *Radiographic atlas of skeletal development of the hand and wrist* 1959
- 39 Noonan KJ, Price CT. Forearm and distal radius fractures in children. *J Am Acad Orthop Surg* 1998;6:146–56.
- 40 Korhonen L, Pokka T, Holappa A, et al. The measurement methods of movement and grip strength in children with a previous upper extremity fracture: a comparative, prospective research. *Scand J Surg* 2020;109:351–8.
- 41 Beaton DE, Wright JG, Katz JN, et al. Development of the quickdash: comparison of three item-reduction approaches. *J Bone Joint Surg Am* 2005;87:1038–46.
- 42 Varni JW, Seid M, Rode CA. The PedsQL: measurement model for the pediatric quality of life inventory. *Med Care* 1999;37:126–39.
- 43 International Committee of Medical Journal Editors. Defining the role of authors and contributors. Available: <http://www.icmje.org/recommendations/browse/roles-and-responsibilities/defining-the-role-of-authors-and-contributors.html>