




Available online at  
**ScienceDirect**  
www.sciencedirect.com

Elsevier Masson France  
**EM|consulte**  
www.em-consulte.com



Original Article

## The outcomes of recurrent wide-necked intracranial aneurysms treated with the Woven EndoBridge (WEB): A retrospective bicenter study<sup>☆</sup>

Kemal Alpay<sup>a,\*</sup>, Alberto Nania<sup>b</sup>, Riitta Parkkola<sup>c</sup>, Jonathan Downer<sup>b</sup>, Antti Lindgren<sup>d,e,f</sup>, Riitta Rautio<sup>a</sup>

<sup>a</sup> Department of Radiology, Turku University Hospital, Turku, Finland

<sup>b</sup> Department of Clinical Neurosciences, Western General Hospital, Edinburgh, United Kingdom

<sup>c</sup> Department of Radiology, Turku University Hospital and Turku University, Turku, Finland

<sup>d</sup> Department of Clinical Radiology, Kuopio University Hospital, Kuopio, Finland

<sup>e</sup> Department of Neurosurgery, Kuopio University Hospital, Kuopio, Finland

<sup>f</sup> Institute of Clinical Medicine, School of Medicine, Faculty of Health Sciences, University of Eastern Finland, Kuopio, Finland

### INFO ARTICLE

Historique de l'article :  
Disponible sur Internet le xxx

Keywords :  
WEB  
Aneurysm  
Endovascular treatment  
Recurrence

### ABSTRACT

**Background.** – The Woven EndoBridge (WEB) is a device for the treatment of intracranial wide-necked bifurcation aneurysms. The safety and effectiveness of WEB for intracranial aneurysms have both been evaluated in previous trials. Our aim was to study the outcomes of recurrent intracranial aneurysms (IAs) treated with WEB.

**Methods.** – Clinical and radiological outcomes of patients with a wide-necked aneurysm recurrence, which was treated with WEB device, were assessed. Imaging follow-up was performed with digital subtraction angiography and/or magnetic resonance angiography. Aneurysm occlusion was determined using by the Raymond-Roy Occlusion Classification (RROC). RROC 1 and RROC 2 were considered as adequate radiological outcome.

**Results.** – Twenty-two patients with 23 recurrent IAs were treated with WEB. Of which, 17 of recurrent IAs (74%) previously treated by coiling, three (13%) by clipping and three (13%) by WEB. The most common location of the recurrent IA was the middle cerebral artery (n = 10, 43%). Endovascular treatment with WEB alone was suitable for 20 recurrent IAs (87%). Ancillary devices were also used: coils in two (9%), and a stent in one (4%). Radiological follow-up results available for all patients (range: 3–60 months; median 24 months). Adequate occlusion (RROC I and II) was achieved in 20 recurrent IAs (87%). A hemorrhagic complication occurred 2 weeks post treatment in one patient (5%).

**Conclusions.** – WEB could be an effective treatment with low rates of complications for challenging cases of recurrent wide-necked IAs.

© 2021 The Author(s). Publié par Elsevier Masson SAS. Cet article est publié en Open Access sous licence CC BY (<http://creativecommons.org/licenses/by/4.0/>).

### Introduction

Coiling and clipping have been mainstay treatments for intracranial aneurysms (IAs). Despite advances in coil technology and

microsurgical procedures, the IA recurrence rate has been estimated to be 20% after coiling and 3%–5% after clipping.<sup>1–3</sup> The recurrence rate is higher after the endovascular treatment (EVT) of wide-necked aneurysms.<sup>4</sup> It is important that recurrent IAs should be treated because of the risk of bleeding. However, it is estimated that every tenth IAs treated with coiling may require re-treatment.<sup>1</sup> The decision for re-treatment and the method to be utilized are based on clinical practice and can vary from clinic to clinic. Possible treatment methods for recurrent IAs are coiling, stent assisted coiling (SAC), flow diverting and microsurgical clipping.

Woven EndoBridge (WEB [Sequent Medical, Aliso Viejo, California, USA]) is a device that has been developed for the treatment of intracranial wide-necked bifurcation aneurysms. WEB functions as

Abbreviations: IA, intracranial aneurysms

EVT, endovascular treatment

RROC, Raymond and Roy occlusion classification.

<sup>☆</sup> Some results of the study were presented at ESMINT congress on 4th of September 2019 in a plenary session.

\* Corresponding author at: TYKS T-hospital, E Wing, 4th floor, Hämeentie 11, PO Box 52, 20521, Turku, Finland.

Adresse e-mail : [kemal@utu.fi](mailto:kemal@utu.fi) (K. Alpay).

<https://doi.org/10.1016/j.neurad.2021.05.008>

0150-9861/© 2021 The Author(s). Published by Elsevier Masson SAS. This is an open access article under the CC BY license (<http://creativecommons.org/licenses/by/4.0/>).

an intrasaccular flow disrupter into the aneurysm. It was first introduced to the market in 2011, and since then, an increasing number of aneurysms have been treated with WEBs. The safety and effectiveness of the WEB have been evaluated in the European Good Clinical Practice (GCP) studies and the WEB Intrasaccular Therapy (WEB-IT) study.<sup>5,6</sup> WEB has been used for both unruptured and ruptured intracranial aneurysms.<sup>7</sup> There are only three retrospective studies in the literature examining the effectiveness, safety and outcomes of WEB in the treatment of recurrent IAs.<sup>8–10</sup> Here, we report our experience in the treatment of recurrent IAs with WEB at two neurointervention centers.

## Materials and methods

### Study population

We retrospectively collected the data of patients with recurrent IAs treated with WEB between 2014 and 2020. Digital subtraction angiography (DSA) was used to decide whether WEB was a feasible treatment for these cases of recurrent wide-necked IA. The recurrent IAs were considered wide-necked, if the neck width was >4 mm and/or the dome-to-neck ratio was <2. All procedure related complications (i.e., transient ischemic attack and ischemic or hemorrhagic stroke) were recorded in the electronic patient file database. Thrombosis in aneurysms was detected using magnetic resonance angiography (MRA).

### Neurointerventions

All possible treatment methods for recurrent IAs (i.e., coiling, stent assisted coiling, balloon assisted coiling, microsurgical clipping) were considered and discussed at a multidisciplinary meeting. WEB was selected for recurrent wide-necked bifurcation aneurysms, which were considered difficult to treat using conventional methods. Flow diversion treatment was only considered for side-wall aneurysms.

All neurointerventions were carried out via triaxial femoral access or radial access in a bi-plane angiographic suite (Siemens Artis Zee biplane). All patients were under general anesthesia during the interventions. The sizing based on only three-dimensional angiography images could not be reliable due to artefacts from clips and coils, the operator measured the dimensions of the recurrent IA using both three-dimensional and two-dimensional angiography images to assess the optimal size of the WEB. In accordance with the manufacturer's guidelines, the WEBs were delivered through an appropriate size VIA microcatheter (Sequent Medical, Aliso Viejo, California, USA). After the interventions, all patients were followed-up in the hospital to monitor for complications.

### Clinical and radiological follow-up

All patients were scheduled for radiological and clinical follow-up after the treatment with WEB. The first radiological follow-up was scheduled either as a DSA or MRA between two- and six-months post-treatment according to institutional protocols. Subsequently, the remainder of the radiological follow-up was performed using MRA. Radiological outcomes were assessed according to the Raymond and Roy Occlusion Classification (RROC). RROC classes I and RROC II were considered to be adequate occlusion, whereas class III was assessed as an aneurysm remnant. Clinical follow-up was performed in the outpatient clinic at either three or six months after the intervention, and clinical outcomes were assessed according to the Modified Rankin Scale (mRS) score.

### Anti-aggregation treatment

All patients received heparin (dosage; 5000 IU–10,000 IU) during the neurointervention in order to double the activated clotting time from the baseline. Cases 12–22 were loaded with 600 mg of clopidogrel and 600 mg of acetylsalicylic acid (ASA) pre-intervention, and the operator decided depending on the position of the WEB in the aneurysm, whether acetylsalicylic acid (ASA) and/or Clopidogrel was to be continued for either two or six weeks after the WEB embolization. In one case in which an ancillary stent (case 5) was inserted, dual antiplatelet therapy was initiated immediately, comprising 10 mg of prasugrel for 6 weeks and ASA for six months. One patient (Case 8) was placed on dual antiplatelet therapy pre-intervention, i.e., 75 mg of Clopidogrel and 100 mg of ASA, because that patient had another aneurysm that was treated with a flow diverter in the same session; dual antiplatelet therapy was then continued for 6 months post-intervention.

### Statistical analysis

Descriptive statistics were used. Categorical variables were presented as numbers and percentages. Continuous variables were presented as the median with ranges.

### Ethical aspects

Local institutional review board waived the need for formal consent for this retrospective registry study. The study permission approved by the local institutional review board of the Hospital District of Southwest Finland (T011/014/18). The Academic and Clinical Central Office for Research and Development (ACCORD) for the University of Edinburgh and NHS Lothian approved data sharing for this study.

## Results

### Patient and aneurysm characteristics

Twenty-two patients (68% females; median: 53 years; range 43–69) with 23 recurrent IAs were included. Seventy-eight percent of aneurysms (n = 18) had ruptured previously. The most common location of the aneurysm was the middle cerebral artery (n = 10, 43%). The median width of the neck in the recurrent IAs was 5 mm (range: 2–8 mm), and all of the recurrent IAs (n = 23) were wide-necked. Initially, 74% of recurrent IAs (n = 17) had been treated by coiling, 13% (n = 3) by clipping, and the remaining three aneurysms (13%) by WEB. The median duration from the first treatment to re-treatment with WEB was four years (range: 2–23 years). Detailed information on the characteristics of the patients and their aneurysms is provided in [Table 1](#).

### Endovascular treatment

EVT with WEB alone was suitable for 87% of the recurrent IAs (n = 20). Ancillary devices (coils or stents) were used in the treatment of three recurrent IAs. In 9% of the recurrent IAs (n = 2), coils were used to ensure occlusion of the aneurysm, and in 4% of recurrent IAs (n = 1), a stent (4%) was used due to prolapse of the WEB within the parent artery. Detailed information on EVT with WEB is shown in [Table 2](#).

### Radiological follow-up and outcome

Radiological follow-up data were available for all recurrent IAs (n = 23, median 24 months, range: 3–60 months) ([Table 2](#)). At the

**Table 1**  
Aneurysm and initial treatment characteristics.

No	Localization	Partially thrombosed	RA/UA	Initial treatment	Interval between initial treatment and re-treatment with WEB (years)
1	Basilar tip	Yes	RA	Clipping	23
2	MCA/MCA	No	UA/UA	Coiling/Coiling	7
3	MCA	No	RA	Clipping	8
4	MCA	Yes	RA	Coiling	4
5	MCA	No	RA	Coiling	2
6	MCA	No	UA	Coiling	13
7	MCA	Yes	UA	WEB	4
8	MCA	No	UA	Coiling	2
9	ACom	No	RA	Clipping	22
10	ACom	No	UA	WEB	4
11	MCA	Yes	UA	WEB	2
12	PCom	No	RA	Coiling	5
13	Basilar tip	No	RA	Coiling	10
14	Acom	No	RA	Coiling	2
15	Acom	No	RA	Coiling	4
16	Pericallosal	No	RA	Coiling	4
17	MCA	No	RA	Coiling	2
18	Acom	No	RA	Coiling	4
19	Basilar tip	No	RA	Coiling	7
20	Pericallosal	No	RA	Coiling	4
21	Acom	No	RA	Coiling	7
22	Acom	No	RA	Coiling	7

MCA, middle cerebral artery; Acom, anterior communicating artery; Pcom, posterior communicating artery; RA, ruptured aneurysm; UA, unruptured aneurysm.

**Table 2**  
Treatment characteristics and radiological follow-up.

No	Type and size of WEB	Ancillary devices	Size of recurrence (maximal width × maximal height)	Width of neck	Post procedural antithrombotic medication (duration)	Follow-up (months)	Radiological outcome
1	SL 10 × 7 mm	Coils	15 × 19 mm	7 mm	Aspirin 100 mg (4 weeks)	53	RROC 3
2	SL 10 × 6 mm/9 × 7 mm	None	9 × 11 mm/10 × 9 mm	8 mm/7 mm	Aspirin 100 mg (permanent)	60	RROC 1/RROC 2
3	SL 6 × 3 mm	None	5 × 5 mm	5 mm	Aspirin 100 mg (4 weeks)	60	RROC 1
4	SL 8 × 4 mm	Coils	9 × 10 mm	6 mm	None	18	RROC 3
5	SL 5 × 3 mm	Stent	3.5 × 3 mm	4 mm	Prasugrel 10 mg (4 weeks) + Aspirin 100 mg (6 months)	25	RROC 1
6	SL 10 × 6 mm + SL 6 × 3 mm	None	8 × 12 mm	5 mm	Aspirin 100 mg (6 weeks)	24	RROC 1
7	SL 11 × 7 mm	None	10 × 8 mm	5 mm	None	24	RROC 3
8	SL 4 × 2 mm	None	4 × 4 mm	3 mm	Plavix 75 mg (6 months) + Aspirin 100 mg (12 months)	24	RROC 1
9	SL 5 × 2 mm	None	4 × 2 mm	4 mm	None	24	RROC 2
10	SL 5 × 2 mm	None	4 × 4 mm	3 mm	None	24	RROC 1
11	SL 6 × 3 mm	None	4.5 × 6 mm	5 mm	None	6	RROC 1
12	SL 4 × 2 mm	None	5.1 × 3 mm	3 mm	None	6	RROC 2
13	SL 4.5 × 3 mm	None	5.9 × 4.3 mm	4 mm	None	7	RROC 2
14	SLS 7 mm	None	7.2 × 5.3 mm	5 mm	None	4	RROC 2
15	SL 7 × 3 mm	None	8.1 × 4.3 mm	4 mm	None	3	RROC 1
16	SLS 5 mm	None	2.4 × 4.9 mm	3 mm	None	15	RROC 1
17	SL 3.5 × 2 mm	None	3.8 × 3.5 mm	2 mm	None	19	RROC 1
18	SL 5 × 3 mm	None	5.5 × 3.8 mm	5 mm	None	25	RROC 2
19	SL 6 × 3 mm	None	5.3 × 4.4 mm	5 mm	None	12	RROC 1
20	SL 4 × 3 mm	None	4.9 × 3.8 mm	6 mm	None	36	RROC 2
21	SL 4.5 × 3 mm	None	4.4 × 2.5 mm	3 mm	None	12	RROC 2
22	SL 4 × 3 mm	None	3.1 × 3.2 mm	4 mm	None	24	RROC 1

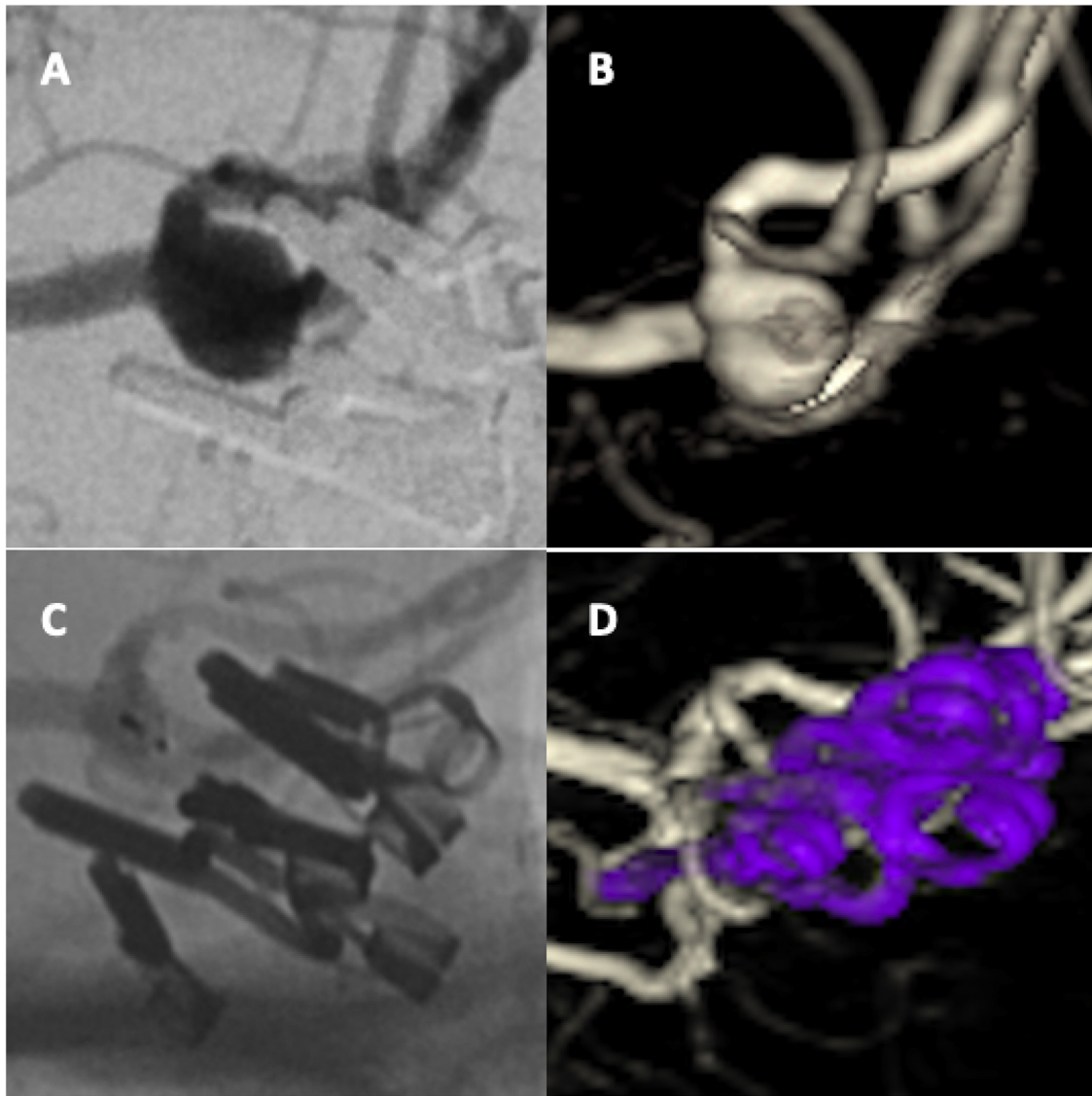
SL, single layer; SLS, single layer sphere; RROC, Raymond Roy Occlusion Criteria.

last radiological follow-up, 87% of recurrent IAs (n = 20) were adequately occluded (RROC classes I and II). Of these aneurysms, the radiological outcome of 12 recurrent IAs (52%) was RROC class I, and eight recurrent IAs (35%) were RROC class II; thus, the overall adequate occlusion rate was 87%. Three aneurysms (13%, RROC class III) were classified as having evidence of remnants. Data from multiple radiological follow-ups were available from 77% of patients (n = 17). Worsening of aneurysm occlusion from RROC class I or RROC II to

RROC III was not seen in any of the aneurysms after the first radiological follow-up (n = 17, median: 24 months, range: 12–60 months). Illustrative cases are presented in [Figs. 1 and 2](#).

*Complications and clinical outcome*

In one patient, an idiopathic intracerebral hemorrhage occurred 2 weeks post-intervention (case 3). As a consequence of this adverse



**Fig. 1.** Ruptured left MCA aneurysm. DSA image (A) of recurrent MCA aneurysm initially treated by clipping. 3D-rotational (B) image showing a large recurrence 8 years after treatment. DSA image showing (C) recurrent IA treated with WEB SL 6 × 3 mm. Follow-up 3D-rotational angiography image (D) after 6 months shows adequate radiologic outcome.

event, the patient's mRS score increased from 1 to 2. There were no cases of procedure-related mortality or aneurysm rupture.

## Discussion

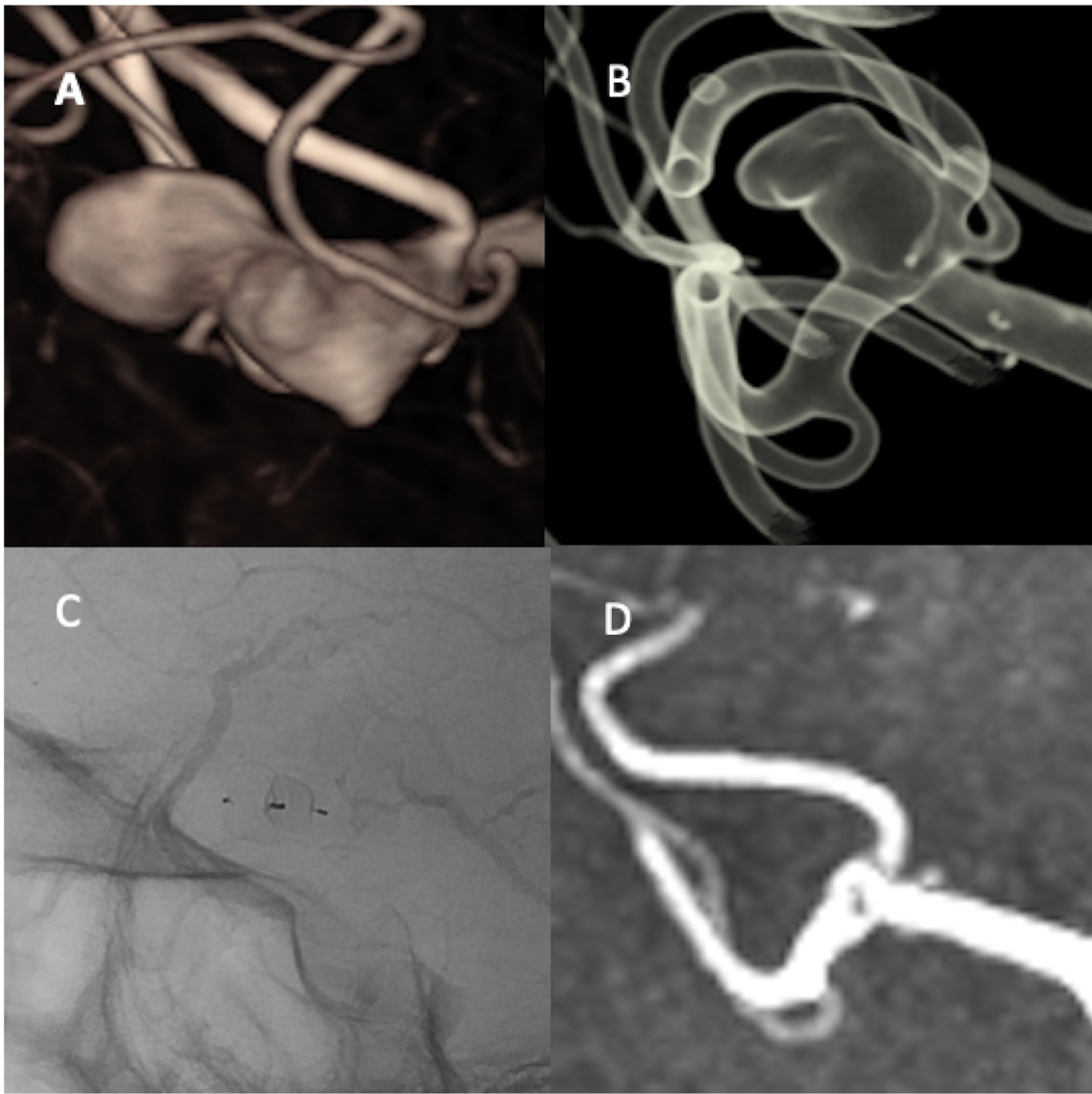
To date, we present the largest cohort of recurrent IAs treated with WEB, with the longest known median duration of radiological follow-up. The results of our study show that WEB is a feasible option for the treatment of recurrent IAs, particularly for wide-necked recurrent IAs. In our series, 87% of recurrent IAs were adequately occluded. In previous reports,<sup>8-10</sup> the overall adequate occlusion rate of recurrent IAs treated with WEB was estimated as 71%. The adequate occlusion rate in our series can be considered good, especially with respect to the size and location of the recurrent IAs. The results of previous studies were summarized in Table 3.

Furthermore, the results of our study may suggest that the radiological outcomes of WEB-treated recurrent IAs remains stable, as the radiological outcome of recurrent IAs treated with WEB in our study did not change after the first radiological follow-up. Data

from two or more radiological follow-up sessions were available from 18 cases of WEB-treated recurrent IAs, and none showed worsening from adequate (RROC classes I and II) to inadequate (RROC class III) radiological outcomes. The radiological outcome of aneurysms treated with WEB was found to be similarly stable in previous multicenter observational studies.<sup>11,12</sup> For instance, in a prospective multicenter study by Arthur et al.,<sup>12</sup> the rate of worsening of radiological outcomes from RROC class I/II to class III was only 4% between the first and second year of follow up.

Eighty-seven percent of recurrent IAs were feasibly treated with WEB alone. However, in our study, ancillary devices were also used to achieve good occlusion or to prevent protrusion of the WEBs into the parent artery; this comprised coils in 9% and a stent in 4% of our cases. In the previous series,<sup>8-10</sup> approximately two-thirds of the recurrent IAs were treated with WEB alone; ancillary devices were used to ensure occlusion of the aneurysms: coils in 18%, stents in 16%, and a flow diverter in 2% of recurrent IAs.

We did not encounter any thromboembolic events in our series. Apart from one late hemorrhagic event, an intracerebral hemorrhage, which occurred two weeks after treatment, no other events



**Fig. 2.** 3D-rotational angiography image (A) shows an unruptured MCA aneurysm before initial treatment with WEB. 3D-rotational angiography image (B) shows a large recurrence 2 years after the initial treatment. Unsubtracted DSA image (C) shows recurrent IA treated with another WEB SL 6 × 3 mm. TOF sequence of MRI (D) shows adequate outcome at 6 months after the treatment of recurrence.

**Table 3**  
 The summary of previous studies on treatment of recurrent intracranial aneurysms treated with WEB.

	Patients/aneurysms (n)	Morbidity (n)	Follow-Up (months)	Adequate radiological outcome (n, %)
Gawlizta et al, 2018 <sup>8</sup>	17/17	1	12	11/15 (73%)
Kabbasch et al, 2019 <sup>9</sup>	11/11	None	7	7/9 (64%)
Van Rooij et al, 2019 <sup>10</sup>	17/17	None	7	11/17 (65%)
Present Study	22/23	1	23	20/23 (87%)

of treatment-related morbidity or mortality were observed. None of the recurrent IAs in our series or previously reported series,<sup>8-10</sup> bled after WEB treatment. In all the previous reports,<sup>8-10</sup> the rate of treatment-related complications was 11%, of which four were thromboembolic and one was hemorrhagic. In accordance with previous reports,<sup>8-10</sup> the safety of WEB was also demonstrated in a multicenter WEB-IT study<sup>5</sup>; thromboembolic complications occurred in 5% of patients but only one patient (1%) experienced a major complication, a late intracranial hemorrhage.

The rate of remnant recurrent IAs was 13% in our series, which is better than the 29% described in the previous series.<sup>8-10</sup> The reason why WEB treatment of recurrent IAs failed in our cases is not clear. In a multicenter study conducted by Kabbasch et al., partially thrombosed aneurysms treated with WEB had high recurrence rates.<sup>13</sup> In our cohort, 13% of recurrent IAs (n = 3), which were also partially thrombosed, did not occlude after treatment with WEB. In general terms, WEB may fail to achieve complete occlusion in wide-neck recurrent aneurysms that are partially thrombosed.

In a study of recurrent IA patients treated with coiling, Henkes et al. reported that a wide neck (>4.5 mm), a large fundus (>10 mm), and the presence of an intra-aneurysmal thrombus were factors that negatively influenced occlusion rates.<sup>14</sup> Stent-assisted coiling is another conventional treatment method for recurrent IAs. Although stent-assisted coiling has been associated with an adequate aneurysm occlusion rate, Consoli found that there was a complication rate of 10% when stent-assisted coiling was used as the primary treatment for aneurysms.<sup>15</sup> Additionally, Kabbach et al. reported a similarly adequate occlusion rate of 94% in IAs treated with WEB or stent-assisted coiling. However, their complication rate was significantly lower for WEB treatment (12% vs 21%).<sup>16</sup> In the single-center series of 55 patients conducted by Tähtinen et al., the adverse outcome rate was 9% when using stent-assisted coiling.<sup>17</sup> In our opinion, due to higher risk of hemorrhagic complications, DAPT is also a disadvantage when linked with stent-assisted coiling for recurrent IAs. Flow diverters are contemporary treatment options for recurrent IAs. However, flow diverting is suitable for mostly side-wall aneurysms, not for bifurcation aneurysms. Furthermore, Caroff et al. reported 43% of ischemic and 21% of procedure related complication rates in flow diverter treatment for MCA bifurcation aneurysms.<sup>18</sup> Their high complication rate was due to branch covering. While microsurgical clipping of previously coiled aneurysms has been reported to be efficacious, it does seem to be associated with major complications and poor outcome attributed to surgery, with the major complication rate being reported to be as high as 8% and poor outcome rate of 12%.<sup>19,20</sup>

The limitations of our study are its retrospective design and small patient population. Another limitation is that due to institutional differences in the imaging follow-up, the data from DSA were not available for all cases. Additionally, non-standardized pre- and post-operative antiplatelet medications may have affected outcomes and complications.

## Conclusion

Our results indicate that WEB could be a feasible and reasonably safe option for the treatment of recurrent IAs. Deterioration from adequate (RROC classes I and II) to inadequate (RROC class III) radiological outcomes of recurrent IAs is unlikely after WEB treatment. Further trials are required to precisely identify subsets of patients and types of recurrent IAs that are most suitable for WEB treatment.

## Funding

No funding was granted for this study.

## Conflict of interest

KA has received personal research grants from Turku University Foundation and Maire Taponen Foundation. AN reports no disclosures or conflict of interest. RP reports no disclosures or conflict of interest. JD is proctor and consultant for Microvention, Stryker and Neurologic/Acanadis. AL reports no disclosures or conflict of interest. RR is consultant for Microvention, Stryker and Medtronic.

## Informed consent

Local institutional review board waived the need for formal consent for this retrospective registry study.

## Ethical approval

The study permission approved by the local institutional review board of the Hospital District of Southwest Finland (T011/014/18) and The Academic and Clinical Central Office for Research and Development (ACCORD) for the University of Edinburgh and NHS Lothian approved data sharing for this study.

## Author contributions

All authors contributed to the study conception and design. Material preparation, data collection and analysis were performed by Kemal Alpay and Alberto Nania. The study was supervised by Riitta Parkkola, Riitta Rautio and Jonathan Downer. The first draft of the manuscript was written by Kemal Alpay and all authors commented on previous versions of the manuscript. All authors read and approved the final manuscript.

## Availability of data and material

The data is not open for public. However, it may be provided upon a proper request.

## Acknowledgements

We thank to Matias Sinisalo, MD, for the clinical work.

## Références

1. Ferns SP, Sprengers ME, van Rooij WJ, et al. Coiling of intracranial aneurysms: A systematic review on initial occlusion and reopening and retreatment rates. *Stroke*. 2009;40(8):e523–e529, <http://dx.doi.org/10.1161/STROKEAHA.109.553099>.
2. Campi A, Ramzi N, Molyneux AJ, et al. Retreatment of ruptured cerebral aneurysms in patients randomized by coiling or clipping in the International Subarachnoid Aneurysm Trial (ISAT). *Stroke*. 2007;38(5):1538–1544, <http://dx.doi.org/10.1161/STROKEAHA.106.466987>.
3. Thornton J, Bashir Q, Aletich VA, et al. What percentage of surgically clipped intracranial aneurysms have residual necks? *Neurosurgery*. 2000;46(6):1294–1300, <http://dx.doi.org/10.1097/00006123-200006000-00003>.
4. Ries T, Siemonsen S, Thomalla G, et al. Long-term follow-up of cerebral aneurysms after endovascular therapy prediction and outcome of retreatment. *Am J Neuroradiol*. 2007;28(9):1755–1761, <http://dx.doi.org/10.3174/ajnr.A0649>.
5. Fiorella D, Molyneux A, Coon, et al. Demographic, procedural and 30-day safety results from the WEB Intra-saccular Therapy Study (WEB-IT). *J Neurointerv Surg*. 2017;9(12):1191–1196, <http://dx.doi.org/10.1136/neurintsurg-2016-012841>.
6. Pierot L, Spelle L, Molyneux A, et al. Clinical and anatomical follow-up in patients with aneurysms treated with the WEB device: 1-year follow-up report in the cumulated population of 2 prospective, multicenter series (WEBCAST and French Observatory). *Neurosurgery*. 2016;78(1):133–141, <http://dx.doi.org/10.1227/NEU.0000000000001106>.
7. Raj R, Rautio R, Pekkola, et al. Treatment of ruptured intracranial aneurysms using the Woven EndoBridge device: a two-center experience. *World Neurosurg*. 2019;123:e709–e716, <http://dx.doi.org/10.1016/j.wneu.2018.12.010>.
8. Gawlitza M, Soize S, Januel AC, et al. Treatment of recurrent aneurysms using the Woven EndoBridge (WEB): Anatomical and clinical results. *J Neurointerv Surg*. 2018;10(7):629–633, <http://dx.doi.org/10.1136/neurintsurg-2017-013287>.
9. Kabbasch C, Goertz L, Siebert E, et al. Treatment of recurrent and residual aneurysms with the Woven EndoBridge Device: analysis of 11 patients and review of the literature. *World Neurosurg*. 2019;129:e677–e685, <http://dx.doi.org/10.1016/j.wneu.2019.05.248>.
10. van Rooij S, van Rooij WJ, Sluzewski M, et al. The Woven EndoBridge (WEB) for recurrent aneurysms: Clinical and imaging results. *Interv Neuroradiol*. 2019;25(1):21–26, <http://dx.doi.org/10.1177/1591019918798806>.
11. Pierot L, Spelle L, Molyneux A, et al. Clinical and anatomical follow-up in patients with aneurysms treated with the WEB device: 1-year follow-up report in the cumulated population of 2 prospective, multicenter series (WEBCAST and French Observatory). *Neurosurgery*. 2016;78(1):133–141, <http://dx.doi.org/10.1227/NEU.0000000000001106>.
12. Arthur AS, Molyneux A, Coon AL, et al. The safety and effectiveness of the Woven EndoBridge (WEB) system for the treatment of wide-necked bifurcation aneurysms: Final 12-month results of the pivotal WEB Intra-saccular Therapy (WEB-IT) study. *J Neurointerv Surg*. 2019;11(9):924–930, <http://dx.doi.org/10.1136/neurintsurg-2019-014815>.

13. Kabbasch C, Goertz L, Siebert E, et al. Factors that determine aneurysm occlusion after embolization with the Woven EndoBridge (WEB). *J Neurointerv Surg.* 2019;11(5):503–510, <http://dx.doi.org/10.1136/neurintsurg-2018-014361>.
14. Henkes H, Fischer S, Liebig T, et al. Repeated endovascular coil occlusion in 350 of 2759 intracranial aneurysms: Safety and effectiveness aspects. *Neurosurgery.* 2006;58(2):224–232, <http://dx.doi.org/10.1227/01.NEU.0000194831.54183.3F>.
15. Consoli A, Vignoli C, Renieri L, et al. Assisted coiling of saccular wide-necked unruptured intracranial aneurysms: Stent versus balloon. *J Neurointerv Surg.* 2016;8(1):52–57, <http://dx.doi.org/10.1136/neurintsurg-2014-011466>.
16. Kabbasch C, Goertz L, Siebert E, et al. WEB embolization versus stent-assisted coiling: Comparison of complication rates and angiographic outcomes. *J Neurointerv Surg.* 2019;11(8):812–816, <http://dx.doi.org/10.1136/neurintsurg-2018-014555>.
17. Tähtinen OI, Manninen HI, Vanninen RL, et al. Stent-assisted embolization of recurrent or residual intracranial aneurysms. *Neuroradiology.* 2013;55(10):1221–1231, <http://dx.doi.org/10.1007/s00234-013-1234-x>.
18. Caroff J, Neki H, Mihalea C, et al. Flow-diverter stents for the treatment of saccular middle cerebral artery bifurcation aneurysms. *Am J Neuroradiol.* 2016;37(2):279–284, <http://dx.doi.org/10.3174/ajnr.A4540>.
19. Daou B, Chalouhi N, Starke RM, et al. Clipping of previously coiled cerebral aneurysms: Efficacy, safety, and predictors in a cohort of 111 patients. *J Neurosurg.* 2016;125(6):1337–1343, <http://dx.doi.org/10.3171/2015.10.JNS151544>.
20. Romani R, Lehto H, Laakso A, et al. Microsurgical technique for previously coiled aneurysms. *J Neurosurg Sci.* 2011;55(2):139–150.