

# Recombinant Human FSH Treatment Outcomes in Five Boys With Severe Congenital Hypogonadotropic Hypogonadism

Ella Kohva,<sup>1</sup> Hanna Huopio,<sup>2</sup> Matti Hero,<sup>1</sup> Päivi J. Miettinen,<sup>1</sup> Kirsi Vaaralahti,<sup>1</sup> Virpi Sidoroff,<sup>3</sup> Jorma Toppari,<sup>4</sup> and Taneli Raivio<sup>1</sup>

<sup>1</sup>University of Helsinki and Helsinki University Hospital, 00014 Helsinki, Finland; <sup>2</sup>University of Eastern Finland and Kuopio University Hospital, 70029 Kuopio, Finland; <sup>3</sup>North Karelia Central Hospital, 80210 Joensuu, Finland; and <sup>4</sup>Institute of Biomedicine, Research Centre for Integrative Physiology and Pharmacology, University of Turku and Department of Pediatrics, Turku University Hospital, 20520 Turku, Finland

**ORCID numbers:** 0000-0001-5654-6772 (E. Kohva); 0000-0002-9843-5082 (M. Hero); 0000-0002-5184-9616 (P. J. Miettinen); 0000-0001-9561-5080 (V. Sidoroff); 0000-0003-2228-334X (J. Toppari); 0000-0001-5385-434X (T. Raivio).

**Context:** Recombinant human FSH (r-hFSH), given to prepubertal boys with hypogonadotropic hypogonadism (HH), may induce Sertoli cell proliferation and thereby increase sperm-producing capacity later in life.

**Objective:** To evaluate the effects of r-hFSH, human chorionic gonadotropin (hCG), and testosterone (T) in such patients.

**Design and Setting:** Retrospective review in three tertiary centers in Finland between 2006 and 2016.

**Patients:** Five boys: *ANOS1* mutation in two, homozygous *PROKR2* mutation in one, *FGFR1* mutation in one, and homozygous *GNRHR* mutation in one. Prepubertal testicular volume (TV) varied between 0.3 and 2.3 mL; three boys had micropenis, three had undergone orchidopexy.

**Interventions:** Two boys received r-hFSH (6 to 7 months) followed by r-hFSH plus hCG (33 to 34 months); one received T (6 months), then r-hFSH plus T (29 months) followed by hCG (25 months); two received T (3 months) followed by r-hFSH (7 months) or r-hFSH plus T (8 months).

**Main Outcome Measures:** TV, inhibin B, anti-Müllerian hormone, T, puberty, sperm count.

**Results:** r-hFSH doubled TV (from a mean  $\pm$  SD of  $0.9 \pm 0.9$  mL to  $1.9 \pm 1.7$  mL;  $P < 0.05$ ) and increased serum inhibin B (from  $15 \pm 5$  ng/L to  $85 \pm 40$  ng/L;  $P < 0.05$ ). hCG further increased TV (from  $2.1 \pm 2.3$  mL to  $8.6 \pm 1.7$  mL). Two boys with initially extremely small testis size (0.3 mL) developed sperm (maximal sperm count range, 2.8 to 13.8 million/mL), which was cryopreserved.

**Conclusions:** Spermatogenesis can be induced with gonadotropins even in boys with HH who have extremely small testes, and despite low-dose T treatment given in early puberty. Induction of puberty with gonadotropins allows preservation of fertility.

Abbreviations: AMH, anti-Müllerian hormone; CHH, congenital hypogonadotropic hypogonadism; hCG, human chorionic gonadotropin; HH, hypogonadotropic hypogonadism; inhB, inhibin B; KS, Kallmann syndrome; r-hFSH, recombinant human FSH; T, testosterone; TV, testicular volume.

Copyright © 2018 Endocrine Society

This article has been published under the terms of the Creative Commons Attribution Non-Commercial, No-Derivatives License (CC BY-NC-ND; <https://creativecommons.org/licenses/by-nc-nd/4.0/>).

**Freeform/Key Words:** FSH, hypogonadotropic hypogonadism, inhibin B, prepubertal

Congenital hypogonadotropic hypogonadism (CHH) is a rare and heterogeneous genetic disorder diagnosed typically in adolescence due to delayed puberty [1]. CHH is caused by impaired production, secretion, or action of GnRH [2]. Approximately half of patients with CHH exhibit impaired sense of smell, a condition termed Kallmann syndrome (KS), and the other half have normosmic HH [2]. CHH can also rarely present as a part of a wider syndrome [e.g., CHARGE (Coloboma, Heart defects, Atresia of the choanae, Retarded growth and development, Genital hypoplasia, and Ear anomalies and/or deafness) and Waardenburg syndrome] [3]. Estimates of CHH and KS incidence are scarce; studies based on French and Sardinian military screening suggest varied incidences from 1 in 10,000 for CHH [4] and 1 in 84,000 for KS [5] in men, whereas in Finnish population the incidence of KS is estimated at 1:30,000 for males and 1:125,000 for females [6].

Adolescent boys with CHH require hormonal treatment to induce puberty. The goals in treatment are to promote virilization, height growth, sexual function, bone health, psychological and emotional well-being, and future fertility [2]. Although boys with CHH achieve virilization with exogenous testosterone, testicular maturation and induction of spermatogenesis require treatment with gonadotropins or pulsatile GnRH [7–9]. However, in the most severe forms of GnRH deficiency, characterized by cryptorchidism and small adult testicular volume (TV) (<4 mL), the outcomes of the above-mentioned fertility-inducing treatments tend to be poor [10].

Prepubertal testis size comprises interstitial tissue and seminiferous cords, formed by somatic Sertoli cells enveloping spermatogonia. In puberty, the seminiferous cords grow in diameter and obtain lumen as Sertoli cells enter a mature, nonproliferative state to support and nurture the developing spermatogenic cells [11]. Subsequently, the number of Sertoli cells in adulthood correlates with sperm output [12]. The stage for future spermatogenesis is, however, already set before puberty. Because only 10% of the Sertoli cell number is reached within the neonatal period, proliferation of immature Sertoli cells continues in the mini-puberty of infancy, and the final proliferation phase occurs in early puberty [13, 14]. At this time, Sertoli cells also differentiate and stop proliferating, which is linked to their increased expression of androgen receptors and increasing intratesticular testosterone levels [15, 16]. Consequently, a decline in the high circulating levels of anti-Müllerian hormone (AMH) secreted by immature, prepubertal Sertoli cells occurs, which reflects androgen-mediated differentiation of Sertoli cells [17]. However, the role of exogenously administered testosterone in this process is unclear.

More than 20 years ago, we introduced the concept of treating boys with prepubertal onset of HH by using recombinant human FSH (r-hFSH) [18], and 10 years later we reported the long-term outcome of this treatment modality in a heterogeneous group of patients [19]. Subsequently, Dwyer *et al.* [20] showed data on men with CHH suggesting proliferation and maturation of Sertoli cells in response to r-hFSH, but their randomized study did not reach conclusive evidence for the superiority of r-hFSH pretreatment on sperm parameters. Although the long-term outcomes of r-hFSH pretreatment are promising, and the European consensus statement on CHH [2] suggests that it may benefit most severely affected patients (*i.e.*, those with small testis size and history of cryptorchidism), there is no conclusive evidence on the possible benefits of this treatment. At the same time, it is unclear whether exogenous testosterone (T), widely used in the induction of puberty in patients with CHH, induces premature differentiation of Sertoli cells and thereby reduces sperm-producing capacity.

In this study, we describe biochemical and clinical markers of puberty and testicular function during and after r-hFSH treatment in five prepubertal patients with CHH who

have a molecular genetic diagnosis. Three of the boys had very small prepubertal testis size, and three boys had a history of cryptorchidism, both known risk factors for poor spermatogenesis later in life [10, 21]. In addition, we describe clinical and hormonal data pertinent to Sertoli cell function in boys with CHH treated with exogenous T.

## 1. Patients and Methods

### A. Patients

Data were retrospectively collected from electronic medical records of five boys with CHH treated in Children's Hospital of Helsinki University Hospital, Turku University Hospital, or Kuopio University Hospital between 2006 and 2016. Patients included in this study are characterized in detail in Tables 1 and 2 and in the Results section. The diagnosis of CHH was based on clinical history, absence of the sense of smell (in patients with KS), low gonadotropin and sex steroid levels for age, and low responses in GnRH stimulation tests. Brain MRI was performed in four of five boys. In all boys, the diagnoses were confirmed by molecular genetic analyses. Genetic testing of patient 4 was carried out commercially in an accredited laboratory (SYNLAB MVZ Humane Genetik); all other patients were tested in a research setting.

During treatment, the boys visited a pediatric endocrinologist at 1- to 8-month intervals. At each visit, their stage of puberty was assessed according to the Tanner system, testis length and width were measured with a ruler to the nearest millimeter, and TV was calculated ( $\text{length} \times \text{width}^2 \times 0.52$ ); TV is reported as the volume of one testis or the mean of both testes when possible. Prepubertal penile length  $< -2.5$  SDs was defined as micropenis [22].

At each visit, blood samples were drawn for serum gonadotropins, T, AMH, and inhB concentrations. Serum AMH was measured by Beckman Coulter AMH Gen II ELISA with a lower limit of detection of 0.08  $\mu\text{g/L}$ . Intra- and interassay coefficients of variation were from 2.5% to 5.4% and from 4.5% to 5.6%, respectively. LH and FSH were measured with Elecsys® Electrochemiluminescence immunoassay (Roche Diagnostics). The lower limit of detection was 0.10 mIU/mL for both LH and FSH; intra- and interassay coefficients of variation were 2% and 3% for LH and 2.5% and 3% for FSH, respectively. Testosterone was measured by liquid chromatography/tandem mass spectrometry (API 2000 LC/MS/MS System; Applied Biosystems) with a detection limit of 0.05 nmol/L. Serum inhB was measured as described recently in detail [23].

Three patients provided semen samples after the treatment period; semen analyses were performed according to World Health Organization criteria [24]. All five patients were treated with r-hFSH [Gonal-F® (EMD Serono), Puregon® (Merck Sharpe & Dohme)] in three weekly subcutaneous doses of 0.9 to 2.1 IU/kg (range, 66.7 to 112.5 IU) for 7 to 40 months. TV and inhB were used to assess response to treatment. Patients 1 and 2 received 6 to 7 months

**Table 1. Molecular Genetic Diagnoses and Clinical Findings of Five Adolescent Boys With CHH**

Patient No.	DG	Mutation	Initial GnRH Test, Baseline/Maximum (IU/L)	Initial T (nM)	Initial TV (mL)	MRI Finding
1	KS	<i>ANOS1</i> c.571C>T p.(Arg191*)	LH: 0.1/1.3; FSH: 0.4/1.8	0.2	0.3	Absent olfactory bulbs
2	nCHH	Homozygous <i>GNRHR</i> c.416G>A p.(Arg139His)	LH: <0.1/<0.1; FSH: NA	0.3	0.3	Normal
3	KS	Homozygous <i>PROKR2</i> c.701G>A p.(Gly234Asp)	LH: <0.1/1.6; FSH: 0.5/3.3	<0.5	2.3	Normal
4	KS	<i>FGFR1</i> c.2059G>A p.(Gly687Arg)	LH: 0.3/5.1; FSH: 1.1/ 6.5	0.3	0.5	Hypoplastic olfactory bulbs
5	KS	<i>ANOS1</i> c.571C>T p.(Arg191*)	LH: 0.1/ NA; FSH: 0.4/ NA	0.3	0.9	NA

Abbreviations: NA, not available; nCHH, normosmic congenital hypogonadotropic hypogonadism.

**Table 2. Clinical Findings and Treatment Schemes of Five Adolescent Boys With CHH**

Patient No.	Age at Beginning of Treatment (y)	Treatment	Testes Position	Micropenis	Final TV (mL)	Maximum Sperm Count (million/mL)
1	14.8	r-hFSH 66.7 IU SC 3 times/wk for 6 mo → r-hFHS 66.7 IU SC 3 times/wk + hCG 500–1500 IU SC/wk for 34 mo	Bilateral retractile testes operated on at age 4 y	No	6.7	2.8
2	15.1	r-hFSH 112.5 IU SC 3 times/wk for 7 mo → r-hFHS 66.7 IU SC 3 times/wk + hCG 500–1500 IU SC/wk for 33 mo	Scrotal	No	7.2	13.8
3	16.7	T 50 mg IM 1 time/mo for 6 mo → T 50–750 mg IM 1 time/1–3 mo + r-hFSH 100 IU SC 3 times/wk for 29 mo → hCG 1000–1500 IU SC 2 times/wk for 25 mo	Scrotal	Yes	12.1	9.3
4	14.7	T 50 mg IM 1 time/mo for 3 mo → r-hFSH 75 IU SC 3 times/wk for 7 mo	R: scrotal; L: operated on at age 13.5 y	Yes	1.8	NA
5	13.3	T 50 mg IM 1 time/mo for 3 mo → T 50–100 mg IM 1 time/mo + r-hFSH 75 IU SC 3 times/wk for 8 mo	R: operated on at age 9.9 y; L: scrotal	Yes	1.3	NA

Abbreviations: IM, intramuscularly; NA, not available; SC, subcutaneously.

of r-hFSH alone, and thereafter hCG (Pregnyl®; Merck) was commenced for 33 to 34 months in one or two weekly doses of 8 to 14 IU/kg (range, 500 to 1500 IU). Low-dose T [Sustanon® (Aspen); Nebido® (Bayer)] treatment (range, 50 to 250 mg per month) was administered for patients 3, 4, and 5 in parallel with r-hFSH for 3 to 29 months. In patient 3, spermatogenesis was induced with hCG in two weekly doses of 15 to 22 IU/kg (Pregnyl®, range, 1000 to 1500 IU). After induction of puberty, three patients (patients 1, 2, and 3) switched to long-acting T (Nebido®) monotherapy (range, 250 mg every 6 weeks to 1000 mg every 3 months). The treatment protocols are described in Fig. 1 and Table 2.

### B. Ethics

This retrospective study based on electronic patient data was approved by the local Ethics Committee of the Helsinki University Hospital and the University of Helsinki, and all centers (Helsinki University Hospital, Turku University Hospital, and Kuopio University Hospital) possessed research permits. Informed consent of patients and/or their guardians was obtained.

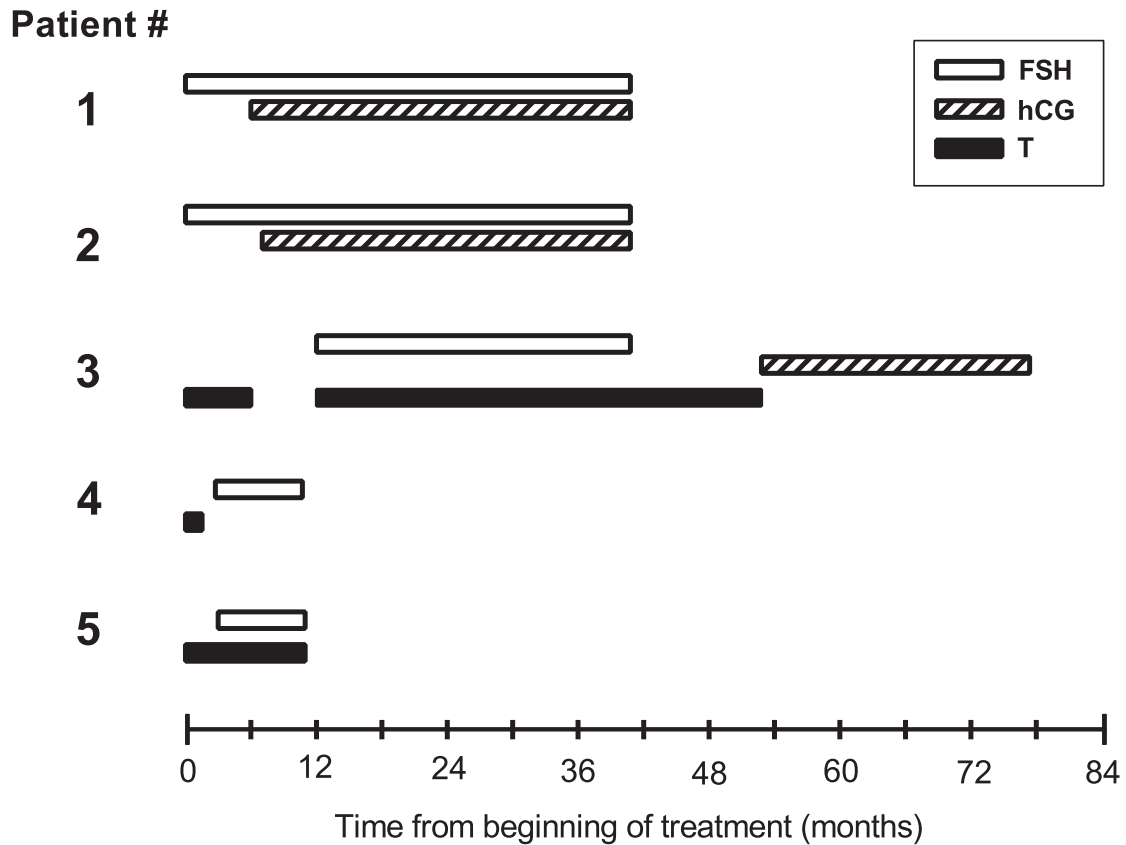
### C. Statistics

Changes in TV and concentration of inhB during r-hFSH pretreatment were assessed with Wilcoxon signed-rank test. The data are presented as mean (SD) unless otherwise stated.  $P < 0.05$  was accepted as indicating statistical significance. Statistical analyses were performed with SPSS statistical software for Windows, version 22.0 (SPSS, Chicago, IL).

## 2. Results

### A. Patient Case Histories

Clinical findings and molecular genetic diagnoses are summarized in Table 1 and 2. Patients 1 and 5 are not related, although they carry the same mutation. The overall impact of r-hFSH pretreatment on AMH, FSH, inhB, and TV is shown in Fig. 2. Figure 3 describes the individual

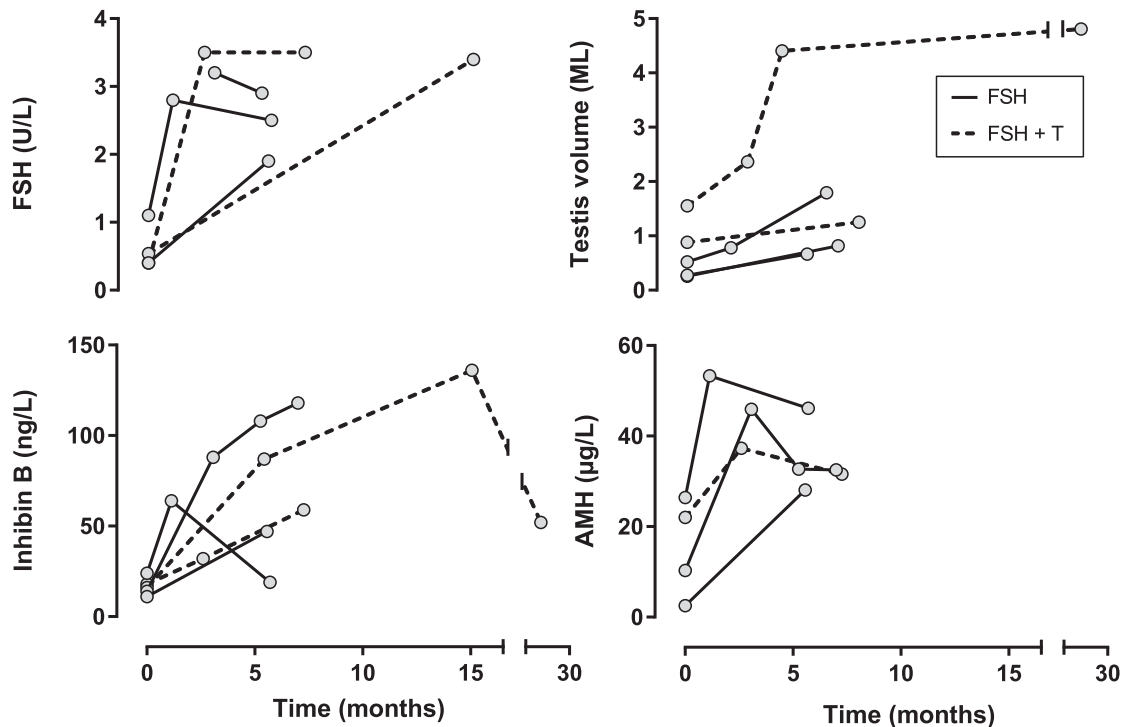


**Figure 1.** Treatment schemes of five boys with CHH on a timeline starting from each boy's first hormonal therapy. White box represents r-hFSH; dashed box, hCG; and black box, T.

responses of patients 1, 2, and 3 to r-hFSH pretreatment followed by induction of puberty with hCG.

Patient 1 was referred to a pediatric endocrinologist at age 14.6 years because of delayed puberty. The patient had undergone surgery for bilateral retractile testis at age 4 years. Clinical examination revealed hyposmia, synkinesia, Tanner stage G1P1, small testes (TV of 0.3 mL), and prepubertal penis. Brain MRI showed absent olfactory bulbs; his gonadotropin and testosterone levels were low for his age; and he was found to carry a hemizygous *ANOS1* nonsense mutation c.571C>T p.(Arg191\*) consistent with KS [25]. r-hFSH treatment was started at 14.8 years of age in three weekly doses (66.7 IU subcutaneously), which he received for 6 months. Pretreatment with r-hFSH increased AMH (from 2.5 to 28.1  $\mu\text{g/L}$ ) and inhB (from 11 to 47 ng/L) levels and TV (from 0.3 to 0.7 mL) (Fig. 2). Subsequently, puberty was induced with hCG (500 to 1500 IU per week in one or two subcutaneous doses). During hCG therapy, TV increased to 6.7 mL, AMH decreased to baseline values, and inhB peaked to 108 ng/L. After 21 months of hCG treatment (at Tanner stage G4P4 and TV of 6.2 mL), he provided four semen samples with a maximum sperm count of 2.8 million/mL (oligozoospermia) (Fig. 3). Sperm was cryopreserved for possible future use. Thereafter, he switched to T monotherapy (T undecanoate, 500 mg every 6 weeks to 750 mg every 3 months intramuscularly). Adult height at age 18.5 years was 178.7 cm.

Patient 2 presented at age 14.9 years with Tanner stage G1P1 and small testis size (TV 0.3 mL). His gonadotropin and testosterone levels were low, a GnRH stimulation test revealed absent LH response, and his brain MRI and sense of smell were normal. He was diagnosed with normosmic HH because of homozygous *GNRHR* mutation c.416G>A p.(Arg139His) [17, 26–30], and r-hFSH pretreatment was initiated at age 15.1 years (112.5 IU subcutaneously in three weekly doses). AMH increased (from 20.3 to 32.5  $\mu\text{g/L}$ ), inhB showed a markedly strong response (from 14 to 118 ng/L), and TV nearly tripled (from 0.3 to

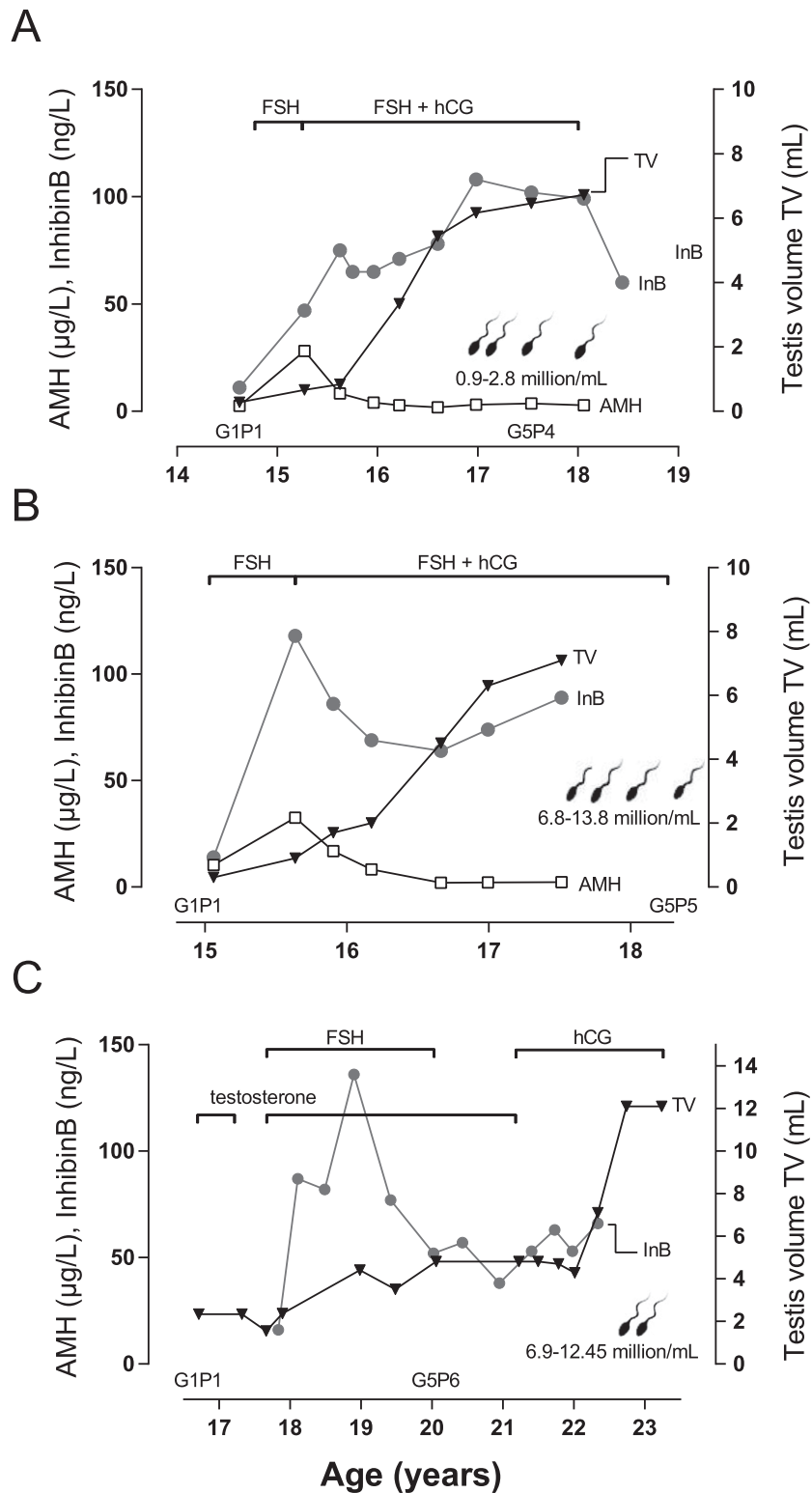


**Figure 2.** Markers of puberty and testicular function during r-hFSH treatment or combination of r-hFSH and T treatment in five adolescents with CHH: inhB, FSH, AMH, and TV. Patients 1 and 2, marked with a solid line, were treated with r-hFSH; patients 3, 4, and 5, marked with a dashed line, were treated with r-hFSH plus T.

0.8 mL) (Fig. 2). Seven months later, hCG (500 to 1500 IU per week in one or two subcutaneous doses) was added to induce spermatogenesis and androgenic puberty. As in patient 1, AMH decreased, T levels increased, and TV increased up to 7.2 mL. He provided four semen samples, the first of which was analyzed after 23 months of hCG + r-hFSH combination therapy (at a Tanner stage of G4P4 and TV of 7.1 mL); maximum sperm count was 13.8 million/mL (oligozoospermia) (Fig. 3). Sperm was cryopreserved for possible future use. Subsequently, gonadotropin treatments were replaced with T monotherapy (T undecanoate, 1000 mg every 3 months intramuscularly). His adult height at age 18.3 years was 175.5 cm.

Patient 3 has been previously described by Tommiska *et al.* [31]. In short, he was referred to a pediatric endocrinologist at 15.5 years of age and was followed up in anticipation of spontaneous activation of puberty until 16.7 years of age. He had small testes (2.3 mL), micropenis, and pubertal stage of G1P1. There was no history of cryptorchidism. Because his puberty did not proceed, he was put on T, 50 mg intramuscularly every 3 weeks. At age 17.7 years, KS was diagnosed; he carried a homozygous *PROKR2* mutation c.701G>A p.(Gly234Asp) [32]. The patient had anosmia and normal brain MRI. T treatment (50 to 125 mg intramuscular doses every 3 weeks) was accompanied with r-hFSH, 100 IU subcutaneously three times a week for 29 months. During that time, inhB increased (from 16 to 136 ng/L) and TV doubled (from 2.3 to 4.8 mL) (Fig. 2). Because of questionable adherence, he was transferred back to T monotherapy (250 mg every 6 weeks to 750 mg every 3 months intramuscularly), during which time TV did not change. At age 21.2 years, the patient desired fertility and spermatogenesis was induced with hCG (1000 to 3000 IU per week in two subcutaneous doses for 25 months). He provided five sperm samples after 18 months of hCG treatment (at Tanner stage of G5P6 and TV of 12.1 mL), maximum sperm count being 9.3 million/mL (oligozoospermia) (Fig. 3), and he was able to conceive a child. Adult height, measured at age 20.6 years, was 173.9 cm.

Patient 4 had surgery for unilateral cryptorchidism at age 13.5 years and was followed up by a pediatric surgeon for contralateral retractile testis as well as multiple syndactyly of the



**Figure 3.** Response to r-hFSH and hCG therapy in three boys with CHH. Schematics and individual responses for treatment in TV, progression of puberty (Tanner G and P stages), AMH, and inhB levels in (A) patient 1 (carrying *ANOS1* mutation), (B) patient 2 (carrying homozygous *GNRHR* mutation), and (C) patient 3 (carrying homozygous *PROKR2* mutation). Maximum sperm count and the time of sperm analyses are indicated by sperm symbols.

feet. He was referred to a pediatric endocrinologist at age 14.5 years for delayed puberty. Tanner stage was G1P2, and he had micropenis and small testes (0.5 mL). Brain MRI showed hypoplastic olfactory bulbs, and molecular analysis confirmed KS diagnosis [*FGFR1* mutation c.2059 G>A p.(Gly687Arg)] [33]. According to Polyphen 2 (<http://genetics.bwh.harvard.edu/pph2/>), this mutation is predicted to be probably damaging with highest possible score (score of 1.000). At age 14.7 years, the patient was treated first for micropenis with three monthly T (50 mg intramuscular) injections. R-hFSH pretreatment was subsequently initiated with three weekly 75 IU subcutaneous doses. Despite the prior T treatment, he responded to r-hFSH favorably: After r-hFSH pretreatment for 7 months, his AMH had doubled from 26.4 to 53.3  $\mu\text{g/L}$ , inhB had increased from 24 to 64 ng/L, and TV increased from 0.5 to 1.8 mL (Fig. 2). For patient 4, the treatment is still ongoing.

Patient 5 had a history of unilateral cryptorchidism and congenital unilateral kidney atrophy. At age 13.3 years, clinical examination showed he had small testes (TV 0.9 mL), micropenis, hyposmia, and synkinesis. KS was diagnosed on the basis of hemizygous nonsense mutation in *ANOS1* [c.571C>T p.(Arg191\*)] [25, 34, 35]. Treatment was initiated with three monthly 50-mg intramuscular doses of T because of micropenis. T was then combined with r-hFSH in three weekly 75-IU subcutaneous doses for 8 months, during which AMH and inhB increased (from 22 to 37  $\mu\text{g/L}$  and from 11 to 59 ng/L, respectively) and TV increased (from 0.9 mL to 1.3 mL) (Fig. 2). His treatment is ongoing.

### B. Summary of Treatment Responses to r-hFSH Pretreatment Followed by hCG

Responses during r-hFSH treatment in inhB, AMH, and FSH levels and TV are summarized in Fig. 2. Hormonal treatment was initiated at the mean age of  $14.9 \pm 1.2$  years (range, 13.3 to 16.7 years). Duration of r-hFSH pretreatment with or without T varied from 6 to 29 months. During r-hFSH treatment, TV doubled from  $0.9 \pm 0.9$  mL to  $1.9 \pm 1.7$  mL ( $P < 0.05$ ) and serum inhB increased from  $15 \pm 5$  ng/L to  $85 \pm 40$  ng/L (maximal value recorded for each patient during treatment;  $P < 0.05$ ). Induction of spermatogenesis and androgenic puberty with hCG treatment was initiated for three of the five patients (Fig. 3): Puberty progressed at a normal rate, TV increased from  $2.1 \pm 2.3$  mL to  $8.6 \pm 3.0$  mL, and patients reached genital maturation at a normal rate in 2.7 to 3.3 years. Each of these three patients provided four to five semen samples with maximum sperm count ranging from 2.8 to 13.8 million/mL; sperm were cryopreserved for future use.

## 3. Discussion

In patients with CHH, timely diagnosis and treatment to induce puberty are considered beneficial for sexual, bone, and metabolic health and might help minimize some of the negative psychological effects of CHH [2]. These patients are at risk for future infertility; given the overall disease burden, evidence-based treatment should be given to maximize testicular function and keep patients in line with their peers in terms of virilization. They should also be offered psychosocial support. Early intervention, such as neonatal gonadotrophin therapy mimicking minipuberty, may also have beneficial effects on testicular function and genital development. Indeed, because the androgen receptor is only weakly expressed in the infant Sertoli cells, hCG can be administered without maturing the Sertoli cells or inducing spermatogenesis [36–38]. However, the long-term benefits of neonatal gonadotrophin therapy are unknown.

The concept of maximizing sperm production with r-hFSH pretreatment in peripubertal boys is not new and has been applied in Finland during the past 20 years, with favorable outcomes [19]. Herein, we report our experience of this treatment modality in five boys with severe CHH. All patients responded to r-hFSH pretreatment with increased TV, inhB, and AMH concentrations, all surrogates of immature Sertoli cell proliferation [11, 39, 40]. These results agree with previous reports [18–20, 39], although we did not consider testicular



biopsies appropriate as part of clinical treatment of these patients. Therefore, the effect of r-hFSH in this age group must be judged on the basis of the above-mentioned indirect evidence.

In three boys, spermatogenesis was successfully induced with hCG following r-hFSH pretreatment. These patients showed an abrupt decline in AMH levels, consistent with maturation of Sertoli cells due to increased intratesticular T concentrations [15, 16]. This result agrees with those reported by Young *et al.* [39]. Our results thus suggest that the age-dependent upregulation of androgen receptor, described by Rey *et al.* [15], also occurs in patients with CHH. Cryptorchidism and small testicular size are negative prognostic factors for future fertility [10, 21]. In our study, however, two patients with an extremely low initial testicular volume (0.3 mL) responded well to gonadotropin treatment and developed sperm. These results agree with our previous reports [19]. Furthermore, two of the boys (patients 4 and 5) showed good response to r-hFSH despite a phenotype suggesting severe GnRH deficiency in infancy (cryptorchidism and small penile size). These findings support the notion that r-hFSH priming treatment should be targeted especially to patients with CHH who have the poorest prognosis for fertility, as suggested by the recent consensus statement [2].

For patients 3 and 5, the impact of r-hFSH pretreatment was not diminished by previously or simultaneously administered exogenous T, and in patient 4 the treatment of micropenis before r-hFSH did not compromise the response to r-hFSH. These findings suggest that exogenous low-dose T does not disturb immature Sertoli cell proliferation, concordant with the conclusions of a meta-analysis by Rastrelli *et al.* [41]: that previous T therapy does not affect the results of gonadotropin treatment. This notion is further enforced by the finding that patient 3 fathered a child even after 4 years of T treatment when hCG was introduced to his treatment. Of note, we did not observe atypical responses to gonadotropin treatment, such as signs of testicular resistance, of remaining hypogonadal, or of being azoospermic, suggested to occur in as many as 26% of men with CHH [42].

Our patients 1 and 5 had *ANOS1* mutation, which has been previously associated with a severe reproductive phenotype and poor outcome of gonadotrophin treatment [42–44]. In the work of Costa-Barbosa *et al.* [44], 50% of patients harboring *ANOS1* mutation did not respond favorably to GnRH therapy, and Sykiotis *et al.* [42] discovered that in their study population all atypical responders (n = 21) displayed mutations in *ANOS1*. However, both our patients with *ANOS1* mutation had good responses to r-hFSH treatment, and patient 1, for whom puberty was initiated with hCG during the study period, was able to produce sperm. These results suggest that patients carrying an *ANOS1* mutation benefit from peripubertal r-hFSH therapy.

In rare diseases such as CHH, even retrospective studies are limited by the small number of patients, as in this study. Patients in our study presented at different ages, had varying expectations for care, and thus had individually designed treatment protocols. Although treatment protocols were not strictly similar for each boy, we were able to evaluate the effects of r-hFSH treatment in this patient group, in which four of five had known risk factors for poor fertility (low TV or cryptorchidism). While we await the results from prospective multicenter studies to validate the role of r-hFSH pretreatment in the management of boys with CHH, smaller patient case series such as ours add to the existing knowledge of benefits of r-hFSH pretreatment in boys with CHH.

We conclude that spermatogenesis can be induced with gonadotropin treatment in boys with CHH despite extremely low baseline TV and that prior exogenous low-dose androgen treatment does not appear to prevent proliferation of immature Sertoli cells. More important, induction of puberty with gonadotropin treatment in patients with CHH allows preservation of fertility, and this option should be explained to these patients and their families.

## Acknowledgments

**Financial Support:** This work was supported by the Finnish Foundation for Pediatric Research, Academy of Finland (T.R.), Emil Aaltonen Foundation (E.K.), and Sigrid Juselius Foundation (J.T.).

**Correspondence:** Taneli Raivio, MD, PhD, University of Helsinki, Biomedicum Helsinki, Haartmaninkatu 8, P.O. Box 63, 00014 Helsinki, Finland. E-mail: [taneli.raivio@helsinki.fi](mailto:taneli.raivio@helsinki.fi).

**Disclosure Summary:** The authors have nothing to disclose.

---

## References and Notes

- Young J. Approach to the male patient with congenital hypogonadotropic hypogonadism. *J Clin Endocrinol Metab*. 2012;**97**(3):707–718.
- Boehm U, Bouloux P-M, Dattani MT, de Roux N, Dodé C, Dunkel L, Dwyer AA, Giacobini P, Hardelin J-P, Juul A, Maghnie M, Pitteloud N, Prevot V, Raivio T, Tena-Sempere M, Quinton R, Young J. Expert consensus document: European Consensus Statement on congenital hypogonadotropic hypogonadism--pathogenesis, diagnosis and treatment. *Nat Rev Endocrinol*. 2015;**11**(9):547–564.
- Lima Amato LG, Latronico AC, Gontijo Silveira LF. Molecular and genetic aspects of congenital isolated hypogonadotropic hypogonadism. *Endocrinol Metab Clin North Am*. 2017;**46**(2):283–303.
- Fromantin M, Gineste J, Didier A, Rouvier J. [Impuberism and hypogonadism at induction into military service. Statistical study]. *Probl Actuels Endocrinol Nutr*. 1973;**16**:179–199.
- Filippi G. Klinefelter's syndrome in Sardinia. Clinical report of 265 hypogonadic males detected at the time of military check-up. *Clin Genet*. 1986;**30**(4):276–284.
- Laitinen E-M, Vaaralahti K, Tommiska J, Eklund E, Tervaniemi M, Valanne L, Raivio T. Incidence, phenotypic features and molecular genetics of Kallmann syndrome in Finland. *Orphanet J Rare Dis*. 2011;**6**(1):41.
- Burris AS, Rodbard HW, Winters SJ, Sherins RJ. Gonadotropin therapy in men with isolated hypogonadotropic hypogonadism: the response to human chorionic gonadotropin is predicted by initial testicular size. *J Clin Endocrinol Metab*. 1988;**66**(6):1144–1151.
- Pitteloud N, Hayes FJ, Dwyer A, Boepple PA, Lee H, Crowley WF Jr. Predictors of outcome of long-term GnRH therapy in men with idiopathic hypogonadotropic hypogonadism. *J Clin Endocrinol Metab*. 2002;**87**(9):4128–4136.
- Miyagawa Y, Tsujimura A, Matsumiya K, Takao T, Tohda A, Koga M, Takeyama M, Fujioka H, Takada S, Koide T, Okuyama A. Outcome of gonadotropin therapy for male hypogonadotropic hypogonadism at university affiliated male infertility centers: a 30-year retrospective study. *J Urol*. 2005;**173**(6):2072–2075.
- Dwyer AA, Raivio T, Pitteloud N. Gonadotrophin replacement for induction of fertility in hypogonadal men. *Best Pract Res Clin Endocrinol Metab*. 2015;**29**(1):91–103.
- Sharpe RM, McKinnell C, Kivlin C, Fisher JS. Proliferation and functional maturation of Sertoli cells, and their relevance to disorders of testis function in adulthood. *Reproduction*. 2003;**125**(6):769–784.
- Orth JM, Gunsalus GL, Lamperti AA. Evidence from Sertoli cell-depleted rats indicates that spermatid number in adults depends on numbers of Sertoli cells produced during perinatal development. *Endocrinology*. 1988;**122**(3):787–794.
- Plant TM, Marshall GR. The functional significance of FSH in spermatogenesis and the control of its secretion in male primates. *Endocr Rev*. 2001;**22**(6):764–786.
- Cortes D, Müller J, Skakkebaek NE. Proliferation of Sertoli cells during development of the human testis assessed by stereological methods. *Int J Androl*. 1987;**10**(4):589–596.
- Rey RA, Musse M, Venara M, Chemes HE. Ontogeny of the androgen receptor expression in the fetal and postnatal testis: its relevance on Sertoli cell maturation and the onset of adult spermatogenesis. *Microsc Res Tech*. 2009;**72**(11):787–795.
- Boukari K, Meduri G, Brailly-Tabard S, Guibourdenche J, Ciampi ML, Massin N, Martinerie L, Picard J-Y, Rey R, Lombès M, Young J. Lack of androgen receptor expression in Sertoli cells accounts for the absence of anti-Müllerian hormone repression during early human testis development. *J Clin Endocrinol Metab*. 2009;**94**(5):1818–1825.
- Hero M, Tommiska J, Vaaralahti K, Laitinen E-M, Sipilä I, Puhakka L, Dunkel L, Raivio T. Circulating antimüllerian hormone levels in boys decline during early puberty and correlate with inhibin B. *Fertil Steril*. 2012;**97**(5):1242–1247.
- Raivio T, Toppari J, Perheentupa A, McNeilly AS, Dunkel L. Treatment of prepubertal gonadotrophin-deficient boys with recombinant human follicle-stimulating hormone. *Lancet*. 1997;**350**(9073):263–264.
- Raivio T, Wikström AM, Dunkel L. Treatment of gonadotropin-deficient boys with recombinant human FSH: long-term observation and outcome. *Eur J Endocrinol*. 2007;**156**(1):105–111.
- Dwyer AA, Sykiotis GP, Hayes FJ, Boepple PA, Lee H, Loughlin KR, Dym M, Sluss PM, Crowley WF Jr, Pitteloud N. Trial of recombinant follicle-stimulating hormone pretreatment for GnRH-induced

- fertility in patients with congenital hypogonadotropic hypogonadism. *J Clin Endocrinol Metab.* 2013;**98**(11):E1790–E1795.
21. Liu PY, Baker HWG, Jayadev V, Zacharin M, Conway AJ, Handelsman DJ. Induction of spermatogenesis and fertility during gonadotropin treatment of gonadotropin-deficient infertile men: predictors of fertility outcome. *J Clin Endocrinol Metab.* 2009;**94**(3):801–808.
  22. Boas M, Boisen KA, Virtanen HE, Kaleva M, Suomi A-M, Schmidt IM, Damgaard IN, Kai CM, Chellakooty M, Skakkebaek NE, Toppari J, Main KM. Postnatal penile length and growth rate correlate to serum testosterone levels: a longitudinal study of 1962 normal boys. *Eur J Endocrinol.* 2006;**154**(1):125–129.
  23. Varimo T, Miettinen PJ, Käsäkoski J, Raivio T, Hero M. Congenital hypogonadotropic hypogonadism, functional hypogonadotropism or constitutional delay of growth and puberty? An analysis of a large patient series from a single tertiary center. *Hum Reprod.* 2017;**32**(1):147–153.
  24. World Health Organization. WHO laboratory manual for the examination and processing of human semen. 2010. <http://www.who.int/reproductivehealth/publications/infertility/9789241547789/en/>. Accessed 30 May 2018.
  25. Oliveira LM, Seminara SB, Beranova M, Hayes FJ, Valkenburgh SB, Schipani E, Costa EM, Latronico AC, Crowley WF Jr, Vallejo M. The importance of autosomal genes in Kallmann syndrome: genotype-phenotype correlations and neuroendocrine characteristics. *J Clin Endocrinol Metab.* 2001;**86**(4):1532–1538.
  26. Costa EM, Bedecarrats GY, Mendonca BB, Arnhold IJ, Kaiser UB, Latronico AC. Two novel mutations in the gonadotropin-releasing hormone receptor gene in Brazilian patients with hypogonadotropic hypogonadism and normal olfaction. *J Clin Endocrinol Metab.* 2001;**86**(6):2680–2686.
  27. Wolczynski S, Laudanski P, Jarzabek K, Mittre H, Lagarde J-P, Kottler M-L. A case of complete hypogonadotropic hypogonadism with a mutation in the gonadotropin-releasing hormone receptor gene. *Fertil Steril.* 2003;**79**(2):442–444.
  28. Laitinen E-M, Tommiska J, Sane T, Vaaralahti K, Toppari J, Raivio T. Reversible congenital hypogonadotropic hypogonadism in patients with CHD7, FGFR1 or GNRHR mutations. *PLoS One.* 2012;**7**(6):e39450.
  29. Zernov N, Skoblov M, Baranova A, Boyarsky K. Mutations in gonadotropin-releasing hormone signaling pathway in two nIHH patients with successful pregnancy outcomes. *Reprod Biol Endocrinol.* 2016;**14**(1):48.
  30. Beneduzzi D, Trarbach EB, Min L, Jorge AAL, Garmes HM, Renk AC, Fichna M, Fichna P, Arantes KA, Costa EMF, Zhang A, Adeola O, Wen J, Carroll RS, Mendonça BB, Kaiser UB, Latronico AC, Silveira LFG. Role of gonadotropin-releasing hormone receptor mutations in patients with a wide spectrum of pubertal delay. *Fertil Steril.* 2014;**102**(3):838–846.e2.
  31. Tommiska J, Toppari J, Vaaralahti K, Käsäkoski J, Laitinen E-M, Noisa P, Kinnala A, Niinikoski H, Raivio T. PROKR2 mutations in autosomal recessive Kallmann syndrome. *Fertil Steril.* 2013;**99**(3):815–818.
  32. Sarfati J, Fouveaut C, Leroy C, Jeanpierre M, Hardelin J-P, Dodé C. Greater prevalence of PROKR2 mutations in Kallmann syndrome patients from the Maghreb than in European patients. *Eur J Endocrinol.* 2013;**169**(6):805–809.
  33. Sato N, Hasegawa T, Hori N, Fukami M, Yoshimura Y, Ogata T. Gonadotrophin therapy in Kallmann syndrome caused by heterozygous mutations of the gene for fibroblast growth factor receptor 1: report of three families: case report. *Hum Reprod.* 2005;**20**(8):2173–2178.
  34. Sato N, Katsumata N, Kagami M, Hasegawa T, Hori N, Kawakita S, Minowada S, Shimotsuka A, Shishiba Y, Yokozawa M, Yasuda T, Nagasaki K, Hasegawa D, Hasegawa Y, Tachibana K, Naiki Y, Horikawa R, Tanaka T, Ogata T. Clinical assessment and mutation analysis of Kallmann syndrome 1 (KAL1) and fibroblast growth factor receptor 1 (FGFR1, or KAL2) in five families and 18 sporadic patients. *J Clin Endocrinol Metab.* 2004;**89**(3):1079–1088.
  35. Albuissou J, Pêcheux C, Carel J-C, Lacombe D, Leheup B, Lapuzina P, Bouchard P, Legius E, Matthijs G, Wasniewska M, Delpech M, Young J, Hardelin J-P, Dodé C. Kallmann syndrome: 14 novel mutations in KAL1 and FGFR1 (KAL2). *Hum Mutat.* 2005;**25**(1):98–99.
  36. Bouvattier C, Maione L, Bouligand J, Dodé C, Guiochon-Mantel A, Young J. Neonatal gonadotropin therapy in male congenital hypogonadotropic hypogonadism. *Nat Rev Endocrinol.* 2011;**8**(3):172–182.
  37. Main KM, Schmidt IM, Skakkebaek NE. A possible role for reproductive hormones in newborn boys: progressive hypogonadism without the postnatal testosterone peak. *J Clin Endocrinol Metab.* 2000;**85**(12):4905–4907.
  38. Bognères P, François M, Pantalone L, Rodrigue D, Bouvattier C, Demesteere E, Roger D, Lahlou N. Effects of an early postnatal treatment of hypogonadotropic hypogonadism with a continuous

- subcutaneous infusion of recombinant follicle-stimulating hormone and luteinizing hormone. *J Clin Endocrinol Metab.* 2008;**93**(6):2202–2205.
39. Young J, Chanson P, Salenave S, Noël M, Brailly S, O’Flaherty M, Schaison G, Rey R. Testicular anti-mullerian hormone secretion is stimulated by recombinant human FSH in patients with congenital hypogonadotropic hypogonadism. *J Clin Endocrinol Metab.* 2005;**90**(2):724–728.
40. Anawalt BD, Bebb RA, Matsumoto AM, Groome NP, Illingworth PJ, McNeilly AS, Bremner WJ. Serum inhibin B levels reflect Sertoli cell function in normal men and men with testicular dysfunction. *J Clin Endocrinol Metab.* 1996;**81**(9):3341–3345.
41. Rastrelli G, Corona G, Mannucci E, Maggi M. Factors affecting spermatogenesis upon gonadotropin-replacement therapy: a meta-analytic study. *Andrology.* 2014;**2**(6):794–808.
42. Sykiotis GP, Hoang X-H, Avbelj M, Hayes FJ, Thambundit A, Dwyer A, Au M, Plummer L, Crowley WF Jr, Pitteloud N. Congenital idiopathic hypogonadotropic hypogonadism: evidence of defects in the hypothalamus, pituitary, and testes. *J Clin Endocrinol Metab.* 2010;**95**(6):3019–3027.
43. Salenave S, Chanson P, Bry H, Pugeat M, Cabrol S, Carel JC, Murat A, Lecomte P, Brailly S, Hardelin J-P, Dodé C, Young J. Kallmann’s syndrome: a comparison of the reproductive phenotypes in men carrying KAL1 and FGFR1/KAL2 mutations. *J Clin Endocrinol Metab.* 2008;**93**(3):758–763.
44. Costa-Barbosa FA, Balasubramanian R, Keefe KW, Shaw ND, Al-Tassan N, Plummer L, Dwyer AA, Buck CL, Choi J-H, Seminara SB, Quinton R, Monies D, Meyer B, Hall JE, Pitteloud N, Crowley WF Jr. Prioritizing genetic testing in patients with Kallmann syndrome using clinical phenotypes. *J Clin Endocrinol Metab.* 2013;**98**(5):E943–E953.