

Clips vs Resilient Liners Used With Bilateral Posterior Prefabricated Bars for Retaining Four Implant-Supported Mandibular Overdentures

Mona Gibreel, BDS, MSD^{1*}

Mohammed Fouad, BDS, MSD, PhD¹

Fatma El-Waseef, BDS, MSD, PhD¹

Nesma El-Amier, BDS, MSD¹

Hamdy Marzook, BDS, MSD, PhD²

The objective of this research was to clinically compare peri-implant tissue health of bar-clips vs silicone-resilient liners used with bilateral posterior bars for retaining 4 implant-supported mandibular overdentures. Thirty completely edentulous male patients (mean age, 65 years) were randomly assigned into 2 equal groups. Each patient received 4 implants in the canine and first molar regions of the mandible using a flapless surgical technique. Mandibular overdentures were immediately connected to the implants with bilateral prefabricated instant adjusting bars. According to the method of retention to the bar, 1 group was retained with clips (GI), whereas the other group was retained with a silicone-resilient soft liner (GII). Peri-implant tissue health was evaluated clinically in terms of plaque scores (MPI), bleeding scores (MBI), probing depth (PD), and implant stability (IS). MPI, MBI, and PD were measured at mesial, distal, buccal, and lingual surfaces of each implant. Evaluations were performed 2 weeks (T0), 6 months (T6), and 12 months (T12) after overdenture insertion. Implants of GI with clips demonstrated significant increase in plaque, bleeding, and PD scores compared with those of GII with silicone-resilient liner at all observation times. Implants in GI demonstrated a significant decrease in implant stability compared with those of GII at T6 and T12 anteriorly and at T12 posteriorly. Resilient liners are considered better than bar-clips when used with bilateral posterior bars for retaining implant-supported mandibular overdentures in terms of peri-implant soft tissue health. Bilateral posterior ready-made bars cannot be proposed as a promising design for supporting implant-assisted mandibular overdentures.

Key Words: dental implants, mandibular, overdenture, resilient liners, retention, tissue health

INTRODUCTION

Conventional complete dentures are not always an ideal treatment for mandibular edentulous patients, as wearers often complain about functional problems due to insufficient retention and stability.¹⁻³ Many treatment options were introduced to increase retention and stability of conventional dentures including implant-retained overdentures for rehabilitation of the edentulous mandible.^{4,5}

The McGill consensus statement suggested that the 2-implant overdenture should be the first treatment of choice for the edentulous mandible.⁶ However, this treatment option demonstrated continued bone resorption in the edentulous posterior regions due to free overdenture rotation when functioning.⁷⁻¹¹ Furthermore, this design transfers a considerable part of the applied force from the denture-bearing area to the implants, especially when the occlusal resiliency of the clips did not compensate for mucosal resiliency.^{9,12}

On the other hand, addition of implants posterior to the mental foramen and connecting them to the anterior implants with bar in a quadrilateral configuration to support mandibular overdentures provides a 4-legged chair denture support that prevents overdenture rotation, reduces soft tissue irritation, and protects the mental nerve.¹³⁻¹⁵ Moreover, 4-implant/bar-supported overdentures show improved stability and retention compared with 2-implant/bar-supported overdentures. Eventually, they are indicated in conditions that require increased retention and stability, such as in cases with high muscle attachments or prominent mylohyoid ridges.¹⁶ This design improves comfort and masticatory performance in a way similar to that of fixed prostheses while keeping hygienic, esthetic, and cost advantages.¹⁷

Attachments used for implant overdentures are mainly divided into the bar type and the solitary type, and into the resilient type and the rigid type, depending on the movement allowance. Attachment selection is affected by implant number, distribution, alignment, bone quality, arch shape, retention, and denture design.¹⁸ Bar attachments are suitable as other attachments concerning implant survival rate, improvement of retention, and maintenance.¹⁹⁻²² However, conventional bar attachments have the disadvantages of complex fabrication, in addition to errors that occur during intraoral implant impres-

¹ Department of Prosthodontics, Faculty of Dentistry, Mansoura University, Mansoura, Egypt.

² Department of Oral Surgery, Faculty of Dentistry, Mansoura University, Mansoura, Egypt.

* Corresponding author: e-mail: monagibreel@mans.edu.eg

DOI: 10.1563/aaid-joi-D-16-00148

sion making and during laboratory fabrication of the bar.²³ Elastic and plastic deformations while removing the casting material, thermal and chemical contraction of cast and impression materials, and laser welding techniques result in dimensional differences between oral and model situations, incorrect connector-implant position, and eventually more stresses over supporting implants and the superstructure.^{24,25}

The design of a prefabricated bar attachment system called Dyna Instant Adjusting Bar (IAB) was developed by Dyna Industries to overcome most of these problems. It provides 100% stress-free construction, allows threading of the fixation screws up to an angulation of 18° with no stresses, and provides preciseness, fully prefabricated in titanium, and time savings. Furthermore, the laboratory can make the complete superstructure with the retention parts only without worrying about the fit of the bar that would be placed intraorally in addition to simple procedures with reduced cost.²⁶

However, the problems of rapid wear, limited rotational freedom, bulk, and soft tissue proliferation in unobstructed regions under bars have been considered the major drawbacks of bars and clips.⁷

Resilient denture liners have been used as a female housing over bar attachments for implant overdentures.^{27,28} These liners are resistant to wear, partially seal the space under the bar, absorb energy, and distribute masticatory forces between implants and the edentulous ridge. Moreover, they show better retention, which even when decreased after multiple insertions, was still greater than that of clips.^{29,30}

Several studies concerning the effect of resilient liners on peri-implant tissue health around implants supporting anterior custom-made bar are available.^{31,32} However, little is known from the relevant literature about the use of resilient liners with bilateral posterior prefabricated bars. Therefore, this study was established to compare the clinical effects of bar-clips vs silicone-resilient soft liners used with bilateral posterior bars on soft tissue around the 4 implants supporting the mandibular overdenture.

MATERIALS AND METHODS

Patient selection

Thirty completely edentulous male patients with an age range between 55 and 70 years were selected from the outpatient clinic of the Prosthodontics Department, Faculty of Dentistry, Mansoura University, from December 2012 to December 2015, after approval of the local committee for scientific research ethics.

Patients were consecutively included in the study, provided that they fulfilled the following criteria: (1) sufficient bone height in the interforaminal region of the mandible and above the mandibular canal posteriorly; (2) 3–6 months of healing after extraction (to allow ossification to occur)³³; (3) good oral and denture hygiene (questionnaire); and (4) sufficient inter-arch space verified by tentative jaw relation. Patients were excluded if they had any of the following: parafunctional habits (eg, bruxism and clenching), bad habits (eg, smoking and alcoholism), history of periodontal diseases, bone metabolic disorders (eg, uncontrolled diabetes and para-thyroidism), or

history of radiation therapy in the head and neck region. The patients were informed about the two treatment strategies that could be followed and were asked to participate in the study without prior knowledge of which treatment they were going to receive.

Patients were randomly classified into 2 equal groups to receive either clips (group I [GI]) or resilient liner attachment (group II [GII]). Randomization was randomly performed using the simple random method and a random generated number in spreadsheets.

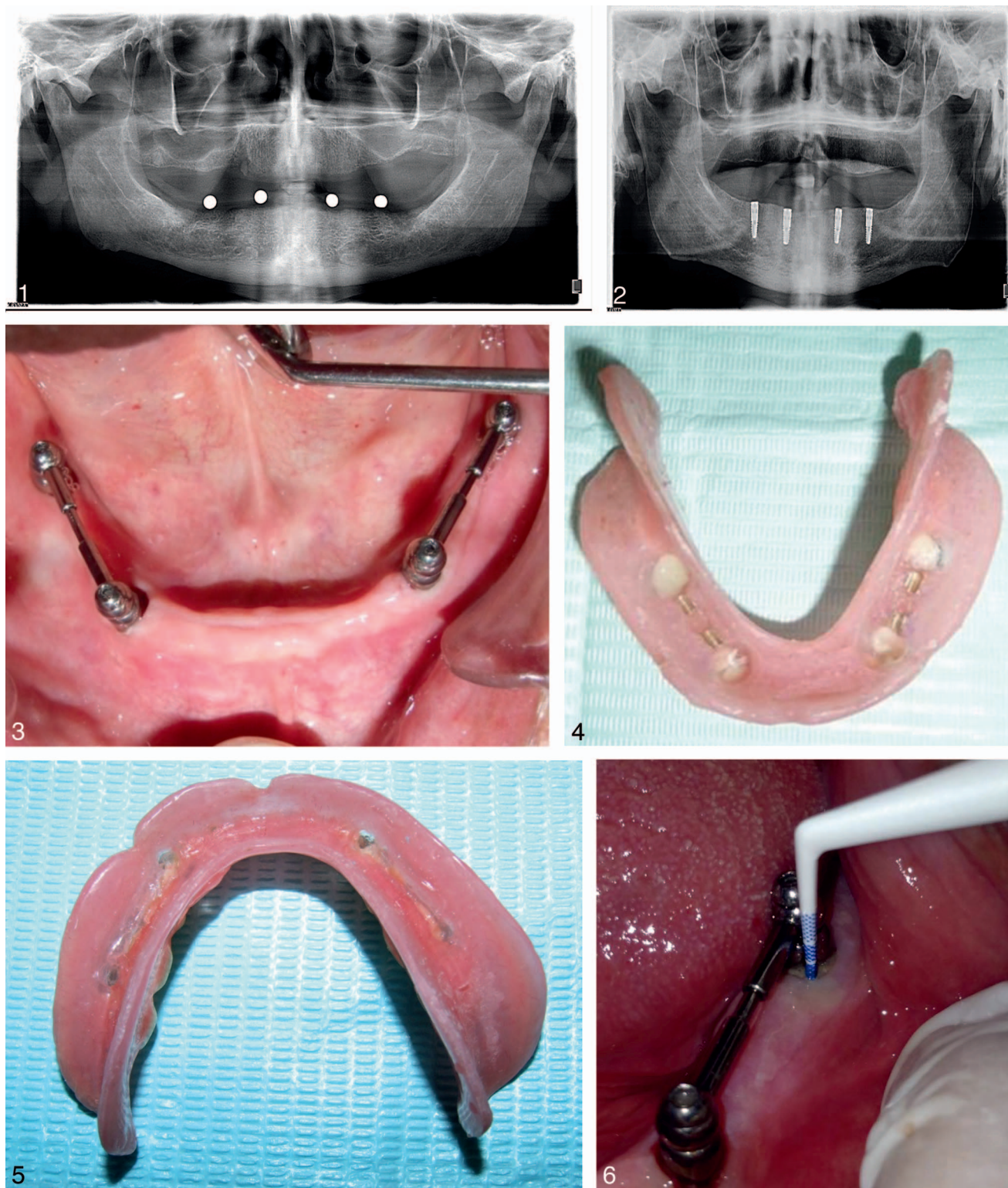
Surgical and prosthetic procedures

For all patients, new conventional maxillary and mandibular dentures were constructed. A surgical guide was fabricated by placing 4 marks on the study cast opposite to canine and first molar regions bilaterally. Radiographic balls (∅ 5 mm, Friadent, Mannheim, Germany) were fixed over marks, and a transparent radiographic stent was constructed. Panoramic radiographs were made with stents intraorally and then traced by a computer program (CorelDraw X5, Corel Corporation, Ottawa, Canada) to estimate available bone height opposite to each ball (Figure 1). Radiographic balls at target implant sites were removed, and their places were drilled into holes to convert the radiographic stent into a surgical stent as described by a previous study.³⁴ All patients were administered prophylactic antibiotics (2 g amoxicillin 1 hour before surgery) and a mouth rinse with 0.12% chlorhexidine digluconate (15 minutes prior to surgery).

For each patient, 4 acid-etched roughened titanium (ART) screw-type implants (Dyna Dental Engineering bv, Bergen op Zoom, Netherlands) that were 11.5 × 3.6 mm were inserted into the canine and first molar areas of the mandibular residual alveolar ridge using the nonsubmerged flapless surgical approach. All implants were placed by the same surgeon. A tissue punch (∅ 3.6 mm) was used to allow gingival access at the center of the surgical stent holes. Drilling of the implant site was performed using the successive drills of the Dyna implant drill kit. Implants were slowly threaded into their final position with a hand ratchet torque wrench at 35 N.

A postinsertion panoramic X ray was made to evaluate proper implant positions (Figure 2). Four instant adjusting bar octa extension abutments (Dyna IAB, Bergen, Netherlands) of 2-mm height were tightened into implants using the insertion key and torque wrench at 30 N. Implants on each side were splinted with an instant adjusting bar round (IAB), which was tightened according to the manufacturer's instructions.²⁶ The distance between the centers of the two bar abutments was measured, 4.5 mm was subtracted (to cut each IAB to the proper length), and then the cut end was polished. The IAB was inserted between each two joints, and the IAB fixation screws were tightened in position (Figure 3). Implants were immediately loaded with the mandibular overdentures.

The fitting surface of the mandibular dentures opposite to abutments was adequately relieved, and holes were made in the lingual surface of the denture to allow release of excess material. Spaces under the bars were blocked out intraorally with wax. For GI, 2 IAB gold riders were incorporated directly in the opposing fitting surface of the mandibular overdenture for each bar using auto-polymerizing resin according to the



FIGURES 1–6. **FIGURE 1.** Panoramic radiograph with stent intraoral to evaluate bone height at proposed implant positions. **FIGURE 2.** Panoramic radiograph with the four implants at their final position slightly under the crest. **FIGURE 3.** Bilateral instant adjusting bars tightened in position above instant adjusting bar abutments. **FIGURE 4.** The bar riders of both sides incorporated in the fitting surface of the overdenture. **FIGURE 5.** Silicone soft liner relined mandibular overdenture. **FIGURE 6.** Calibrated plastic periodontal probe used to measure probing depth.

TABLE 1

Comparison between anterior and posterior implants of GI at different observation times (T0, T6, and T12) regarding PI, BI, and PD*

Group/Time	Modified Plaque Index				Modified Bleeding Index			
	T0	T6	T12	P†	T0	T6	T12	P†
GI anterior, mean ± SD	1.3 ± 0.053	1.05 ± 0.034	0.88 ± 0.043	.001	0.34 ± 0.018	0.32 ± 0.01	0.22 ± 0.01	.001
GI posterior, mean ± SD	1.4 ± 0.085	1.15 ± 0.047	0.97 ± 0.063	.001	0.39 ± 0.019	0.33 ± 0.026	0.27 ± 0.01	.001
P‡	.003	.001	.002		.001	.008	.001	

*GI indicates group I; T0, 2 weeks after; T6, 6 months after; T12, 12 months after; PI, plaque index; BI, bleeding index; PD, probing depth.

†Friedman test, $P \leq .05$.

‡Mann-Whitney test, $P \leq .05$.

TABLE 2

Comparison between anterior and posterior implants of GII at different observation times (T0, T6, and T12) regarding PI, BI, and PD*

Group/Time	Modified Plaque Index				Modified Bleeding Index			
	T0	T6	T12	P†	T0	T6	T12	P†
GII anterior, mean ± SD	0.29 ± 0.01	0.20 ± 0.015	0.12 ± 0.01	.001	0.21 ± 0.005	0.12 ± 0.008	0.015 ± 0.02	.001
GII posterior, mean ± SD	0.38 ± 0.01	0.20 ± 0.008	0.12 ± 0.007	.001	0.24 ± 0.012	0.13 ± 0.014	0.019 ± 0.03	.001
P‡	.001	.503	.839		.001	.003	.847	

*GII indicates group II; T0, 2 weeks after; T6, 6 months after; T12, 12 months after; PI, plaque index; BI, bleeding index; PD, probing depth.

†Friedman test, $P \leq .05$.

‡Mann-Whitney test, $P \leq .05$.

TABLE 3

Comparison between anterior implants of GI vs GII at different observation times (T0, T6, and T12) in terms of PI, BI, and PD*

Group/Time	Modified Plaque Index				Modified Bleeding Index			
	T0	T6	T12	P†	T0	T6	T12	P†
GI anterior, mean ± SD	1.3 ± 0.053	1.05 ± 0.034	0.88 ± 0.043	.001	0.34 ± 0.018	0.32 ± 0.01	0.22 ± 0.01	.001
GII anterior, mean ± SD	0.29 ± 0.01	0.20 ± 0.015	0.12 ± 0.01	.001	0.21 ± 0.005	0.12 ± 0.008	0.015 ± 0.02	.001
P‡	.001	.001	.001		.001	.001	.001	

*GI indicates group I; GII, group II; T0, 2 weeks after; T6, 6 months after; T12, 12 months after; PI, plaque index; BI, bleeding index; PD, probing depth.

†Friedman test, $P \leq .05$.

‡Mann-Whitney test, $P \leq .05$.

TABLE 4

Comparison between posterior implants of GI vs GII at different observation times (T0, T6, and T12) in terms of PI, BI, and PD*

Group/Time	Modified Plaque Index				Modified Bleeding Index			
	T0	T6	T12	P†	T0	T6	T12	P†
GI posterior, mean ± SD	1.4 ± 0.085	1.15 ± 0.047	0.97 ± 0.063	.001	0.39 ± 0.019	0.33 ± 0.026	0.27 ± 0.01	.001
GII posterior, mean ± SD	0.38 ± 0.01	0.20 ± 0.008	0.12 ± 0.007	.001	0.24 ± 0.012	0.13 ± 0.014	0.019 ± 0.03	.001
P‡	.001	.001	.001		.001	.001	.001	

*GI indicates group I; GII, group II; T0, 2 weeks after; T6, 6 months after; T12, 12 months after; PI, plaque index; BI, bleeding index; PD, probing depth.

†Friedman test, $P \leq .05$.

‡Mann-Whitney test, $P \leq .05$.

method described by De Vries and Meijer,³⁵ the dentures were polished, and the occlusion was re-examined carefully for any adjustment (Figure 4). For GII, the relieved fitting surface opposite to the IAB on both sides was painted with a soft liner adhesive, and relining procedures were performed with the addition of an auto-polymerizing silicone resilient liner (Soft-liners, Promedica, GmbH, Neumunster, Germany) using the

closed mouth technique (Figure 5). Overdenture fit and occlusion were evaluated. Glazing of the relining was performed by mixing equal drops of glaze base and catalyst homogeneously on a mixing pad (2-minute working time; 10-minute setting time), and the mixture was painted to the soft liner using a soft bristle brush to seal surface roughness.

All prosthetic procedures were performed by the same

TABLE 1

Extended

Probing Depths			
T0	T6	T12	P†
1.4 ± 0.06	1.26 ± 0.035	1.91 ± 0.073	.001
1.4 ± 0.08	1.33 ± 0.046	2.13 ± 0.073	.001
.563	.001	.001	

TABLE 2

Extended

Probing Depths			
T0	T6	T12	P†
1.17 ± 0.044	0.91 ± 0.043	0.63 ± 0.056	.001
1.19 ± 0.037	1.01 ± 0.02	0.82 ± 0.078	.001
.110	.001	.001	

TABLE 3

Extended

Probing Depths			
T0	T6	T12	P†
1.41 ± 0.06	1.26 ± 0.035	1.91 ± 0.073	.001
1.17 ± 0.044	0.91 ± 0.043	0.63 ± 0.056	.001
.001	.001	.001	

TABLE 4

Extended

Probing Depths			
T0	T6	T12	P†
1.4 ± 0.08	1.33 ± 0.046	2.13 ± 0.073	.001
1.19 ± 0.037	1.01 ± 0.02	0.82 ± 0.078	.001
.001	.001	.001	

prosthodontist who was not blind to the type of retention used. The dentures were delivered to the patients with emphasis on oral hygiene instructions, and the patients were recalled every 3 days in the first 3 weeks for denture adjustment and occlusal refinement and then every 3 months for further adjustments. These adjustments included replacement of the soft liner if separated from the denture, metal clips if worn, and

glaze re-application if detached or every 3 months as recommended by Sesma et al.³⁶

Evaluation of peri-implant tissues

Peri-implant tissue health was clinically evaluated at 2 weeks (T0), 6 months (T6), and 12 months (T12) after implant loading.

Plaque scores and bleeding scores were assessed using the modified plaque (MPI) and bleeding (MBI) indices, respectively, as reported by Mombelli et al.³⁷ A calibrated plastic periodontal probe (Kerr, Rastatt, Germany) was used to measure the distance between border of the peri-implant mucosa and the tip of the probe, and the measured distance was considered the peri-implant pocket depth (PD) (Figure 6).³⁸ MPI, MBI, and PD were recorded around each implant at 4 locations: lingually, mesially, buccally, and distally.

Also, implant stability (IS) was assessed at the time of implant placement and at subsequent visits using Periotest³⁹ (Periotest S, Medizintechnik Gulden e.K., Modautal, Germany) because primary stability is important to reduce the risk of implant failure.⁴⁰ Moreover, primary stability measurement at the time of implant placement using Periotest or implant stability quotient (ISQ) values is commonly used as a good indicator for immediate loading, as it allows the clinician to predict implant stability before implant treatment.⁴¹

The measurements were made at the abutment level with the rod held perpendicular to the longitudinal axis of implants. The Periotest values (PTV) scale ranged from -8 to +50. The smaller the value level, the higher the stability of the measured implant. Periotest values ranged from -8 to 0 and indicated adequate osseointegration.³⁴

For reasons of objectivity, evaluations of clinical parameters were performed by a periodontist (A) who was blind to the study groups after instruction and calibration with two different dentists (B and C).

Statistical analysis

Collected data were statistically analyzed using Statistical Package for Social Science (SPSS) version 17 (SPSS Inc, Chicago, Ill). Data was expressed as mean ± standard deviation. A one-sample Kolmogorov-Smirnov test was used to diagnose the normality of data distribution. The Friedman test was used to detect significant differences in plaque scores (MPI), bleeding scores (MBI), PDs, and IS between different observation times within the same group. The Mann-Whitney test was used to compare between groups (GI vs GII) and between sites (anterior vs posterior). The Spearman correlation test was used to test the correlation between IS and the other clinical parameters (MPI, MBI, PD).

RESULTS

For GI, the analysis could not be completed for 2 patients; 2 of the 4 implants failed during the period between the first and the second evaluation (T0 and T6), and they were planned for a bone grafting procedure. Another patient in the same group was excluded because of his inability to regularly attend the evaluation process due to severe illness. In GII, 1 patient died

TABLE 5

Comparison between anterior and posterior implants of GI vs GII at different observation times (T0, T6, and T12) in terms of implant stability*

Group/Time	Anterior (Periotest value)				Posterior (Periotest value)			
	T0	T6	T12	P†	T0	T6	T12	P†
GI, mean ± SD	-2.71 ± 0.40	-2.83 ± 0.69	-3.25 ± 0.583	.057	-0.71 ± 1.22	-0.88 ± 1.43	0.958 ± 1.98	.003§
GII, mean ± SD	-2.8 ± 0.582	-3.46 ± 0.144	-3.71 ± 0.257	.001§	-2.3 ± 0.500	-1.7 ± 1.45	-1.25 ± 2.15	.207
P‡	.856	.008§	.022§		.505	.062	.001§	

*GI indicates group I; GII, group II; T0, 2 weeks after; T6, 6 months after; T12, 12 months after.

†Friedman test, $P \leq .05$.

‡Mann-Whitney test, $P \leq .05$.

§Significance.

after 6 months, and the analysis could not be completed for 2 patients in the same group because they moved out of the area. Therefore, 24 patients (12 in each group) were available for evaluation.

The mean ± standard deviation of MPI, MBI, PDs, and IS Periotest values at different observation times (T0, T6, and T12) for anterior and posterior implants of both groups (GI and GII) are shown in Tables 1 through 5.

Plaque scores decreased significantly with advance of time for anterior and posterior implants of both groups (Friedman test, $P = .001$). GI demonstrated a significant increase in plaque scores compared with GII at all observation times (T0, T6, and T12) for both anterior and posterior implants (Mann-Whitney test, $P < .5$). For GI, posterior implants showed significantly higher plaque scores than anterior implants at different observation times (Mann-Whitney test, $P < .5$). For GII, posterior implants showed significant higher plaque scores than anterior implants at T0 only (Mann-Whitney test, $P < .5$), but there was no significant difference at T6 and T12.

Bleeding scores demonstrated a significant decrease with advance of time for anterior and posterior implants of both groups (Friedman test, $P = .001$). GI bleeding scores were significantly higher than GII at all observation times (T0, T6, and T12) for anterior and posterior implants (Mann-Whitney test, $P > .5$). Within GI, posterior implants showed a significant increase in bleeding score compared with anterior implants at all observation times (T0, T6, and T12), whereas in GII, these increases were at T0 and T6 only (Mann-Whitney test, $P > .5$).

Probing depths of GI significantly increased with advance of time (Friedman test, $P = .001$ for both anterior and posterior

implants), unlike the PD of GII, which decreased significantly with advance of time (Friedman test, $P = .001$ for both anterior and posterior implants). GI demonstrated a significant increase in PD compared with GII at all observation times (T0, T6, and T12) for both anterior and posterior implants (Mann-Whitney test, $P < .5$). Except for T0, posterior implants had a significant increase in PD compared with anterior implants in both groups (Mann-Whitney test, $P > .5$).

Implant stability increased significantly with the advance of time for anterior implants of GII (Friedman test, $P = .001$) and decreased significantly with advance of time for posterior implants of GI (Friedman test, $P = .003$). Anterior implants of GII showed a significant increase in IS at T6 and T12 compared with anterior implants of GI (Mann-Whitney test, $P < .05$). Posterior implants of GI showed a significant decrease in IS in comparison with those of GII only at T12 (Mann-Whitney test, $P < .05$; Table 5). Also, anterior implants showed a significant increase in IS at T6 and T12 compared with posterior implants in both groups (Mann-Whitney test, $P = .001$; Table 6). Implant stability was significantly positive correlated with MPI, MBI, and PD (Spearman correlation: $P = .006$, $.007$, and $.002$, respectively; Table 7).

DISCUSSION

In this study, we prospectively followed up peri-implant tissues in patients randomly assigned into 2 groups to receive either clip-retained or resilient liner-retained implant overdentures at different observational times (T0, T6, and T12).

TABLE 6

Comparison between anterior implants vs posterior implants of both groups at different observation times (T0, T6, and T12) in terms of implant stability*

Implant Location/Time	GI (Periotest value)				GII (Periotest value)			
	T0	T6	T12	P†	T0	T6	T12	P†
Anterior, mean ± SD	-2.71 ± 0.40	-2.83 ± 0.69	-3.25 ± 0.583	.057	-2.8 ± 0.582	-3.46 ± 0.144	-3.71 ± 0.257	.001§
Posterior, mean ± SD	-0.71 ± 1.22	-0.88 ± 1.43	0.958 ± 1.98	.003§	-2.3 ± 0.500	-1.7 ± 1.45	-1.25 ± 2.15	.207
P‡	.095	.001§	.001§		.09	.001§	.001§	

*GI indicates group I; GII, group II; T0, 2 weeks after; T6, 6 months after; T12, 12 months after.

†Friedman test, $P \leq .05$.

‡Mann-Whitney test, $P \leq .05$.

§Significance.

TABLE 7

Correlation between implant stability and other clinical parameters (PI, BI, PD)*

Parameter	Implant Stability	
	Correlation Coefficient	Spearman Correlation (P value)
Modified plaque index	.160†	.006
Modified bleeding index	.160†	.007
Probing	.182†	.002

*PI, plaque index; BI, bleeding index; PD, probing depth.

†Significant correlation at .01 level of significance (2-tailed).

GII patients (with clips) demonstrated significant increases in MPI, MBI scores, and PD compared with GII patients (with resilient soft liner) with advance of time for both anterior and posterior implants. This was in agreement with Elsyad and Shoukoui,³¹ who demonstrated the same significant increased difference in these clinical parameters between bar/clip and bar/resilient liner-retained mandibular 2-implant overdentures 1 year after overdenture insertion, and consistent with Davis et al,⁴² who reported a significant increase in PD with time when the overdenture was retained with clips over the bar.

This may be attributed to the space around/under the bar and around abutments that remain unobturated,⁴³ thus plaque accumulation with pathogenic bacteria producing peri-implant bleeding and gingival inflammation. Also, this may be attributed to another reason, which is the difficulty in performing sufficient oral hygiene measures by wearers of clip-retained overdentures, especially in the abutment region as stated by Reitz et al.⁴⁴

Peri-implant PD values were lower than those reported by Elsyad and Shoukoui.³¹ The explanation might be gingival recession and the absence of soft tissue proliferation around the abutments.⁴⁵ Moreover, it was presumed by Hammerle and Glauser⁴⁶ that, at healthy sites, the probe tip stops at around the level of the most coronal aspect of connective tissue adhesion to the implant neck, whereas at inflamed sites, the probe consistently reaches close to or comes in contact with the bone level.

On the contrary, GII demonstrated better soft tissue response with advance of time. This may be attributed to the fact that the soft liner female housing completely encircles the bar, completely obturates the space around it, and partially obturates space under it,²⁷ and this minimizes plaque formation. Another reason is that adherence of microorganisms and plaque to the silicone soft lining materials was found significantly less than that for acrylic resin denture base materials due to the smoother glazed surface of silicone soft liners created by the glazing material, as noted by Waters et al.⁴⁷ In addition, soft liners have a cushion effect that absorbs and distributes masticatory forces, thus reducing both stresses around implants and peri-implant bone. Also, this cushion effect conditions marginal gingival tissues with no undue trauma; therefore, it prevents alveolar bone loss and any break in epithelial attachment to implants. All these factors combined with cleansing and the antimicrobial effects of

the soft liner result in significantly better peri-implant soft tissue health.⁴⁸

This study showed a significant increase in MPI, MBI scores, and PD of posterior implants than anterior implants for both groups. This may be due to the difficulty in performing oral hygiene measures in posterior regions, which allows for plaque accumulation and gingival inflammation. This was confirmed by Behneke et al,⁴⁹ who noted that an increased incidence of remarkable plaque deposits represents patient difficulty in maintaining a high level of oral hygiene.

The gradual decrease in MPI and MBI for each single group with advancement of time is thought to be due to the emphasis on oral hygiene instructions and precise patient education during the scheduled follow-up visits.

An important finding in this study was that posterior implants showed a significant decrease in implant stability (PTV) than anterior implants in both groups at T6 and T12. This may result from the increased plaque accumulation (MPI) and PD in posterior implants. Another cause may be due to poor bone quality and high occlusal forces in the posterior region of the mandible.⁵⁰ In addition to the previously mentioned factors, stresses induced on splinted posterior implants by mandibular deformation (flexure) that occurs during jaw opening and protrusion may be another cause for reduced posterior implants stability. In 1976, Fischmann et al⁵¹ indicated that flexure was reduced with splints, but none of them can completely eliminate mandibular flexure. This suggests that splints may be subjected to a certain type of stress. These stresses could be transmitted and, over time, cause damage to the bone-implant interface. This concurs with Zarone et al.⁵²

Implant stability was greater in GII; the difference was significant only at T6 and T12 for anterior implants and at T12 for posterior implants. However, it can be explained by the greater stresses transmitted to implants through the metal clips of GI in comparison to the shock-absorbing silicone female housings of GII. This observation appears to be in agreement with the findings of dos Santos MB et al⁵³ and Tanoue et al,⁵⁴ who demonstrated that metal clips have induced more stresses than plastic ones. Furthermore, the presence of the soft liners compensates for the acrylic resin contraction that may occur during denture processing. This prevents the implants and the bar from coming into direct contact with the acrylic resin and minimizes implant overloading.⁵⁵

The results of this study may be limited by the small sample size, the short-term follow-up period, and the lack of a power analysis, so it is recommended to support this study with further investigations while using larger sample sizes, a power analysis, and longer observation times to evaluate this treatment modality and compare it with others.

CONCLUSIONS

Within the limitations of this study, the following can be concluded: (1) despite the splinting action of the bilateral posterior ready-made bars and the advantage that this design can be used in patients with tapered or V-shaped arches, they cannot be proposed as a promising design for supporting immediate loaded implant-assisted mandibular overdentures; (2) with regard to peri-implant soft tissue health, bar/resilient

liners can be considered better than the bar/clips when used with bilateral posterior bars for retaining implant-supported mandibular overdentures; and (3) implants installed in canine areas provide better stability and tissue health than those inserted in first molar areas.

ABBREVIATIONS

ART: acid etched roughened titanium
IAB: instant adjusting bar
IS: implant stability
ISQ: implant stability quotient
MBI: modified bleeding index
MPI: modified plaque index
PD: probing depth
PTV: periostest values
SPSS: statistical package for social science

NOTE

The authors declare no conflict of interest. The study was self-funded by the authors.

REFERENCES

1. Assad AS, Abd El-Dayem MA, Badawy MM. Comparison between mainly mucosa-supported and combined mucosa-implant-supported mandibular overdentures. *Implant Dent.* 2004;13:386–94.
2. Van der Bilt A, van Kampen FM, Cune MS. Masticatory function with mandibular implant-supported overdentures fitted with different attachment types. *Eur J Oral Sci.* 2006;114:191–196.
3. Hyland R, Ellis J, Thomason M, El-Feky A, Moynihan P. A qualitative study on patient perspectives of how conventional and implant-supported dentures affect eating. *J Dent.* 2009;37:718–723.
4. Emami E, Heydecke G, Rompré PH, de Grandmont P, Feine JS. Impact of implant support for mandibular dentures on satisfaction, oral and general health-related quality of life: a meta-analysis of randomized-controlled trials. *Clin Oral Implants Res.* 2009;20:533–544.
5. Sadig W. A comparative in vitro study on the retention and stability of implant-supported overdentures. *Quintessence Int.* 2009;40:313–319.
6. Feine JS, Carlsson GE, Awad MA, et al. The McGill consensus statement on overdentures. Mandibular two-implant overdentures as first choice standard of care for edentulous patients. *Gerodontology.* 2002;19:3–4.
7. Jacobs R, Schotte A, Van Steenberghe D, Quirynen M, Naert I. Posterior jaw bone resorption in osseointegrated implant-supported overdentures. *Clin Oral Implants Res.* 1992;3:63–70.
8. Kordatzis K, Wright PS, Meijer HJ. Posterior mandibular residual ridge resorption in patients with conventional dentures and implant overdentures. *Int J Oral Maxillofac Implants.* 2003;18:447–452.
9. de Jong MH, Wright PS, Meijer HJ, Tymstra N. Posterior mandibular residual ridge resorption in patients with overdentures supported by two or four endosseous implants in a 10-year prospective comparative study. *Int J Oral Maxillofac Implants.* 2010;25:1168–74.
10. Tymstra N, Raghoebar GM, Vissink A, Meijer HJ. Maxillary anterior and mandibular posterior residual ridge resorption in patients wearing a mandibular implant-retained overdenture. *J Oral Rehabil.* 2011;38:509–516.
11. Raedel M, Lazarek-Scholz K, Marr'e B, Boening KW, Walter MH. Posterior alveolar ridge resorption in bar-retained mandibular overdentures: 10-year results of a prospective clinical trial. *Clin Oral Implants Res.* 2015;26:1397–1401.
12. Heckmann SM, Winter W, Meyer M, Weber HP, Wichmann MG. Overdenture attachment selection and the loading of implant and denture-bearing area. Part 2: a methodical study using five types of attachment. *Clin Oral Implants Res.* 2001;12:640–647.
13. Elysyad MA, Hegazy SA, Hammouda NI, Al-Tonbary GY, Habib AA.

Chewing efficiency and electromyographic activity of masseter muscle with three designs of implant-supported mandibular overdentures. A cross-over study. *Clin Oral Implants Res.* 2014;25:742–748.

14. Elysyad MA, Elsaadawy MG, Abdou AM, Habib AA. Effect of different implant positions on strain developed around four implants supporting a mandibular overdenture with rigid telescopic copings. *Quintessence Int.* 2013;44:679–686.
15. Walton JN, MacEntee MI. A retrospective study on the maintenance and repair of implant-supported prostheses. *Int J Prosthodont.* 1993;6:451–455.
16. Mericske-Stern R, Taylor TD, Belser U. Management of the edentulous patient. *Clin Oral Imp Res.* 2000;11:108–125.
17. Caruso G, Cattaneo A. Removable prosthesis supported by implants according to the Cagliari modified conometry technique: case report. *Int J Periodontics Restorative Dent.* 2007;27:259–265.
18. Trakas T, Michalakis K, Kang K, Hirayama H. Attachment systems for implant retained overdentures: a literature review. *Implant Dent.* 2006;15:24–34.
19. MacEntee MI, Walton JN, Glick N. A clinical trial of patient satisfaction and prosthodontic needs with ball and bar attachments for implant-retained complete overdentures: three-year results. *J Prosthet Dent.* 2005;93:28–37.
20. Dudic A, Mericske-Stern R. Retention mechanisms and prosthetic complications of implant-supported mandibular overdentures: long-term results. *Clin Implant Dent Relat Res.* 2002;4:212–219.
21. Naert I, Alsaadi G, Quirynen M. Prosthetic aspects and patient satisfaction with two-implant-retained mandibular overdentures: a 10-year randomized clinical study. *Int J Prosthodont.* 2004;17:401–410.
22. Naert I, Alsaadi G, van Steenberghe D, Quirynen M. A 10-year randomized clinical trial on the influence of splinted and unsplinted oral implants retaining mandibular overdentures: peri-implant outcome. *Int J Oral Maxillofac Implants.* 2004;19:695–702.
23. Ender A, Mehl A. Accuracy of complete-arch dental impressions: a new method of measuring trueness and precision. *J Prosthet Dent.* 2013;109:121–128.
24. Wee AG, Aquilino SA, Schneider RL. Strategies to achieve fit in implant prosthodontics: a review of the literature. *Int J Prosthodont.* 1999;12:167–178.
25. Deslis A, Hasan I, Bourauel C, Bayer S, Stark H, Keilig L. Numerical investigations of the loading behaviour of a prefabricated non-rigid bar system. *Ann Anat.* 2012;194:538–544.
26. Biesaga RK. *Dyna Instant Adjusting Bar Connection Manual Engels.* Bergen op zoom, Netherlands: Dyna Dental Engineering; 2004.
27. Adrian ED, Krantz WA, Ivanhoe JR. The use of processed silicone to retain the implant-supported tissue-borne overdenture. *J Prosthet Dent.* 1992;67:219–222.
28. Kawano F, Koran A, Asaoka K, Matsumoto N. Effect of soft denture liner on stress distribution in supporting structures under a denture. *Int J Prosthodont.* 1993;6:43–49.
29. Kiat-Amnuay S, Khan Z, Gettleman L. Overdenture retention of four resilient liners over an implant bar. *J Prosthet Dent.* 1999;81:568–573.
30. Shaygan F, Khan Z, Gettleman L. Retention and longevity of resilient denture liners in implant overdentures. *J Dent Res.* 1993;72:272.
31. Elysyad MA, Shoukoui AH. Resilient liner vs. clip attachment effect on peri-implant tissues of bar-implant-retained mandibular overdenture: a 1-year clinical and radiographical study. *Clin Oral Implants Res.* 2010;21:473–480.
32. Elysyad MA. Soft liner/clip attachment for bar retained implant overdentures. A technical note *J Oral Implantol.* 2016;42:442–445.
33. Barzilay I, Graser GN, Iranpour B, Natiella JR. Immediate implantation of pure titanium in to an extraction socket: report of a pilot procedure. *Int J Oral Maxillofac Implants.* 1991;6:277–284.
34. El-Amier NM, Elsayh EA, El-Motaam HA, Al-Shahat MA. Effect of implant location on palateless complete overdenture retention: preliminary study. *J Dent Implant.* 2015;5:6–11.
35. De Vries CT, Meijer HJ. Replacement of a clip in one session. *J Prosthet Dent.* 1999;82:492–493.
36. Sesma N, Lagana' DC, Morimoto S, Gil C. Effect of denture surface glazing on denture plaque formation. *Braz Dent J.* 2005;16:129–134.
37. Mombelli A, van Oosten MAC, Schürch E, Lang NP. The microbiota associated with successful or failing osseointegrated titanium implants. *Oral Microbiol Immunol.* 1987;2:145–151.
38. Eickholz P, Grotkamp FL, Steveling H, Mühling J, Staehle HJ.

- Reproducibility of peri-implant probing using a force-controlled probe. *Clin Oral Implants Res.* 2001;12:153–158.
39. Olivé J, Aparicio C. Periotest method as a measure of osseointegrated oral implant stability. *Int J Oral Maxillofac Implants.* 1990;5:390–400.
 40. Sennerby L, Meredith N. Implant stability measurements using resonance frequency analysis: biological and biomechanical aspects and clinical implications. *Periodontol 2000.* 2008;47:51–66.
 41. Song YD, Jun SH, Kwon JJ. Correlation between bone quality evaluated by cone-beam computerized tomography and implant primary stability. *Int J Oral Maxillofac Implants.* 2009;24:59–64.
 42. Davis RK, Renner RP, Antos EW Jr, Schissel ER, Baer PN. A two-year longitudinal study of the periodontal health status of overdenture patients. *J Prosthet Dent.* 1981;45:358–363.
 43. Lachmann S, Kimmerle-Müller E, Gehring K, et al. A comparison of implant-supported, bar-or ball-retained mandibular overdenture: a retrospective clinical, microbiologic, and immunologic study of 10 edentulous patients attending a recall visit. *Int J Prosthodont.* 2007;20:37–42.
 44. Reitz PV, Weiner MG, Levin B. An overdenture survey: second report. *J Prosthet Dent.* 1980;43:457–462.
 45. Oetterli M, Kiener P, Mericske-Stern R. A longitudinal study on mandibular implants supporting an overdenture: the influence of retention mechanism and anatomic-prosthetic variables on peri-implant parameters. *Int J Prosthodont.* 2001;14:536–542.
 46. Hämmerle CH, Glauser R. Clinical evaluation of dental implant treatment. *Periodontol 2000.* 2004; 34:230–239.
 47. Waters MG, Williams DW, Jagger RG, Lewis MA. Adherence of *Candida albicans* to experimental denture soft lining materials. *J Prosthet Dent.* 1997;77:306–312.
 48. Graham BS, Jones DW, Sutow EJ. Clinical implication of resilient denture lining material research. Part I: flexibility and elasticity. *J Prosthet Dent.* 1989;62:421–428.
 49. Behneke A, Behneke N, d'Hoedt B. The Longitudinal clinical effectiveness of ITI solid-screw implants in partially edentulous patients: a 5 year follow-up report. *Int J Oral Maxillofac Implants.* 2000;15:633–645.
 50. Blanes RJ, Bernard JP, Blanes ZM, Belser UC. A 10-year prospective study of ITI dental implants placed in the posterior region. I: clinical and radiographic results. *Clin Oral Implants Res.* 2007;18:699–706.
 51. Fischman BM. The influence of fixed splints on mandibular flexure. *J Prosthet Dent.* 1976;35:643–647.
 52. Zarone F, Apicella A, Nicolais L, Aversa R, Sorrentino R. Mandibular flexure and stress build-up in mandibular full-arch fixed prostheses supported by osseointegrated implants. *Clin Oral Implants Res.* 2003;14:103–114.
 53. dos Santos MB, Bacchi A, Correr-Sobrinho L, Consani RL. The influence of clip material and cross sections of the bar framework associated with vertical misfit on stress distribution in implant-retained overdentures. *Int J Prosthodont.* 2014;27:26–32.
 54. Tanoue M, Kanazawa M, Takeshita S, Minakuchi S. Effects of clip materials on stress distribution to maxillary implant overdentures with bar attachments. *J Prosthet Dent.* 2016;115:283–289.
 55. Cain JR, Mitchell DL. Soft liner-retained, implant-supported overdenture: a technical note. *Int J Oral Maxillofac Implants.* 1998;13:857–860.