

# Age-related variations of varicose veins anatomy

Alberto Caggiati, MD, PhD, Caterina Rosi, BSc, Rosemarie Heyn, VMD, PhD,  
Marco Franceschini, MD, and Maria Cristina Acconcia, MD, Rome, Italy

**Background:** Primary varicose veins are commonly considered a progressive disease starting from the saphenous junctions and extending to tributaries in a retrograde fashion along the saphenous trunks. This theory has been criticized by studies indicating different patterns of development and progression of varicose veins. To contribute to the understanding of the pathogenesis of the disease, the anatomy of the venous bed was comparatively evaluated by duplex sonography in patients with varicose veins with a marked difference in age.

**Methods:** The study included 100 varicose limbs in 82 patients aged <30 years and 238 limbs in 183 patients aged >60 years. Veins were designated as saphenous veins (SVs), tributaries of the SVs (STVs), and veins not connected with the SVs (NSVs). Four main anatomic patterns were comparatively evaluated: (1) varicose changes only along SVs, (2) varicose changes along SVs and STVs, (3) varicose changes only in STVs, and (4) varicose changes only in NSVs.

**Results:** SVs were normal in 44% of varicose limbs. In most limbs from young subjects, varicose changes afflicted only STVs (25%) and NSVs (36%). Varicose SVs were more frequent in the older group (62%) than in younger one (39%) owing to a higher prevalence of limbs with combined SV and STV varicosities (respectively, 59% and 37%). In the older group, varicosities in the STVs were more frequently observed in association with incompetence of the SV trunks.

**Conclusion:** The frequent occurrence of normal SVs in varicose limbs of all patients does not support the crucial role commonly credited to SVs in the pathogenesis of primary varicosities. Moreover, the SV trunks were normal in most varicose limbs from young patients. These findings suggest that varicose disease may progressively extend in an antegrade fashion, spreading from the STVs to the SVs. This hypothesis suggests that the saphenous trunks could be spared in the treatment of a relevant number of varicose legs. Prospective longitudinal studies with serial duplex evaluations of large series of extremities are necessary to confirm this hypothesis. (J Vasc Surg 2006;44:1291-5.)

Primary varicose veins are commonly considered a progressive disease starting from one point of incompetence. The belief has been long held that the initial incompetent points are the saphenous junctions, and that “. . . the saphenous trunks are responsible for a progressive retrograde spreading of varicose veins . . .”<sup>1</sup> (Fig 1). This “safenocentric” theory dates back to the seventh century (Paulus of Aegina), was diffused many centuries later by Friedrich Trendelenburg,<sup>1</sup> and finally explained on a scientific basis by Ludbrook and Beale only in 1963.<sup>2</sup>

Although widely accepted, the safenocentric theory has been criticized. In 1870, Callender pointed out that many varicose limbs show a normal great saphenous vein (GSV) trunk.<sup>3</sup> This was confirmed by McPheeters,<sup>4</sup> who demonstrated in 1930 by dynamic venography that saphenous veins (SVs) were competent in 71% of limbs with “early and beginning varicose veins” and in 30% of “advanced or moderately advanced cases.” One year later, the role of incompetence of the safenofemoral junction (SFJ) was questioned by Turner Warwick,<sup>5</sup> who affirmed that it is competent in many varicose limbs. Cotton<sup>6</sup> demonstrated in 1961 that the typical changes of varicose disease, including vein dilation, elongation, and tortuosity, appear first

and are greater in saphenous tributaries. He also noted that “. . . the change in calibre of the GSV is often abrupt and coincides with the point of entry of a large varicose tributary.”<sup>6</sup> Finally, in 1967 Fegan<sup>7</sup> affirmed that “. . . an ascending uniform gradual dilatation of the superficial veins occurs.”

More recently, the safenocentric theory was challenged by duplex ultrasonography, which demonstrated that (1) in a significant number of limbs with varicosities, the saphenous trunks and junctions are normal,<sup>8-10</sup> (2) reflux in the proximal saphenous trunks does not necessarily imply junctional incompetence because it can also originate from junctional tributaries,<sup>11-14</sup> (3) an incompetent SFJ may coexist with a healthy GSV,<sup>15</sup> and (4) in most limbs with varicose veins, only a segment of the GSV is incompetent.<sup>16</sup>

To contribute to the understanding of the development and progression of the varicose disease, the anatomy of the venous bed was comparatively evaluated by duplex ultrasonography in 338 limbs with primary varicose veins. The patients in the study had a marked difference in age and thus with a presumable wide difference in duration of the disease.

## MATERIALS AND METHODS

All patients considered for this study were referred to a private vascular laboratory (Villa Mafalda Hospital, Rome, Italy). The comparative evaluation included 338 limbs with primary varicose veins (CEAP classes C2 to C6). Group A consisted of 100 limbs in 82 consecutive patients (11 men, 71 women) aged <30 years (mean, 26.9 years), and group B consisted of 238 limbs in 183 consecutive patients (78 men and 105 women) aged >60 years (mean, 69.7 years). All patients gave their informed consent to be included in the study. Varicose limbs were excluded for the

From the Department of Anatomy and Department of Health and Great Vessels “Attilio Reale,” University of Rome “La Sapienza,” and Villa Mafalda Hospital.

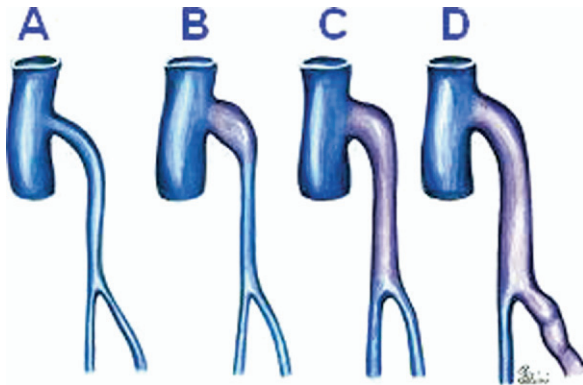
Competition of interest: none.

Reprint requests: Alberto Caggiati, MD, Department of Anatomy, University of Rome, “La Sapienza,” Via Borelli 50, 00161 Rome, Italy (e-mail: alberto.caggiati@uniroma1.it).

0741-5214/\$32.00

Copyright © 2006 by The Society for Vascular Surgery.

doi:10.1016/j.jvs.2006.07.040



**Fig 1.** Progression of varicose changes (from A to D) according to the Trendelenburg saphenocentric theory.

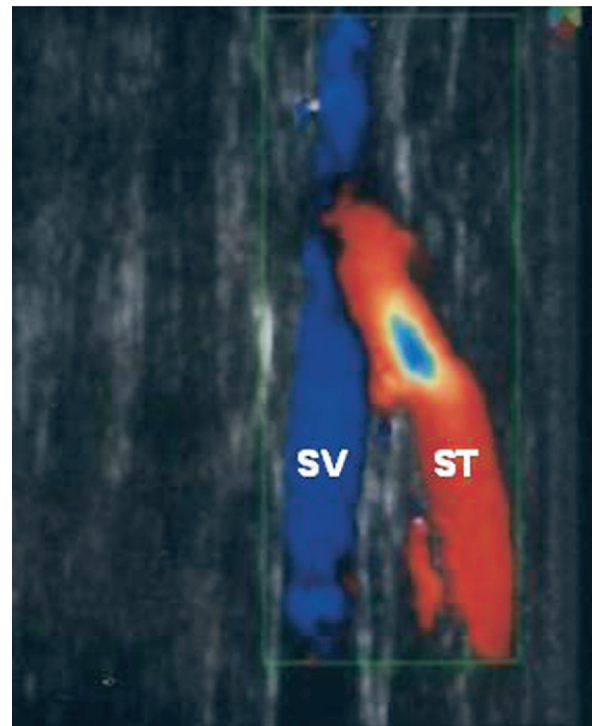
**Table I.** Classification of clinical severity according to CEAP<sup>18</sup>

	Pattern			
	1	2	3	4
Group A				
C2	1	17	16	27
C3	0	14	8	7
C4	1	5	1	2
C5	0	0	0	0
C6	0	1	0	0
Group B				
C2	2	62	20	40
C3	1	44	6	11
C4	4	27	4	8
C5	1	5	0	0
C6	0	2	1	0

following indications: previous treatment of varicosities either operatively or with sclerotherapy, clinical or duplex findings of superficial or deep venous thrombosis, or angiodysplastic disorders.

Vein morphology and valvular competence were evaluated by duplex ultrasonography in the standing position at the SFJ and saphenopopliteal junction (SPJ), along the GSV and the small saphenous vein (SSV), their tributaries and other epifascial veins. Vein patency was evaluated in supine position.<sup>17</sup> The clinical severity of the varicose disease was assigned according to CEAP (Table I).<sup>18</sup>

**Vein identification and terminology.** SVs were identified by their topography and interfascial path.<sup>19-22</sup> In fact, they course deep in the subcutaneous tissue, within the saphenous compartment defined by the hyperechoic muscular and saphenous fasciae.<sup>19-20</sup> Longitudinal and oblique epifascial veins, which course close to the dermis to end into the SVs (namely, saphenous accessories and circumflex veins), were designated as saphenous vein tributaries (SVTs). According to CEAP statements,<sup>18</sup> SVs and SVTs were classified as “varicose” if dilated and incompetent. Reflux in SVs and in larger SVTs was defined as a retrograde flow lasting >0.5 seconds.<sup>23</sup> Tubular SVs with demon-



**Fig 2.** Color flow duplex imaging shows reverse flow (in red) in a saphenous tributary (ST) joining a competent saphenous vein (SV).

strated reflux were also classified as varicose. Varicose veins >3 mm in which no direct connections with the SVs could be demonstrated by clinical and duplex examinations were called “not-saphenous” veins (NSVs).

**Comparative evaluation and statistical analysis.** To compare anatomic findings, four main patterns were considered:

Pattern 1—varicose changes were limited to the SV trunks.  
Pattern 2—varicose changes affected the SV trunks and extended to one or more of their tributaries.

Pattern 3—varicose changes affected only SVTs (Fig 2). SV trunks were competent and normally sized, as described by Browse et al.<sup>24</sup>

Pattern 4—varicose changes affected only NSVs. SV trunks and SVTs were competent and normally sized.

Categoric data were presented as absolute frequencies and percent values. Fisher’s exact probability test was performed to evaluate the significance of the differences in the proportion of patterns between the two groups of limbs. This comparison was performed on overall patients and on patients stratified by sex. Bonferroni’s correction was applied for multiple comparisons. The odds ratio was also computed to evaluate the possible role of aging on the occurrence of pattern 2 in the overall group and when stratifying by sex (Mantel-Haenszel odds ratio).  $P \leq .05$  was considered statistically significant.

**Table II.** Prevalence of the anatomic patterns in the two groups of limb

	Pattern				Total
	1 n (%)	2 n (%)	3 n (%)	4 n (%)	
Group A					
Males	0 (0)	5 (5)	4 (4)	6 (6)	15
Females	2 (2)	32 (32)	21 (21)	30 (30)	85
Total	2 (2)	37 (37)	25 (25)	36 (36)	100
Group B					
Males	3 (1)	59 (24)	12 (5)	29 (12)	103
Females	5 (2)	81 (34)	19 (8)	30 (12)	135
Total	8 (3)	140 (58)	31 (13)	59 (24)	238
A + B	10 (3)	177 (52)	56 (16)	95 (28)	338

**Table III.** Prevalence of saphenic junctions incompetence

	Group A n (%)	Group B n (%)
SFJ reflux	28 (28)	88 (37)
SPJ reflux	10 (10)	52 (22)
Total	38 (38)	140 (59)

SFJ, Saphenofemoral junction; SPJ, saphenopopliteal junction.

## RESULTS

The prevalence of the four anatomic patterns differed between the two groups of limbs (Table II). In particular:

1. The SVs were normal in 151 (44%) of 338 limbs. The GSV was normal in 68% of varicose limbs of group A and in 52% of group B. The SSV was normal in 86% of varicose limbs of group A and in 66% of group B. In all these limbs, varicose changes affected only SVTs and NSVs (patterns 3 and 4). These patterns were more frequent in limbs of group A (25% and 36%, respectively) than in those of group B (13% and 24.8%, respectively).
2. The prevalence of limbs with a varicose SV (patterns 1 and 2) was significantly higher in the group B than in group A (62% vs 39%,  $P = .0001$ ). This was primarily due to a much larger proportion of limbs with pattern 2 (59% and 37%, respectively). The differences in the proportion of patterns 2 and 3 between the two groups of limbs was significant in the overall population ( $P = .0009$ ) and in the female subpopulation ( $P < .05$ ). In the male subpopulation, this comparison was not significant owing to the low number of legs included. However, the Mantel-Haenszel odds ratio demonstrated that the relationship between age and patterns 2 and 3 was homogeneous between sexes ( $\chi^2, 0.17_1, P = .6826$ ).
3. The prevalence of junctional incompetence (Table III) was significantly higher in limbs from older patients (59%) than in those from younger subjects (38%) ( $P = .0005$ ).

Junctional refluxes coexisted with normal SVs in 2.9%, whereas varicosities involving the SV trunks did

not imply junctional incompetence in 6.8% of limbs. Nonjunctional GSV refluxes were more frequent in legs from older patients (21%) than in those from younger ones (13%). Conversely, nonjunctional SSV refluxes were more frequent in limbs belonging to younger subjects (40% vs 32%).

4. The prevalence of limbs with two or more incompetent sites that do not communicate with or affect each other were significantly higher in the group of older patients (26%) than in younger ones (9%) ( $P = .0004$ ).

## DISCUSSION

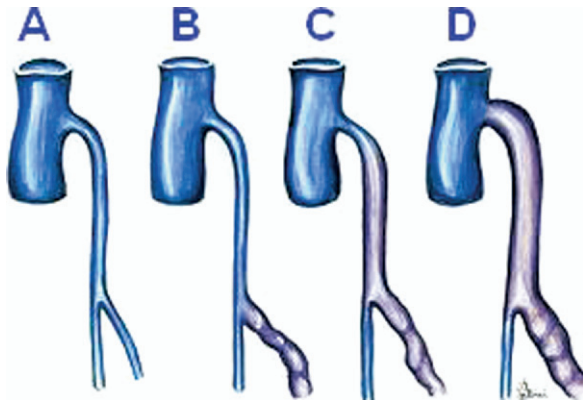
SV ablation or obliteration is currently considered of pivotal importance for the treatment of varicose limbs. This attitude is based on the widely accepted saphenocentric theory of a retrograde spreading of varicose changes along the SVs. In agreement with previous reports,<sup>3-12,15,16,23</sup> the comparative evaluation of duplex ultrasonographic findings from varicose patients of different ages suggests a reconsideration of the role commonly ascribed to the SV trunks and junctions in the pathogenesis of the varicose disease. In fact:

1. The overall prevalence of normal SVs (44%) does not support a crucial role of SVs in the pathogenesis and progression of primary varicose veins.
2. Most limbs from younger subjects (61%) showed varicose changes limited to SVTs (25%) and NSVs (36%). This supports the notion that reflux can develop in epifascial veins in the absence of saphenous junctional or truncal incompetence, or both.<sup>8,10,15,16,23</sup>

Epifascial veins could be susceptible to those changes occurring to initiate reflux owing to their unfavorable anatomic characteristics.<sup>19,25</sup> The wall of epifascial vein is thinner and less muscularized than that of the SVs trunks.<sup>26</sup> In addition, SVTs and NSVs are surrounded only by a yielding layer of fat that cannot counteract vessel dilation. On the contrary, SVs run closely encased by the two unyielding connective walls of the saphenous compartment, which works like a sort of shield against vessel dilation.<sup>19</sup> Finally, varicose changes of SVTs and NSVs are more easily evidenced by patients and clinicians because these veins course close to the dermis.

The overall prevalence of limbs with varicose changes limited to SVTs and NSVs (44%) is comparable with recent reports but is higher than in older articles.<sup>8,10,12,23,27</sup> Such an apparent discrepancy can be explained by:

1. the rigorous implementation of the recommendations published in 2002 for SV identification,<sup>21</sup> which prevent possible confusions between SVs and other superficial veins;
2. differences in designation of "not saphenous" veins;
3. the benefit of comprehensive whole-leg duplex evaluation, not limited to the GSV or SSV trunks; and
4. presumably differing populations. In fact, the present series included patients who did not come from the public health care system. Therefore, many of them



**Fig 3.** Progression of varicose changes (from A to D) according to the ascending centripetal hypothesis.

were probably mainly concerned with the aesthetic aspects of varicose disease rather than with more significant clinical symptoms.

The greater prevalence of pattern 2 and the lower prevalence of pattern 3 observed in the limbs from older patients led us to hypothesize that at least in part of the limbs, a centripetal progression of the varicose disease from saphenous tributaries to the saphenous trunks occurs (Fig 3).

Limbs from older subjects showed higher CEAP scores and a greater proportion of either varicose SVs and junctional incompetence. These findings agree with previous experiences<sup>13,28-30</sup> and are suggestive for an ascending progression of the reflux along the saphenous trunk, as demonstrated by duplex ultrasonography in 2005.<sup>29</sup>

A centripetal progression of the varicose disease from SVTs to SVs and its upward extension along the saphenous trunks do not contrast with classic postulates of phlebologic education. In fact, these were formulated many decades before diffusion of duplex sonography, when only limbs with full-blown varicose changes and predominant SV involvement, were considered by clinicians. Incompetence at the SV junctions and/or varicosity of the SV trunks “. . . makes the disease more serious from a hemodynamic point of view . . .” and “. . . reflects a stage where disease is more widespread rather than being the initiating factor.”<sup>13,30</sup>

The prevalence of limbs with two or more independent varicose sites is significantly higher in the group of older subjects. In agreement with previous studies,<sup>15,24,29,31</sup> this finding suggests that in a relevant part of limbs, varicogenesis occurs as a multifocal process.

**Clinical implications.** The hypothesis of a centripetal progression of varicose veins from SVTs and NSV to the SVs would imply that early treatment of varicose SVTs and NSVs might prevent the development of more important varicose vein changes by blocking their extension to the saphenous trunks. In agreement with previous reports, the present findings indicate that the treatment of the saphenous junctions and trunks possibly results in an “excessive

and unnecessary surgery,”<sup>11,12,15,16,29,32</sup> especially in young subjects with varicose veins.<sup>15</sup>

## CONCLUSIONS

The present findings corroborate previous experiences indicating an antegrade progression of reflux along the SVs and suggest a centripetal spreading of the varicose disease from the tributaries to the trunks. In addition, a multicentric progression of the disease occurs in a relevant part of limbs. The questions about the development of reflux (descending or ascending, centrifugal or centripetal) can be answered only by long-term prospective studies based on serial duplex ultrasonography evaluations of large series of untreated varicose limbs. Similar studies are also needed to possibly confirm the efficiency of early treatment of SVTs and NSVs in preventing the evolution of the varicose disease.

## AUTHOR CONTRIBUTIONS

Conception and design: AC  
Analysis and interpretation: AC, CR  
Data collection: AC, MF  
Writing the article: AC, RH  
Critical revision of the article: AC, RH  
Final approval of the article: AC  
Statistical analysis: MA  
Obtained funding: Not applicable  
Overall responsibility: AC

## REFERENCES

1. Trendelenburg F. Über die Tunderbindung der Vena Saphena Magna bie unterschenkel varicen. *Beitr Z Clin Chir* 1890;7:195.
2. Ludbook J, Beale G. Femoral venous valves in relation to varicose veins. *Lancet* 1962;1:79-82.
3. Callender GW. Diseases of the veins. In: Holmes T, editor. *System of surgery*. London: Parker and Bourn, 1862. Quoted by Browse NL, Burnand KG, Thomas ML: *Malattie delle vene*. Momento Medico; 1992. p. 173.
4. Mc Pheeters HO, Rice CO. Varicose veins-the circulation and direction of venous flow. *Surg Gynecol Obstet* 1929;49:29-35.
5. Turner Warwick W. *The rational treatment of varicose veins and varicocele*. London: Faber & Faber; 1931. p. 47.
6. Cotton LT. Varicose veins. Gross anatomy and development. *Br J Surg* 1961;48:589-98.
7. Fegan G. *Varicose veins*. Gorge Fegan, editor, Hereford: Berrington Press; 1967.
8. Labropoulos N, Kang SS, Mansour MA, Giannoukas AD, Buckman J, Baker WH. Primary superficial vein reflux with competent saphenous trunk. *Eur J Vasc Endovasc Surg* 1999;18:201-6
9. Wong JKF, Duncan JL, Nichols DM. Whole-leg duplex mapping for varicose veins: observations on patterns of reflux in recurrent and primary legs, with clinical correlations. *Eur J Vasc Endovasc Surg* 2003;25:267-75.
10. Seidel A, Miranda F, Juliano Y, Novo N, dos Santos J, de Souza D. Prevalence of varicose veins and venous anatomy in patients without truncal saphenous reflux. *Eur J Vasc Endovasc Surg* 2004;28:387-90.
11. Abu-Own A, Scurr JH, Coleridge Smith P. Saphenous vein reflux without incompetence at the saphenofemoral junction. *Br J Surg* 1994; 81:1452-4.
12. Jiang P, van Rij AM, Christie RA, Hill GB, Thomson IA. Non-saphenofemoral venous reflux in the groin in patients with varicose veins. *Eur J Vasc Endovasc Surg* 2001;21:550-7.

13. Barros MVL, Labropoulos N, Ribeiro ALP, Okawa RY, Machado FS. Clinical significance of ostial great saphenous vein reflux. *Eur J Vasc Endovasc Surg* 2006;31:320-4.
14. Pieri A, Vannuzzi A, Duranti A, Vin F, Benelli L, Michelagnoli S, Chaillard Ph, De Saint Pierre G. Role central de la valvole preostiale de la veine saphene interne dans la ganesee des varices tronculaires des membres inferieurs. *Phlebologie* 1995;48:227-9.
15. Labropoulos N, Leon L, Engelhorn C, Amaral S, Rodriguez H, Kang S, et al. Sapheno-femoral junction reflux in patients with a normal saphenous trunk. *Eur J Vasc Endovasc Surg* 2004;28:595-9.
16. Engelhorn C, Engelhorn A, Cassou M, Salles-Cunha S. Patterns of saphenous reflux in women with primary varicose veins. *J Vasc Surg* 2005;41:645-51.
17. Fraser JD, Andersen DR. Deep venous thrombosis: recent advances and optimal investigation with US. *Radiology* 1999;211:9-24.
18. Eklof B, Rutherford RB, Bergan JJ, Carpentier PH, Gloviczki P, Kistner RL, et al. American Venous Forum International Ad Hoc Committee for Revision of the CEAP Classification. Revision of the CEAP classification for chronic venous disorders: consensus statement. *J Vasc Surg* 2004;40:1248-52.
19. Caggiati A. Fascial relationships of the long saphenous vein. *Circulation* 1999;100:2547-9.
20. Caggiati A. Fascial relationships of the short saphenous vein. *J Vasc Surg* 2001;34:241-6.
21. Caggiati A, Bergan JJ, Gloviczki P, Jantet G, Wendell-Smith CP, Partsch H. Nomenclature of the veins of the lower limbs: an international interdisciplinary consensus statement. *J Vasc Surg* 2002;36:416-22.
22. Caggiati A, Bergan JJ, Gloviczki P, Eklof B, Allegra C, Partsch H. Nomenclature of the veins of the lower limbs: extensions, refinements and clinical application. *J Vasc Surg* 2005;41:719-24.
23. Labropoulos N, Tiongson J, Pryor L, Tassiopoulos AK, Kang SS, Mansour A, et al. Nonsaphenous superficial vein reflux. *J Vasc Surg* 2001;34:872-87.
24. Browse NL, Burnand KG, Lea Thomas M. *Disease of the veins*. London: Edward Arnold; 1988. p. 158
25. Caggiati A, Mendoza E. Segmental hypoplasia of the great saphenous vein and varicose disease. *Eur J Vasc Endovasc Surg* 2004;28:257-61.
26. Caggiati A. Fascial relations and structure of the tributaries of the saphenous veins. *Surg Radiol Anat* 2000;22:191-6.
27. Labropoulos N, Mansour MA, Nicolaides AN, Baker WH. Where does the reflux start? *J Vasc Surg* 1997;26:736-42.
28. Sarin S, Shields DA, Farrah J, Scurr JH, Coleridge-Smith P. Does venous function deteriorate in patients waiting for varicose vein surgery? *J R Soc Med* 1993;86:21-3.
29. Labropoulos N, Leon L, Kwon S, Tassiopoulos A, Gonzales-Fajardo JA, Kang SS, et al. Study of the venous reflux progression. *J Vasc Surg* 2005;41:291-5.
30. Cooper D, Hillman-Cooper CS, Barker SG, Hollingsworth SJ. Primary varicose veins: the sapheno-femoral junction, distribution of varicosities and patterns of incompetence. *Eur J Vasc Endovasc Surg* 2003;25:53-9.
31. Labropoulos N, Tassiopoulos AK, Bhatti AF, Leon L. Development of reflux in the perforator veins in limbs with primary venous disease. *J Vasc Surg* 2006;43:558-62.
32. Goren G, Yellin AE. Primary varicose veins: topographic and hemodynamic correlations. *J Cardiovasc Surg* 1990;31:672-7.

Submitted Mar 20, 2006; accepted Jul 25, 2006.