



TITLE:

# Y-shaped Muscular Wrapping Technique Avoiding Re-infection of a Replaced Aortic Graft: A Cadaveric Study

AUTHOR(S):

Tsuge, Itaru; Saito, Susumu; Kataoka, Masako;  
Yamanaka, Hiroki; Katsube, Motoki; Sakamoto,  
Michiharu; Morimoto, Naoki

---

CITATION:

Tsuge, Itaru ...[et al]. Y-shaped Muscular Wrapping Technique Avoiding Re-infection of a Replaced Aortic Graft: A Cadaveric Study. *Plastic and Reconstructive Surgery - Global Open* 2021, 9(6): e3626.

ISSUE DATE:

2021-06

URL:

<http://hdl.handle.net/2433/277094>

RIGHT:

Copyright © 2021 The Authors. Published by Wolters Kluwer Health, Inc. on behalf of The American Society of Plastic Surgeons; This is an open-access article distributed under the terms of the Creative Commons Attribution-Non Commercial-No Derivatives License 4.0 (CCBY-NC-ND), where it is permissible to download and share the work provided it is properly cited. The work cannot be changed in any way or used commercially without permission from the journal.

# Y-shaped Muscular Wrapping Technique Avoiding Re-infection of a Replaced Aortic Graft: A Cadaveric Study

Itaru Tsuge, MD, PhD\*

Susumu Saito, MD, PhD\*

Masako Kataoka, MD, PhD†

Hiroki Yamanaka, MD, PhD\*

Motoki Katsube, MD, PhD\*

Michiharu Sakamoto, MD, PhD\*

Naoki Morimoto, MD, PhD\*

**Summary:** Replacing an infected prosthetic thoracic aorta graft carries a high re-infection risk. We previously reported two clinical cases successfully treated with a new muscular wrapping technique: latissimus dorsi (LD) muscle flap with a distally based serratus anterior (SA) extension; however, a cadaveric study to prove the regular existence of the distal attachment area was lacking. We tried to establish an appropriate way of elevating the combined muscle flap safely. All of the cadavers were preserved using the Thiel embalming technique to retain flexibility. We checked for the existence of the distal attachment area between the LD and SA. Combined muscle flaps were elevated proximally while identifying the thoracodorsal artery, including the LD and SA branches. After the SA branch was ligated and cut, the SA muscle was manually peeled from the LD muscle with only the distal tight attachment area remaining. Contrast-enhanced computed tomography was performed using a multislice computed tomography system. Six human cadavers (three men, three women: 91 years old, on average) were examined. All six LD and SA combined muscle flaps showed a distal tight attachment area at the level from the seventh rib to the ninth rib. The tip of the SA muscle easily reached the sternum. Contrast-enhanced computed tomography failed to reconfirm the distal vascular flow from the LD to the reverse SA muscle, which we had visualized in a clinical case. We demonstrated the anatomical reliability of the new Y-shaped muscular flaps, which are suitable for preventing re-infection of aortic graft replacement. (*Plast Reconstr Surg Glob Open* 2021;9:e3626; doi: [10.1097/GOX.0000000000003626](https://doi.org/10.1097/GOX.0000000000003626); Published online 16 June 2021.)

Prosthetic graft infection of the thoracic aorta requires replacing the infected graft with a new graft in addition to surgery for the infectious cause, such as esophageal fistula or pulmonary fistula.<sup>1</sup> Because the re-infection risk is high and life-threatening, surgical procedures to reduce this risk are essential. Pedicled omental wrapping is the first choice for covering the newly implanted graft;<sup>2</sup> however, a history of omental flap use or other abdominal surgeries necessitated another method. We previously reported a new

breakthrough surgical method for salvaging aortic graft infection using the latissimus dorsi (LD) muscle flap with a reverse serratus anterior (SA) muscle flap.<sup>3</sup> The key was the advancement of the pivot point of the SA muscle using the distal continuity between the LD and SA to maintain the blood flow to the reverse SA muscle. The Y-shaped muscle flap was shown to be suitable for wrapping the aortic arch with the reverse SA muscle and the descending aorta with the LD muscle. We herein report the results of cadaveric studies to prove the regular existence of distal continuity between the LD and SA. We also established the best flap elevation approach for safely creating this combined muscle flap.

## METHODS

All cadavers were donated to the Kyoto University Clinical Anatomy Laboratory. Donors formally agreed

**Disclosure:** All the authors have no financial interest to declare in relation to the content of this article.

Related Digital Media are available in the full-text version of the article on [www.PRSGlobalOpen.com](http://www.PRSGlobalOpen.com).

From the \*Department of Plastic and Reconstructive Surgery, Graduate School of Medicine, Kyoto University, Kyoto, Japan; and †Department of Diagnostic Imaging and Nuclear Medicine, Graduate School of Medicine, Kyoto University, Kyoto, Japan.

Received for publication March 4, 2021; accepted April 14, 2021.

Copyright © 2021 The Authors. Published by Wolters Kluwer Health, Inc. on behalf of The American Society of Plastic Surgeons. This is an open-access article distributed under the terms of the [Creative Commons Attribution-Non Commercial-No Derivatives License 4.0 \(CCBY-NC-ND\)](https://creativecommons.org/licenses/by-nc-nd/4.0/), where it is permissible to download and share the work provided it is properly cited. The work cannot be changed in any way or used commercially without permission from the journal.

DOI: [10.1097/GOX.0000000000003626](https://doi.org/10.1097/GOX.0000000000003626)

to the use of their body for research and education purposes by signing the donation form of the Clinical Anatomy Laboratory (Kyoto University Medical Ethics Committee approval number: R1785). Additional ethical approval numbers for our anatomical research were R1862 and R2125. All the cadavers were preserved using the Thiel embalming technique (Formalin 3.5%–6.4%, propylene glycol, phenol, sodium sulfite, ethanol) to retain flexibility, color, and tone.<sup>4</sup>

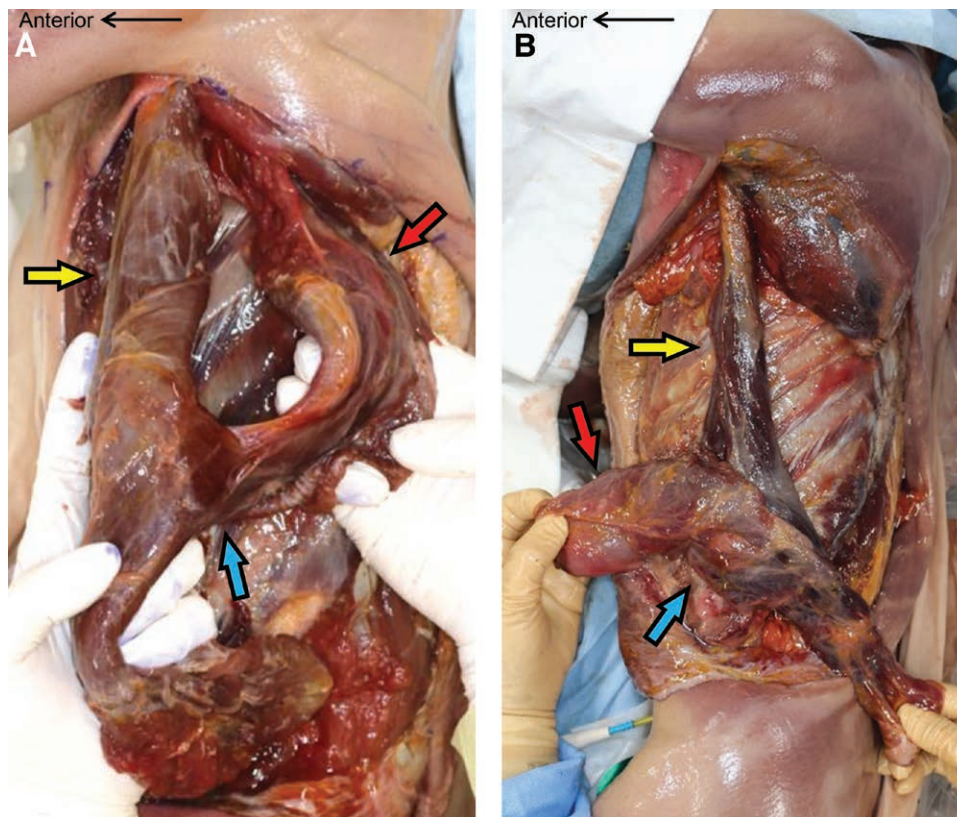
First, we explored the existence of the distal attachment area between the LD and SA, which had not previously been described anatomically. Muscle flaps, including the LD and SA, were elevated on the surface of ribs and intercostal muscles with ligating perforators from intercostal vessels. SA slips from the third rib to the ninth rib were included in the flap with cutting off the origin of ribs and the insertion of scapula. Combined muscle flaps were elevated proximally while identifying the thoracodorsal artery, including the LD and SA branches. After the SA branch was ligated and cut, the SA muscle was manually peeled from the LD muscle with only the distal tight attachment area remaining.

Next, contrast-enhanced computed tomography (CT) was performed using a multislice CT system (Aquilion; Canon, Japan). Three cadavers were evaluated with different contrast types injected intraarterially

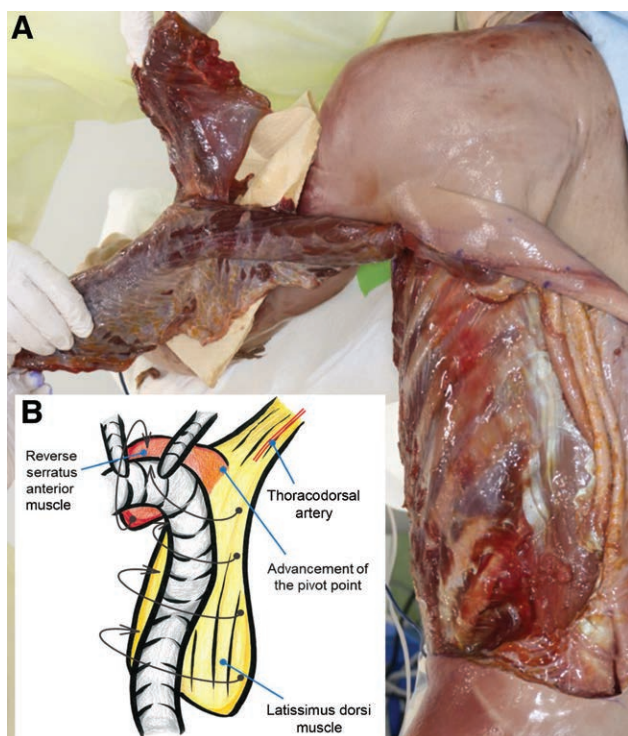
via a thoracodorsal artery of the LD or SA branch and an intercostal artery perforator. After elevating the combined muscle flaps, the arteries were cannulated using a 24-gauge catheter. After reflux with heparin (10 U/ml), methylene blue solution was infiltrated to identify vascular leaks, which were then ligated. Contrast medium Omnipaque 240 (GE Healthcare, Ill.) diluted six-fold with 0.9% saline was injected.

## RESULTS

Six human cadavers (three men, three women; 91 years old, on average) were examined. All LD and SA combined muscle flaps had the distal tight attachment area, while the proximal area between the LD and SA remained loose enough for manual dissection (Fig. 1A). After attempting to elevate the combined flaps from the anterior-to-posterior direction, the distal attachment area was difficult to detect. In contrast, finding the layer to enter the back of the SA muscle was easy when we elevated the flap from the posterior-to-anterior direction by cutting the thoracolumbar fascia to enter the layer between the LD muscle and rib periosteum. After cutting off the SA muscle insertion at the scapula and origin on multiple ribs, the combined LD and SA muscle flaps were elevated while preserving the distal attachment area (Fig. 1B). The attachment area was detected



**Fig. 1.** Cadaveric studies to prove the regular existence of distal continuity between the LD and SA (A). A Y-shaped muscle flap constructed with combined LD muscle and reverse SA muscle (B). Arrows represent the following: yellow, LD muscle; red, SA muscle; blue, distal attachment of the LD and SA.



**Fig. 2.** Advancement of the pivot point of the reverse SA muscle is key. The schematic illustration (modified from our previous clinical report<sup>3</sup>) shows the muscular coverage for the replaced thoracic graft.

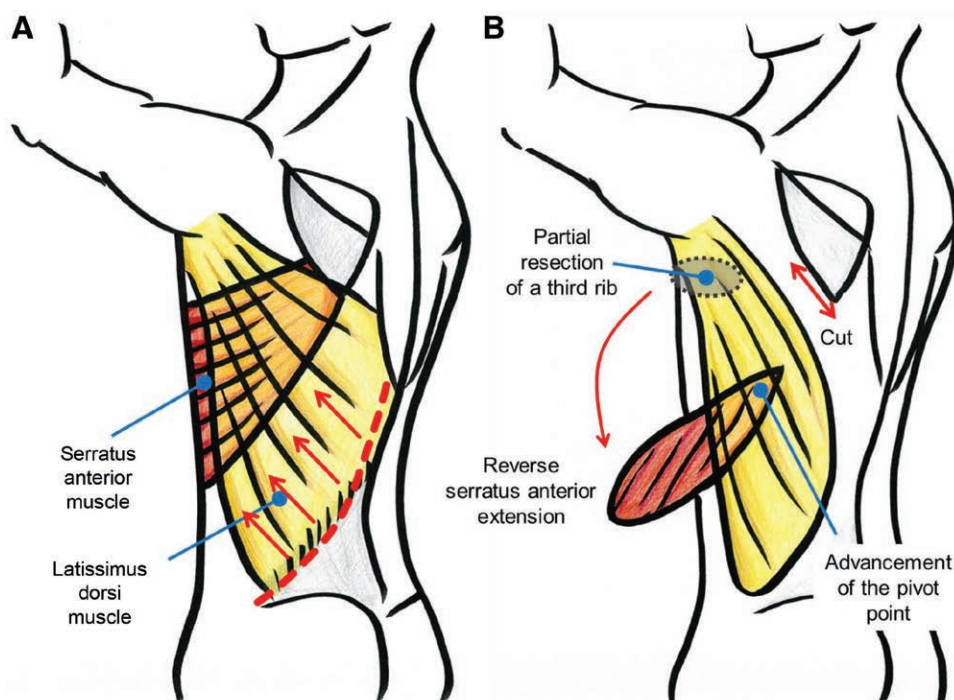
from the seventh rib to the ninth rib, which allowed the SA muscle to easily reach the sternum. Partial excision of the third rib made the Y-shaped muscle flap directly transfer to the aortic arch with the reverse SA muscle and the descending aorta with the LD muscle, respectively (Fig. 2).

Contrast-enhanced CT revealed the course of the cannulated arteries, but none with a large diameter were observed at the distal attachment area. (See figure, **Supplemental Digital Content 1**, display of the CT findings for injection via the LD branch of the thoracodorsal artery. <http://links.lww.com/PRSGO/B667>.)

## DISCUSSION

Thoracic aortic graft infection is a severe complication with high mortality. A comprehensive review of the literature proved that autologous vascularized tissue coverage was a successful approach for treating infected aortic grafts, including from the omentum (69%), pectoralis major muscle (19%), rectus abdominis muscle (5%), and latissimus dorsi muscle (4%).<sup>5</sup> The combined LD and SA muscle flap can expand the size of the muscle flap; however, it does not cover the whole area from the aortic arch to the descending aorta.<sup>6</sup>

In 2020, we first reported clinical cases of an infected aortic graft salvaged using a Y-shaped muscle flap containing LD muscle and reverse SA muscle as a new salvage technique for complete muscular coverage of the aortic arch and descending aorta.<sup>3</sup> An intraoperative



**Fig. 3.** "Posterior-to-anterior" flap elevation maintains the distal attachment of the LD and SA. The reverse SA muscle extends to the aortic arch.

indocyanine green (ICG) test demonstrated the distal vascular flow from the LD to the entire area of the reverse SA muscle (See Video [online], which shows the intraoperative ICG fluorescence imaging of our previous clinical case). This surgical method differs from combined reverse LD and SA muscle flaps vascularized by lumbar perforator vessels for diaphragmatic reconstruction.<sup>7,8</sup> In this study, we proved the existence of a distal attachment area between the LD and SA in six cadavers. Despite attempts to show the vascular network by conventional CT, the distal vessels were not large enough to visualize. Studies using fresh cadavers<sup>9</sup> and high-resolution CT<sup>10</sup> are needed to prove the vascular anatomy.

Through this study, we learned a stable procedure for elevating this new muscle flap. Typical LD flap elevation is started from the anterior edge of the LD muscle, where the layers between the LD and SA can be distinguished. However, this area is the origin of the SA, which attaches to the periosteum of multiple ribs; therefore, SA elevation is complicated. Combined elevation of the LD and SA muscle flap from the thoracolumbar fascia facilitated the maintenance of the distal attachment area between the LD and SA (Fig. 3). A possible disadvantage of this flap is the loss of the LD and SA muscles, which may cause functional deterioration in the upper extremities and aesthetic drawbacks as a winged scapula.

### CONCLUSIONS

We showed the anatomical reliability of the new Y-shaped muscular flaps suitable for preventing re-infection of aortic graft replacement. Possible disadvantages concerning the loss of the LA and SA functions should be verified in more clinical cases.

*Itaru Tsuge, MD, PhD*

Department of Plastic and Reconstructive Surgery  
Graduate School of Medicine

Kyoto University  
54 Shogoin Kawahara-cho, Sakyou-ku  
Kyoto 606-8507, Japan  
E-mail: [itsuge@kuhp.kyoto-u.ac.jp](mailto:itsuge@kuhp.kyoto-u.ac.jp)

### ACKNOWLEDGMENTS

*We thank all donors for their willingness to support our research. Furthermore, we thank the Clinical Anatomy Laboratory committee of Kyoto University for helping with the cadaveric studies.*

### REFERENCES

1. Luehr M, Etz CD, Nozdrzykowski M, et al. Emergency open surgery for aorto-oesophageal and aorto-bronchial fistulae after thoracic endovascular aortic repair: a single-centre experience. *Eur J Cardiothorac Surg.* 2015;47:374–82; discussion 382.
2. Takano T, Terasaki T, Wada Y, et al. Treatment of prosthetic graft infection after thoracic aorta replacement. *Ann Thorac Cardiovasc Surg.* 2014;20:304–309.
3. Tsuge I, Saito S, Yamazaki K, et al. Latissimus dorsi muscle flap with a distally based serratus anterior extension for salvaging aortic graft infection. *Plast Reconstr Surg Glob Open.* 2020; 8:e2926.
4. Thiel W. [The preservation of the whole corpse with natural color]. *Ann Anat.* 1992;174:185–195.
5. Frautschi RS, Bassiri Gharb B, Duong MM, et al. The cardioplastic approach to the treatment of infected aortic grafts. *Ann Plast Surg.* 2017;79:221–225.
6. Hernandez JA, Stranix JT, Piwnica-Worms W, et al. Omental flap coverage for management of thoracic aortic graft infection. *Ann Thorac Surg.* 2020;109:1845–1849.
7. Meyer C, Blucher G, Bruand-Rodier C, et al. [Combined latissimus dorsi and serratus anterior reverse flow pedicle flap. Report of a clinical case]. *Ann Chir Plast Esthet.* 1998;43:269–274.
8. Samarakkody U, Klaassen M, Nye B. Reconstruction of congenital agenesis of hemidiaphragm by combined reverse latissimus dorsi and serratus anterior muscle flaps. *J Pediatr Surg.* 2001;36:1637–1640.
9. Saint-Cyr M, Wong C, Schaverien M, et al. The perforasome theory: Vascular anatomy and clinical implications. *Plast Reconstr Surg.* 2009;124:1529–1544.
10. Zubler C, Haberthür D, Hlushchuk R, et al. The anatomical reliability of the superficial circumflex iliac artery perforator (SCIP) flap. *Ann Anat.* 2021;234:151624.