



TITLE:

Fournier's Gangrene with Edwardsiella tarda: A Gas Production Case by Bacterial Synergism with Streptococcus anginosus

AUTHOR(S):

Tsuge, Itaru; Matsui, Miho; Kanno, Toru; Kaisho, Junichi; Takahashi, Toshifumi; Yamanaka, Hiroki; Katsube, Motoki; Sakamoto, Michiharu; Morimoto, Naoki

CITATION:

Tsuge, Itaru ...[et al]. Fournier's Gangrene with Edwardsiella tarda: A Gas Production Case by Bacterial Synergism with Streptococcus anginosus. Plastic and Reconstructive Surgery - Global Open 2021, 9(6): e3625.

ISSUE DATE:

2021-06

URL:

<http://hdl.handle.net/2433/277093>

RIGHT:

Copyright © 2021 The Authors. Published by Wolters Kluwer Health, Inc. on behalf of The American Society of Plastic Surgeons; This is an open-access article distributed under the terms of the Creative Commons Attribution-Non Commercial-No Derivatives License 4.0 (CCBY-NC-ND), where it is permissible to download and share the work provided it is properly cited. The work cannot be changed in any way or used commercially without permission from the journal.

Fournier's Gangrene with *Edwardsiella tarda*: A Gas Production Case by Bacterial Synergism with *Streptococcus anginosus*

Itaru Tsuge, MD, PhD*

Miho Matsui, MD, PhD†

Toru Kanno, MD, PhD‡

Junichi Kaisho, MD†

Toshifumi Takahashi, MD‡

Hiroki Yamanaka, MD, PhD*

Motoki Katsube, MD, PhD*

Michiharu Sakamoto, MD, PhD*

Naoki Morimoto, MD, PhD*

Summary: *Edwardsiella tarda* is an anaerobe associated with freshwater and marine life. Necrotizing soft tissue infection caused by *E. tarda* is rare, but its mortality rate is extremely high (61.1%). We experienced a survival case of Fournier's gangrene with *E. tarda*. A key clinical feature for the diagnosis was gas production; however, there have been no previous reports of such a phenomenon in relation to *E. tarda*. A 64-year-old man was admitted with a 3-day history of a high fever. His medical history, which included paraplegia from the Th6 level down, made the focus of inflammation at the perineum difficult to notice. Whole-body CT revealed subcutaneous gas from the posterior scrotum around the entire circumference of the anus. During emergency surgery, an incision at the posterior scrotum revealed extensive fascia necrosis, and *E. tarda* and *Streptococcus anginosus* were identified. We speculated the gas production in this case to be the product of a mixed infection of aerobes and anaerobes, which acted synergistically to induce bacterial growth. Timely surgical debridement and antibiotic therapy led to the patient's survival. (*Plast Reconstr Surg Glob Open* 2021;9:e3625; doi: [10.1097/GOX.0000000000003625](https://doi.org/10.1097/GOX.0000000000003625); Published online 15 June 2021.)

Edwardsiella tarda is a Gram-negative, facultative anaerobe associated with freshwater and marine life. In humans, *E. tarda* infection has been reported as a rare cause of bacterial gastroenteritis in 83% and wound infection in 8%.¹ The intestinal colonization rate in Japanese is reported to be only 26 among 353,600 (0.007%),² and consumption of contaminated food (eg, sushi, raw fish, catfish, and eels) is considered to be a risk factor.³ The mortality rate of necrotizing soft tissue infection (NSTI) caused by *E. tarda* is extremely high at 61.1%.⁴

We herein report a survival case of Fournier's gangrene with *E. tarda*, in which there were no risk factors for NSTI. Paraplegic sensory loss of the lower half of the body caused by previous spinal cord injury made it difficult to make an early diagnosis. A key clinical feature for the diagnosis was gas production; however, there have been

no previous reports of such a phenomenon. We suspected bacterial synergism between *E. tarda* and *Streptococcus anginosus* to be the cause of this gas.

CASE REPORT

A 64-year-old man was admitted to our hospital with a 3-day history of a high fever of 38°C, malaise, and sweating. His medical history included a spinal cord injury caused by a previous surgery for ossification of the posterior longitudinal ligament 20 years earlier, which had resulted in paraplegia from the Th6 level down, suffering complete motor and sensory paralysis at the lower half of the body with bladder and rectal disorders. In addition, he was extremely obese (172 cm, 113 kg, body mass index: 38.2 kg/m²), had received surgical intervention of coronary artery bypass grafting for myocardial infarction, and had diabetes mellitus (HbA1c: 6.1%). His activities of daily living were performed with a wheelchair, and he worked as a remote work clerk. Sacral pressure ulcers had been repeatedly generated and gradually deepened with necrotic tissue over the past 2 years (Fig. 1).

A blood test on the first day of admission showed the following: CRP, 16.4 mg/dl; WBC, 13,300/μl; Hb, 9.2 g/

From the *Department of Plastic and Reconstructive Surgery, Graduate School of Medicine, Kyoto University, Kyoto, Japan; †Department of Dermatology, Ijinkai Takeda General Hospital, Kyoto, Japan; ‡Department of Urology, Ijinkai Takeda General Hospital, Kyoto, Japan.

Received for publication March 4, 2021; accepted April 14, 2021.

Copyright © 2021 The Authors. Published by Wolters Kluwer Health, Inc. on behalf of The American Society of Plastic Surgeons. This is an open-access article distributed under the terms of the [Creative Commons Attribution-Non Commercial-No Derivatives License 4.0 \(CCBY-NC-ND\)](https://creativecommons.org/licenses/by-nc-nd/4.0/), where it is permissible to download and share the work provided it is properly cited. The work cannot be changed in any way or used commercially without permission from the journal.

DOI: [10.1097/GOX.0000000000003625](https://doi.org/10.1097/GOX.0000000000003625)

Disclosure: All the authors have no financial interest to declare in relation to the content of this article.

Related Digital Media are available in the full-text version of the article on www.PRSGlobalOpen.com.

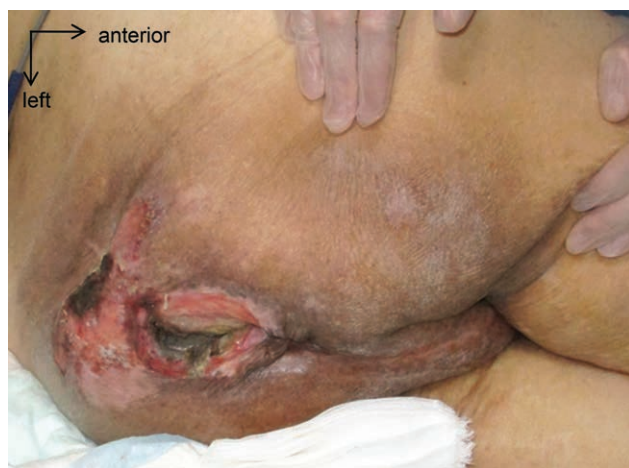

Fig. 1. Preoperative findings of a sacral pressure ulcer. The posterior part of the scrotum shows no erythema.

dl; PLT, 265,000/ μ l; Alb, 1.9g/dl; CK, 531 U/l; Cre, 1.83 mg/dl; Na, 134 mEq/l; Glu, 115 mg/dl. The LRINEC (Laboratory Risk Indicator for Necrotizing Fasciitis) score was 10. Because there was no erythema or purpura near the sacral pressure ulcer and perineum part, antibiotic therapy was started under the suspicion of urinary catheter infection. (See figure, Supplemental Digital Content 1, which shows the findings on admission. <http://links.lww.com/PRSGO/B668>.) Cefotiam was administered for 3 days; however, his blood data worsened (CRP, 25.0 mg/dl; WBC, 25,200/ μ l; Hb, 8.5g/dl; Cre, 4.97 mg/dl; Na, 125 mEq/l; Glu, 114 mg/dl; LRINEC score, 12). Whole-body

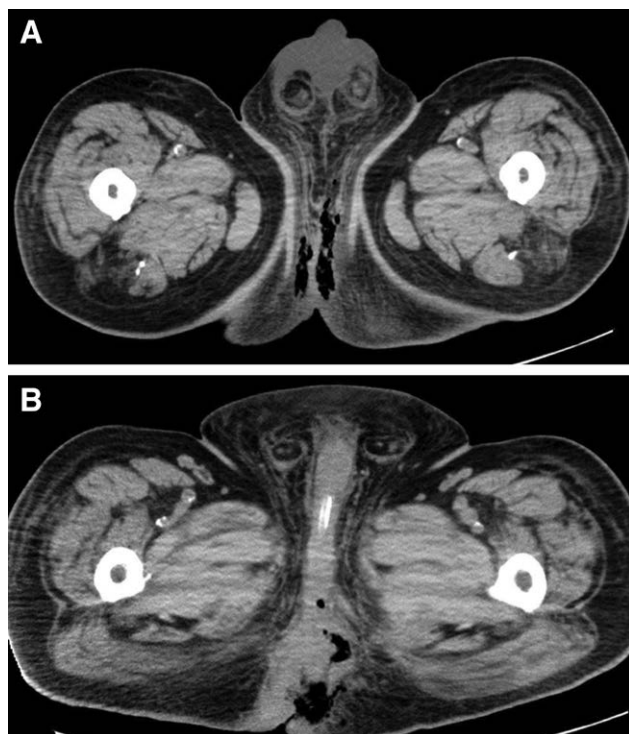


Fig. 2. CT scan findings. Gas gangrene from the posterior part of the scrotum was shown (A). It reached around the entire circumference of the anus (B).

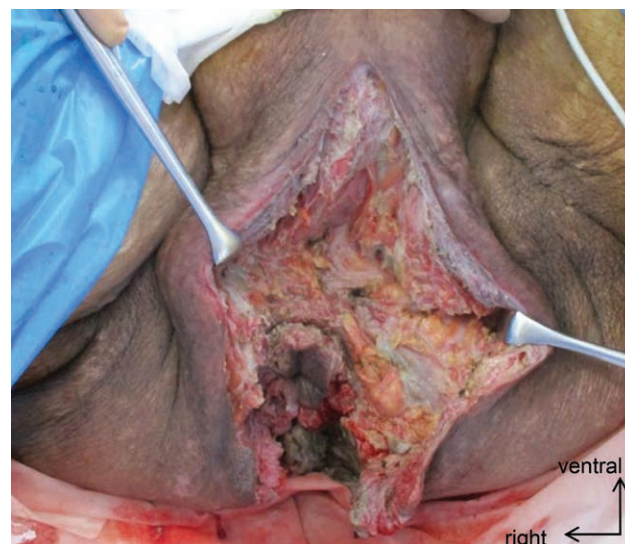


Fig. 3. Intraoperative findings. The necrosis had spread along the fascia as Fournier's gangrene.

computed tomography (CT) revealed subcutaneous gas extending from the perineum around the entire circumference of the anus (Fig. 2). Careful palpation showed crepitus suggesting subcutaneous emphysema at the posterior part of the scrotum. The sensory loss due to his spinal cord injury made the findings difficult for the patient to notice. The plastic surgery team was consulted, and an emergency general anesthesia surgery for extensive gas gangrene was performed.

The surgery was started in the lithotomy position. First, we made an incision at the posterior scrotum. The superficial subcutaneous layer was clear, but the fascia level was highly necrotic with an offensive smell and “dish-water-like” discharge. The fascia was sampled for wound culture. The necrosis had spread along the fascia toward both sides of the anus (Fig. 3). No fistula or perforation was found at the rectum, and the subcutaneous-fascial necrosis was continuous like a tunnel to the wound of sacral pressure ulcer. The necrotic tissue was removed, and the debridement surgery was finished with the wound opened. Postoperatively, antibiotics were changed to imipenem/cilastatin, and the patient was carefully observed in the intensive-care unit due to the risk of shock following gas gangrene. With no severe vital collapse, the inflammation gradually decreased, and renal function improved. *E. tarda* and *S. anginosus* were isolated from the intraoperative tissue culture. All of the blood cultures were negative. Wound culture of the sacral sore detected *Escherichia coli* and *Enterococcus faecalis*.

A detailed interview about dietary history before hospitalization showed multiple records of the patient consuming grilled eel 2–3 weeks before the hospitalization. After the patient's transfer to a general operating room, additional debridement surgeries were performed with local anesthesia on days six and 15 following the first surgery. With regard to the wound of the perineum and around the anus, the secondary intention was obtained by controlling the infection and promotion granulation without any

additional surgeries. The sacral pressure ulcer was treated with avoiding pressure and changing postures.

DISCUSSION

E. tarda infection can cause a life-threatening NSTI. Early surgical debridement surgery can provide an opportunity to achieve a survival; however, descriptions in the plastic surgery literature are limited.⁵ Like a previous NSTI case caused by parastomal ulcer infection with *E. tarda*,⁶ our case also had an infection route of deep chronic sacral pressure ulcer with necrotic tissue, which resulted in Fournier's gangrene as the NSTI subtype. The patient had a dietary history of consuming grilled eel 2–3 weeks before hospitalization; however, the direct causal relationship was unclear because the consumption of contaminated raw food is a risk factor for the condition. The background factors were obesity and diabetes mellitus, and the deteriorating factor was diagnostic difficulty due to no perception of his lower body. The gas image on whole-body CT was useful for the diagnosis and deciding on surgical intervention.

To our knowledge, there have been no reports of gas-producing NSTI caused by *E. tarda* infection. *E. tarda* is an anaerobic bacterium capable of producing hydrogen sulfide in a number of common laboratory media¹; however, previous CT findings of clinical NSTI cases with *E. tarda* have included subfascial and subcutaneous edema with fluid collection.^{5–8} The gas production in this case was suspected to be caused by mixed infection of *E. tarda* and *S. anginosus*. Animal studies have shown that mixed infection of aerobes and anaerobes acts synergistically to induce bacterial growth⁹; in particular, the *S. milleri* group (including *S. anginosus*) shows bacterial synergy with anaerobes to enhance growth and suppress the immune response.¹⁰

CONCLUSIONS

We reported a survival case of Fournier's gangrene caused by *E. tarda*. A case of gas production has not been

previously reported, and it was speculated to have been caused by bacterial synergism with *S. anginosus*.

Iharu Tsuge, MD, PhD

Department of Plastic and Reconstructive Surgery
 Graduate School of Medicine, Kyoto University
 54 Shogoin Kawahara-cho, Sakyou-ku
 Kyoto 606-8507, Japan
 E-mail: itsuge@kuhp.kyoto-u.ac.jp

REFERENCES

- Janda JM, Abbott SL. Infections associated with the genus *Edwardsiella*: The role of *Edwardsiella tarda* in human disease. *Clin Infect Dis*. 1993;17:742–748.
- Onogawa T, Terayama T, Zen-yoji H, et al. [Distribution of *Edwardsiella tarda* and hydrogen sulfide-producing *Escherichia coli* in healthy persons]. *Kansenshogaku Zasshi*. 1976;50:10–17.
- Nishida K, Kato T, Yuzaki I, et al. *Edwardsiella tarda* bacteremia with metastatic gastric cancer. *Idcases*. 2016;5:76–77.
- Hirai Y, Asahata-Tago S, Ainoda Y, et al. *Edwardsiella tarda* bacteremia. A rare but fatal water- and foodborne infection: review of the literature and clinical cases from a single centre. *Can J Infect Dis Med Microbiol*. 2015;26:313–318.
- Hamidian Jahromi A, Jing XL, Luce E. *Edwardsiella tarda* as a cause for limb- and life- threatening soft tissue infections: what all plastic surgeons need to know. *Plast Reconstr Surg Glob Open*. 2020;8:e3016.
- Kubo N, Tamachi K, Tsubakihara H. Parastomal soft tissue infection caused by *Edwardsiella tarda*: a case report. *STOMA*. 2019;26:12–15.
- Hara K, Ouchi H, Kitahara M, et al. A case of fasciitis localized in the calf muscles associated with *Edwardsiella tarda* sepsis. *Clin Neurol*. 2011;51: 694–698.
- Frumberg DB, Epstein SE, Jauregui JJ, et al. Prosthetic hip infection with *Edwardsiella tarda* in sickle cell beta thalassemia disease: A case report. *J Clin Orthop Trauma*. 2016;7(Suppl 1):130–133.
- Kingston D, Seal DV. Current hypotheses on synergistic microbial gangrene. *Br J Surg*. 1990;77:260–264.
- Shinzato T, Saito A. A mechanism of pathogenicity of "Streptococcus milleri group" in pulmonary infection: Synergy with an anaerobe. *J Med Microbiol*. 1994;40:118–123.