

Arteriovenous Fistula Rescues Radial Forearm Phalloplasty: A Case Report on Patients with Microvascular Obstruction

Richard A. Santucci, MD, FACS,
HON FC Urol(SA)*
Keeley D. Newsom, BS†
Galen S. Wachtman, MD*
Curtis N. Crane, MD*

Background: Radial forearm free flap phalloplasty (RFFFP) is the most common surgery performed for genital reconstruction of female-to-male transgender patients. However, up to 19% require anastomotic re-exploration. The postoperative creation of an arteriovenous fistula (AVF) to bypass obstruction and salvage RFFFP was first reported in 1996 and has subsequently been reported by 1 high-volume center in Belgium.

Methods: Here, we present 2 cases in which intraoperative microvascular obstruction threatened the viability of the RFFF of transgender phalloplasty patients. In each patient, an AVF was created between the radial artery and cephalic vein in the distal flap either after being transferred out of the operating room, as has previously been described, or during initial operation.

Results: In both cases, the creation of a distal AVF salvaged the neophallus. Importantly, the patient that had been transferred out of the operating room before reintervention suffered partial flap necrosis compared with no flap loss in the patient who had an AVF created during initial surgery. One AVF was ligated 18 days postoperative, whereas the other was never formally closed.

Conclusions: These cases demonstrate that AVF can be reliably used for RFFFP salvage both intraoperatively and for reintervention. They also suggest that earlier detection of persistent vascular compromise and utilization of AVF can further minimize flap loss. Finally, in contrast with the prior explanation of this technique, timing of AVF ligation may be less critical than previously described. Microsurgeons are reminded that this technique may save complicated flaps in the uncommon case of microcirculatory flap obstruction. (*Plast Reconstr Surg Glob Open* 2021;9:e3595; doi: 10.1097/GOX.0000000000003595; Published online 21 May 2021.)

INTRODUCTION

Radial forearm free flap phalloplasty (RFFFP) is the most common surgical technique utilized in genital reconstruction for the female-to-male (FTM) transgender patient.^{1,2} Because the flap is large and configured into a complex geometry, vascular complications are common.³ Vascular compromise is generally the result of flow problems caused by thrombosis or kinking, with up to 19% of RFFFP patients demonstrating early free flap thrombosis necessitating surgical reintervention.³ In the case of

microvasculature obstruction, the vein and artery remain widely patent, and treatment must allow perfusion of the flap and sufficient vessel flow that it does not itself cause arterial or venous clotting.

Creation of an arteriovenous fistula (AVF) is a well-documented technique in which a vein graft is attached to the recipient vessel as a flow-through loop, creating a shunt that reduces risk of thrombosis by enhancing flow.^{4,5} The use of a distal AVF in the salvage of transgender neophallus was first described in 1996 as a re-intervention technique to address postsurgical flap thrombosis.⁶ Subsequently, it was recommended that AVF be temporary, and that it should be ligated after 6 weeks to minimize chances of sequelae, including edema, arterial thrills, and venous hypertension.⁷ Based on prior reports, it is unclear whether AVF can be utilized upon first observing a vascular compromised state in the operating room, nor has there been an update on when ligation is safe.

We present 2 FTM transgender patients who underwent RFFFP complicated by microvascular obstruction. In

From the *Crane Center for Transgender Surgery, Austin, Tex.; and †Indiana University School of Medicine, Indianapolis, Ind.

Received for publication December 6, 2020; accepted March 29, 2021.

Copyright © 2021 The Authors. Published by Wolters Kluwer Health, Inc. on behalf of The American Society of Plastic Surgeons. This is an open-access article distributed under the terms of the [Creative Commons Attribution-Non Commercial-No Derivatives License 4.0 \(CCBY-NC-ND\)](https://creativecommons.org/licenses/by-nc-nd/4.0/), where it is permissible to download and share the work provided it is properly cited. The work cannot be changed in any way or used commercially without permission from the journal.

DOI: 10.1097/GOX.0000000000003595

Disclosure: All the authors have no financial interests to declare in relation to the content of this article.

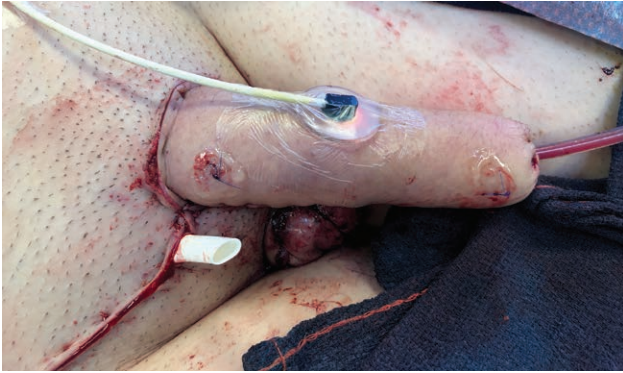

Fig. 1. Immediate postoperative appearance of patient WA after phalloplasty.

In 1 case, the patient required emergent surgical reintervention, and creation of a delayed AVF salvaged the neophallus but with some tissue necrosis. In the second case, a prompt AVF was created during initial surgery after the patient appeared to have microvascular flap obstruction despite widely patent artery and vein. The AVF was either never ligated or ligated after 18 days, respectively. These cases further underscore the utility of this technique, and define the timeliness of creating and ligating AVF for use in RFFF salvage.

CASE PRESENTATIONS

Patient WA

In May 2018, a 46-year-old FTM patient underwent RFFF for genital gender affirmation using previously described techniques.¹ The patient was previously diagnosed with serpiginous choroiditis (a rare disease proposed to be an immune response causing localized vasculitis of the subretina) and was on oral methotrexate, which was stopped before surgery. He was cleared for surgery by his ophthalmologist and his primary physician.

Intraoperatively, his case was complicated by microvascular arterial thromboses requiring 2 revisions and eventual vein grafting of his arterial pedicle (Fig. 1). Within 1 hour of surgery, he had hemorrhage from the groin wound and was returned to the operating room. The flap artery was pulsing distally, but there was no venous outflow. The anastomoses were flushed and an AVF between the distal radial artery and the cephalic vein was created, resulting in immediate strong pulse through the cephalic vein and vena comitans. Due to relative vascular compromise, the patient suffered urethral flap loss (Fig. 2) requiring debridement and placement of a perineal urethrostomy at 21 days postoperative. The remainder of the flap was salvaged, and 6 months after surgery, after placing skin grafts ventrally to address severe chordee, an acceptable surgical result was obtained (Fig. 3). The AV fistula was never formally closed.

Patient AH

In June 2020, a 37-year-old FTM patient underwent uneventful RFFF. Doppler of the flap revealed blood flow within the anastomoses, but signal was lost, and the arteriolar mixed oxygen concentration fell from 50% to

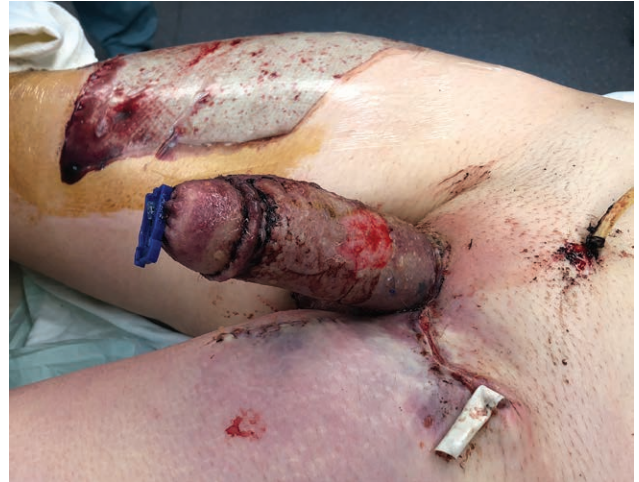

Fig. 2. Patient WA on postoperative day 10 after phalloplasty and AV fistula showing tissue edema, superficial skin loss, and dusky appearance.

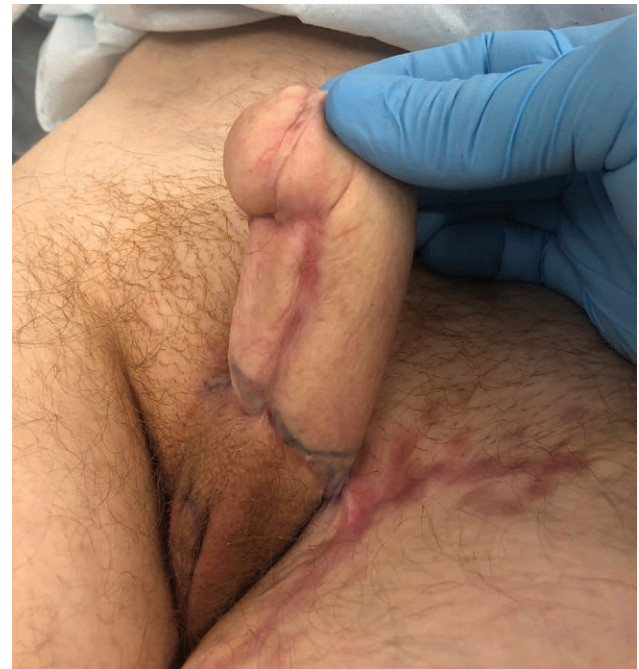

Fig. 3. Patient WA 6 months after surgery showing healthy appearing phallus with significant distal ventral chordee, which was repaired using incision and placement of skin grafts.

12% (T-stat; Spectros; Houston, Tex.). Similar to WA, flushing of the anastomoses revealed pulsatile arterial flow through the flap without venous return. A distal AVF was created between the distal radial artery and cephalic vein, and the phallus became pink with good blood flow postoperatively. T-stat mixed oxygen concentration stayed low at 12% but climbed to 70% over the next 12 hours. During postoperative visits, the patient maintained a healthy phallus without necrosis. The fistula was successfully closed 18 days postoperative.

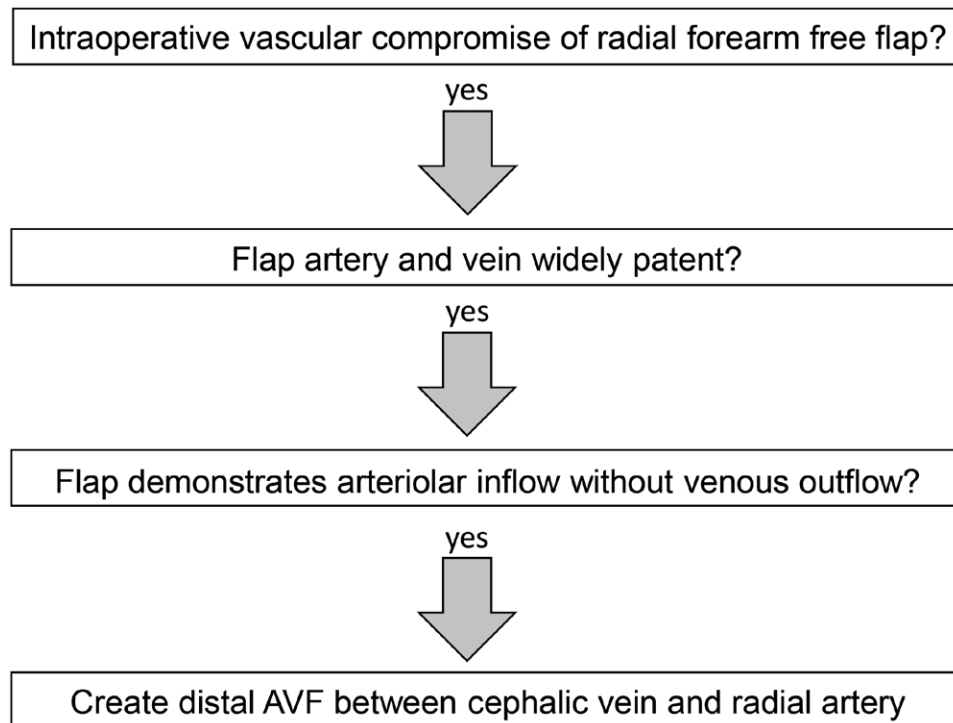


Fig. 4. Proposed decision-making algorithm for RFFFP patients demonstrating persistent intraoperative microvascular flap obstruction.

DISCUSSION

RFFFP is the gold standard for genital reconstruction in FTM transgender patients,² but due to its complex structure, it may be complicated by arteriolar thrombosis, venous thrombosis, or both, resulting in partial or full flap loss.³ Here, we underscore the utility and discuss the timeliness of AVF in flap salvage of RFFFP patients demonstrating persistent microvascular-level obstruction.

In the first case of AVF used to salvage RFFFP described in 1996, an AVF was created between a superficial vein and the radial artery after evidence of ischemia on the first postoperative day.⁷ Similarly to the delayed AVF placed in our patient WA, healing was complicated by partial flap loss and necrosis of the neourethra.⁷ Interestingly, no flap loss was observed when AVF was placed promptly upon initial signs of vascular compromise in AH. This suggests that an early detection of vascular compromise in an RFFF that demonstrates arteriolar inflow without venous return despite patent vessels may be an ideal candidate for early distal AVF placement (Fig. 4).

Importantly, distal AVF in the salvage of RFFFP has previously been considered temporary,⁷ but patient WA never had formal surgical ligation of the fistula and recovered without detectible sequelae. Further, it has been suggested to ligate AVF at earliest 6 weeks, citing optimal endothelium repair.⁷ However, in the case of AH, we elected to ligate the AVF 18 days after surgery without further complication. These 2 cases suggest that the closure of the fistula may be less critical than first

suggested. More research is necessary to validate the observations in these cases.

CONCLUSIONS

Distal AVF is a reliable technique used to salvage the neophallus in transgender patients undergoing RFFFP with microvascular obstruction.^{6,8} The cases in this report suggest 2 novel aspects of this technique: (1) prompt distal AVF placement may be enough to salvage the RFFF without subsequent necrosis or flap loss and (2) the timing of AVF ligation may be less critical than previously described and can be ligated before 6 weeks or not at all.

Richard A. Santucci MD, FACS, HON FC Urol(SA)

Crane Surgical Services

5656 Bee Cave Road, Suite J 201

Austin, TX 78746

E-mail: richard@cranects.com

Twitter: @RsantucciTGMD

Facebook: @Richard Santucci MD

REFERENCES

1. Chang TS, Hwang WY. Forearm flap in one-stage reconstruction of the penis. *Plast Reconstr Surg.* 1984;74:251–258.
2. Monstrey S, Hoebeker P, Selvaggi G, et al. Penile reconstruction: is the radial forearm flap really the standard technique? *Plast Reconstr Surg.* 2009;124:510–518.
3. Monstrey S, Hoebeker P, Dhont M, et al. Radial forearm phalloplasty: a review of 81 cases. *Eur J Plast Surg.* 2005;8:206–212.
4. Ibrahim IM, Sussman B, Dardik I, et al. Adjunctive arteriovenous fistula with tibial and peroneal reconstruction for limb salvage. *Am J Surg.* 1980;140:246–251.

5. Aherne T, Kheirleisid E, O'Neill D, et al. The use of arteriovenous fistulae as an adjunct to peripheral arterial bypass: A systematic review and meta-analysis. *Eur J Vasc Endovasc Surg*. 2016;51:707–717.
6. Hage JJ, Winters HA. Salvage of a “free flap” phalloplasty by distal arteriovenous fistula: Case report. *J Reconstr Microsurg*. 1996;12:279–282.
7. Hage JJ, Monstrey S. Free-flap distal arteriovenous fistula: When to close it? *J Reconstr Microsurg*. 1998;14:407–410.
8. Doornaert M, Hoebeke P, Ceulemans P, et al. Penile reconstruction with the radial forearm flap: An update. *Handchir Mikrochir Plast Chir*. 2011;43:208–214.