

CLINICAL IMAGE

Floppy interatrial septum mimicking an ASD: The role of left atrial pressure

Veronika Zach¹ | Elisabeth Pieske-Kraigher^{1,2,3} | Burkert Pieske^{1,2,3,4} |
Matthias Schneider^{1,4} 

¹Department of Internal Medicine and Cardiology, Charité – Universitätsmedizin Berlin (Campus Virchow-Klinikum), Berlin, Germany

²DZHK (German Center for Cardiovascular Research) Partner Site Berlin, Berlin, Germany

³Berlin Institute of Health (BIH), Berlin, Germany

⁴Department of Cardiology, German Heart Center Berlin, Berlin, Germany

Correspondence

Matthias Schneider, Department of Internal Medicine and Cardiology, Charité – Universitätsmedizin Berlin, Augustenburger Platz 1, 13353 Berlin, Germany.
Email: matthias.schneider@charite.de

Transesophageal echocardiography examination (TEE) was performed in a 61-year-old male patient who presented to our emergency department with a 3-day history of palpitations, tightness in the chest, and dyspnea on exertion. A remarkable interatrial septum (IAS) was observed, with the anterior/superior aspect pointing towards the right atrium (RA) exposing a substance defect with left-to-right shunting in color Doppler and a washout towards the RA in the intravenous (iv) contrast study with agitated saline (Figure 1, Videos S1-S4).

Previous medical history included an addiction to alcohol and chronic obstructive pulmonary disease. Liver function was normal, and there was no history of stroke. The electrocardiogram revealed atrial fibrillation (AF) with a heart rate of 159 bpm, oxygen saturation was normal, and physical examination was unremarkable except tachycardia.

The patient received electrical cardioversion. TEE was repeated 8 weeks later in sinus rhythm. This time, the IAS is highly mobile (“floppy”), showing a large patent foramen ovale (PFO) with

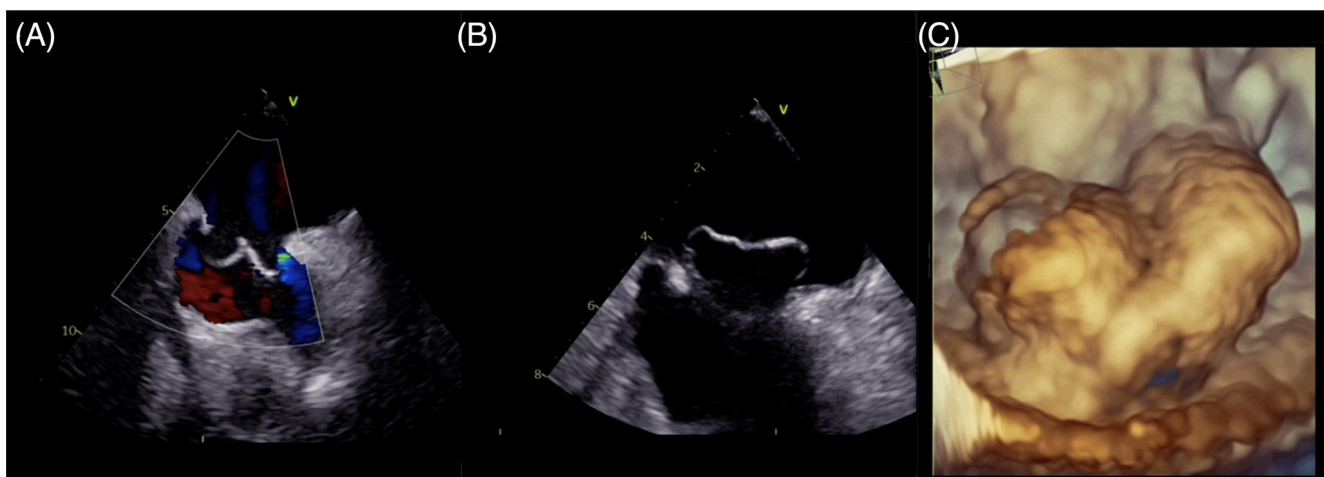


FIGURE 1 In atrial fibrillation, a substance defect of the interatrial septum (IAS) is seen by color Doppler (Panel A). After cardioversion, the IAS is floppy and predominantly points to the left atrium (Panels B and C), revealing a patent foramen ovale

This is an open access article under the terms of the Creative Commons Attribution-NonCommercial-NoDerivs License, which permits use and distribution in any medium, provided the original work is properly cited, the use is non-commercial and no modifications or adaptations are made.

© 2021 The Authors. *Health Science Reports* published by Wiley Periodicals LLC.

spontaneous right-to-left shunting in the iv contrast study, and maximal diameter of membrane separation was 5 mm.

This clinical image presents the same patient in two diverging hemodynamic situations with significant differences in left atrial (LA) pressure between the two examinations. It demonstrates that a large PFO with spontaneous right-to-left shunting can be concealed or even turned into a left-to-right shunt depending on LA pressure. It illustrates the previously shown correlation of pulmonary capillary wedge pressure and the movement of the IAS.^{1,2} The absence of detectable right-to-left shunting can be due to image quality, angulation, and elevated LA pressure.³ Therefore, it is crucial to evaluate the anatomy and the morphology of the IAS in every TEE. In conclusion, elevated LA pressure due to any reason can impede the detection of PFO.

ACKNOWLEDGEMENT

Open Access funding enabled and organized by Projekt DEAL.

CONFLICT OF INTEREST

All authors have read and approved the submission of the manuscript and have no conflict of interest to disclose.

AUTHOR CONTRIBUTIONS

Conceptualization: Veronika Zach, Matthias Schneider.

Supervision: Burkert Pieske, Matthias Schneider.

Visualization: Veronika Zach, Matthias Schneider.

Writing—Original Draft Preparation: Veronika Zach, Matthias Schneider.

Writing—Review and Editing: Elisabeth Pieske-Kraigher, Burkert Pieske.

All authors have read and agreed to the published version of the manuscript.

The corresponding author confirms that he had full access to all of the data and takes complete responsibility for the integrity of the data and the accuracy of the data analysis.

TRANSPARENCY STATEMENT

The manuscript is an honest, accurate, and transparent account of the clinical image being reported; no important aspects have been omitted.

DATA AVAILABILITY STATEMENT

Data sharing not applicable to this article as no datasets were generated or analyzed.

ETHICS STATEMENT

As this report is a “clinical image,” no formal ethics committee vote is available. This research was carried out in accordance with recognized standards (the Declaration of Helsinki, as revised in 2013). Informed consent was obtained from the patient for publication of the clinical image and related accompanying images.

ORCID

Matthias Schneider  <https://orcid.org/0000-0002-6320-3708>

REFERENCES

1. Royse CF, Royse AG, Soeding PF, Blake DW. Shape and movement of the interatrial septum predicts change in pulmonary capillary wedge pressure. *Ann Thorac Cardiovasc Surg.* 2001;7(2): 79-83.
2. Haji DL, Ali MM, Royse A, Canty DJ, Clarke S, Royse CF. Interatrial septum motion but not Doppler assessment predicts elevated pulmonary capillary wedge pressure in patients undergoing cardiac surgery. *Anesthesiology.* 2014;121(4):719-729.
3. Cohen A, Donal E, Delgado V, et al. EACVI recommendations on cardiovascular imaging for the detection of embolic sources: endorsed by the Canadian Society of Echocardiography. *Eur Heart J Cardiovasc Imaging.* 2021;22(6):e24–e57.

SUPPORTING INFORMATION

Additional supporting information may be found in the online version of the article at the publisher's website.

How to cite this article: Zach V, Pieske-Kraigher E, Pieske B, Schneider M. Floppy interatrial septum mimicking an ASD: The role of left atrial pressure. *Health Sci Rep.* 2021;4:e415. doi:10.1002/hsr2.415