

Teratoma of lesser omentum in a male infant

Baviskar BP, Dongre SD, Karle RR, Sewlikar VN*

Departments of Pathology and *General Surgery, Rural Medical College, Loni, Ahmednagar - 413 736, India

Correspondence: Bharati P. Baviskar, E-mail: bharatibaviskar63@yahoo.co.in

Received : 14-03-06
Review completed : 29-03-06
Accepted : 31-07-06
PubMed ID :
J Postgrad Med 2006;52:304-5

An eight-month-old male child presented with a lump in the abdomen. The lump was gradually increasing in size for the last five months and was palpable in the epigastrium and left hypochondrium. It was not associated with vomiting or fever. Both testes were palpable in the scrotum.

USG abdomen revealed a 14x8x7 cm, heterogeneous mass in epigastric and hypochondriac regions extending on both sides of the midline with multiple cystic areas. The gall bladder, liver, spleen, pancreas, kidneys and bladder were normal in morphology and echotexture. Computed tomography (CT) scan showed a tumor with evidence of calcification, multiple septa and fat cysts. Confirming the clinical diagnosis of dermoid cyst of the lesser omentum. Fine needle aspiration of the mass showed squames of epithelial cells and degenerated necrotic material.

During operation a well-encapsulated mass was seen occupying the epigastrium and left hypochondrium. The mass was partly cystic with glistening white wall, situated in the lesser omentum and pushing the gall bladder laterally and lesser curvature of the stomach on the left lateral side. There was no evidence of any intestinal or other organ involvement.

The patient was followed up for two years every six months. Patient is asymptomatic and without any signs of tumor recurrence clinically as well as on USG.

Pathological findings

The tumor weighed 300 gm and measured 14x8x7 cm. It was encapsulated, glistening white in appearance and partly cystic in nature. Cut section showed firm gray white areas mixed with myxoid areas [Figure 1]. Microscopy of the multiple sections studied showed a tumor composed of derivatives of all germ cell layers with no specific arrangement. Ectodermal elements seen were stratified squamous epithelium, columnar to cuboidal epithelium, pseudostratified squamous epithelium along with sebaceous glands and hair follicles [Figure 2]. Mesodermal elements in the tumor included well-

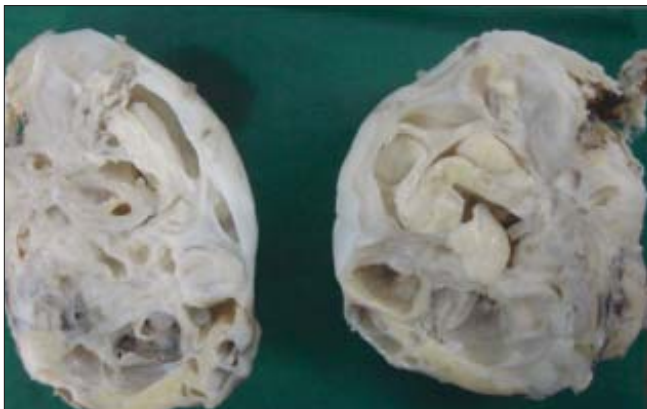

Figure 1: Gross: Cut surface of the tumour showing cystic and solid areas

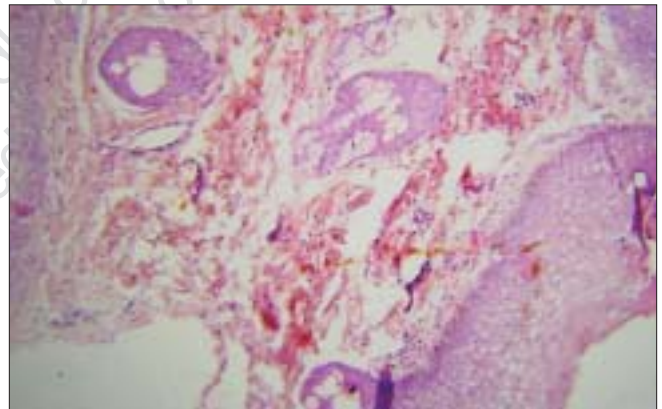


Figure 2: Photomicrograph showing lining of stratified squamous epithelium with well developed adnexal structures- (H&E, 100x)

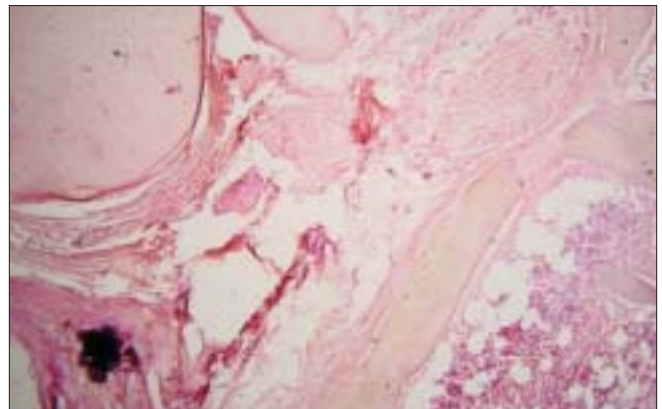


Figure 3: Photomicrograph showing bony trabeculae with well formed haematopoietic tissue, chondroid tissue, fat cells & fibrous tissue- (H&E, 40x)

formed cartilage, bone, muscle, mature neural tissue, fat and fibrous tissue [Figure 3]. Endodermal derivatives such as colonic epithelium with goblet cells were seen. There was no evidence of any immature tissue in the 14 sections studied. A diagnosis of mature teratoma of the lesser omentum was provided.

Discussion

Teratoma is the most commonly encountered germ cell tumor, but primary teratoma of the omentum is extremely rare. Approximately 25 mature and three immature teratomas in the omentum have been reported.^[1-3] Out of these only four cases of mature teratoma were found in the lesser omentum. The occurrence of teratoma in males is less common than in females.^[3-5]

The important distinguishing feature of teratoma is the presence of tissues derived from all three germ cell layers within a single lesion. Teratomas are classified as “mature” and “immature” replacing the terms “benign” and “malignant”. The term immature teratoma is used for tumors containing primitive neuroectodermal, endodermal or mesodermal tissues. When malignant germinal epithelial component like endodermal sinus tumor, embryonal carcinoma of adult type, choriocarcinoma, seminoma/dysgerminoma or nongerminoma component like squamous cell carcinoma, adenocarcinoma or sarcoma are associated with immature teratoma, their presence should be noted separately in the diagnosis. Teratoma has to be differentiated from fetus in fetu. Recent concepts regarding the origin of fetus in fetu suggest that it is part of a spectrum of monozygotic twinning gone awry, ranging from conjoined twins at one end to fetaform teratomas at the other.^[7] Presence of vertebral axis (which develops from the primitive streak), appropriate arrangement of other organs or limbs with respect to the vertebral axis are the diagnostic features of fetus in fetu and these features help in differentiating this entity from the highly differentiated teratoma.^[8]

Grading of immature teratoma at all sites depends on the degree of differentiation and presence of immature elements.

While it is generally stated that immature teratoma has a greater potential to metastasize than mature teratoma, increasing evidence indicates that other factors such as location of the tumor, patient's age and sex are also important factors in determining the potential of the malignant behavior of these tumors. It is interesting to note that nearly all teratomas presented in the neck during infancy, regardless of the degree of immaturity, have been benign.^[1] While mature testicular teratomas of adult males can metastasize, testicular teratomas of children, even those having immature elements have not metastasized. In contrast to testicular teratomas, the malignant potential of ovarian teratoma appears to be related to the amount and type of immature component of the tumor and not to patient age.

Acknowledgement

Dr. Baviskar Padmakar K, Department of General Surgery, Rural Medical College, Loni.

References

1. Ordonez NG, Manning JT Jr, Ayala AG. Teratoma of the omentum. *Cancer* 1983;51:955-8.
2. Naik R, Baliga PB, Pai HR, Nayar KS, Shankararayan. Benign teratoma of the lesser omentum-A case report. *Indian J Pathol Microbiol* 2003;46:461-3.
3. Ratan SK, Ratan J, Kalra R. Large benign cystic teratoma of the mesosigmoid causing intestinal obstruction: Report of a case. *Surg Today* 2002;32:922-4.
4. Bowen B, Ros PR, McCarthy MJ, Olmsted WW, Hjermstad BM. Gastrointestinal teratomas: CT and US appearance with pathologic correlation. *Radiology* 1987;162:431-3.
5. Patankar T, Prasad S, Chaudhry S, Patankar Z. Benign cystic teratoma of the lesser omentum. *Am J Gastroenterol* 1999;94:288.
6. Yoshida A, Murabayashi N, Shiozaki T, Okugawa T, Tabata T. Case of mature cystic teratoma of the greater omentum misdiagnosed as ovarian cyst. *J Obstet Gynaecol Res* 2005;31:399-403.
7. Ollapallil J, Werapitiya SB, Irukulla S, Gunawardena ID. Benign cystic teratoma of the omentum. *ANZ J Surg* 2002;72:67-8.
8. Higgins KR, Coley BD. Fetus in fetu and fetaform teratoma in 2 neonates: An embryologic spectrum? *J Ultrasound Med* 2006;25:259-63.
9. Nagar A, Raut AA, Narlawar RS. Fetus in fetu. *J Postgrad Med* 2002;48:133-4.
10. Bell DA, Demopoulos RI. Benign cystic teratoma in the omentum: A mechanism of its development. *Diagn Gynecol Obstet* 1980;2:205-8.

Source of Support: Nil, **Conflict of Interest:** None declared.