

Thoracoscopic management of thoracic duct injury: Is there a place for conservatism?

Kumar S, Kumar A, Pawar DK*

Departments of Surgical disciplines and *Anaesthesia, All India Institute of Medical Sciences, Ansari Nagar, New Delhi - 110029, India.

Correspondence:
Arvind Kumar, MS
E-mail:
arvindreena@hotmail.com

Received : 23-09-03
Review completed : 03-11-03
Accepted : 22-12-03
PubMed ID : 15048002
J Postgrad Med 2004;50:57-59

ABSTRACT

Thoracic duct injury is a rare but serious complication following chest surgeries and major neck dissections. Clinically, it can present as cervical chylous fistula, chylothorax or chylopericardium. Without treatment, the mortality is up to 50% and thus, early aggressive therapy is indicated. Traditional conservative management includes low-fat diet, parenteral nutrition, careful monitoring of fluid and electrolytes, and drainage of the neck wound or chylothorax. Patients with failed conservative management require definitive treatment in the form of ligation of the thoracic duct, which has traditionally been done by thoracotomy. The advent of Video-Assisted-Thoracoscopic-Surgery (VATS) over the last decade has changed the approach towards the management of numerous chest diseases. Thoracoscopic ligation of the thoracic duct has also been reported. We report herein a case of postoperative cervical chylous fistula managed successfully by VATS thoracic duct ligation and present a systematic analysis of the English literature to highlight the current trends in the management of thoracic duct injury.

KEY WORDS: Video-assisted-thoracoscopic-surgery, thoracic duct, chylous fistula, chylothorax

Thoracic duct injury is a rare but serious complication following chest surgeries and major neck dissections with high mortality in untreated patients.^{1,4} Traditional conservative management has a failure rate of up to 48% especially in high output fistulae.¹ Definitive treatment is in the form of ligation of the thoracic duct by open thoracotomy. Video-Assisted-Thoracoscopic-Surgery (VATS) offers excellent magnified view of the thoracic structures, minimal access trauma and a quick postoperative recovery. VATS thoracic duct ligation has also been reported. We report herein a case of postoperative cervical chylous fistula managed successfully by VATS thoracic duct ligation and present a systematic review of the current trends in the management of thoracic duct injury.

Case History

A 26-year-old lady underwent excision of left-sided recurrent brachial plexus neurofibroma under the neurosurgery service. An intraoperative injury to the axillary artery due to tumour adherence was repaired with 5-0 prolene sutures. Postoperatively, the neck drain showed milky white fluid. On the 3rd postoperative day (POD), the patient developed axillary artery thrombosis necessitating re-exploration and placement of a venous graft. A suspicious leaking end of the thoracic duct was also identified and tied. However, the neck drain continued to be milky white. The fluid was confirmed to be chyle and not pus, by dissolving it completely in ether. The average chyle output was 1000-1200 ml/day. A trial of conservative treatment for 5 days in the form of low-fat diet and parenteral nutrition failed. She then underwent VATS thoracic duct ligation (right side). The cervical drain output decreased to 110 ml the next day, the chest tube was removed and the patient resumed normal diet. She was discharged 5 days later after further reduction in drain output allowing removal of the neck

drain.

Under general anaesthesia with double lumen intubation, the patient was positioned in the semi-left lateral position. Four entry ports of 10 mm size each were made on the right side of the chest (one for 30° telescope and three working ports) in the 4th, 5th, 6th and 7th intercostal spaces. The inferior pulmonary ligament was mobilized and the right lung retracted medially and cranially. The azygous vein was identified and clipped at the level of the lung hilum to make it prominent in the supra-diaphragmatic area. The parietal pleura over the azygous vein was divided low down in the chest, just above the diaphragm. The thoracic duct was identified by its longitudinal course medial to the azygous vein and beaded appearance. We further confirmed the duct by making a nick in it, which led to spurting of chylous fluid. Metallic clips were applied on either side of the cut. Wounds were closed after wash and placing a chest drain.

Discussion

The reported incidence of thoracic duct injury ranges from 0.5-2% following chest operations and 1-3% following major neck dissections.^{1,4} Thoracic duct injury is a serious complication, which may lead to nutritional deficiencies, respiratory dysfunction and immunosuppression with a mortality up to 50%.⁵⁻⁹ It can present as cervical chylous fistula, chylothorax or chylopericardium. Chyle leak is suspected by its milky appearance and can be confirmed by high triglyceride levels. We confirmed the presence of chyle at the bedside by its appearance and its solubility in ether.

Conservative management consists of low-fat diet with medium chain triglycerides, total parenteral nutrition, correction



of electrolyte imbalance and an adequate drainage by chest tube or neck drain.^{1,9} Drugs like Somatostatin 14 and more recently, Etilefrine, an adrenergic agent that acts by causing smooth muscle contraction of the thoracic duct, have been reported to be effective.¹⁰ However, it takes several weeks for the chylothorax to resolve with an overall failure rate up to 50%, requiring surgical intervention later.¹¹

The definitive treatment is ligation of the thoracic duct, first reported by Lampson et al.² Despite excellent results, the morbidity, pain and the risks associated with thoracotomy have deterred surgeons from offering this therapy early and conservative therapy for 1-2 weeks is generally instituted initially. Sufficient T cell depletion, to place the patient at risk of septicemia, can occur within 8 days of chyle drainage despite optimal supportive care.⁶ Any major surgery at this stage is logically associated with high morbidity and mortality.

Video-Assisted-Thoracic-Surgery (VATS), introduced in the early 90s, has been applied in the management of chyle leaks also. Inderbitzi et al¹¹ first reported the successful thoracoscopic management of a postoperative chylothorax by fibrin glue application. Since then, 14 reports have attested to the uniform success of the thoracoscopic approach in 21 patients including 16 cases of chylothorax, 4 of chylopericardium and 1 of cervical chylous leak (Table 1). These patients had failed a trial of conservative treatment. All patients had clipping or ligation of the thoracic duct except one who had glue application to the site of the leak. There were no postoperative complications.

The site of ligation of the duct is important for the successful outcome. Wurnig et al reported 4 cases of successful VATS management of chylothorax and chylopericardium and reviewed the anatomical variations in the thoracic duct.³ They concluded that clipping or ligating the duct much above the diaphragm is more likely to fail than if it is done near the diaphragm. In cases where fibrosis makes dissection difficult, VATS mass ligation of the tissues between the azygous vein and the aorta (or sometimes including the azygous vein also) just above the diaphragm has been suggested with as good an outcome as with thoracic duct ligation.³ Full cream milk, methylene blue or sudan black have been recommended orally preoperatively to help identify the thoracic duct or leak.^{12,13,16} However, it may make identification more difficult due to tissue staining and absorption of the light during thoracoscopy.⁵ We feel that magnification by VATS allows identification of this beaded structure between the azygous vein and the aorta. Based on the reported experience with VATS thoracic duct ligation and review of the problems and outcome of conservative management, we feel that the guidelines regarding timing of surgery in patients with chylous leak need revision. Conservative treatment is expensive and fails in the majority of the high-output chylous fistulae. On the other hand, VATS is uniformly effective and is less expensive with low morbidity. Surprisingly, however, conservative treatment continues to be recommended by most authors. Fahimi et al⁴ described 10 patients with postoperative chylothorax; 7 failed two weeks of conservative treatment, requiring surgical intervention. Yet they recommended 2 weeks of conservative trial for all cases.⁴ An elegant commentary has questioned this recommendation,

Table 1: Reported cases of thoracoscopic thoracic duct ligation in English literature

Author	No. of Cases	Age (years)	Sex Surgery	Previous treatment (days)	Presentation	Conservative period (days)	Procedure	Chest tube
1. Inderbitzi et al 1992 ¹¹	1	69	M	CABS	CT (L)	21	(L) VATS + fibrin glue	2
2. Zoetmulder et al 1994 ¹²	1	51	F	Excision of PMT(L)	CT (L)	NA	(L) VATS + ligation	2
3. Janssen et al 1994 ¹³	1	58	M	CABS	CT (L)	14	(L) VATS + clipping	10
4. Graham et al 1994 ⁹	1	82	M	Spinal Surgery	CT (R)	NA	(R) VATS + clipping + fibrin glue + pleurodesis	6
5. Crosthwaite et al 1995 ⁵	1	56	F	Oesophageal mobilisation	CT (R)	5	(R) VATS N + clipping	A
6. Furrer et al 1996 ⁷	1	35	M	No	Primary CP	14	(R) VATS + mass ligation + Pericard	NA
7. Lapp et al, 1998 ¹	1	50	M	MRND (L)	CCF (L)	7	(R) VATS + ligation	NA
8. Selzer et al 1999 ¹⁴	1	26	F	(L) VATS splachniectomy	CT (L)	14	(L) VATS + clipping	NA
9. Wurnig et al 2000 ³	4	46.5 (18-65)	M:2 F: 2	Oesophagectomy: 1 venous catheter: 1 Trauma: 1	CT (R) : 2 CP : 2	NA	(R) VATS + clipping: 4 + pericard.: 2	6 (5-7)
10. Sakata et al 2000 ⁸	1	20	M	No	Primary CP	14	(R) VATS + clipping + pericard	NA
11. Stringel et al 2000 ¹⁵	2	4 72	F M	Fontan produre Trauma	CT (R) CT (R)	NA NA	(R) VATS + ligation	14 4
12. Bonavina et al 2001 ⁶	1	60	M	Esophagectomy	CT (R)	14	(R) VATS + mass ligation	2
13. Buchan et al 2001 ¹⁶	1	18	M	Trauma	CT (R)	5	(R) VATS + clipping	11
14. Fahimi et al 2001 ⁴	4	62.5 (31-80)	M: 3 F : 1	TAA : 2 Sympathectomy: 1 Pneumonectomy: 1	CT (L): 2 (R): 1 (BL): 1	14	(R) VATS: 2 (L) VATS: 2 +Clipping + fibrin glue	5
15. Present case 2002	1	26	F	Excision of brachial plexus neurofibroma (L)	CCF (L)	5	(R) VATS + clipping	1

CABS: Coronary artery bypass surgery, PMT: Posterior mediastinal tumour, MRND: Modified radical neck dissection, CP: Chylopericardium, CT: Chylothorax, CCF: Cervical chylous fistula, VATS: Video-assisted-thoracoscopic-surgery, TAA: Thoracic aortic aneurysm, (R): Right (L): Left, BL: bilateral, Pericard: Partial pericardiectomy, NA: Not available



suggesting instead that all patients with major fistulae (> 1 Litre /24 h) should be immediately re-operated to avoid loss of chyle and lengthy hospital stay.⁴ A similar view has been expressed by others after extensive review of cervical chylous fistulae, with a recommendation of early thoracoscopic intervention for persistent high-volume fistulae that fail conservative management on POD 3 or 4.¹

We too recommend early intervention in patients with high-output fistula (> 1000ml / 24 h) and one-week trial of conservative treatment in others. If the leak is still >200ml/ day after one week, VATS intervention should be offered (Figure 1).

References

1. Lapp GC, Brown DH, Gullane PJ, McKneally M. Thoracoscopic management of chylous fistula. *Am J Otolaryngol* 1998;19:257-62.
2. Lampson RS. Traumatic chylothorax, a review of literature and report of a case treated by mediastinal ligation of the thoracic duct. *J Thorac Surg* 1948;17:778-91.
3. Wurnig PN, Hollaus PH, Ohtsuka T, Flege JB, Wolf RK. Thoracoscopic direct clipping of the thoracic duct for chylopericardium and chylothorax. *Ann Thorac Surg* 2000;70:1662-5.
4. Fahimi H, Casselman FP, Mariani MA, van Boven WJ, Knaepen PJ, van Swieten HA. Current management of postoperative chylothorax. *Ann Thorac Surg* 2001;71:448-51.
5. Crosthwaite GL, Joypaul BV, Cuschieri A. Thoracoscopic management of thoracic duct injury. *J R Coll Surg Edinb* 1995;40:303-4.
6. Bonavina L, Saino G, Bona D, Abraham M, Peracchia A. Thoracoscopic management of chylothorax complicating esophagectomy. *J Laparoendosc Adv Surg Tech A* 2001;11:367-9.
7. Furrer M, Hopf M, Ris HB. Isolated primary chylopericardium: treatment by thoracoscopic thoracic duct ligation and pericardial fenestration. *J Thorac Cardiovasc Surg* 1996;112:1120-1.
8. Sakata S, Yoshida I, Otani Y, Ishikawa S, Morishita Y. Thoracoscopic treatment of primary chylopericardium. *Ann Thorac Surg* 2000;69:1581-2.
9. Graham DD, McGahren ED, Tribble CG, Daniel TM, Rodgers BM. Use of video-

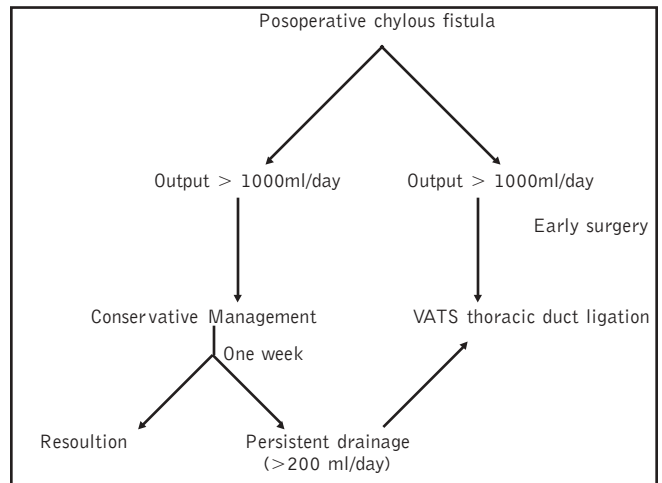


Figure 1: Suggested algorithm for the management of posoperative chylous fistula

10. Collard JM, Laterre PF, Boemer F, Reynaert M, Ponlot R. Conservative treatment of postsurgical lymphatic leaks with somatostatin-14. *Chest* 2000;117:902-5.
11. Inderbitzi RG, Krebs T, Stirnemann P, Althaus U. Treatment of postoperative chylothorax by fibrin glue application under thoracoscopic view with use of local anaesthesia. *J Thorac Cardiovasc Surg* 1992;104:209-10.
12. Zoetmulder F, Rutger E, Baas P. Thoracoscopic ligation of thoracic duct leakage. *Chest* 1994;106:1233-4.
13. Janssen JP, Joosten HJ, Pöbustus PE. Thoracoscopic treatment of postoperative chylothorax after coronary bypass surgery. *Thorax* 1994;49:1273.
14. Selzer DJ, Howard TJ, Kesler KA. Management of chylothorax after thoracoscopic splanchnicectomy. *J Laparoendosc Adv Surg Tech* 1999;9:273-6.
15. Stringel G, Teixeira JA. Thoracoscopic ligation of the thoracic duct. *JLS* 2000;4:239-42.
16. Buchan KG, Hosseinpour Ar, Ritchie AJ. Thoracoscopic thoracic duct ligation for traumatic chylothorax. *Ann Thorac Surg* 2001;72:1366-7.

*S*ubscription Form

To
The Editor,
Journal of Postgraduate Medicine
Sir,

Kindly enter my subscription to "Journal of Postgraduate Medicine". The details are as follows:

Name of the subscriber
Current institutional attachment
Designation
Delivery address

City Pin code
State Country

Phone no. (with STD/ISD code)
Fax no. (with STD/ISD code)
E-mail address

Subscription details
Subscription period One year / Three years / Fifteen years
Subscription type Individual / Institutional AND Print only / Print + yearly CD
Subscription starting from (month/year)

Payment details
Cheque No Dated
Amount Drawn on

Signature of the subscriber Date: