

# Correlation between cyanide-induced decreases in ocular $\text{Ca}^{2+}$ -ATPase and lenticular opacification

*NP Okolie<sup>a</sup> and K Audu<sup>a</sup>*

## ABSTRACT

The effect of cyanide toxicity on  $\text{Ca}^{2+}$ -ATPase activities in lens, cornea and vitreous humour was investigated in New Zealand White rabbits fed for seven weeks on either pure growers mash or mash containing 400ppm inorganic cyanide. Results indicate that  $\text{Ca}^{2+}$ -ATPase activities were significantly decreased in the lens and vitreous humour of the cyanide-fed rabbits ( $p < 0.05$ ), while the corneal enzyme was unaffected. Ophthalmoscopic examination of the cyanide-exposed rabbits revealed adverse morphological changes, including pale fundus, low retinal reflex and lenticular opacification. The results suggest that cyanide-induced cataractogenesis may be a consequence of disruption of vitreous humour and lenticular calcium homeostasis.

## INTRODUCTION

Cyanide is a potent respiratory poison in all aerobic organisms. It combines irreversibly with ferrocytochrome  $a/a_3$ , thereby inhibiting electron transport, mitochondrial oxygen uptake and cellular respiration.<sup>1,2</sup> Humans are exposed to cyanide through dietary and environmental sources.<sup>3</sup> The dietary routes of cyanide exposure include cassava<sup>4</sup>, legumes<sup>5</sup> and cereal grains<sup>6</sup>; while one major environmental source of cyanide is tobacco smoke.<sup>7</sup> Indeed it has been suggested that cyanide in tobacco smoke might be the principal culprit in the pathogenesis of tobacco

amblyopia, characterised by sudden dimness of vision amongst smokers.<sup>8</sup> However, the precise mechanism by which cyanide interferes with visual acuity remains to a large extent unclear. Recently it has been reported that cyanide imposes oxidative stress on the lens, compromises ocular antioxidant status, and triggers off lenticular opacification in rabbits.<sup>9</sup> Studies have shown that calcium ions play a vital role in the development of cataracts.<sup>10,11</sup> Indeed the maintenance of  $\text{Ca}^{2+}$  homeostasis by lenticular  $\text{Ca}^{2+}$  ATPase is an imperative for lens clarity.<sup>12</sup> Inhibition of  $\text{Ca}^{2+}$ -ATPase has been shown to cause  $\text{Ca}^{2+}$  accumulation and lenticular opacification.<sup>13</sup>

The present study was carried out to investigate the influence of cyanide exposure on some ocular tissue  $\text{Ca}^{2+}$ -ATPases so as to see if a link exists between cyanide-induced visual impairment and alterations in calcium homeostasis.

---

KEY WORDS: *Cyanide,  $\text{Ca}^{2+}$ -ATPase, cataracts*

---

<sup>a</sup>*Department of Biochemistry, Faculty of Science, University of Benin, PMB 1154, Benin City, Nigeria.*

**Correspondence:** NP Okolie, Department of Biochemistry, Faculty of Science, University of Benin, PMB 1154, Benin City, Nigeria. E-mail: [ajino@uniben.edu](mailto:ajino@uniben.edu)

## MATERIALS AND METHODS

### Animals and feeding

Two-month-old New Zealand White rabbits (initial mean weight 1.072kg) were purchased from a breeder in Benin City. The animals were housed in clean rabbit hutches and acclimatised on growers mash (Bendel Feed and Flour Mills BFFM Ltd, Ewu, Nigeria) for three weeks prior to the study. They were subsequently assigned randomly to two groups (seven rabbits each). One group (test) was fed growers mash containing 400ppm cyanide. To achieve this, 1g of potassium cyanide was thoroughly mixed with 1000g of growers mash in a plastic bowl prior to presentation. Members of the second group were fed pure mash and served as controls. Before feeding, each feed type was mixed with distilled water in the ratio of 10:1 (w/v) to minimise feed dust and enhance acceptability. Fresh feed was provided on daily basis, while stale remnants were discarded after weighing. On the average, each rabbit received 130g feed/day; and clean drinking water was provided *ad lib*. At the end of seven weeks, the animals were weighed and their eyes were carefully examined using an ophthalmoscope. They were subsequently sacrificed by cervical dislocation, and their eyeballs were carefully dissected out into a beaker containing physiological saline (0.9% NaCl w/v).

### Preparation of tissue homogenates

The lens, vitreous humour and cornea of each eyeball were dissected out. Each tissue was finely ground in a hand mortar with 1.0ml of ice-cold physiological saline (0.9% NaCl w/v) for two minutes. The homogenate was then transferred into a vial and preserved in a refrigerator at 4°C. All tissue extracts were analysed within 48 hours.

### Assay of Ca<sup>2+</sup>-ATPase

Ca<sup>2+</sup>-ATPase was assayed by estimating the amount of inorganic phosphate liberated following incubation of aliquots of tissue

homogenate with disodium ATP.<sup>15</sup> The assay mixture contained 0.1ml of 1mM EDTA; 0.4ml of 30mM MgCl<sub>2</sub>; 0.4ml of 5mM CaCl<sub>2</sub>; 0.3ml of 160mM tris buffer, pH 7.4 and 0.4ml of 0.3mM disodium ATP. Reaction was started by the addition of 0.4ml tissue homogenate. The mixture was vortexed and incubated at room temperature (≈30°C) for 30 minutes, after which 4.0ml of 5% (v/v) trichloroacetic acid was added to stop the reaction. The mixture was subsequently clarified by centrifugation, and inorganic phosphate estimated in the supernatant using ammonium molybdate.<sup>16</sup> Corrections were made for endogenous inorganic phosphate arising from inherent ATP hydrolysis by incorporating a homogenate ATP blank in the assay. Ca<sup>2+</sup>-ATPase was expressed in terms of µg inorganic phosphate liberated/ml of tissue extract.

### Statistics

Means ± SEM values for parameters were compared between tests and controls using Student's t-test, and p values < 0.05 were taken as significant.

## RESULTS

Table 1 shows the mean feed intake, weight gain and feed efficiency values for rabbits in both groups. The cyanide-treated rabbits consumed significantly higher feed (p < 0.05) than those in controls, although this did not translate into superior weight gains for this group.

Figure 1 shows the pattern of changes in Ca<sup>2+</sup>-ATPase activities in some ocular tissues as a result of cyanide exposure. The enzyme activity was significantly decreased in the lenses and vitreous humour of the cyanide-toxified rabbits (p < 0.05). However, there were no significant changes in corneal Ca<sup>2+</sup>-ATPase.

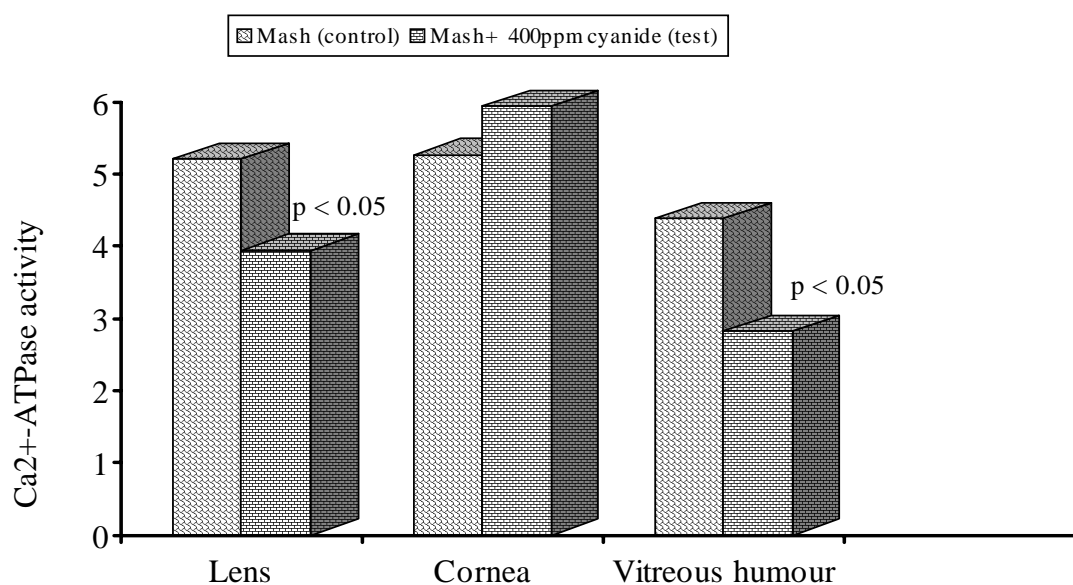
Table 2 shows results obtained in ophthalmoscopic examination of rabbits in both groups before sacrifice. While the rabbits in the control group showed normal features,

those in the cyanide-fed group had weak opacification (cataracts).  
retinal reflex, pale fundus and lenticular

**Table 1** Mean feed intake, weight gain and feed efficiency for the cyanide-treated groups and controls

Feed/group	Mash (control)	Mash + 400ppm cyanide (test)
Mean feed intake (g/rabbit/day)	53 ± 11 <sup>a</sup>	71 ± 9 <sup>b</sup>
Mean weight gain (g/rabbit)	458 ± 18 <sup>a</sup>	401 ± 13 <sup>a</sup>
Feed efficiency (weight gain/g feed)	8.6	5.6

\*Values are mean ± SEM (n = 7). Those having different superscripts across differ significantly (p < 0.05).



**Figure 1**  $Ca^{2+}$ -ATPase activities in lens, cornea and vitreous humour of the cyanide-fed rabbits and controls ( $\mu\text{g P/ml}$  of tissue homogenate)

**Table 2** Retinal reflex, fundus morphology and lens clarity of rabbits in the cyanide-treated group controls\*

Feed/group	Mash (control)	Mash + 400 ppm cyanide (test)
Normal fundus	7	0
Pale fundus	0	7
Mild cataracts	0	5
Marked cataracts	0	2

\* Expressed as number of animals manifesting a given feature in each group.

## DISCUSSION

Lenticular  $\text{Ca}^{2+}$ -ATPase functions to maintain low internal calcium within the lens through the removal of cytosolic calcium across the plasma membrane.<sup>12</sup> Disturbances in lenticular calcium homeostasis have been associated with opacification of the lens and cataracts.<sup>17-19</sup> This is in agreement with results obtained in the present study, in which the cyanide-induced significant decreases in  $\text{Ca}^{2+}$ -ATPase activities in lens and vitreous humour were accompanied by opacification of the lens. It is known that  $\text{Ca}^{2+}$  accumulation within the lens stimulates proteolysis of lens proteins, leading to deleterious changes in lens permeability, thereby making it opaque.<sup>8,20</sup> Indeed it has been demonstrated that the activity of  $\text{Ca}^{2+}$ -ATPase is 50% less in human cataractous lenses than in clear ones.<sup>19</sup> Thus, the significant reductions in  $\text{Ca}^{2+}$ -ATPase activities in the lens and vitreous humour of the cyanide-toxified rabbits are consistent with the observed functional and morphological changes in the lens, fundus and retina. The vitreous humour is a gelatinous matrix that helps to maintain the shape and pliability of the eye.<sup>12</sup> Clarity of vitreous humour ensures minimal light scattering, and enhances vision. As a result, the cyanide-induced reduction in vitreous humour  $\text{Ca}^{2+}$ -ATPase activity will have adverse consequences for vision, arising from alterations in its clarity and permeability due to disruption of  $\text{Ca}^{2+}$  homeostasis in this tissue.

One characteristic feature of cyanide-fed experimental animals is dramatic increase in feed consumption.<sup>14,20,21</sup> A similar characteristic was observed in the present study. The significant increase in feed intake has been attributed to an adaptation to compensate for shortfalls in ATP production arising from the inhibition of aerobic metabolism by cyanide.<sup>22</sup>

This study has established that chronic cyanide toxicity leads to significant reduc-

tions in  $\text{Ca}^{2+}$ -ATPase activities in lens and vitreous humour. Thus, it would appear that one mechanism by which cyanide causes visual impairment might be via the disruption of ocular calcium homeostasis. If this is so, it offers a biochemical explanation for the association between dimness of vision and cyanide exposure from various sources including tobacco smoke and dietary staples such as cassava, legumes and cereals.

## References

1. Jones MG, Bickar D, Wilson MT, Brunori M, Colosimo A and Sarti P. A re-examination of the reactions of cyanide with cytochrome oxidase. *Biochem J* 1984; 220: 56–66.
2. Greer JJ and Jo E. Effects of cyanide on neural mechanisms controlling breathing in neonatal rat in vivo. *Neurotoxicol* 1995; 16: 211–215.
3. Adewusi SR and Akindahunsi AA. Cassava processing, consumption and cyanide toxicity. *J Toxicol Environ Health* 1994; 43: 13–23.
4. Rosling H. Cassava cyanide and epidemic spastic paraparesis – a study in Mozambique on dietary cyanide exposure. Ph.D thesis, University of Upsalla, Sweden, 1986.
5. Okolie NP and Ugochukwu EN. Cyanide contents of some Nigerian legumes and the effects of simple processing. *Food Chem* 1989; 32: 209–216.
6. Erb N, Zinsmeister HD and Nahrsted A. The cyanogenic glucosides of *Triticum aestivum* spp. (*Spelta*), *Secale cereale* and *Sorghum bicolor* var. hybridum. *Planta Med* 1981; 41: 84–89.
7. Hantson P, Benaissa L and Baud F. Smoke poisoning. *Press Med* 1999; 28: 1949–1954.
8. Wilson J, Linell JC and Matthews DM. Plasma cobalamin in neuro-ophthalmological disease. *Lancet* 1966 1: 259–261.
9. Okolie NP and Osobase S. Cataractogenic potential of cyanide-induced oxidative stress in rabbits. *Global J Sci Technol* (In press).
10. Sanderson J, Marcantonio JM and Duncan G. Calcium-induced opacification and

- proteolysis in the organ-cultured human lens. *Invest Ophthalmol Visual Sci* 1998; 39: S660.
11. Sanderson J, Marcantonio JM and Duncan G. A human lens model of cortical cataracts:  $Ca^{2+}$ -induced protein loss, vimetin cleavage and opacification. *Invest Ophthalmol Visual Sci* 2000; 41: 2251–2261.
  12. Paterson CA, Zeng J, Hussein Z, Borchman D, Delamere NA, Garland D and Jimenez-Asensio J. Calcium ATPase activity and membrane structure in clear and cataractous human lenses. *Curr Eye Res* 1997; 16: 333–338.
  13. Hightower RR and Reddy VN. Metabolic studies on calcium transport in mammalian lenses *Curr Eye Res* 1981; 1: 197–207.
  14. Okolie NP, Onoagbe IO and Aisien FA. A comparative study of the effect of oral chronic cyanide administration on some rabbit tissue ATPases. *Comp Biochem Physiol* 1994; 109c: 215–217.
  15. Heskett JE, Loudon JB, Reading WH and Glen AM. The effect of lithium treatment on erythrocyte membrane ATPase activities and erythrocyte ion content. *Br J Clin Pharm* 1978; 5: 323–329.
  16. Fiske C and Subbarow M. The colorimetric determination of phosphorus. *J Biol Chem* 1925; 66: 375–400.
  17. Hightower KR. Cytotoxic effects of internal calcium on lens physiology. A review. *Curr Eye Res* 1985; 4: 453–459.
  18. Whitehart DR. *Biochemistry of the Eye*. Butterworth: Heinemann, 1994.
  19. Duncan G, Marcantonio JM and Tomlinson J. Lens calcium and cataracts. In: G Obrecht and LW Stark (Eds.). *Presbyopia Research* 1991; 30–40.
  20. Okolie NP and Uanseoje OS. Enhancement of vascular contractility and inhibition of  $Na^+$ - $K^+$ -ATPase by chronic cyanide intoxication in rabbits. *Afr J Sci Technol* 2000; 1: 48–51.
  21. Okolie NP and Osagie AU. Liver and kidney lesions and associated enzyme changes induced in rabbits by chronic cyanide exposure. *Food Chem Toxicol* 1999; 37: 745–750.