



The 'DIY Plug' – A cost effective plug hernia repair

M. Sintler, D. Rittoo, R. Patel¹, R. K. Vohra

Department of Vascular Surgery, Selly Oak Hospital, University Hospital Birmingham NHS Trust, Selly Oak, Birmingham, UK, ¹Russell's Hall Hospital, Dudley, West Midlands, UK

For correspondence

M Sintler, Research Department of Vascular Surgery, University Hospital NHS Trust, Selly Oak Hospital, Raddlebarn Road, Selly Oak, Birmingham, B29 6JD, UK. Email: sintler@lineone.net

How to cite this article:

Sintler M, Rittoo D, Patel R, Vohra RK. The 'DIY Plug' – A cost effective plug hernia repair. *Indian J Surg* 2005;67:162-3.

The Royal College of Surgeons Working Party recommends the Lichtenstein 'tension free' mesh repair, to be the treatment of choice for inguinal hernia repair in adults.^[1] It is a relatively easy, and a quick procedure to perform, can be mastered by junior staff, and can be done as a day-case under local or general anaesthesia. It is well tolerated by patients, and has very low reported recurrence rates.^[2]

In the U.S.A., the trend has been more towards a suture-less plug and patch repair. Lichtenstein first described this in 1974.^[3] This method has shown good results in the U.S.A., and U.K. centres are starting to publish their results.^{[4]-[6]} This method has several advantages; the incision is smaller, there is less dissection involved, operative time is shorter, and postoperative pain is less. Patients tend to make a faster recovery, and their time to return to full activity and work is shorter.^[4] Plug migration is a rare complication, but is overcome by the use of tacking sutures between the hernial orifice and the mesh plug.^[7]

In the U.K., the mesh plug repair technique is becoming increasingly popular. The Bard PerFix plug system (Davol, Cranston, RI, USA) being a common choice. The technique is performed by making a 4–6 cm incision medially above the inguinal canal. In a direct hernia, the preformed plug is placed directly in the reduced sac, and in the indirect type the sac is dissected to the deep ring and inverted with a plug placed in the defect. If the defect is large

or the plug has a tendency to 'pop out' it can be secured with 2–4 interrupted sutures. A preshaped mesh is then placed on the posterior wall as reinforcement. This mesh is not sutured. The wound is then repaired as standard.

Recurrence rates are comparable to the onlay mesh repair but postoperative pain, bleeding, and bruising are less and return-to-work time is shorter.^[4] The main disadvantage of the preformed mesh plug repair is the cost of the plug. This is approximately four times that of the standard flat mesh.

In 1974, Lichtenstein was repairing femoral hernias and recurrent inguinal hernias by plugging the defect with a rolled up piece of mesh.^[3] Gilbert, in 1991, popularized the suture-less repair with a cone shaped 'umbrella' mesh plug formed from a sheet of flat mesh.^[8] Robbins and Rutkow modified this plug to form the commercially available PerFix plug system.^[9] We have developed a similar plug, 'the DIY plug' (Do It Yourself plug) folded from half a standard sized 15 x 15 cm sheet of flat prolene mesh (Surgipro™ mesh, United States Surgical/Autosuture, Norwalk, CA, USA). Starting at one edge, the first piece of mesh is folded to create a series of 1-cm pleats. This is then folded in half to form a fan or shuttlecock shape [Figure 1]. This is secured at its waist by a single prolene suture to maintain its shape [Figure 2]. This plug can then be inserted into the reduced hernia sac and held into position with tacking sutures. The other half of the mesh is cut and shaped and placed on the posterior wall for reinforcement. The dimensions of the plug are very similar to the manufactured plug and it holds its self in the defect in a similar manner. The operative technique is the same as that for other plugs.^[9]

The important difference in today's cost-cutting envi-

Paper Received: May 2005. **Paper Accepted:** July 2005. **Source of Support:** Nil.






Figure 1: The mesh is first folded to create a pleated mesh, and then folded in half to form a fan shape. The other half of the mesh is cut and shaped to place on the posterior wall for reinforcement

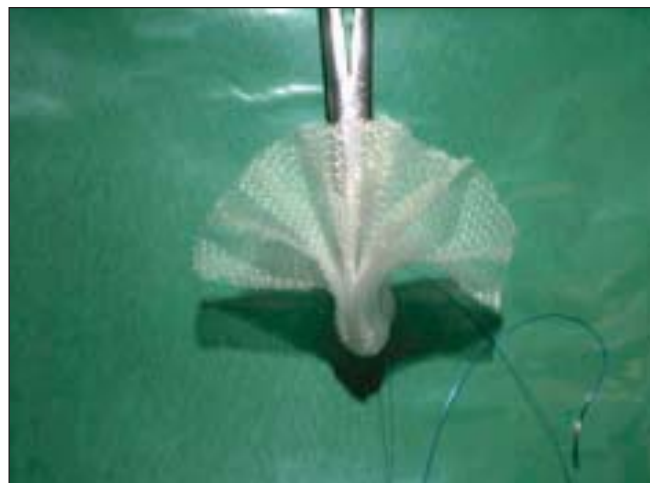


Figure 2: The 'plug' is secured at its waist by a single prolene suture

ronment is that the cost is one-fourth that of the commercial system, \$40 vs \$153. So far our series is small; however, home-made plugs have been used for many years with good results. There is no reason to suggest that this technique is in any way inferior to either the standard 'tension free' repair or to the other plug repair systems. We find the 'DIY plug' method particularly useful for recurrent inguinal hernia repair. One possible advantage of our fan or shuttlecock-shaped plug is that once inserted it tends to hold itself into the defect as the pleats try to unfold.

For any surgeon wishing to perform mesh plug repairs within a limited budget we recommend this 'DIY plug' repair.

REFERENCES

1. The Royal College of Surgeons of England Working Party. Clinical Guidelines on the Management of Groin Hernias in Adults. London: RCSE, 1993
2. Amid PK, Shulman AG, Lichtenstein IL, Hakakha M. Biomaterials for abdominal wall hernia surgery and principals of their applications. *Langenbecks Arch Chir* 1994;379:168-171
3. Lichtenstein IL, Shore JM. Simplified repair of femoral and recurrent inguinal hernias by a 'plug' technique. *Am J Surg* 1974;128:439-44
4. Fasih T, Mahapatra TK, Waddington RT. Early results of inguinal hernia repair by the 'mesh plug' technique – first 200 cases. *Ann R Coll Surg Engl* 2000;82:396-400
5. Goyal S, Abbasakoor F, Stephenson BM. Experience with the preperitoneal 'plug and patch' inguinal hernia repair. *BJS* 1999; 86: 1284-85
6. Nienhuijs SW, van Oort I, Keemers-Gels ME, Strobbe LJA, Rosman C. Randomised clinical trial comparing the Prolene Hernia System, mesh plug repair and Lichtenstein method for open inguinal hernia repair. *BJS* 2005;92:33-38
7. Moorman ML, Price PD. Migrating mesh plug: complication of a well-established hernia repair technique. *American Surgeon* 2004;70(4):298-99
8. Gilbert AI. Sutureless repair of inguinal hernia. *Am J Surg* 1992;163:331-35
9. Robbins AW, Rutkow IM. Mesh plug repair and groin surgery. *Surgical Clinics of North America* 1998;78(6):1007-23