

Retroesophageal right subclavian artery: a case report and review of the literature

Anthony Ocaya

Department of Anatomy, Faculty of Medicine, Gulu University, Gulu, Uganda.

Abstract

Background: Variations of vessels arising from the aortic arch are numerous. One of the common anatomical variations is the right subclavian artery originating as the last branch of the aortic arch. This is a report of a case of an adult male cadaver with a retroesophageal right subclavian artery.

Objective: To highlight the significance of a retroesophageal right subclavian artery, especially its clinical and surgical implications.

Method: Is a report of a case of an anomalous vessel found during routine student dissection of the chest region in a male cadaver.

Result: The retroesophageal subclavian artery was seen originating as the last branch from the postero-lateral aspect of the thoracic aorta at the vertebral level T4. The heart was normal with no other vascular variations seen in this region.

Conclusion: Anatomists and pathologists mainly encounter a retroesophageal right subclavian artery by chance and is usually described as asymptomatic, but several clinical conditions have been associated with its occurrence. This is a clear example of when knowledge of an anatomical variation is helpful in clinical practice.

Keywords: Retroesophageal subclavian artery, arterial variation, male cadaver, Uganda

DOI: <http://dx.doi.org/10.4314/ahs.v15i3.44>

Cite as: Ocaya A. *Retroesophageal right subclavian artery: a case report and review of the literature.* *Afri Health Sci.* 2015;15(3):1034-7. doi: <http://dx.doi.org/10.4314/ahs.v15i3.44>

Introduction

Various vascular anomalies usually occur as a result of failure in the congenital development of the primordial aortic arch¹. In about 80% of individuals, 3 branches arise from the aortic arch; the brachiocephalic trunk, the left subclavian artery, and the left common carotid artery. Adachi first described this branching pattern as type A². Another 11% of reported cases exhibit Adachi's type B pattern, which consists of a common trunk for the left common carotid artery and the brachiocephalic artery. This branching pattern results in only 2 trunks originating from the aortic arch. The third most common pattern, type C, is characterized by the vertebral artery originating proximally to the left subclavian artery as a 4th branch of the aortic arch. Numerous other variations of the branching pattern of the aortic arch are found in less than 1% of cases³. In type G, Ad-

achi described the pattern, in which the right subclavian artery was found as the last branch of the aortic arch. He found the frequency of the type G at 0.2% out of 516 Japanese cadavers.

The subclavian arteries may vary in their origin, course and length. A right retroesophageal subclavian artery (RRESA) is a frequent defect of the embryological aortic arches. It is the most common significant aortic arch anomaly with a reported incidence between 0.4 to 1.8% of the population^{4,5}. This variation is due to interruption of the fourth right aortic arch between the notches for the common carotid artery and subclavian artery while the left fourth arch remains intact⁶. A regression of the proximal portion of the right subclavian artery occurs and the retroesophageal aortic arch persists⁷. The retroesophageal right subclavian artery is usually described as not producing symptoms, because its discovery is usually coincidental. Nevertheless, it may be the site of formation of atherosclerotic plaque, inflammatory lesions or aneurysm⁶. The seriousness of the RRESA aneurysm is associated with the high risk of clot-related events, tracheal or venous compression and rupture^{8,9}. The anatomic and morphologic variations of the aortic arch and its branches are significant for diagnostic and surgical procedures in the thorax and neck. This present study describes a case of RRESA in our specimen and discusses the anatomy and embryology

Corresponding author:


Anthony Ocaya
Lecturer and Head,
Department of Anatomy,
Faculty of Medicine,
Gulu University, Uganda.
P.O.Box 166, Gulu
Tel: +256 772 463 917
Email: antocaya@gmail.com

of this case, the first report of its kind from Uganda, and the likely clinical and surgical implications.

Case report

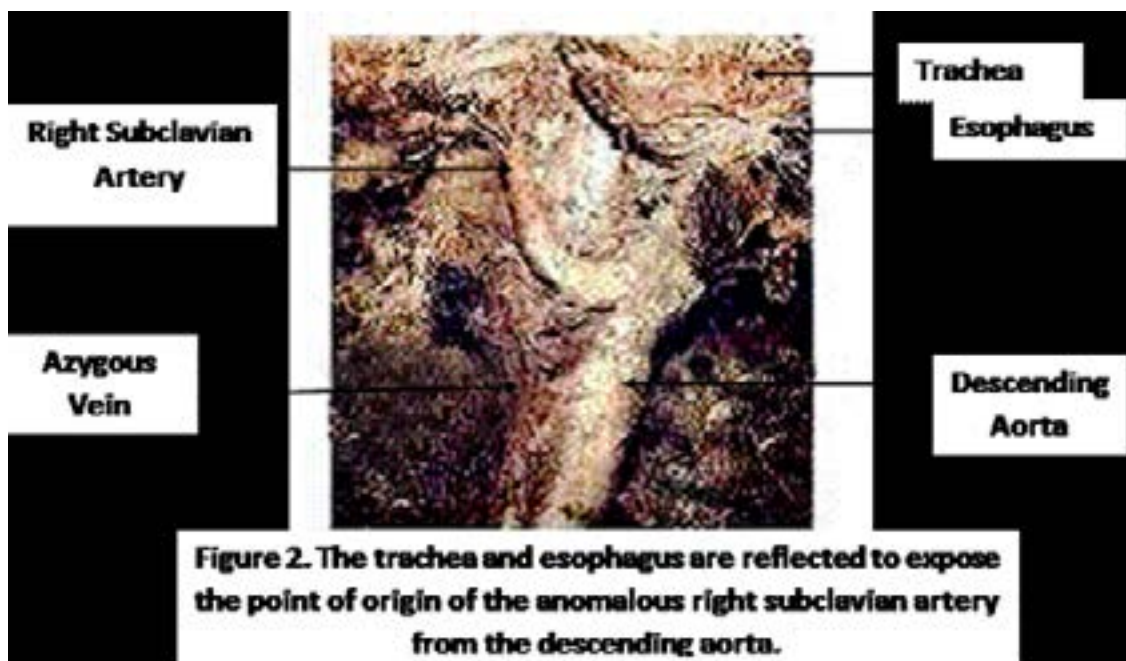
During routine students' dissection teaching of the retropharyngeal space to medical students in the Anatomy dissection laboratory of Mbarara University of Science and Technology, an abnormal vessel with an unusual origin and course was found originating from the right

postero-lateral aspect of the descending aorta at the level of the fourth thoracic vertebra. It measured about 10mm in diameter at its origin. The specimen was an African, adult male formalin-fixed cadaver and there were no records as to the exact age and cause of death. The variant vessel passed antero-laterally to the right, posterior to the esophagus and trachea, to the right axilla allowing it to be more accurately described as a retroesophageal right subclavian artery (Figure 1).



The vessel left an impression of its course on the right lung. Further dissection revealed that this vessel was a

retroesophageal right subclavian artery (Figure 2), consistent with the Adachi type G classification.



The right vertebral and internal thoracic arteries originate normally from this vessel. No other aortic arch or vascular variations were noted in this region. The aortic arch appeared of normal length and width, located above the heart. Four branches originated from the aortic arch, namely from right to left; the right common carotid, the left common carotid, the left subclavian and right subclavian arteries respectively. The abdominal viscera were all normal.

Case discussion

During the fourth and fifth week of embryological development, aortic arches arise from the aortic sac ventral to the pharynx, and terminate in the right and left dorsal aortae¹⁰. Usually, six pairs of aortic arches are formed, and during the sixth to eighth weeks of development, the primitive aortic arch pattern is transformed into the adult arterial arrangement¹¹.

In the normal development of the right subclavian artery, the proximal part of the artery is formed from the fourth embryonic aortic arch and part of the right dorsal aorta from the fourth aortic arch to the seventh inter-segmental artery¹¹. In the case of an abnormal or-

igin of the right subclavian artery, it occurs when the right fourth aortic arch and the right dorsal aorta disappear cranial to the seventh intersegmental artery¹². As a result, the retroesophageal right subclavian artery forms from the seventh intersegmental artery distally, and the distal part of the right dorsal aorta proximally¹². With further development, differential growth shifts the origin of the retroesophageal right subclavian artery and the left subclavian artery cranially¹¹. The fact that the stem of the anomalous subclavian artery is derived from part of the right dorsal aorta explains the retroesophageal course that this artery takes as it passes to the upper limb¹³.

In the adult, an abnormal origin of the subclavian artery is usually from the arch of the aorta, just distal to the origin of the left one¹⁴. Other variations of the branches of the aortic arch are shown in Figure 3. Our specimen represented a right retroesophageal artery, which, by definition is a right subclavian artery that arises from the distal portion of the aortic arch as its last branch (Figure 3e). This condition is possibly explained by the persistence of the embryonic right aorta and the obliteration of the fourth aortic arch of the right side¹⁵. Other branches of the arch were normally placed.

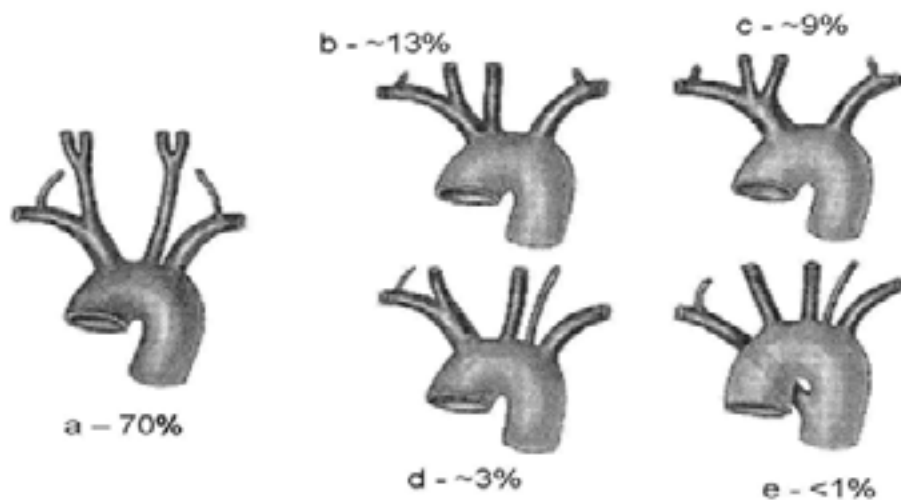


Figure 3 Variations in the origins of the main arterial branches from the aortic arch.

- a) "textbook case" or "normal case"
- b) common origin of the brachiocephalic trunk and the left common carotid
- c) common stem from the left common carotid artery and the brachiocephalic trunk
- d) left vertebral artery as an independent branch of the aortic arch
- e) right subclavian artery as the last branch of the aortic arch (*as observed in our case*). In this variation the artery usually passes to the right, behind the oesophagus. This may cause difficulties in swallowing (dysphagia lusoria). [Putz and Pabst, 2001]

Much as RRESA is usually described as asymptomatic¹⁶, several clinical conditions have been associated with its occurrence. Symptoms from a right retroesophageal artery may include inequality of upper extremity pulses, dysphagia and dyspnoea. Dysphagia lusoria may occur as a clinical finding, due to the compression of the esophagus between the right common carotid artery and the trachea anterior to it and the right subclavian artery posterior to it¹⁷. Acute ischemia of the right upper limb due to thrombosis of an aberrant subclavian artery was described^{16,18}. Akers Jr et al.¹⁸ described a case of non-occlusive and presumably non-atherosclerotic thrombosis in a 35-year-old woman that led to an extensive distal embolization requiring amputation of the right hand.

Boas et al.¹⁶ reported a case of acute ischemia of the right upper extremity due to an extensive thrombosis of a RRESA in a 79-year-old woman that was successfully treated by extensive thrombectomy of the arteries in the upper extremity and right subclavian-to-carotid artery transposition. Other rare but clinically important complications include tracheoesophageal fistulas and arterioesophageal fistulas. The presence of a variant subclavian artery should be considered especially when ischemia of the upper limb is severe and occlusion is located at the shoulder level.

Conclusion

This is a clear example of when knowledge of an anatomical variation is helpful in clinical practice. This case report therefore becomes imperative as it shows that the possibility of occurrence of a retroesophageal right subclavian artery is still in the population.

Acknowledgment

I would like to thank the staff of the Department of Anatomy at Mbarara University of Science and Technology for their support and guidance during my placement with them.

References

1. McDonald JJ, Anson BJ: Variation in the origin of arteries from the aortic arch in American whites and negroes. *Am J Phys Anthropol* 1940; 27: 91–107.
2. Adachi B. *Das Arteriensystem der Japaner*. 1st Ed. Vol. 1. Kyoto: Verlag der Kaiserlich-Japanischen Universität, Kenyusha Press, 1928, pp. 29-41.
3. Bergman RA, Thompson SA, Afifi AK, Saadeh FA, *Compendium of human anatomic variation: catalog,*

atlas and world literature, Urban & Schwarzenberg, Baltimore– Munich, 1988.

4. Richardson J, Doty D, Rossi N. Operation for Aortic Arch Anomalies. *Ann Thorac Surg* 1981; 31: 426-32.
5. Rahman HA, Sakurai A, Dong K, Setsu T, Umetani T, Yamadori T. The retroesophageal right subclavian artery: A case report and review. *Acta Anat* 1993; 68: 281-7.
6. Feugier P, Lemoine L, Gruner L, Bertin- Maghit M, Rousselet B, Chevalier JM. Arterioesophageal Fistula: A Rare Complication of Retroesophageal Subclavian Arteries. *Ann Vasc Surg* 2003; 17: 302-5.
7. Momma K, Matsuoka R, Takao A. Aortic Arch Anomalies Associated with Chromosome 22q11 Deletion (CATCH 22). *Pediatr Cardiol* 1999; 20: 97-102.
8. Roland CF, Cherry KJ. Symptomatic Atherosclerotic Stenotic Disease of an Aberrant Right Subclavian Artery. *Ann Vasc Surg* 1991; 5: 196-8.
9. Schmidt FE, Hewitt RL, Flores Jr AA. Aneurism of Anomalous Right Subclavian Artery. *J Vasc Surg* 1992; 16: 90-5.
10. Sadler TW. *Langman's Medical Embryology*. 9th Ed., Baltimore: Williams and Wilkins. 2004.
11. Moore KL, Persaud TVN. *The Developing Human: Clinically Oriented Embryology*. 6th Ed., WB Saunders Co., Philadelphia. 1998; 384-394
12. Hollinshead WH. *Anatomy for Surgeons*, 2nd Ed., Vol 2, New York: Harper & Row. 1968.
13. Tubbs SR, Oakes JW, Salter GE, Zehren SJ. Retroesophageal right subclavian artery with persistent ductus arteriosus. *Anat Sci Inter*. 2004; 79: 98-100.
14. Sinnatamby CS. *Last's Anatomy: Regional and Applied*. 11th Ed., Edinburgh, Churchill Livingstone. 2006.
15. Standring S. *Grey's Anatomy: The Anatomical basis of clinical practice*. 39th Ed., Edinburgh, Churchill Livingstone. 2005; 1044.
16. Boas N, Desmoucelle F, Bernadet V, Ranceschi JC. Rare Cause of Acute Ischemia of the Right Upper Extremity: Thrombosis of a Retroesophageal Subclavian Artery. *Ann Vasc Surg* 2002; 16: 387-90.
17. Fazan VPS, Ribeiro RA, Ribeiro JAS, Rodrigues Filho OA. Right retroesophageal subclavian artery. *Acta Cir Bras* 2003 vol. 18 suppl 5. Disponível em www.scielo.br/acb.
18. Akers Jr DL, Fowl RJ, Plettner J, Kempczinski RF. Complications of Anomalous Origin of the Right Subclavian Artery: Case Report and Review of the Literature. *Ann Chir Vasc* 1991; 5: 358-88.
19. Putz R, Pabst R. *Sabotta Atlas of Human Anatomy* 13th Ed., Munich, Urban & Fisher. 2001.