

Inducing repigmentation by regrafting and phototherapy (311 nm) in punch grafting failure cases of lip vitiligo: A pilot study

Koushik Lahiri, Subrata Malakar, Nilendu Sarma, Uttam Banerjee

Pigmentary Disorder Unit, Rita Skin Foundation, GD-381, Sector III, Salt Lake, Kolkata - 700 106. India.

Address for correspondence: Dr. Koushik Lahiri, Pigmentary Disorder Unit, Rita Skin Foundation, GD-381, Sector III, Salt Lake, Kolkata - 700 106. India. E-mail: koushik66@vsnl.com

ABSTRACT

Background: Punch grafting followed by PUVA/PUVASOL is an established mode of therapy in vitiligo including that on the lips. **Aims:** To assess the efficacy of NB-UVB along with regrafting in patients in whom punch grafting had failed to evoke any response. **Methods:** Five patients with stable and isolated lip vitiligo in whom punch grafting and PUVA had failed to produce pigmentation were treated by regrafting and subsequent NB-UVB (311 nm) phototherapy. **Results:** Complete repigmentation was observed in three of the five cases after 16 weeks. In the remaining two, the results were mixed. **Conclusions:** Stable lip vitiligo usually responds very well to punch grafting and PUVA/PUVASOL. In patients who fail to respond to this treatment, complete repigmentation following regrafting and NB-UVB is an observation that needs to be explained.

KEY WORDS: Vitiligo surgery, Punch grafting, Phototherapy, NB-UVB

INTRODUCTION

Lip vitiligo (LV) occurs either as an isolated condition or as an extension of vitiligo vulgaris. Owing to a complete lack of pigment cell reservoir in the lips, medical management often fails to repigment the achromic lip. In such cases punch grafting (PG) is considered to be the easiest, fastest and least expensive treatment modality even on the lips.¹ Punch grafting (PG) followed by PUVA/PUVASOL is an effective therapy.²⁻⁵ In the present study an attempt was made to explore the efficacy of narrow band-ultraviolet B (NB-UVB) phototherapy along with regrafting in patients of LV in whom punch grafting had failed to evoke any response.

MATERIAL AND METHODS

Regrafting was done at the insistence of one patient of LV in whom PG had failed (Figures 1-4) and who was on NB (311 nm) phototherapy. The new grafts started showing spread of pigment and within 4 months his lip was completely repigmented (Figure 5). Inspired by this, we performed regrafting in another four patients with LV who had failed to respond to PG. None of them had a history of herpes simplex. All cases were stable for at least 6 months and lacked Koebner phenomenon. Test grafting was done in doubtful cases.

PG was performed with 1.5 mm punches. The grafts were placed directly from the donor area (buttock or upper

How to cite this article: Lahiri K, Malakar S, Sarma N, Banerjee U. Inducing repigmentation by regrafting and phototherapy (311 nm) in punch grafting failure cases of lip vitiligo: A pilot study. *Indian J Dermatol Venereol Leprol* 2004;70:156-8.

Received: January, 2004. **Accepted:** March, 2004. **Source of Support:** Nil.

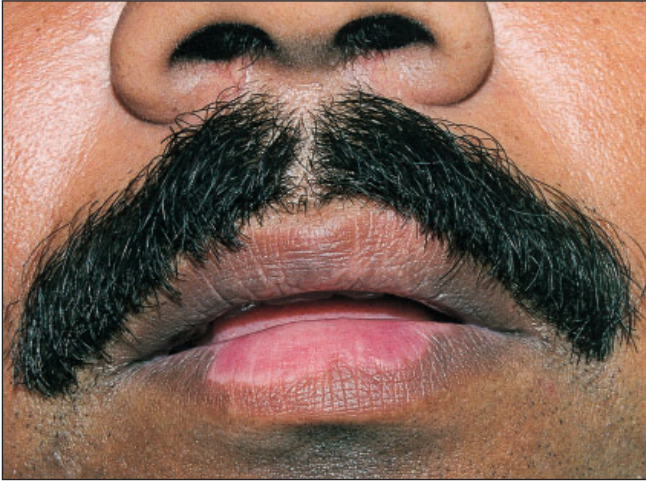


Figure 1: Lip vitiligo on lower lip (Case1)

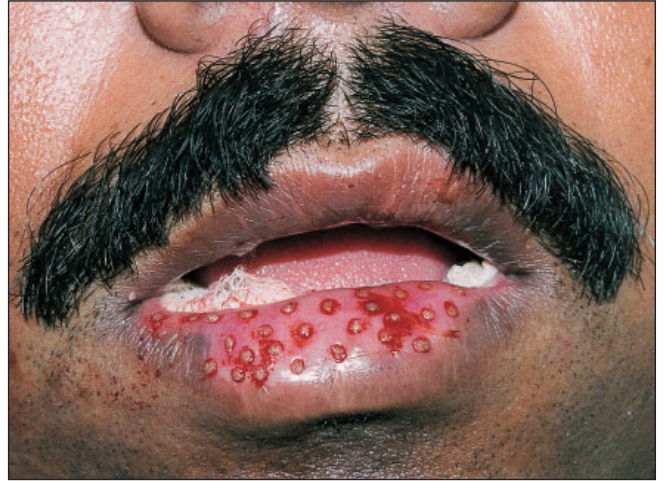

Figure 2: First session of punch grafting

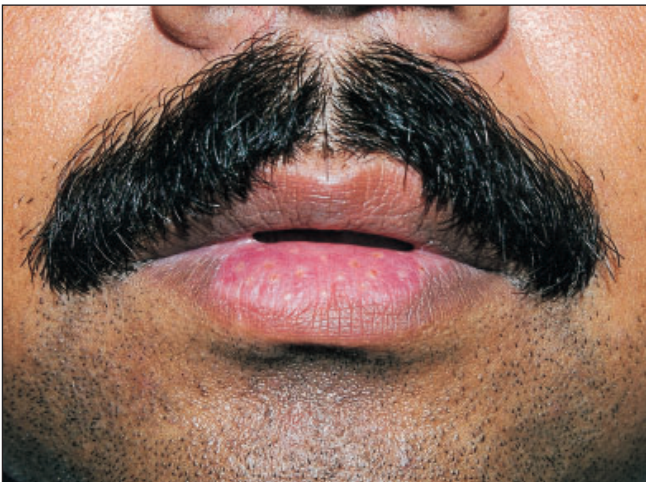


Figure 3: Grafts depigmented with no pigment spread.

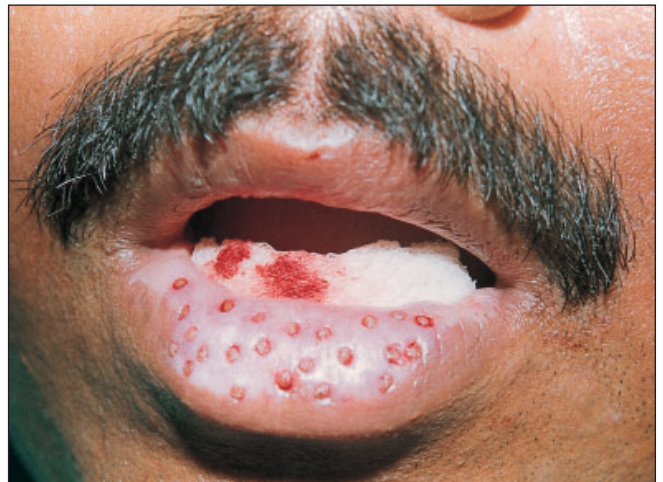

Figure 4: Re-grafting, under NB-UVB cover

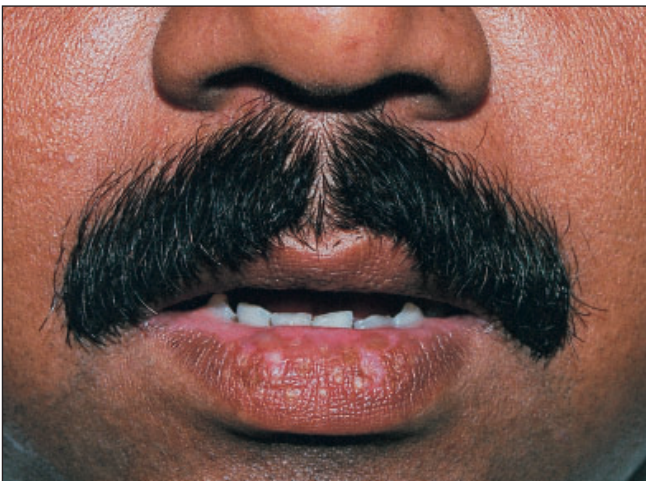


Figure 5: Complete repigmentation with NB-UVB after 16 weeks

thigh) to the recipient area so as to speed up the procedure and lessen the chance of infection. Same sized punches were used for both the sites. If both the lips were involved, one lip was taken up for grafting at a time to avoid inconvenience to the patient. There were three layers of dressing from inside out: paraffin-embedded gauze (Gelonet®), Surgipad® and Micropore®. The patients were advised to take a liquid diet for the first 24 hours, preferably with a straw. The dressings were removed on the 3rd or 5th post-operative day.

Most of our patients were of skin types Fitzpatrick 4 and 5. All were put on NB phototherapy (311 nm) by a Spiegel series 8 machine with Philips TL/01 311 nm

lamps before and after PG. The dose was 8.41 mw/cm². The minimal erythema dose (MED) was calculated; the average MED was 1261.5 mJ/cm². A suberythema dose of 1000 mJ/cm² was used initially. It was increased by 10% to 20% per treatment. After 10 weeks (20 treatments) the increment rate was reduced to 2% to 5% up to a maximum of 2270 mJ/cm².

RESULTS

A total of 66 grafts were placed on 5 individuals. The lower lip was grafted in 4 patients and both lips in 1. Repigmentation started within 16 days in one patient, and on the 19th and 20th day respectively in another two. In one patient no pigment spread was observed even 12 weeks after the second session. In the last patient pigment spread was very slow and unsatisfactory. Graft rejection was not noted in our patients. Transient cobblestoning was observed in one patient, but it subsided with time. The donor area healed with minimal scarring in all the cases.

DISCUSSION

The melanocytes are stimulated during photochemotherapy in vitiligo. They migrate from the hair follicle reservoir, spread centrifugally from the infundibulum to the basal cell layer and recolonize the epidermis with functional pigment cells. This does not occur on the lips as there are no hair follicles, explaining why medical management often results in a slow or poor response. Thus, transplantation of melanocytes by any of the surgical modalities is the most logical procedure in these cases. In our opinion, early treatment of LV by surgical methods speeds up the repigmentation and thereby avoids frustration both for the patients and doctors.¹

Amongst the various phototherapy options, NB-UVB therapy (311 nm) is effective and has a good safety profile.⁶⁻¹¹ Stable LV usually responds well to punch grafting and PUVA/PUVASOL,¹ but herpes simplex induced lip leucoderma does not.^{12,13} The first session of PG failed to evoke any result in our patients of LV, but complete repigmentation occurred after regrafting and NB-UVB. Recently, perilesional and circulating melanocyte-specific cytotoxic

CD8 cells have been identified and it was also found that UVB therapy promotes T-cell apoptosis.^{14,15} This theory may explain our observation of repigmentation after regrafting and NB-UVB therapy. To the best of our knowledge such an effort of regrafting followed by phototherapy (311 nm) in repigmenting failed cases of lip vitiligo was not attempted before.

REFERENCES

1. Malakar S, Lahiri K. Punch grafting in lip leucoderma. *Dermatology* 2004;208:125-8.
2. Orentreich N, Selmanwiz VJ. Autograft repigmentation of leucoderma. *Arch Dermatol* 1972;105:734-6.
3. Falabella R. Repigmentation of segmental vitiligo by autologous minigrafting. *J Am Acad Dermatol* 1983;9:514-21.
4. Lahiri K, Sengupta SR. Treatment of stable and recalcitrant depigmented skin conditions by autologous punch grafting. *Indian J Dermatol Venereol Leprol* 1997;63:11-4.
5. Malakar S, Dhar S. Treatment of stable and recalcitrant vitiligo by autologous miniature punch grafting: A prospective study of 1,000 patients. *Dermatology* 1999;198:133-9.
6. Njoo MD, Bos JD, Westerhof W. Treatment of generalized vitiligo in children with narrow-band (TL-01) UVB radiation therapy. *J Am Acad Dermatol* 2000;42:245-53.
7. Natta R, Somsak T, Wisuttida T, Laor L. Narrowband ultraviolet B radiation therapy for recalcitrant vitiligo in Asians. *J Am Acad Dermatol* 2003;49:473-6.
8. Scherschun L, Kim JJ, Lim HW. Narrow-band ultraviolet B is a useful and well-tolerated treatment for vitiligo. *J Am Acad Dermatol* 2001;44:999-1003.
9. Acharya S, Srinivas CR, Sheno SD, Balchandran C. Determination of minimal erythema dose in Indian patients for ultraviolet-B phototherapy. *Indian J Dermatol Venereol* 1991;57:214-5.
10. Pai GS, Vinod V, Krishna V. MED estimation for narrow band UV-B on type IV and type V skin in India. *Indian J Dermatol Venereol Leprol* 2001;67:251-2.
11. Serish, Srinivas CR. Minimal erythema dose (MED) to narrow band ultraviolet-B (NB-UVB) broad band ultraviolet-B (BB-UVB). A pilot study. *Indian J Dermatol Venereol Leprol* 2002;68:63-4.
12. Malakar S, Dhar S. Rejection of punch grafts in three cases of herpes labialis induced lip leucoderma, caution and precaution. *Dermatology* 1997;195:414.
13. Malakar S, Dhar S. Acyclovir can abort rejection of punch grafts in herpes-simplex induced lip leucoderma. *Dermatology* 1999;199:75.
14. Ortonne JP. Vitiligo pathogenesis: What's new? *J EADV* 2003;17:30.
15. van den Wijngaard RM, Aten J, Scheepmaker A, Expression and modulation of apoptosis regulatory molecules in human melanocytes: Significance in vitiligo. *Br J Dermatol* 2000;143:573-81.