



## Case Report

---

# Disseminated primary cutaneous histoplasmosis successfully treated with itraconazole

M. K. Singhi, Lalit Gupta, Dilip Kacchawa, Dhruv Gupta

Department of Skin, STD & Leprosy, Dr. S.N. Medical College, Jodhpur, India.

Address for correspondence: Dr. M. K. Singhi, Bungalow No. III, M.D.M. Hospital Road, Shastri Nagar, Jodhpur - 342003, India.  
E-mail: mks\_2\_in@yahoo.com

---

### ABSTRACT

A 60-year-old immunocompetent lady with disseminated primary cutaneous histoplasmosis is reported. Histology showed a granulomatous skin infiltrate with numerous intracellular PAS positive rounded yeast cells within macrophages. Culture on Sabouraud's dextrose agar yielded a typical cottony white colony characteristic of *Histoplasma capsulatum*. Treatment with itraconazole showed an excellent response.

**KEY WORDS:** *Histoplasma capsulatum*, Itraconazole

### INTRODUCTION

Histoplasmosis, also called as Darling's disease, is caused by a dimorphic fungus *Histoplasma capsulatum*.<sup>1</sup> The fungus has two variants viz. *Histoplasma capsulatum* var. *capsulatum*, which is found in America and the tropics, and *Histoplasma capsulatum* var. *duboisii*, which is found in Africa.

*Histoplasma capsulatum* (the American form) mainly causes pulmonary involvement resembling tuberculosis and may pass asymptotically to involve the reticuloendothelial system and the skin. *H. duboisii* mainly causes cutaneous and osseous involvement and is strictly restricted to the African continent.<sup>1</sup> The pulmonary and disseminated forms of histoplasmosis are very common in AIDS patients and cause great morbidity and mortality. Primary cutaneous histoplasmosis is rare. We report a case of disseminated

primary cutaneous histoplasmosis caused by *H. capsulatum* in an immunocompetent patient on account of its rarity.

### CASE REPORT

A 60-year-old female presented in the skin out-patient department with gradually progressive erythematous nodules and plaques distributed over the neck, chest and abdomen (Figure 1) present since the last 2 years. She experienced mild burning and pain in the lesions. Some of them also showed spontaneous ulceration and crusting.

She gave a history of residing in an area which was heavily inhabited by birds and the soil in that area contained plenty of birds' excreta. There was no history of trauma preceding the onset of skin lesions. There was no generalized lymphadenopathy, hepatosplenomegaly

**How to cite this article:** Singhi MK, Gupta L, Kacchawa D, Gupta D. Disseminated primary cutaneous histoplasmosis successfully treated with itraconazole. *Indian J Dermatol Venereol Leprol* 2003;69:405-7.

**Received:** November, 2003. **Accepted:** December, 2003. **Source of Support:** Nil.



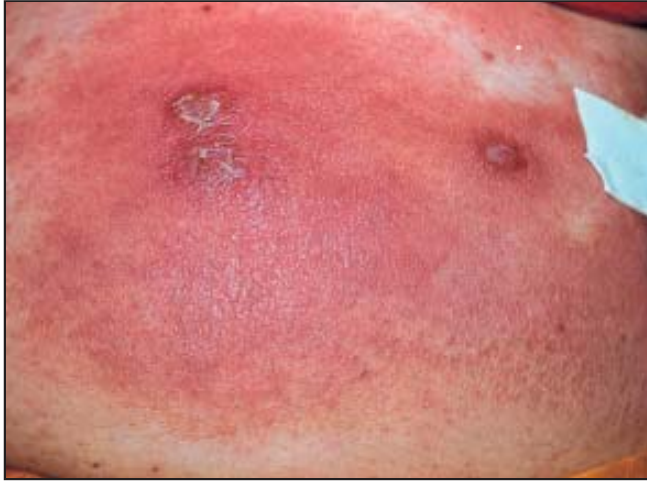


Figure 1: Large erythematous plaque with satellite lesions on the abdomen



Figure 2: Characteristic cottony white colonies of *Histoplasma capsulatum*

or any other detectable systemic abnormality. Her general health was good.

Laboratory investigations including routine haemogram, urine and stool examination, and renal and liver function tests were within normal limits. Roentgenogram of the chest and bones were normal. Mantoux test, VDRL test and ELISA for HIV were negative. Ultrasonography of the abdomen revealed a mildly enlarged liver with fatty liver change.

Tissue culture for fungus on Sabouraud's dextrose agar yielded typical cottony white buff colonies (Figure 2) in 4 weeks. Histopathology from the lesions showed a granulomatous infiltrate involving the dermis and subcutaneous tissue mainly consisting of macrophages and scattered giant cells. Small (2-4 microns), PAS-positive, round-to-oval organisms with a clear halo were seen inside the macrophages (Figure 3). The dermis showed prominently dilated blood vessels with a lymphohistiocytic infiltrate. The histopathology was compatible with the diagnosis of histoplasmosis.

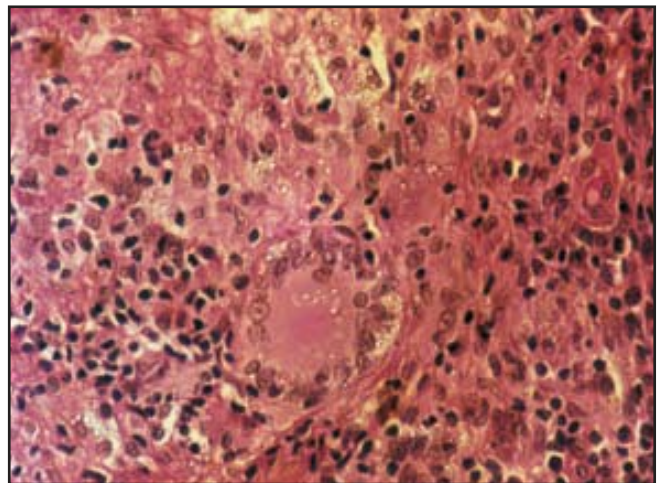


Figure 3: Granulomatous infiltrate in the dermis showing multiple round cysts of *Histoplasma capsulatum* inside a giant cell and macrophages (100X H&E)

With itraconazole 100 mg BD for 6 months, the patient showed complete clearing of lesions after 16 weeks of therapy (Figure 4).

## DISCUSSION

*H. capsulatum* is an intracellular organism parasitizing the reticuloendothelial system and involving the spleen,

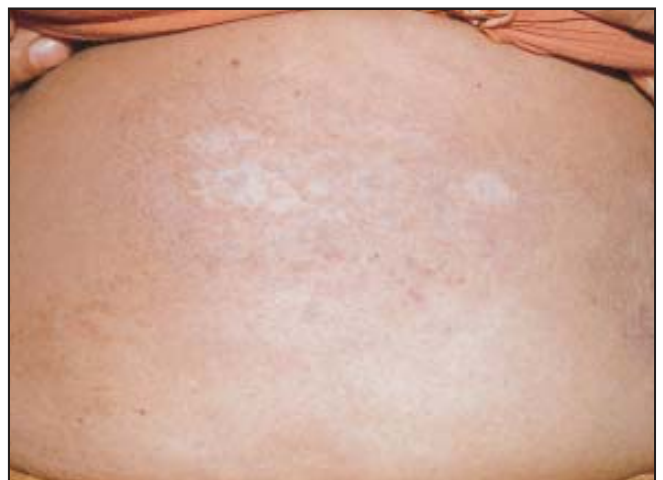

Figure 4: Complete clearing after 16 weeks of itraconazole therapy





liver, kidney, CNS and other organs. *H. capsulatum* exists as a saprophyte in nature and has been isolated from soil, particularly when contaminated with chicken feathers or droppings. Its spores are infectious to humans by the airborne route.<sup>1</sup>

Histoplasmosis is caused by either *Histoplasma capsulatum* var. *capsulatum*, which is found in America and the tropics, and *Histoplasma capsulatum* var. *duboisii*, which is found in Africa. The African form differs from the classical American form in its clinical and pathological features. In the African form, lesions of skin and bones predominate in contrast to the American form, in which pulmonary changes dominate the clinical picture.<sup>2</sup> The histopathology of the African form characteristically shows a giant cell granuloma containing yeast cells 10-15 microns in diameter, whereas in the American form smaller (3-4 microns) yeast cells are embedded in histiocytes.<sup>2</sup> Primary cutaneous histoplasmosis is very rare. There is a report of widespread mucocutaneous histoplasmosis with papular or nodular lesions without internal involvement that resolved with amphotericin B.<sup>3</sup> Another report is of a patient with generalized erythroderma due to histoplasmosis who had no internal lesions.<sup>4</sup>

Histoplasmosis is rarely reported from India, perhaps on account of its varied clinical presentation and lack of awareness amongst dermatologists. Panja and Sen first reported histoplasmosis from India in 1959.<sup>5</sup> *Histoplasma capsulatum* is considered to be endemic in certain North Indian states like West Bengal, where a study showed a prevalence of skin positivity of 9.4% to histoplasmin antigen.<sup>6</sup> There are a few sporadic case reports from South India as well.<sup>7</sup> To the best of our knowledge, no cases have been reported from the northern and western parts of India.

Our patient showed widespread cutaneous lesions

without any evidence of systemic involvement and immunosuppression. There was no evidence of any internal organ involvement. Cutaneous nodules and plaques, which are generally seen in the African form of histoplasmosis, were associated with the histopathological features of classical histoplasmosis. Similar cases have been reported earlier.<sup>7</sup>

Histoplasmosis usually responds to itraconazole, fluconazole or amphotericin B.<sup>8</sup> Our patient showed an excellent response to itraconazole 100 mg BD. The lesions started healing after 4 weeks of therapy and completely cleared in 16 weeks. Even after clearing of lesions, therapy was continued for another 8 weeks (total 24 weeks). The patient was followed up for 6 months after cessation of therapy, but there was no recurrence. The treatment was tolerated well, with no side effects.

## REFERENCES

1. Hay RJ, Moore M. Mycology. In: Champion RH, Burton JL, Burns DA, Breathnach SM, editors. Rook/Wilkinson/Ebling Textbook of dermatology. 6th ed. Oxford: Blackwell Science; 1998. p. 1363-6.
2. Adetokunbo LA. Cutaneous manifestations of African histoplasmosis. Br J Dermatol 1970;82:435-47.
3. Soo-Hoo TS, Adams BA, Yusof D. Disseminated primary cutaneous histoplasmosis. Aust J Dermatol 1980;21:105-7.
4. Cramer HJ. Erythrodermatische Hauthistoplasrose. Dermatologica 1973;146:249-55.
5. Panja G, Sen S. A unique case of histoplasmosis. J Indian Med Assoc 1959;23:257-8.
6. Sanyal M, Thammaya. Skin sensitivity to histoplasmin in Calcutta and its neighbourhood. Indian J Dermatol Venereol Leprol 1980;46:94-8.
7. Nair PS, Vijayadharan M, Vincent M. Primary cutaneous histoplasmosis. Indian J Dermatol Venereol Leprol 2000;66:151-3.
8. Negróni R, Palmieri O, Koren F, Tiraboschi IL, Galimberti RL. Oral treatment of paracoccidioidomycosis and histoplasmosis with itraconazole in humans. Rev Infect Dis 1987;9:S47-50.

