

## CONTENTS

### Editorial

- Criteria for deciding cost-effectiveness for expensive new anti-cancer agents  
*Rajiv Sarin*..... 1

### Original Articles

- The effect of three mouthwashes on radiation-induced oral mucositis in patients with head and neck malignancies: A randomized control trial  
*PD Kumar Madan, PS Sequeira, Kamalaksha Shenoy, Jayaram Shetty* ..... 3
- Implications of contrast-enhanced CT-based and MRI-based target volume delineations in radiotherapy treatment planning for brain tumors  
*Niloy R Datta, Rajasekar David, Rakesh K Gupta, Punita Lal* ..... 9
- Radiofrequency ablation of hepatic metastasis: Results of treatment in forty patients  
*GK Rath, PK Julka, S Thulkar, DN Sharma, Amit Bahl, S Bhatnagar*..... 14
- Execution of mantle field with multileaf collimator: A simple approach  
*Ramachandran Prabhakar, Kunhi Parambath P Haresh, Pappiah S Sridhar, Macharla A Laviraj, Pramod K Julka, Goura K Rath*..... 18
- Prognostic and diagnostic value of serum pseudocholinesterase, serum aspartate transaminase, and serum alanine transaminase in malignancies treated by radiotherapy  
*Arun Chougule, Sofia Hussain, Dwaraka Prasad Agarwal* ..... 21

### Review Article

- An overview on applications of optical spectroscopy in cervical cancers  
*C Murali Krishna, GD Sockalingum, MS Vidyasagar, M Manfait, Donald J Fernanades, BM Vadhiraja, K Maheedhar*..... 26

### Case Reports

- Radiotherapy for management of skin cancers in fibrodysplasia ossificans progressiva: A case report and review of the literature  
*John Antony Frew, Charles G Kelly* ..... 37
- Sarcomatoid squamous cell carcinoma of uterine cervix: Pathology, imaging, and treatment  
*Milind Kumar, Amit Bahl, Daya Nand Sharma, Shipra Agarwal, Dhanapathi Halanaik, Rakesh Kumar, Goura Kishore Rath* ..... 39

### Brief Communications

- Chest wall metastasis from hepatocellular carcinoma in the absence of a primary: An unusual presentation  
*Kaustav Talapatra, Reena Engineer, Jai Prakash Agarwal, Shilpa Vyas, Shyam Kishore Shrivastava*..... 42
- Endobronchial metastasis of follicular thyroid carcinoma presenting as hemoptysis: A case report  
*RAS Kushwaha, Sanjay Kumar Verma, Sanjay Vineet Mahajan*..... 44
- Accelerated partial breast irradiation: An advanced form of hypofractionation  
*Ashwini Budrukkar* ..... 46
- Coexistence of carcinoma breast and Paget's disease of bone  
*S Sundaraiya, PK Pradhan, A Gupta, M Jain, SK Mishra, BK Das*..... 48

### Letter to Editor

- Dysplastic hematopoiesis and underlying dysthyroidism  
*Riad Akoum, Michel Saade, Wafic Tabbara, Emile Brihi, Marwan Masri, Khaled Habib, Gerard Abadjian*..... 50

### Reviewers' List, 2007 ..... 51

# Execution of mantle field with multileaf collimator: A simple approach

Ramachandran  
Prabhakar, Kunhi  
Parambath P Haresh,  
Pappiah S Sridhar,  
Macharla A Laviraj,  
Pramod K Julka,  
Goura K Rath

Department of Radiation  
Oncology, All India  
Institute of Medical  
Sciences, New Delhi -  
110 029, India

**For correspondence:**  
Dr. Ramachandran  
Prabhakar, Department  
of Radiation Oncology,  
Institute Rotary Cancer  
Hospital, All India  
Institute of Medical  
Sciences, New Delhi -  
110 029, India.  
E-mail: prabhakar\_smr@  
hotmail.com

## ABSTRACT

**Background:** Until very recently mantle field radiotherapy remained the gold standard for the treatment of favorable early-stage Hodgkin's lymphoma. The classic mantle includes all the major lymph nodes above the diaphragm and extends from the inferior portion of the mandible to the level of the insertion of the diaphragm.

**Aims:** To describe a simple technique that has been devised to treat the mantle field with the help of multileaf collimator and using computed tomography (CT)-based treatment planning.

**Materials and Methods:** CT scan was performed with the patient in the supine position and the datasets were transferred to the Eclipse™ treatment planning system. Elekta Precise™ linear accelerator equipped with 40 pairs of multileaf collimator (MLC) was used for the execution of the mantle field. The MLC's shapes were designed to take the shape of the conventional customized blocks used for treatment of mantle field. The anterior mantle field was divided into three separate MLC segments with the collimator kept at 0°. The first MLC segment was shaped to cover the neck, clavicular regions, and mediastinum. The second and the third MLC segments covered the right and left axilla, respectively. The posterior fields were opposed to the anterior subfields in a similar fashion. The dose was prescribed at the midplane, using reference points.

**Results and Conclusion:** The technique described in this study is very simple, easy to implement, and avoids unnecessary delay in the execution of the mantle field. The mantle field can be easily shaped with the multileaf collimators, without any collimator rotation.

**KEY WORDS:** Hodgkin's lymphoma, mantle field, multileaf collimator, radiotherapy

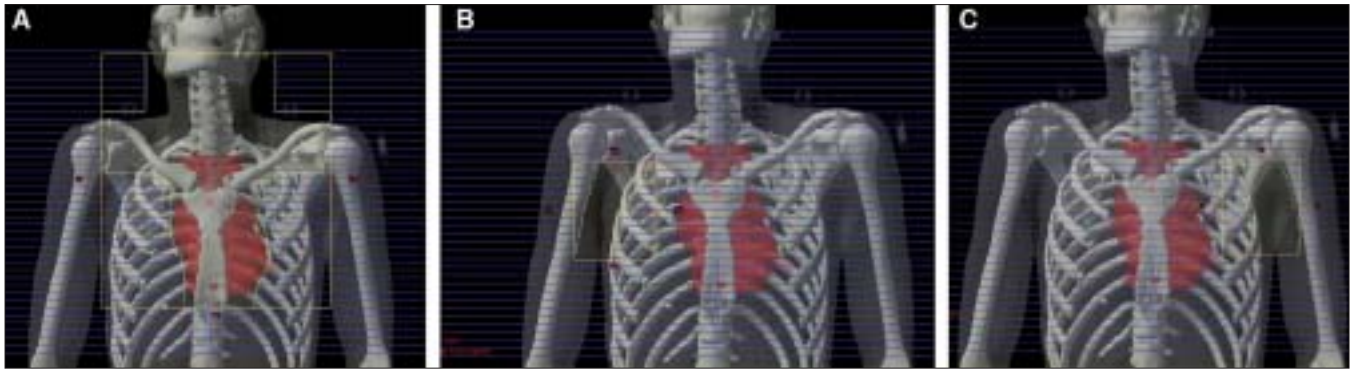
## INTRODUCTION

Hodgkin's lymphoma (HL) was initially described by Thomas Hodgkin's in 1832.<sup>[1]</sup> In those days, it used to be a dreaded disease. With the evolution of newer techniques in radiotherapy after 1960 and the availability of newer chemotherapeutic drugs, HL has become a prime example of a curable malignancy. Most of the credit for the initial developments in radiotherapy in the treatment of this disease go to Henry Kaplan of Stanford University.<sup>[2]</sup> Until very recently, mantle field radiotherapy remained the gold standard for the treatment of favorable, early-stage HL.

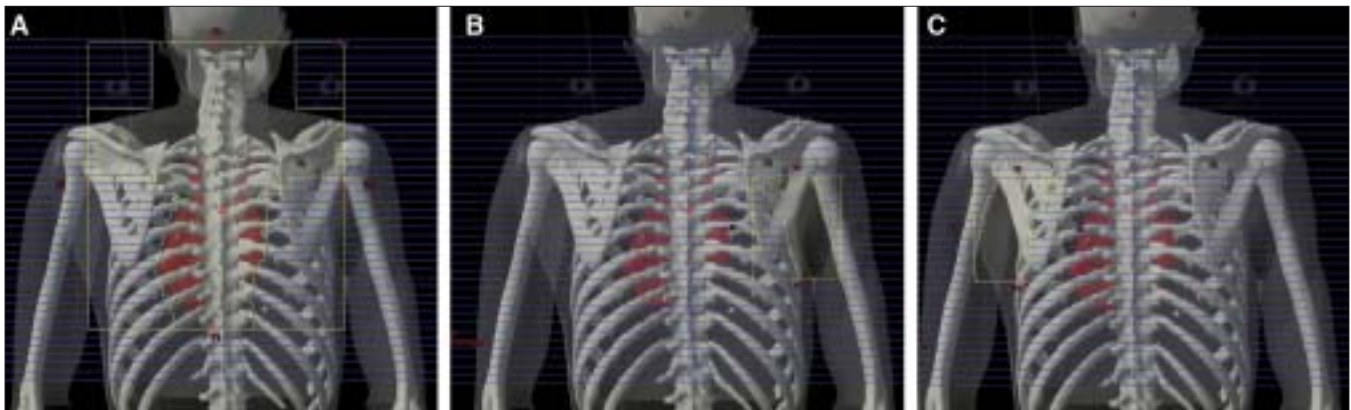Mantle field planning used to be a cumbersome process, involving repeated simulations to make customized lead shielding blocks for the lungs, humeral head, larynx, etc. It often took a week to finalize the plan. Nowadays, with the wide availability of the multileaf collimator (MLC) inbuilt in the linear accelerator treatment head, this process is much easier. This paper describes a simple approach in defining the mantle field with MLC by splitting the anterior and posterior field into multiple subfields.

## MATERIALS AND METHODS

The patient was immobilized with Vacloc™ and uniframe head mask (Med-Tec™) in the supine position and then scanned in a Somatom Volume Zoom™ CT scanner for 2.5 mm slice thicknesses. The CT datasets were transferred to the Eclipse™ treatment planning system through the DICOM network for treatment planning. Bones were delineated using the segmentation wizard available in the treatment planning system. The nodal regions were contoured on individual slices for fitting the MLCs. With the help of bony landmarks and the planning target volume (PTV), the MLC shapes were designed to obtain the shape of the mantle field. Elekta Precise™ equipped with 40 pairs of MLC was used and the whole treatment was performed with 6 MV x-rays. The anterior mantle field was divided into three separate MLC segments. The collimator was kept at 0°. The first MLC segment was shaped to cover the neck, clavicular regions, and mediastinum. The MLC leaves were moved in or out to get the required shape. The second and the third MLC segments covered the right and left axilla, respectively. The posterior field was designed in a similar fashion. Three reference points were



**Figure 1:** (A) Central anterior MLC subfield; (B) Right anterior MLC subfield; (C) Left anterior MLC subfield



**Figure 2:** (A) Central posterior MLC subfield; (B) Right posterior MLC subfield; (C) Left posterior MLC subfield

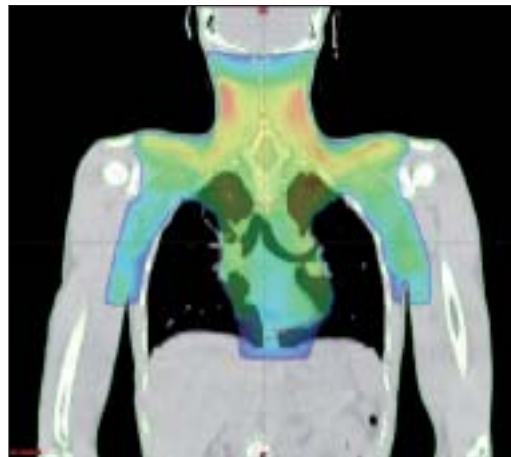
defined in the mid-plane for the three MLC subfields and the dose was prescribed to their respective reference points. The whole treatment was performed in the SAD technique. For inhomogeneity correction, equivalent tissue-air ratio method was used for dose calculation. Summation of the three anterior subfields and their matching was verified by exposing an enhanced dose range (EDR) film.

## RESULTS

Figure 1[A-C] shows the anterior MLC subfields. Figure 1A shows the first MLC segment shaped to cover the neck, clavicular regions, and mediastinum. Figure 1B and C show the MLC segment shaped to cover the right and left axilla, respectively. Similarly, Figure 2 [A-C] shows the posterior MLC subfields opposed to their respective anterior subfields. Figure 3 shows the resultant coronal dose distribution obtained out of the combined anterior and posterior MLC subfields.

## DISCUSSION

Until recently the mantle field technique remained the standard for good prognosis, early-stage HL treated by radiotherapy alone. The present trend in the treatment is to use fewer chemotherapy cycles, along with less dose and volume of radiotherapy, to get a better overall therapeutic ratio.<sup>[3]</sup> In a recent study, Hoskins *et al.*<sup>[4]</sup> have shown that involved-field radiotherapy for stage I



**Figure 3:** Coronal dose distribution of the summated anterior and posterior MLC subfields

and IIA HL resulted in a 11% greater risk of relapse compared with extended-field radiotherapy. Even though mantle is less frequently used nowadays, the planning and execution of mantle still remains a concern for the radiation oncologist, physicist, dosimetrist, and the radiation technologist.

There are a number of advantages in adopting the MLC technique instead of using the conventional lead blocks for shaping the mantle field. The conventional technique requires

considerable amount of time for preparation of the shielding blocks; this can be avoided with MLCs and the treatment can be started without any delay. The MLC technique also considerably reduces the time required for delivering a fraction as compared to the conventional mode. The MLC-based mantle technique avoids the risk of injury to the patient due to inadvertent falling of shielding blocks from the shadow tray while placing and removing them. It also avoids any chance of mismatch in the placement of the anterior and posterior shielding blocks during treatment. It eliminates the exposure to toxic lead, both for the radiation staff and the patient. In case of conventional mantle field employing blocks, the presence of hotspots are unavoidable inside the treated volume. Using multiple MLC subfields, hotspots arising at areas above the supraclavicular region and other areas where effective anterior/posterior separation are thin can be minimized. This eliminates the use of compensators<sup>[5]</sup> and also provides better dose homogeneity within the treated volume than the conventional method. With more and more cobalt being replaced with linac, the use of MLCs for mantle field with this technique simplifies the whole treatment process.

MacDonald *et al.*<sup>[6]</sup> has described a technique for defining the mantle field with MLC by rotating the collimator either to 90° or 270°. The disadvantage here is that we still might need additional blocks to the mantle field to shield the extra lung volume coming within the field above the hilar area. Our method avoids the requirement for any additional shielding blocks other than the use of the MLC. In this method, during matching of the three MLC subfields [Figure 1A-C], due to a tongue-and-groove effect, there may be a slight underdosage at the junction, which can be avoided by shifting the junction on alternate fractions.

In this study, the prescription dose was kept at 25 Gy, and so we did not use any laryngeal shielding. In situations where the prescription dose is more than 25 Gy, the whole treatment can be divided into phase I and phase II. Phase I can be carried out without any laryngeal shield up to 20 Gy and in phase II, the larynx may be shielded with MLCs. A set of MLCs of one bank can be made to overtravel to the other end, at the level of the larynx, in phase II. Those shielded portions which are adjacent to the larynx on either side can be treated with two separate MLC subfields. With this method, the need for a separate laryngeal shielding block can be avoided.

The maximum possible field size in Elekta Precise is 40 × 40 cm at 100 cm SSD. For fields more than 40 cm, the patient can be treated at extended SSD. One might argue about the interleaf leakage with the MLC that may lead to a high dose being delivered to the underlying lung. Here one should not forget that in case of conventional mantle fields, shielding achieved by 5 HVL thickness may also result in a similar dose. The X-jaws of Elekta Precise machine has the capability of over-traveling the central axis by 12.5 cm. So the secondary back-up jaws (X-jaws) can still minimize the interleaf leakages. The combination of MLC and jaws for shielding further reduces the scattered dose to the patient. The only disadvantage of our technique is that it requires multiple subfields for achieving the conventional mantle dose distribution.

## CONCLUSION

The technique described in this study is very simple, easy to implement, and avoids unnecessary delay in the execution of the mantle field. The shape of the mantle block can be easily achieved with the MLCs.

## REFERENCES

1. Yahalom J. Don't throw out the baby with the bathwater: On optimizing cure and reducing toxicity in Hodgkin's lymphoma. *J Clin Oncol* 2006;24:544-8.
2. Kaplan H. The radical radiotherapy of Hodgkin's disease. *Radiology* 1962;78:553-61.
3. Hodgson DC, Hudson MM, Constine LS. Pediatric hodgkin lymphoma: Maximizing efficacy and minimizing toxicity. *Semin Radiat Oncol* 2007;17:230-42.
4. Hoskin PJ, Smith P, Maughan TS, Gilson D, Vernon C, Syndikus I, *et al.* Long term results of a randomised trial of involved field radiotherapy versus extended field radiotherapy in stage I and II Hodgkin lymphoma. *Clin Oncol (R Coll Radiol)* 2005;17:47-53.
5. Davis QG, Paulino AC, Miller R, Ting JY. Mantle fields in the era of dynamic multileaf collimation: Field shaping and electronic tissue compensation. *Med Dosim* 2006;31:179-83.
6. MacDonald S, Bernard S, Balogh A, Spencer D, Sawchuk S. Electronic compensation using multileaf collimation for involved field radiation to the neck and mediastinum in non-Hodgkin's lymphoma and Hodgkin's lymphoma. *Med Dosim* 2005;30:59-64.

**Source of Support:** Nil, **Conflict of Interest:** None declared.