

# Three way translocation in a new variant of t(8;21) acute myeloid leukemia involving Xp22

Vundinti BR, Kerketta L, Madkaikar M, Jijina F<sup>1</sup>, Ghosh K

Institute of Immunohaematology (ICMR), 13<sup>th</sup> Floor, New Multistoreyed Building, <sup>1</sup>Department of Haematology, KEM Hospital Campus, Parel, Mumbai - 400 012, Maharashtra, India

Correspondance to: Dr. Vundinti BR, E-mail: vbaburao@hotmail.com

---

## Abstract

The t(8;21)(q22;q22) is one of the most frequent chromosomal abnormality associated with acute myeloid leukemia (AML) M2 sub type. The additional chromosomal abnormalities including structural and numerical are frequently reported with the translocation, t(8;21)(q22;q22). We report a case of AML-M2 with t(X;8;21)(p22;q22;q22) associated with loss of Y chromosome. Using a dual color fluorescence *in situ* hybridization (FISH) analysis with *ETO* and *AML1* probes, we demonstrated an *ETO/AML1* fusion signal on the derivative chromosome 8 and one *ETO* signal on derivative Chromosome Xp22. The patient did not respond to therapy and follow-up of cytogenetics revealed same chromosome abnormality. Hence, this three way translocation involving X chromosome might be associated with poor prognosis.

**Key words:** Acute myeloid leukemia, AML-M2, *ETO/AML* fusion, Xp22

---

## Introduction

The t(8;21) is one of the most frequent chromosomal abnormality associated with acute myeloid leukemia (AML) involves the *AML1* (acute leukemia 1 also called RUNX1, core binding factor protein (CBF alpha) and PEBP2 alpha B) gene on Chromosome 21 and the *ETO* (eight-twenty one also MTG8) gene on Chromosome 8.<sup>[1]</sup> The t(8;21)(q22;q22) is associated with 12% of denovo AML cases and up to 40% in the AML subtype M2 of the French-American-British (FAB) classification. Furthermore, it is also reported in a small portion of M0, M1 and M4 AML patients. Clinically t(8;21) with AML usually shows some specific characteristics and has a good response to chemo therapy with a higher remission rate and a long median survival.<sup>[2]</sup> On the other hand, some patients also showed poor prognosis in AML with t(8;21) and the associated bad prognosis factors have not been strongly established to date. The t(8;21)(q22;q22) frequently associated with additional chromosomal aberrations and it is one of the most recurrent chromosomal abnormalities in AML.<sup>[3]</sup> Approximately 3% to 4% of AML associated with t(8;21) have variant translocations.<sup>[4]</sup> Some investigators have reported a favorable outcome for patients with

AML with variant t(8;21),<sup>[5]</sup> similar to patients with classical t(8;21) but others have reported that patients who have AML with variant t(8;21) have a worse prognosis.<sup>[6]</sup> Here we report a case of AML(M2) with a 45,t(X;8;21)(p22;q22;q22),-Y karyotype as a variant chromosomal abnormality.

## Case Report

A-30-year-old male, farmer by occupation, presented with fever and pain in joints for one month and progressive weakness and fatigability. He was a non-smoker and a non-consumer of alcohol. Complete blood count values were as follows; hemoglobin (Hb), 11.4g/dL; mean corpuscular volume (MCV), 102.2 fl; white blood cells (WBC), 0.015X10<sup>9</sup>/L; and platelets, 0.095X10<sup>9</sup>/L. Bone marrow aspirate was hypercellular with 56% blasts and majority are medium large sized with 0-1 nucleoli and Aur rods. All stages of erythroid maturation, reduction in megakaryocytes and presence of iron stores were observed. The patient was diagnosed as AML-M2 according to the French-American -British classification. The patient's thyroid function was normal; vitamin B12 and folate levels were within the normal range. Tests for antinuclear factor and HIV antibody

were negative. The patient was treated with 7 + 3 regime Ara-C and Mitoxanthrone. The BM aspiration after one month showed remission and cytogenetic findings were unchanged. Patient died after two months in remission from remittent relapse.

### Immunophenotype

Immunophenotyping of leukemia blasts was done using fluorescein isothiocyanate and phycoerythrin-conjugated monoclonal antibodies (Becton Dickinson, Franklin Lakes, NJ). Antibodies against the following antigens were used; CD2, CD3, CD4, CD5, CD7, CD8, CD10, CD11c, CD13, CD14, CD15, CD19, CD33, CD34, CMPO and HLA-DR. Less than 20% positivity was considered a negative result. The blasts showed positivity with CD13 (84%) CD19 (66%), CD33 (61%), CD34 (65%), HLA-DR (71%) and MPO stain positivity. Based on these findings and using a European Group for the Immunological characterization of acute leukemias (EGIC) criteria, the patient was diagnosed with AML-M2.

### Cytogenetics

Cytogenetic analysis of unstimulated bone marrow cell was performed at the time of diagnosis and after one month of treatment using direct harvest and harvest after 24h-culture. Metaphase chromosomes were GTG-banded and karyotyped according to ISCN 2005. Chromosomal analysis revealed mosaic karyotype with 45,X,t(X;8)(p22;q22)-Y [17] and 46,XY [8] [Figure 1].

Fluorescence *in situ* hybridization (FISH) was performed according to standard procedure using *AML1* and *ETO* dual color dual fusion probe (Vysis, Germany). FISH analysis revealed *AML1/ETO* fusion on Chromosome 8q22 region and the *ETO* (red) gene translocated to Chromosome Xp22 [Figure 2]. The combination

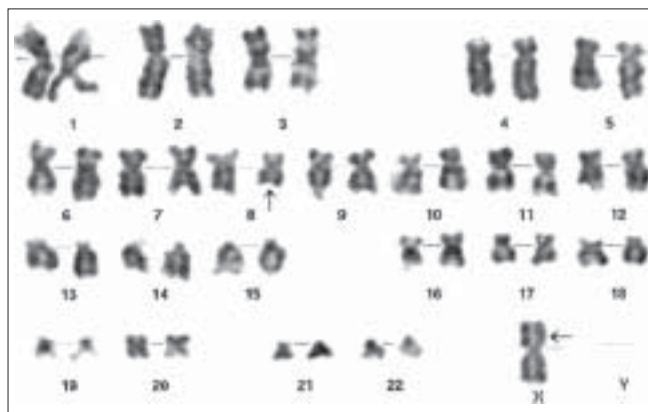


Figure 1: Karyotype showing t(X;8)(p22;q22) and loss of Y chromosome

of FISH and G-banding chromosome analysis of the patient was 45,X,t(X;21;8)(p22.1;q22;q22),-Y karyotype.

### Discussion

The t(8; 21)(q22; q22) is most commonly reported chromosomal abnormality in ANLL. This anomaly is seen in 15% of all the AML with differentiations (M2) and some cases of AML (M4).<sup>[1]</sup> Patients with t(8;21) reported to have a favorable prognosis with uniformly high complete remission rate, they respond well to high dose Ara-C containing regime.<sup>[2]</sup> The additional chromosome abnormalities were frequently reported in t(8;21) cases. The additional numerical changes and structural changes reported to be two third and one third cases respectively.<sup>[3]</sup> The deletions of Chromosomes 7q and 9q in t(8;21) associated with good prognosis. Recently Huang *et al*,<sup>[7]</sup> reported four cases with three way translocation involving t(8;21) and these variant translocation had good response as in typical t(8;21) cases. Others also reported variant translocation in t(8;21) patients and shown good prognosis.<sup>[8]</sup> In our case, chromosome analysis in combination with GTG-banding and FISH revealed three way translocation t(X;21;8)(p22;q22;q22), where *ETO* gene is translocated to Xp22 region. It is presumed to be Xp22.1 region translocated to Chromosome 21 and *AML1* translocated to 8q22. The Xp22 translocation to 21q22 has been reported in one case of AML.<sup>[9]</sup> Though molecular cytogenetic evaluation of Xp22.2 was not possible, to the best of our knowledge this is the first case of translocation between Xp22 and 8q22 in AML-M2.

The Xp22 region contain *PRDX4* gene, which is one of six peroxiredoxin-family genes that are highly conserved in eukaryotes and prokaryotes and are ubiquitously

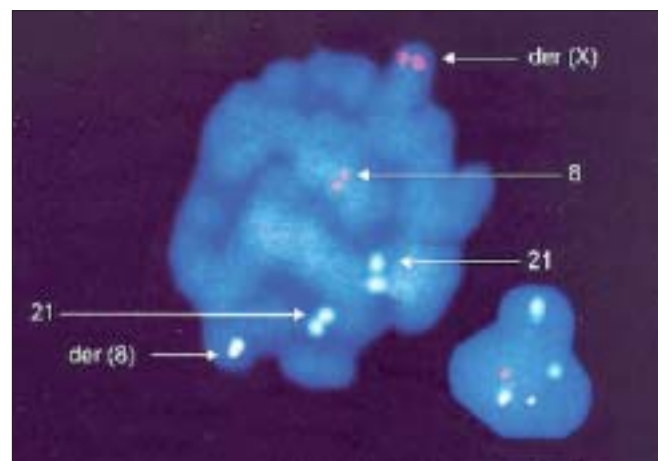


Figure 2: FISH showing *AML1-ETO* fusion signal on chromosome 8 and *ETO* (red) on chromosome X

expressed. Peroxiredoxin genes exhibit thioredoxin-dependent peroxidase activity and have been implicated in a number of other cellular functions such as cell proliferation and differentiation. *PRDX4* plays a regulatory role in the activation of the transcription factor NF-kappa B and is significantly down regulated in acute promyelocytic leukemia.<sup>[9]</sup> This is the first case of antioxidant enzyme gene involved through translocation in leukemia. The loss of Y chromosome in t(8;21) have been reported to be associated with an aggressive clinical and intermediate prognosis.<sup>[10]</sup> Recently *KIT* and internal tandem duplications (*ITD*) of *FLT3* is considered to be predicting poor prognosis in AML. However *FLT3* mutations were ruled out in our case. The patient was not responding to therapy and died after two months. Since the patient had loss of Y chromosome and had three way translocation involving Xp22.1, the variant t(8;21) with X chromosome might be poor prognostic indicator. It is also essential to see the loss of Y chromosome in variant translocation for better management of the disease. However molecular biological studies are important to understand the molecular mechanism of variant translocations in leukemia.

## References

1. Friedman AD. Leukemogenesis by CBF oncoproteins. *Leukemia* 1999;13:1932-42.
2. Chen Z, Sandberg AA. Molecular cytogenetic aspects of haematological malignancies: Clinical implications. *Am J Med Genet* 2002;15:130-41.
3. Claus M, Haferlach T, Schnittger S, Kern W, Hiddemann W, Schoch C. Cytogenetic profile in denovo acute myeloid leukemia with FAB subtypes M0,M1 and M2: A study based on 652 cases analysed with morphology cytogenetics and fluorescence *in situ* hybridization. *Cancer Genet Cytogenet* 2004;155:47-56.
4. Groupe Francais de cytogenetique Hematologique. Acute myelogenous leukemia with an 8;21 translocation: A report on 148 cases from the Groupe Francias de cytogenetique. *Cancer Genet Cytogenet* 1990;44:169-79.
5. Ishii Y, Sashida G, Takaku TI, Sumi M, Nakajima A, Ohyashiki K. Cryptic chromosomal anomaly in a patient with acute myeloid leukemia leading to AML1/ETO fusion with unfavorable prognostic factors. *Cancer Genet Cytogenet* 2005;160:94-5.
6. Ishida F, Uneno M, Tanaka H, Makishima H, Suzawa K, Hosaka S, *et al.* t(8;21;14)(q22;q22;q24) is a novel variant of t(8;21) with chimeric transcripts of AML1-ETO in acute myelogenous leukemia. *Cancer Genet Cytogenet* 2002;132:133-5.
7. Huang L, Abruzzo LV, Valbuena JR, Medeiros LJ, Lin P. Acute myeloid leukemia associated with variant t(8;21) detected by conventional and molecular studies. *Am J Clin Pathol* 2006;125:267-72.
8. Haslo HH, Sashida G, Kodama A, Fukutake K, Ohyashiki. Variant translocation t(2;21;8)(q36;q22;q22) with RUNX1/CBFA2T1 (AML1/ETO) transcript in a case of acute myelogenous leukemia. *Cancer Genet Cytogenet* 2005;159:96-7.
9. Zhang Y, Emmanuel N, Kamboja G, Chen J, Shurafa M, Van Dyke D, *et al.* PRDX4 a member of the peroxiredoxin family is used to AML1 (RUNX1) in an acute myeloid leukemia patient with t(X;21)(p22;q22) translocation. *Genes Chromosomes Cancer* 2004;40:365-70.
10. Holmes RI, Keating MJ, Cork A, Trujillo JM, McCredie KB, Freireich EJ. Loss of the Y chromosome in acute myelogenous leukemia: A report of 13 patients. *Cancer Genet Cytogenet* 1985;17:269-78.

**Source of Support:** Nil, **Conflict of Interest:** None declared.