

Neoadjuvant chemotherapy followed by surgical cytoreduction in advanced epithelial ovarian cancer

Deo SVS, Goyal Hemant, Shukla NK, Raina V*, Kumar Lalit*, Srinivas G

Departments of Surgical Oncology and *Medical Oncology, Institute Rotary Cancer Hospital, All India Institute of Medical Sciences, New Delhi, India

Correspondence to: Dr. SVS Deo, E-mail: svsdeo@yahoo.co.in

Abstract

AIMS: To study the role of neoadjuvant chemotherapy (NACT) followed by surgical cytoreduction in the management of advanced epithelial ovarian cancers. **MATERIALS AND METHODS:** A retrospective analysis of 82 patients with advanced epithelial ovarian cancers (stage IIIC and IV) who were treated with NACT followed by surgical cytoreduction between 1995 and 2004 was performed. Response to NACT, optimal cytoreduction rate, disease-free survival and overall survival were analyzed. **RESULTS:** There were 59 patients (72%) with stage IIIC disease and 23 (28%) with stage IV disease. Diagnosis was established by imaging, ascitic fluid cytology and CA-125 estimations in 75% and by laparotomy in 25% of the patients. After NACT, complete response occurred in 17 patients (20.7%), 50 (61.0%) had partial response and no response was documented in 15 (18.3%) patients. Optimal surgical cytoreduction could be achieved in 72% of the patients. At the median follow-up of 34 months (range 6-102 months), 5-year disease-free and overall survivals were 31 and 32% respectively. The median disease free interval was 25.4 months. On multivariate analysis, degree of optimal cytoreduction was the only factor ($P < 0.05$) affecting survival. **CONCLUSIONS:** NACT followed by surgical cytoreduction is a promising treatment strategy for the management of advanced epithelial ovarian cancers. A significant number of patients exhibit response to NACT. Downstaging following NACT leads to higher optimal cytoreduction rates and improved survival in comparison to historical controls.

Key words: Advanced ovarian cancer, neoadjuvant chemotherapy, surgical cytoreduction

Introduction

Ovarian cancer is the fifth most common cancer among women with a lifetime risk of about 1 in 70. Ovarian cancer ranks fourth in cancer deaths among women, accounting for more deaths than any other cancer of the female reproductive system.^[1-4] Due to nonspecific symptoms, diagnosis is frequently delayed and nearly 70% have advanced disease (stage III or IV) at the time of presentation.^[5] Advanced ovarian cancer is a disease associated with poor prognosis, with the 5-year survival ranging from 5-25%.^[2,5-7] The standard management of advanced disease has so far been surgical staging and debulking followed by adjuvant

chemotherapy.^[8] Optimal cytoreduction during initial surgery is an important prognostic indicator, resulting in survival advantage to optimally cytoreduced patients.^[9,10] However, optimal cytoreduction is feasible in only 40-50% of patients with advanced ovarian cancer.^[11,12] Ovarian cancer is a chemo-sensitive tumor and majority of the patients receive adjuvant chemotherapy. Recently, neoadjuvant chemotherapy (NACT) has been advocated for patients with advanced ovarian cancer with an aim to improve resectability rates and survival.^[13-16] Till now there are no definite guidelines regarding the role of NACT in advanced ovarian cancer. In this study, we have reviewed our experience of neoadjuvant chemotherapy followed by surgical cytoreduction in 82

patients with advanced epithelial ovarian cancer.

Materials and Methods

A retrospective analysis of a prospective ovarian cancer database of the Department of Surgical Oncology was performed. Eighty-two patients with advanced epithelial ovarian cancers treated with NACT followed by surgical cytoreduction between 1995 and 2004 were included in the analysis. All patients with Stage IV disease and stage IIIC with large volume ascites (>500 ml), extensive peritoneal disease not amenable for optimal cytoreduction and patients considered unresectable by the treating surgical team were subjected to NACT followed by surgical cytoreduction after obtaining an informed consent. Patients who had significant primary surgical cytoreduction (any cytoreductive procedure other than exploratory laparotomy and biopsy) elsewhere were excluded from the study. Diagnosis was established by CECT of the abdomen, ascitic fluid cytology and CA-125 estimation in 61 patients (75%) and by laparotomy in 21 (25%) patients. Radiological criteria as described in earlier studies^[14,17,18] for staging advanced disease - presence of large (>5 cm) omental caking, diffuse peritoneal deposits, large volume ascites, large abdominal mass (>5 cm) and contiguous organ involvement-were followed. After obtaining an informed consent, patients were subjected to NACT followed by surgical cytoreduction. NACT comprised of 3-5 (mean 4) cycles of platinum-based chemotherapy during initial phase and taxane-based chemotherapy during the later phase of the study. Fifty-two patients (65.7%) received CAP regime (cisplatin 50 mg/m², adriamycin 50 mg/m² and cyclophosphamide 500 mg/m²) I.V. three weekly cycles and the remaining 30 patients (34.3%) received PC regime (paclitaxel 175 mg/m² and carboplatin 300 mg/m²) I.V. three weekly injections. In the initial part of study patients received CAP regimen while in the latter part, majority of the patients received PC regimen.

Response to NACT was assessed clinically, radiologically and by CA-125 estimations. Thereafter, patients underwent surgical cytoreduction. Standard surgical procedure involved peritoneal washings, total abdominal hysterectomy, bilateral salpingo-oophorectomy, total omentectomy and peritoneal biopsies. An attempt was made to achieve maximal surgical cytoreduction. Optimal cytoreduction was defined for this study purpose as residual disease less than 1 cm in the largest diameter.^[9] Extended resections including gut resections were performed if their removal resulted in optimal surgical cytoreduction. Only retroperitoneal nodal sampling was done and no formal retroperitoneal lymph node dissection was performed. All patients were

subjected to three cycles of postoperative adjuvant chemotherapy with the same agents used for NACT and in the same dosages except in cases of poor response, when alternative chemotherapeutic agents were used based on the treating physician's preference. At the completion of adjuvant chemotherapy, patients were again reassessed clinically, radiologically and by CA-125 estimations to determine the disease status at the completion of treatment. Patients with residual / progressive disease were offered second-line chemotherapy. Patients were kept on regular follow-up. Follow-up evaluations included history and clinical examination every 3 months and CA-125 and CT scan every 6 months.

An analysis of patient and disease profiles, response to NACT, optimal surgical cytoreduction rates and disease-free and overall survival was performed. Univariate and multivariate analyses of factors affecting survival were performed using Cox regression. Kaplan Meier method was used for survival analysis. SPSS 10.0 was used as statistical tool for the study.

Results

Totally there were 82 patients with a mean age of 49.9 years (range 32-72 years). Fifty-nine patients (72%) had stage IIIC and 23 patients (28%) had stage IV disease (pleural effusion). Twenty-seven (32.9%) patients were premenopausal, while the rest were postmenopausal. The median duration of symptoms was 3 months (range 0.5-12 months). Grade I-III gastrointestinal and hematological toxicities occurred in 40% patients, while no patient had grade IV toxicity. The overall response to NACT was 81.7%. Seventeen patients (20.7%) had complete response and 50 (61.0%) had partial response and no response was documented in 15 (18.3%) patients.

Optimal surgical cytoreduction could be achieved in 59 out of 82 patients (72%). Fifteen patients (18.2%) had suboptimal surgical cytoreduction and in 8 (9.8%) patients exploratory laparotomy and closure was performed in view of frozen pelvis. Gut resection was required in only 6 (7.3%) patients (large bowel - 3; small bowel - 3). Mean hospital stay was 4 days (range 2-30 days). Postoperative complications occurred in 4 patients (4.9%) - in the form of wound infections in 3 and pancreatic fistula in 1 patient. After completion of postoperative adjuvant chemotherapy, 61 patients (74.4%) attained disease-free status, while 21 patients (25.6%) had residual disease and were switched over to second-line chemotherapy. At a median follow-up of 34 months (range 6-102 months), 5-year disease-free and overall survival were

31 and 32% respectively [Figures 1 and 2]. The median disease-free interval was 25.4 months. Univariate analysis for survival identified response to NACT, degree of surgical cytoreduction and disease status at completion of treatment as significant factors. Other factors like age, stage of disease, menopausal status, type of chemotherapy received did not influence survival. On multivariate analysis, only degree of optimal surgical cytoreduction emerged as an independent prognostic factor for survival. The median survival in patients with optimal cytoreduction was 41.4 months (C.I. 26.3-56.4 months) while that in patients without optimal cytoreduction was 26.2 months (C.I. 18.7-33.7 months) ($P=0.02$).

Discussion

Advanced epithelial ovarian cancer continues to be a disease with bad prognosis and high mortality.^[2,5-7] The standard management of advanced ovarian cancer is

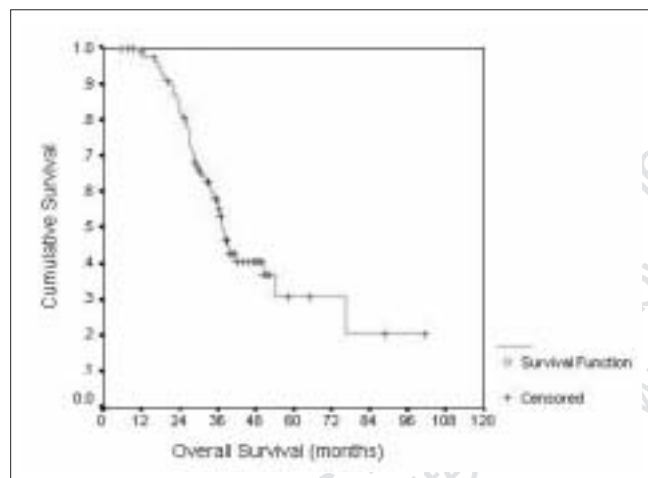


Figure 1: Overall survival after neoadjuvant chemotherapy and secondary surgical cytoreduction in advanced ovarian cancers

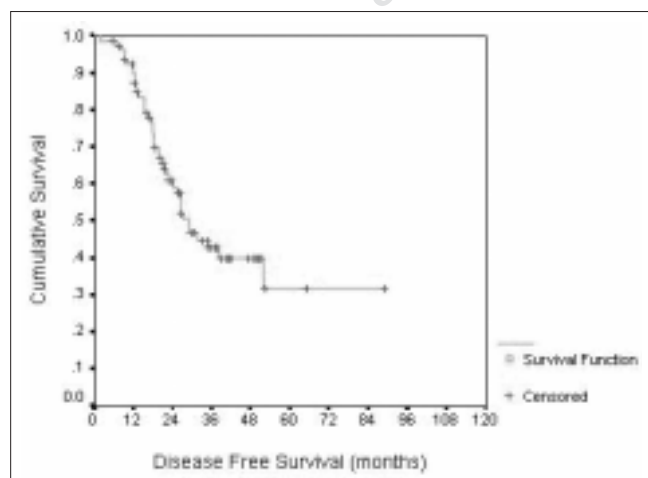


Figure 2: Disease-free survival after neoadjuvant chemotherapy and secondary surgical cytoreduction in advanced ovarian cancers

surgical debulking followed by adjuvant chemotherapy.^[8] Prognosis largely depends upon the degree of cytoreduction achieved during primary surgery. Gross residual disease more than 2 cm carries poor prognosis, as shown in the meta-analysis by Bristow *et al.*^[9,10] Most people today accept optimal cytoreduction as residual tumor volume of <1 cm or even <0.5 cm. However, due to bulky disease in advanced ovarian cancer, optimal cytoreduction is possible in only 40 to 50% of the patients.^[11,12] Hence efforts are being made to increase the optimal surgical cytoreduction rates in order to improve survival. NACT is emerging as an effective treatment modality in many locally advanced solid tumors, including breast, gastrointestinal and bone and soft tissue tumors. The rationale behind NACT protocol is to make inoperable advanced disease operable, increase R0 resection rates and facilitate organ conservation. Since ovarian cancer is a chemo-sensitive disease where effective chemotherapeutic agents like platinum and taxane group of drugs are available, conceptually, the use of neoadjuvant chemotherapy may decrease the tumor burden and allow a higher optimal surgical cytoreduction rate and an improvement in overall survival.

Since the staging of ovarian cancer is essentially surgical, selection of locally advanced disease for neoadjuvant protocols becomes difficult. Many studies have shown good correlation between radiological and surgical staging, especially in advanced disease.^[19,20] Qayyum *et al.*^[21] have shown a positive predictive value of 94% using CT scan for suboptimal cytoreduction in advanced ovarian cancer. CT scan was used in the current study for staging advanced ovarian cancer in majority of the patients and laparotomy was required for diagnosis and staging only in 25% of patients.

Ovarian cancer is a chemo-sensitive disease and a number of cytotoxic agents have activity against it. They include the platinum compounds, the alkylating agents, the anthracyclines, paclitaxel oral etoposide, topotecan, gemcitabine, navelbine, doxil and hexamethylmelamine.^[22] A number of trials^[23-25] have compared platinum-containing combinations to nonplatinum-containing regimens and have found them to be superior. Recently, a prospective randomized trial by GOG^[26] comparing 'cisplatin plus cyclophosphamide' with 'cisplatin plus paclitaxel' showed a significantly higher response rate in the paclitaxel group and established 'platinum plus taxane' based chemotherapy as the preferred adjuvant treatment in advanced ovarian cancer.

Good overall response rate using platinum and taxane based chemotherapy in suboptimally cytoreduced

patients^[26] sparked an interest in neoadjuvant chemotherapy in advanced ovarian cancers. Initial reports of NACT in advanced ovarian cancers have reported a response rate of 70-80%^[13,15,16] and an acceptable toxicity profile.^[27,28]

In our study, all patients could complete planned NACT with acceptable toxicity profile. Eighty-one percent of patients showed an objective response to NACT, with 20% patients having complete clinical and radiological response and 61% patients showing partial response.

Primary surgical cytoreduction in advanced ovarian cancer leads to an optimal cytoreduction in only 40 to 50% of patients.^[11,12] Since the amount of residual disease is the most important prognostic factor, every effort should be made to increase the optimal cytoreduction rate. NACT followed by surgical cytoreduction is one such approach. Many authors have reported an optimal cytoreduction rate of 60-75% following NACT in nonrandomized trials.^[13-16] In our study, optimal cytoreduction rate was 72%, which is similar to that reported in the literature using NACT. The surgical cytoreduction was 100% in patients with clinical and radiological complete response, 84% in patients with partial response and 0% in patients with no response to NACT. Hence response to NACT may also predict the degree of surgical cytoreduction likely to be achieved. In addition, NACT may provide an *in vivo* assessment of the chemo-sensitivity of the tumor.

Primary surgery in advanced ovarian cancers is associated with significant morbidity and prolonged hospital stay due to presence of large volume ascites, high tumor burden and involvement of adjacent pelvic organs.^[28] NACT followed by surgical cytoreduction has many theoretical advantages in this kind of disease spectrum, including a dry operative field (due to resolution/decrease in ascites), decreased tumor burden, better operative planes with adjacent viscera leading to less extensive resections and high optimal cytoreduction rates. All these factors can contribute to a decreased postoperative morbidity and hospital stay and improve the patients' ability to tolerate postoperative adjuvant chemotherapy. Maurice *et al* have shown the rates of bowel resection, large peritoneal resection and postoperative morbidity were significantly reduced in the NACT group as compared to primary surgery.^[29] In our study, postoperative complications occurred in four patients (4.9%) - in the form of wound infections in three and pancreatic fistula in one patient. The mean duration of hospital stay in our study was 4 days. In the current study, 72% of patients achieved optimal surgical cytoreduction following NACT in comparison to the 40 to 50% optimal surgical cytoreduction rates

reported in literature^[11,12] in patients without NACT.

Extended resections, including that of rectum, small bowel, colon or urinary bladder, may sometimes require maximal cytoreduction in advanced ovarian cancer. However, the utility of extended resections has been questioned by many authors.^[30,31] In our series of 82 patients with advanced ovarian cancers, only 6 patients required segmental bowel resections (3 - large bowel; 3 - small bowel) for optimal cytoreduction. We undertook bowel resections only if it were to lead to optimal cytoreduction.

Survival in advanced ovarian cancers treated with primary cytoreduction followed by adjuvant chemotherapy ranges from 5 to 25%.^[2,5-7] Studies using NACT may lead to an improvement in overall and progression-free survival, as indicated in early reports from EORTC trial.^[32] Overall 5-year survival in the current study was 32% with a median disease-free interval of 25.4 months, which is comparable to the survival figures quoted by other investigators using NACT.^[13,15,16,32,33]

As far as the factors affecting survival in advanced ovarian cancer, many studies have consistently shown amount of residual disease to be a significant prognostic factor.^[9,10] Multivariate analysis of factors affecting survival in the current study has shown that the degree of cytoreduction was the only factor affecting overall survival. Survival was significantly better in patients who had optimal cytoreduction compared to those who could not be optimally cytoreduced ($P < 0.05$). Presence of malignant pleural effusion has been cited as a bad prognostic factor in many studies.^[34,35] The patient population in this study included nearly 25% patients with metastatic disease in the form of cytologically proven pleural effusion. Response to NACT, surgical cytoreduction and overall survival were no different in this group compared to those with stage IIIC disease, contrary to the reports published^[34,35] showing an inferior survival in patients with pleural effusion. However, larger studies are needed to further elucidate this aspect of ovarian cancer.

Conclusion

The results of the current study show that NACT is a feasible and promising approach in advanced ovarian cancer. A significant number of patients respond to NACT leading to a higher optimal surgical cytoreduction, which may result in improved survival. Till the long-term results of the randomized trials (EORTC 55971 and MRC-CHORUS study) are available, surgery followed by chemotherapy will remain

as the standard of care for managing advanced ovarian cancers.

References

- Landis SH, Murray T, Bolden S, Wingo PA. Cancer statistics, 1999. *CA Cancer J Clin* 1999;49:8-31.
- Yeole BB, Kumar AV, Kurkure A, Sunny L. Population-based survival from cancers of breast, cervix and ovary in women in Mumbai, India. *Asian Pac J Cancer Prev* 2004;5:308-15.
- Bray F, Loos AH, Tognazzo S, La Vecchia C. Ovarian cancer in Europe: Cross-sectional trends in incidence and mortality in 28 countries, 1953-2000. *Int J Cancer* 2005;113:977-90.
- Quirk JT, Natarajan N. Ovarian cancer incidence in the United States, 1992-1999. *Gynecol Oncol* 2005;97:519-23.
- Ozols RF, Schwartz PE, Eifel PJ. Ovarian Cancer, Fallopian Tube Carcinoma and Peritoneal Carcinoma. *In: DeVita VT Jr, Hellman S, Rosenberg SA, Editors. Cancer: Principles and practice of oncology, 6th ed. Williams and Wilkins: Lippincott; 2001. p. 1597-632.*
- Holschneider CH, Berek JS. Ovarian cancer: Epidemiology, biology and prognostic factors. *Semin Surg Oncol* 2000;19:3-10.
- Beard CM, Hartmann LC, Atkinson EJ, O'Brien GD, Malkasian GD, Keeney GL, et al. The epidemiology of ovarian cancer: A population-based study in Olmsted County, Minnesota, 1935-1991. *Ann Epidemiol* 2000;10:14-23.
- Hoskins WJ. Surgical staging and cytoreductive surgery of epithelial ovarian cancer. *Cancer* 1993;71:1534-40.
- Hoskins WJ, McGuire WP, Brady MF, Homesley HD, Creasman WT, Berman M, et al. The effect of diameter of largest residual disease on survival after primary cytoreductive surgery in patients with suboptimal residual epithelial ovarian carcinoma. *Am J Obstet Gynecol* 1994;170:974-80.
- Bristow RE, Tomacruz RS, Armstrong DK, Trimble EL, Montz FL. Survival effect of maximal cytoreductive surgery for advanced ovarian carcinoma during the platinum era: A meta-analysis. *J Clin Oncol* 2002;20:1248-59.
- van der Burg ME. Advanced ovarian cancer. *Curr Treat Options Oncol* 2001;2:109-18.
- Fioretti P, Gadducci A, Del Bravo B, Prato B. The potential of primary cytoreductive surgery in patients with FIGO stages III and IV ovarian carcinoma. *Eur J Gynaecol Oncol* 1990;11:175-9.
- Mazzeo F, Berliere M, Kerger J, Squifflet J, Duck L, D'Hondt V, et al. Neoadjuvant chemotherapy followed by surgery and adjuvant chemotherapy in patients with primarily unresectable, advanced-stage ovarian cancer. *Gynecol Oncol* 2003;90:163-9.
- van der Burg ME, van Lent M, Buyse M, Kobierska A, Colombo N, Favelli G, et al. The effect of debulking surgery after induction chemotherapy on the prognosis in advanced epithelial ovarian cancer. Gynecological cancer cooperative group of the European organization for research and treatment of cancer. *N Engl J Med* 1995;332:629-34.
- Pectasides D, Farmakis D, Koumariou A. The role of neoadjuvant chemotherapy in the treatment of advanced ovarian cancer. *Oncology* 2005;68:64-70.
- Vergote I, De Wever I, Tjalma W, Van Grambaren M, Decloit J, van Dam P. Neoadjuvant chemotherapy or primary debulking surgery in advanced ovarian carcinoma: A retrospective analysis of 285 patients. *Gynecol Oncol* 1998;71:431-6.
- Dowdy SC, Mullany SA, Brandt KR, Huppert BJ, Cliby WA. The utility of computed tomography scans in predicting suboptimal cytoreductive surgery in women with advanced ovarian carcinoma. *Cancer* 2004;101:346-52.
- Forstner R, Hricak H, Occhipinti KA, Powell CB, Frankel SD, Stern JL. Ovarian cancer: Staging with CT and MR imaging. *Radiology* 1995;197:619-26.
- Kawamoto S, Urban BA, Fishman EK. CT of epithelial ovarian tumors. *Radiographics* 1999;19:S85-102.
- Nelson BE, Rosenfield AT, Schwartz PE. Preoperative abdominopelvic computed tomographic prediction of optimal cytoreduction in epithelial ovarian carcinoma. *J Clin Oncol* 1993;11:166-72.
- Qayyum A, Coakley FV, Westphalen AC, Hricak H, Okuno WT, Powell B. Role of CT and MR imaging in predicting optimal cytoreduction of newly diagnosed primary epithelial ovarian cancer. *Gynecol Oncol* 2005;96:301-6.
- James Tate Thigpen: Ovaries and fallopian tubes. *In: Abeloff MD, Armitage JO, Lichter AS, Niederhuber JE, Editors. 2nd ed. Clinical Oncology: Churchill Livingstone; 2000. p. 2020-35.*
- Decker DG, Fleming TR, Malkasian GD Jr, Webb MJ, Jeffries JA, Edmonson JH. Cyclophosphamide plus CIS-platinum in combination: Treatment program for stage III or IV ovarian carcinoma. *Obstet Gynecol* 1982;60:481-7.
- Neijt JP, ten Bokkel Huinink WW, van der Burg ME, van Oosterom AT, Vriesendorp R, Kooymans CD, et al. Randomized trial comparing two combination chemotherapy regimens (Hexa-CAF vs CHAP-5) in advanced ovarian carcinoma. *Lancet* 1984;2:594-600.
- Omura GA, Bundy BN, Berek JS, Curry S, Delgado G, Mortel R. Randomized trial of cyclophosphamide plus cisplatin with or without doxorubicin in ovarian carcinoma: A gynecologic oncology group study. *J Clin Oncol* 1989;7:457-65.
- McGuire WP, Hoskins WJ, Brady MF, Kucera PR, Partridge EE, Look KY, et al. Cyclophosphamide and cisplatin compared with paclitaxel and cisplatin in patients with stage III and stage IV ovarian cancer. *N Engl J Med* 1996;334:1-6.
- Kjorstad K, Harris A, Bertelsen K, Slevin M, Shultz H, Hellman K, et al. A multicenter phase II study of carboplatin in advanced ovarian carcinoma: Final report. *Ann Oncol* 1992;3:217-22.
- Einzig AI, Wiernik PH, Sasloff J, Runowicz CD, Goldberg GL. Phase II study and long-term follow-up of patients treated with taxol for advanced ovarian adenocarcinoma. *J Clin Oncol* 1992;10:1748-53.
- Morice P, Dubernard G, Rey A, Atallah D, Pautier P, Pomel C, et al. Results of interval debulking surgery compared with primary debulking surgery in advanced stage ovarian cancer. *J Am Coll Surg* 2003;197:955-63.
- Guidozzi F, Ball JH. Extensive primary cytoreductive surgery for advanced epithelial ovarian cancer. *Gynecol Oncol* 1994;53:326-30.
- Gillette-Cloven N, Burger RA, Monk BJ, McMeeken DS, Vasilev S, DiSaia PJ, et al. Bowel resection at the time of primary cytoreduction for epithelial ovarian cancer. *J Am Coll Surg* 2001;193:626-32.
- van der Burg ME, Vergote I; Gynecological Cancer Group of the EORTC. The role of interval debulking surgery in ovarian cancer. *Curr Oncol Rep* 2003;5:473-81.
- Kuhn W, Rutke S, Spathe K, Schmalfeldt B, Florack G, von Hundelshausen B, et al. Neoadjuvant chemotherapy followed by tumor debulking prolongs survival for patients with poor prognosis in International Federation of Gynecology and Obstetrics Stage IIIC ovarian carcinoma. *Cancer* 2001;92:2585-91.
- Eitan R, Levine DA, Abu-Rustum N, Sonoda Y, Huh JN, Franklin CC, et al. The clinical significance of malignant pleural effusions in patients with optimally debulked ovarian carcinoma. *Cancer* 2005;103:1397-401.
- Goodman HM, Harlow BL, Sheets EE, Mooto MG, Brooks S, Stellar M, et al. The role of cytoreductive surgery in the management of stage IV epithelial ovarian carcinoma. *Gynecol Oncol* 1992;46:367-71.

Source of Support: Nil, **Conflict of Interest:** None declared.