

Attili VSS, Rama Chandra C*, Dadhich HK, Sahoo TP, Anupama G, Bapsy PP

Departments of Medical Oncology and *Surgical Oncology, Kidwai Memorial Institute of Oncology, Bangalore, Karnataka, India

Correspondence to: Dr. AVS Suresh, E-mail: sureshattili@yahoo.com

Abstract

Metastasis from colorectal carcinoma occurs by either lymphatic or hematogenous spread. The most common sites of colorectal metastasis are the liver and lung. Involvement of the skin, muscles and bones are quite rare. The prognosis in such patients is usually poor. Herewith, we are reporting a case of colonic carcinoma who had cutaneous metastasis, muscular involvement and diffuse skeletal metastasis. At the end, she had brain metastasis, but liver and lung involvement was not observed till the end.

Key words: Cutaneous metastasis, bone metastasis, colorectal carcinoma.

Metastatic spread from colonic carcinoma (ca. colon) is quite predictable, initially by lymphatics, followed by the hematogenous route. The commonest sites for distant metastasis, are liver and lung. Occasional case reports of cutaneous,^[1] skeletal,^[2] muscular^[3] and other organ metastases were described.

The present case is unusual in 4 distinct aspects:

- The patient had cutaneous metastasis at presentation.
- She had muscular involvement along with diffuse skeletal metastasis, which is rare.
- Despite brain metastasis, liver and lung were spared.
- The disease had a very rapid course and interval between the various organ involvements was short.

Case Report

A 35 years old female presented with complaints of a rapidly growing mass over the filtrum of upper lip, bleeding per rectum and constipation for 25 days. She denied any history of associated systemic complaints. Past history and family history did not contribute any further information. On examination, positive findings were a hard mass measuring 1.8 x 1.6 cm with irregular surface and margins over the filtrum of upper lip [Figure 1] and per rectal examination revealing a hard mass 8 cms from the anal verge. The rest of the systemic examination was within normal limits. The hematological and biochemical parameters were normal.

Computer tomography (CT) thorax, was normal at presentation. Ultrasound abdomen showed a pelvic mass arising from the colon, along with a small suspicious mass over the left ovary. Colonoscopy revealed a large recto sigmoid mass at 10 cms from the anal verge and multiple polyps in the sigmoid and descending colon. The patient was planned for laparotomy. Intraoperatively, a huge mass in the rectosigmoid region, fixed to the pelvic wall, with deposits over both ovaries was observed and the liver appeared grossly normal. The patient underwent left ovariectomy (because the left ovary was adherent to the

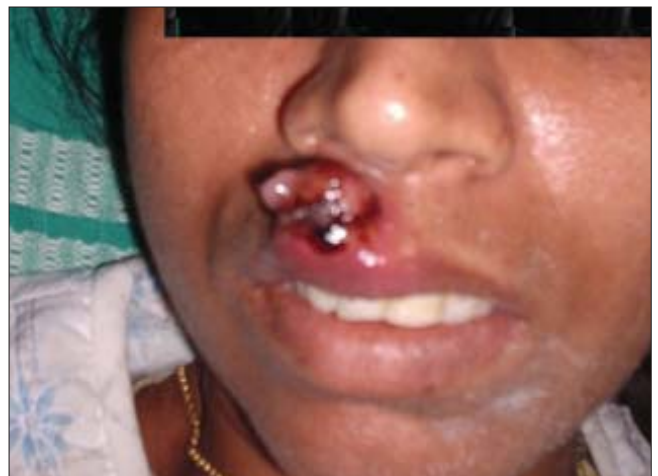

Figure 1: Lip metastasis in colorectal carcinoma.

colon causing obstruction and impending erosion to the nearing vessels) and palliative transverse colostomy, with incisional biopsy from lip. Histopathological features were consistent with adenocarcinoma, both from lip as well as colon.

Post-operatively, on day 25, the patient developed severe pain in the right upper limb. On examination, there was a hard mass over the right deltoid region, extending up to scapular region. CT scan showed a mass involving teres muscles, glenoid capsule, scapula and humerus. Bone scan revealed multiple skeletal metastases. The patient was planned for palliative chemotherapy with 5FU + leucovorin. After 6 weeks of chemotherapy, the lip lesion regressed in size and the patient's general condition improved. However she developed seizures at this point. All over the brain parenchyma, multiple enhancing lesions were noted in CT scan cranium [Figure 2]. Further chemotherapy was deferred, owing to progressive disease.

Discussion

Cutaneous metastasis

At presentation, less than 6.4% of all patients with malignancy had cutaneous concurrent metastasis.^[1] In colon cancers, it usually occurs after identification of the primary tumour, although a few cases of synchronous presentation are known.^[2] The most frequent sites of cutaneous metastasis from Ca. colon are, abdomen followed by extremities, perineum, head and neck and penis.^[4] If tumour cells invade vessels, they present as cutaneous metastasis at distant sites, while if they involve lymphatics, late local recurrence at a primary site is common. Presence of cutaneous metastasis, typically signifies widespread disease with median survival of 3 months, after the detection of metastasis.^[5]

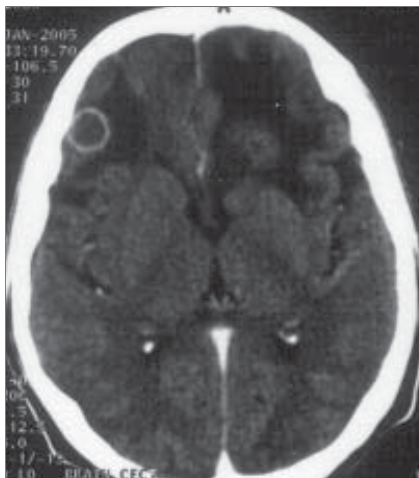


Figure 2: Ct cranium in patient of colorectal carcinoma showing metastasis.

Few patients with cutaneous metastasis had surprisingly long term survival up to 18 months or more. But after carefully reviewing the long term survivals, it was observed that they had either long disease-free interval, or had long history of malignancy, indicating slow growing tumor. In most of the patients where cutaneous metastasis is isolated without visceral involvement, the removal of the metastatic site offered considerable survival. In the rest of the cases wherein cutaneous metastasis was a part of the widespread disease, the disease free interval is small and in most of them it is less than 3 months.

Musculo-skeletal involvement

Incidence of colon carcinoma metastasizing to skeletal muscle is quite rare, with only 8 case reports till 2000.^[3] Such rarity is attributed to anatomical and biochemical microenvironment in muscle, which hardly supports growth of malignant cells.^[3] Due to less number of case reports, it is difficult to characterize the histological pattern of tumour cells invading muscles and the survival. Skeletal metastasis is also quite uncommon and is usually a late manifestation of Ca colon. The reported frequency is less than 1.3% of all bony metastasis.^[6]

Brain metastasis bypassing lung and liver

The common route of CNS involvement is via portal vein - liver-heart - lung - carotid - brain and very rarely both liver and lung have escaped.^[7] A few case reports exist for isolated brain metastasis, with Ishuara *et al.* reporting largest series of 11 such patients.^[8] He explained them on the basis of micro-metastasis to liver. However, till 1999 only a single case of Ca. colon with cerebellar metastasis was reported, wherein lung and liver were spared.^[8] In the present case also, the patient had cerebellar involvement, making it probably the second case.

Micro-metastasis

The imaging techniques (spiral CT/Magnetic resonance imaging) usually pick up lesions exceeding 0.5 to 1 cms, in cases of visceral metastasis. We do not feel that Positron emission tomography (PET) scan would have added to this, as liver is usually a hot area on normal PET scan. So in the present case, we assume that the patient had micro-metastasis.

Treatment

From available evidence, it is known that patients with disseminated colorectal cancer fare poorly and the same was observed in the present case. We acknowledge the fact that the regimen used here, cannot be considered the standard of care. Combination chemotherapy with 5

fluorouracil, leucovorin, irinotecan and bevacuzimab, have shown the longest progression free survival (PFS).^[9] If treated with this combination, a longer PFS could have been possible.

In conclusion, although local lymph nodes, liver and lungs, are the common and initial sites of spread from colorectal cancers, disseminated metastasis with sparing of these organs is unlikely, but possible. Combination chemotherapy as mentioned, might be the ideal regimen, although the prognosis remains dismal.

References

1. Lookingbill DP, Spauler N, Helm KF. Cutaneous metastases in patients with metastatic carcinoma: A retrospective analysis of 4020 patients. *J Am Acad Dermat* 1993;29:228-36.
2. Camci C, Turk HM, Buyukberber S, Karakok M, Koruk M, Beyazity Y, *et al.* Colon carcinoma with synchronous subcutaneous and osseous metastasis: A case report. *J Dermatol* 2002;29:362-5.
3. Hasegawa S, Sakurai Y, Imazu H, Matsubara T, Ochiai M, Funabiki T, *et al.* Metastasis to the forearm skeletal muscle from an adenocarcinoma of the colon: Report of a case. *Surg Today* 2000;30:1118-23.
4. Stavrianos SD, McLean NR, Kelly CG, Fellows S. Cutaneous metastasis to the head and neck from colonic carcinoma. *Eur J Surg Oncol* 2000;26:518-9.
5. Sarid D, Wigler N, Gutkin Z, Merimsky O, Leider-Trejo L, Ron IG. Cutaneous and subcutaneous metastases of rectal cancer. *Int J Clin Oncol* 2004;9:202-5.
6. Oh YK, Park HC, Kim YS. Atypical bone metastasis and radiation changes in a colon cancer: A case report and review of the literature. *Jpn J Clin oncol* 2001;31:168-71.
7. Garg PK, Bohidar NP, Sharma MP, Mohapatra AK, Saha A, Pande GK. Isolated cerebellar metastasis from carcinoma of the colon. *Postgrad Med J* 1999;75:119-21.
8. Ishikura A, Hunaki N, Watanabe K. Brain metastases of colorectal cancer- a case report. *Gan No Rinsho* 1987;33:188-92.
9. Allegra C, Sargent DJ. Adjuvant Therapy for Colon Cancer- The Pace Quickens: Editorial *N Eng J Med* 2005;352:2746-8.

Advertisement

X National Pediatric Haematology-Oncology Conference (PHOCON - 2006)

Vellore, November 16th -18th, 2006

Enquiries to:

Dr. Leni Mathew

Organising Secretary

Child Health Unit I

CMC Hospital

Vellore - 632 004, Tamil Nadu

E-mail: lenimathew@cmcvellore.ac.in

Ph: 91-416-2283350/Fax: 91-416-2232103/2232035