

Giant cystosarcoma phyllodes tumor of prostate: Case report of a rare entity

Bhat DM, Poflee SV, Kotwal MN, Pangarkar MA, Gadkari RU, Bobhate SK

Department of Pathology, Government Medical College, Nagpur, India.

Correspondence to: Dr. Dharitri M. Bhat, E-mail: rasikaug@nagpur.dot.in

Abstract

Although glandular and stromal proliferations of prostate are very common in adult men, neoplastic proliferations of prostatic stroma are distinctly uncommon. These tumors are now grouped as Prostatic Stromal Proliferations of Uncertain Malignant Potential (PSPUMP). Phyllodes tumor of the prostate is a rare neoplasm in this group with cellular, sarcomatoid stroma and benign hyperplastic glands. It is a locally expansile tumor with clinical course varying from benign to aggressive. We report a case of a 45-year-old man presented with retention of urine and abdominal lump. On laparotomy it was a huge tumor of 4 kg and was histologically characterized by cellular pleomorphic stroma and hyperplastic epithelium. Immunohistochemistry demonstrated prostate specific antigen in the glands. It was diagnosed as cystosarcoma phyllodes tumor of prostate. This is extremely uncommon tumor similar in histology to that of breast and its clinical course varies with the grade. The patient was without recurrence one year after surgery.

Key Words: Cystosarcoma phyllodes tumor of prostate, Prostatic stromal proliferations.

Introduction

In contrast to the common occurrence of benign prostatic hyperplasia and adenocarcinoma, hyperplastic and neoplastic glandular and stromal proliferations in the prostate are extremely uncommon lesions.¹ These tumors are histologically characterized by exuberant proliferation of prostatic stroma with variable number of normal and hyperplastic glands.² They have been designated by a variety of names including Cystadenoleiomyofibroma, prostatic stromal hyperplasia with bizarre nuclei and phyllodes type of atypical prostatic hyperplasia.^{3,4} Recently this group of tumors have been labeled as Prostatic Stromal Proliferations Of Uncertain Malignant Potential (PSPUMP).⁵ Phyllodes tumor of the prostate reflects the end of the spectrum beginning with prostatic stromal hyperplasia and histologically it resembles mammary phyllodes tumor.¹ Yamamoto et al mentioned a case as eleventh reported case of malignant phyllodes tumor of prostate in the world.⁶ The largest reported prostatic tumor was

weighing 11.2 kg. and was diagnosed as Giant cystosarcoma phyllodes (CSP) tumor.² We present a case of unusually large prostatic tumor characterized by hyperplastic glands and pleomorphic stroma without any feature of malignancy. Positive Immunoreactivity for prostate specific antigen (PSA) in the epithelial component confirmed the prostatic origin of this tumor.

Case Report

A 45-year-old male presented with retention of urine, lump in abdomen and alteration of bowel habits since six months. He had no history of hematuria, bleeding per rectum, vomiting or loss of weight. On examination a lump was palpable in lower abdomen occupying almost all quadrants extending upwards. Rectal examination suggested a firm mass encircling rectum with free rectal mucosa. Other systems revealed no significant finding. **Abdominal and Pelvic-CT** showed a huge partially cystic mass in pelvic cavity with extension into abdomen. It was separate from all

visceral organs and was pressing over right urethra with hydronephrotic changes in right kidney. It was heterogeneous in texture with multiple high, attenuating solid areas and many septate lobulated cystic areas. Separate prostate gland was not identified. Radiological impression was a retroperitoneal tumor or a tumor arising from bladder wall.

This large solid - cystic mass was seen to occupy whole of the abdominal cavity; pushing small bowel and transverse colon upwards. It was fixed to bladder wall posteriorly and loosely adherent to rectal wall. Lymph nodes were not enlarged. Rest of the viscera was normal. Enucleation of the whole mass was done and it was sent for histopathological examination. Preoperative serum PSA levels were not done as he was subjected to surgery without any clinical suspicion of a prostatic tumor. Postoperative serum PSA levels were undetectable thus favoring the complete removal of a prostatic tumor. The patient did not receive any chemo/

radiotherapy and was without any evidence of recurrence one year later.

A large irregular mass measuring 30C 25C 10 cm, weighing 4 kg. was received. Cut surface showed multiple solid and cystic areas (Figure 1). The cysts were from few mm to 2-3 cm in diameter and filled with yellowish clear fluid. Solid areas were grayish white in color with no areas of hemorrhage and necrosis. Multiple sections were taken from different areas and were subjected to microscopic examination.

Sections from the tumor showed both stromal and glandular components. The stroma was very cellular and composed of spindle shaped cells with scanty, pale, eosinophilic cytoplasm, and ill-defined margins. The spindle shaped nuclei showed atypia, hyperchromasia and pleomorphism. Many of the nuclei were so bizarre as to suggest a sarcoma (Figure 2). Occasional mitoses were observed. Interspersed in between this stroma

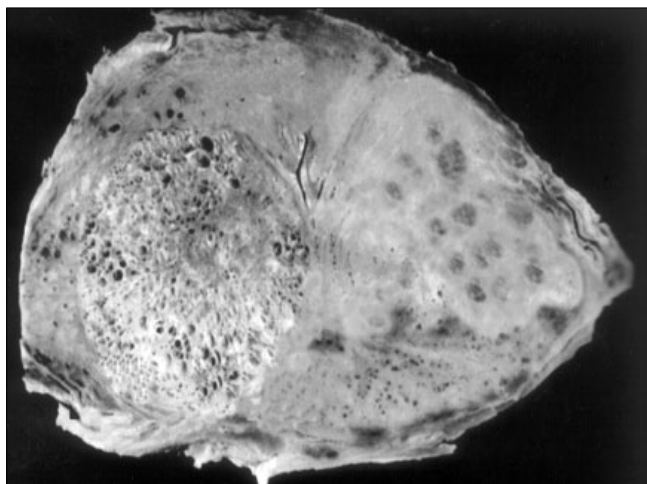


Figure 1: Photograph of cut section of the tumor showing solid and cystic areas




Figure 2: Photomicrograph showing spindle shaped stromal cells with many bizarre nuclei

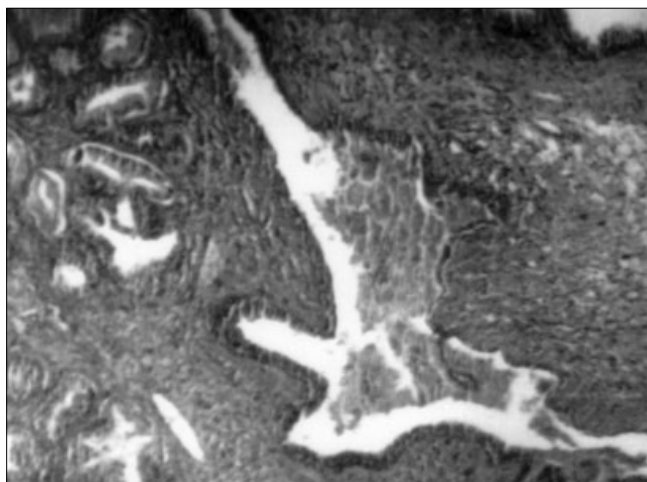


Figure 3: Photomicrograph showing epithelium with cleft like dilated spaces

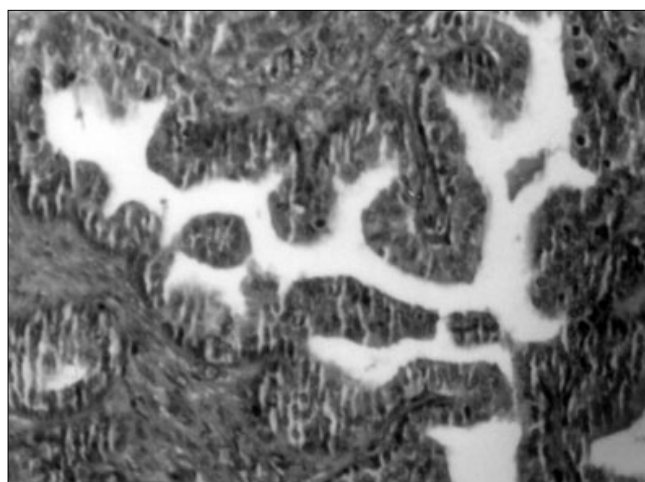


Figure 4: Photomicrograph showing hyperplastic glands with papillary infoldings lined by two layered epithelium

were seen glands of varying sizes. Few glands were cystically dilated while other collapsed or compressed to slit like structures (Figure 3) resembling the phyllodes pattern as seen in breast, whereas many glands were hyperplastic and proliferating showing papillary formations lined clearly by two layered epithelium, the tall columnar and the reserve cell layer (Figure 4). Some glands contained amorphous eosinophilic secretions. More than 75% of the sampled tumor area showed presence of glands in varying proportions. We suspected a prostatic stromal-epithelial tumor, studied special stains (Masson's trichrome) and extensively sampled the tumor from the periphery for further typing.

On studying more sections and reviewing the slides, we noted that in spite of many bizarre, pleomorphic nuclei, mitoses were inconspicuous or occasional. Many nuclei showed nuclear vacuolation, giving a bubbly appearance to it (Figure 5). Some nuclei showed eosinophilic inclusions probably cytoplasmic invaginations. In some foci hyalinised stroma was seen while other places showed loose edematous stroma suggestive of a degenerative change. To confirm the prostatic origin of the tumor immunohistochemistry was done. The glandular element showed positive immunostaining for PSA (Figure 6).

Considering the clinical and radiological, gross and microscopic features of this tumor we diagnosed this tumor as **CSP tumor of prostate**.

Discussion

The proliferations of specialized prostatic stroma has been called by various names including Cystadenoleiomyofibroma, prostatic stromal hyperplasia

with bizarre nuclei and CSP tumor. The later is named due to its histological resemblance to mammary phyllodes tumor. It represents the end of the spectrum beginning with prostatic stromal hyperplasia.^{1,3} All of them are characterized by marked proliferation of stromal-glandular elements in various proportions and variable clinical outcome.⁷ These tumors are grouped in two broad categories, 1) Prostatic stromal Proliferations of Uncertain Malignant Potential (PSPUMP) and 2) Prostatic Stromal Sarcoma (PSS) to help predict biologic behavior and guide therapy. In PSPUMP, four histological patterns are recognized further based on the proportion of glands and stroma with presence of atypia. One of these patterns is reminiscent of phyllodes tumor of breast and is characterized by marked stromal proliferation associated with non-neoplastic glandular elements with variable degree of proliferation. Few cases of PSS also show histological pattern similar to phyllodes tumor of breast.⁵ The prostatic phyllodes tumors are graded from I to III corresponding to benign, borderline and malignant based on the stromal mitotic activity, pleomorphism and necrosis similar to mammary phyllodes tumor.⁸ Tumors composed of cellular stroma with only focal atypia, without pleomorphism, necrosis and mitosis are graded as grade I or benign. They are usually associated with benign clinical course. Tumors with cellular, pleomorphic stroma, with atypia in most of the fields, occasional mitosis (less than one per high power field) and no necrosis are graded as borderline tumors. These tumors may recur or progress. Malignant tumors are diagnosed based on the presence of mitosis (>ten/ten hpf). These tumors show necrosis, marked pleomorphism and are associated with aggressive clinical behaviour.^{9,10} In the present case, though the tumor was expansile, it was not invading adjacent structures, the lymph nodes were not enlarged. Histologically the cellular stroma showed

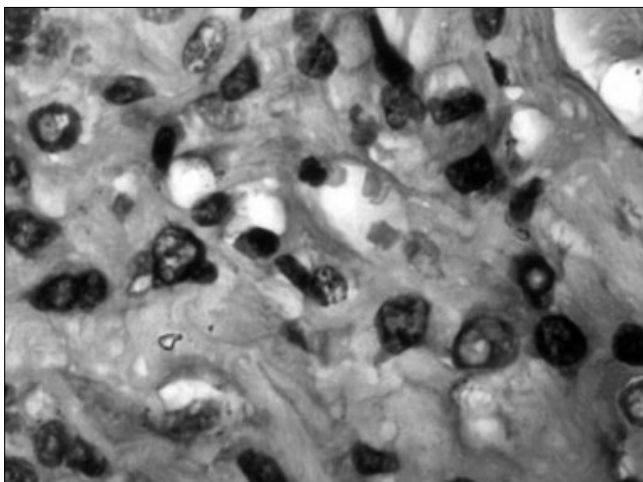


Figure 5: Photomicrograph showing spindle shaped stromal cells with many nuclei showing nuclear vacuolation.

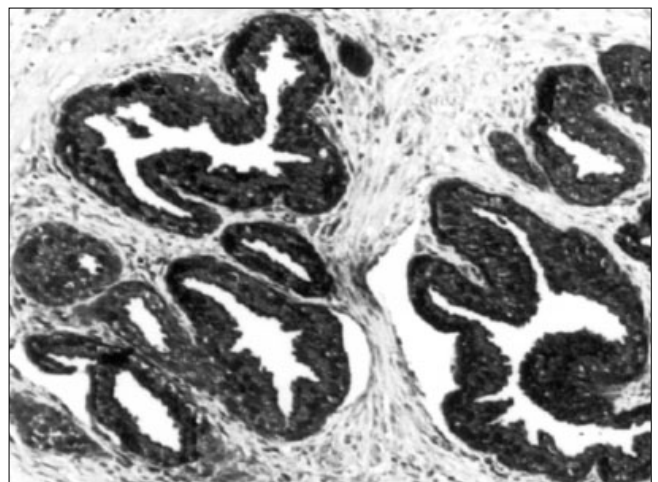


Figure 6: Photomicrograph showing positive immunoreactivity to PSA in the glands

atypia and bizarre nuclei with occasional mitosis (<one/hpf). Necrosis was not seen. Sections from the periphery of the tumor showed degenerative changes. Glandular element was consistently present throughout the tumor with variable histological patterns, many areas resembling phyllodes pattern, Hence we interpreted the the tumor as CSP tumor, borderline or grade II. Postoperative serum PSA levels were undetectable thus indirectly suggesting complete removal of a prostatic tumor. The patient was free of recurrence one year after surgery. Grossly the size of the tumor is greatly variable and not related to grade. The largest mentioned prostatic tumor was 58*34*16 cm weighing 11.2 kg and was diagnosed as a case of Giant CSP of prostate with presence of foci of well differentiated adenocarcinoma.² In present study the tumor was 30*25*10 cm, weighing 4 kg. All the sections showed benign hyperplastic glandular component with focal phyllodes tumor like pattern. No focus of malignancy was seen; neither the stroma showed significant mitotic activity. Extensive sampling, specially from the periphery of the tumor is essential for proper categorization of these tumors.⁶ Radiological features of this tumor exhibit several characteristic findings, thus helping in the preoperative diagnosis.⁴ The nature of PSPUMP is controversial and is considered by some as pseudosarcomatous, hyperplastic or neoplastic. Many of these tumors often recur and few may progress to PSS where as a subset of them neither recurs nor progresses hence these are termed as proliferative rather than neoplastic.⁵ The histogenesis of CSP of the prostate has not been firmly established.⁸

The prostatic origin of the epithelium is demonstrated by positivity for PSA. It can be fibrous or the fibromuscular stroma of the prostate. The specialized prostatic stroma is hormonally responsive hence it is likely that the diverse proliferative and metaplastic changes seen in the epithelial component of these tumors are the result of anomalous or exaggerated stromal epithelial interactions.⁵

References

1. Manival C, Shinoy V, Wick MR, Dehner LP. Cystosarcoma Phyllodes of the prostate. A Pathologic and immunohistochemical study. *Arch Pathol Lab Med* 1986;110:534.
2. Kerley SW, Pierce P, Thomas J. Giant cystosarcoma Phyllodes of the prostate. Associated with Adenocarcinoma. *Arch Pathol Lab Med* 1992;116:195-7.
3. Eble JN, Tejada E. Prostatic stromal hyperplasia with Bizarre Nuclei. *Arch Pathol Lab Med* 1991;115:87-9.
4. Reese JH, Lombard CM, Krone K, Stomey TA. Phyllodes Type of Atypical Prostatic hyperplasia. A report of Three New cases. *J Urol* 1987;138:623-6.
5. Gaudin PB, Rosai J, Epstein JI. Sarcomas and related proliferative lesions of specialized prostatic stroma. A clinicopathological study of 22 cases. *Am J Surg Pathol* 1998;2:148-62.
6. Pins MR, Campbell SC, Laskin WB, Steinbronn K, Dalton DP. Solitary Fibrous tumor of the prostate. A report of 2 cases and review of the literature. *Arch Pathol Lab Med* 2001;125:274-77.
7. Yamamoto S, Ito I, Miki M, Serizawa H, Mackawa S, Furusato M. Malignant phyllodes tumor of the prostate. *International J Urology* 2000;7:378-82.
8. Young JF, Jences PE, Wiley CA. Malignant Phyllodes Tumor of the prostate. A Case Report with immunohistochemical and ultra structural studies. *Arch Pathol Lab Med* 1992;116:296-8.
9. Pietruszka M, Barnes L. Cystosarcoma Phyllodes. Clinicopathological analysis of 42 cases. *Cancer* 1978;41:1974-83.
10. Ward RM, Evans HL. Cystosarcoma Phyllodes. Clinicopathological study of 26 cases. *Cancer* 1986;58:2282-9.