

ORIGINAL ARTICLE

DESCRIPTION OF THE NORMAL VARIANTS OF THE ANATOMICAL SHAPES OF THE SELLA TURCICA USING PLAIN RADIOGRAPHS: EXPERIENCE FROM SOKOTO, NORTHWESTERN NIGERIA

A. D. Zagga¹, H. Ahmed², A. A. Tadros¹, and S. A. Saidu³

¹Departments of Anatomy, College of Health Sciences, Usmanu Danfodiyo University, Sokoto, Nigeria

²Department of Paediatrics, College of Health Sciences, Usmanu Danfodiyo University, Sokoto, Nigeria

³Department of Radiology, College of Health Sciences, Usmanu Danfodiyo University, Sokoto, Nigeria

Reprint requests to: Dr. A.D. Zagga, Department of Anatomy, College of Health Sciences, Usmanu Danfodiyo University, P. M. B. 2346, Sokoto, Nigeria. E-mail: adauduzagga@yahoo.com

Abstract

Background: The anatomy of the sella turcica is variable in size and shape. It has been classified into three types: round, oval and flat. It can also be deep or shallow in both children and adults. The floor of the sella turcica which in most cases is concave may be, flat or even convex. In both anatomical and radiological practice in Nigeria, normal data in relation to the description of the normal variants of the anatomical shapes of the sella turcica are based on Caucasian studies.

Methods: All available lateral skull radiographs of subjects over a 3-year period, from 2002 to 2004, were retrieved from the Radiology Department of the Usmanu Danfodiyo University Teaching Hospital, Sokoto for the study. Radiographs were mounted on the viewing boxes and sellae turcicae were studied and classified.

Results: A total of 228 subjects were involved in this study. Of this figure, 171 (75%) were males, and 57 (25%) were females (m: f ratio=3:1). The predominant shape of sella in the African subjects studied is oval, and the difference in frequency of oval shaped sella and that of round or flat types is highly statistically significant. ($P<.001$). The commonest type of sella floor in the African subjects studied is concave and the difference in frequency of concave shaped sella floor and that of flat and convex types is highly statistically significant. ($P<.001$). In both the various anatomical shapes of the sella turcica and the types of floor of the sella turcica in relation to sex of the subjects studied, the difference in frequency of males and females is highly statistically significant. ($P<.001$).

Conclusion: It is concluded that the prevalence and the relative frequencies of the normal variants of the anatomical shapes of the sella turcica reported in this study on Nigerian subjects is similar to those reported in Caucasians. Further studies on a larger scale are needed to corroborate our findings.

Key words: Description, normal variants, anatomical shapes, sella turcica

Résumé

Arrière Plan: L'anatomie de sella turcica varie selon la forme et la plat. Elle peut aussi être profond ou plat, aussi chez les enfants que chez les adults. Le planche de sella turcica, qui est généralement concave peut être convexe, ou plat de forme. Bien en anatomie et en radiologie pratiques au Nigéria. Les données relatives à la description des variants normales de formes anatomiques de sella turcica sont basées sur des études caucasiennes.

Méthodes: Toutes les radiographies laterales du été collectées du departement de 3 ans (2002 a 2004) ont été collectées du departement de Radiologie de centre uiversitaire hospitalier de université Usmanu Danfodiyo pour cette étude. Les radiographies ont été montées sur les boîtes de visualization et sella turcica ont été étudiées et classifiées.

Resultats: Un total de 228 sujets ont été impliqués dans cette étude. De ce total, 171 (75%) étaient males, et 57 (25%) étaient femelles (m: f ratio = 3:1). La forme predominante de sella turcica pour les sujets africains étudiés est ovale, et la différence en frequence entre sella à forme ovale et sella à forme ronde ou plate est statistiquement très élevée. (PL 0.001).

Le plancher de sella de plus commun pour les sujets africains étudiés est concave et la différence en frequence entre sella a plancher concave sella à plancher convexe is statistiquement ties élevée. (PL 0.001).pour les deux cas de formes plancher de sella turcica et les différents types de plancher de sella turcica, en ce qui est du sex des sujets étudiés, la différence en frequence entre les mâles et les femelles est statistiquement très élevée. (PL 0.001).

Conclusion: Il est conclue la predominance et relativité des frequences de variantes normales de formes anatomiques de sella turcica considérées dans cette étude surdes sujets Nigériens est similaire à celle considérées pour les "caucasians". Des études plus poussées sur un champ plus étendu sont nécessaires pour confirmer nos decouvertes.

Mots clés: *Description, variantes normales, formes anatomiques, sella turcica*

Introduction

The sella turcica ('Turkish saddle')¹ is the superior saddle shaped concavity on the intracranial surface of the body of the sphenoid bone.² It contains the central hypophyseal or pituitary fossa which lodges the hypophyses cerebri or pituitary gland. Anteriorly its bony landmarks include the planum sphenoidale, the limbus sphenoidale, the chiasmatic sulcus, and the tuberculum sellae. Anterolateral landmarks include the optic canal, the anterior clinoid processes, and the optic strut, which forms the floor of the optic canal. The floor of the sella is the roof of the sphenoidal air sinus. Posteriorly, the sella is bounded by the dorsum sellae and the posterior clinoid processes; its lateral margins are the carotid sulci, and its superior boundary is the diaphragma sellae.³

The anatomy of the sella turcica is variable in size and shape. It has been classified into three types: round, oval and flat.⁴ It can also be deep or shallow in both children and adults. In children, 70% of sella turcica are round. In adults only 24.4% are round, whereas 58% are oval and 17.2% are flat.⁵ In profile, the sella at times has a somewhat high concave appearance caused by what appears to be an excavation beneath the anterior clinoids. This is frequently described in children and has no pathological significance. The floor of the sella turcica which in most cases is concave may be, flat or even convex.⁶

The sella turcica is usually demarcated by a dense thin white line in lateral radiographs. It is sometimes more important to recognize this feature than to estimate the size of the fossa.⁷ In both anatomical and radiological practice in Nigeria, normal data in relation to the description of the normal variants of the anatomical shapes of the sella turcica are based on Caucasian studies. There is therefore the need to have base line databased on studies from indigenous population. This study was, therefore, designed to describe the normal variants of the anatomical shapes of the sella turcica using normal lateral radiographs of Nigerians examined in the department of Radiology, Usmanu Danfodiyo University Teaching Hospital (UDUTH), Sokoto, from 2002 to 2004.

Materials and Methods

Selection of materials

All available lateral radiographs of subjects over a 3-year period from 2002 to 2004 were retrieved from the Radiology Department of the Usmanu Danfodiyo University Teaching Hospital, Sokoto for the study. Of the three hundred and fifty (350) lateral radiographs only 228 satisfied the inclusion criteria. Sample size was determined using the formula proposed by Oyejide.⁸

All the radiographs were ascertained to have been taken by trained radiographers in a standardized condition/manner (focus to film distance/target to film distance (FFD/TFD) of 40 inches (100cm).⁹ Radiographs studied were of good quality and clearly showed the anatomical features of the sella turcica. Only radiographs interpreted by experienced radiologists were studied. Thus, radiographs for study were selected on the basis of good lateral positioning, without patient rotation and having no visible evidence of pathology, which might be related to the sella turcica.

Inclusion criteria

Selection of radiographs for the study was based on the following: (a) Perfect superimposition of the clinoid processes, to rule out tilting of the skull during positioning of the patient. (b) Clear visualization and recognition of the dorsum sellae and tuberculum sellae. (c) Distinct sella turcica floor so that the shape of the fossa and its floor could be classified.

Exclusion criteria

(a)Thirty two radiographs showed abnormal sella turcica and were excluded from the study. (b)Twenty six radiographs were excluded from the study because of poor quality. (c) Sixty four radiographs were excluded because they were not interpreted by experienced radiologists.

Description technique

Radiographs were mounted on the viewing boxes and variants of the anatomical shapes of the sella turcica were studied and classified according to the methods adapted by Jones et al⁴ and Isadore⁵ (for the shapes of the sella) and Bruneton et al.⁶ (for the shapes of sella floor).

Statistical methods

Data was initially sorted out manually and tabulated and then entered into the computer using Microsoft Word, Microsoft Excel and Minitab 13.1 statistical package. χ^2 (with Yates correction) was used for comparison of proportions.

Results

The results obtained are summarized in Tables 1-4. A total of 228 subjects were involved in this study. Of

this number, 171(75%) were males, and 57(25%) were females (m: f ratio=3:1).

The various anatomical shapes of the sella turcica seen in the study are shown in Table 1.The predominant shape of sella in the Nigerian subjects studied is oval (Figure 1), and the difference in frequency of oval shaped sella and that of round (Figure 2) or flat (Figure 3) types is highly statistically significant. ($\chi^2=257.1579$; $df=2$; $P<.001$).

With regards to the various anatomical shapes of the sella turcica (oval, round and flat) in relation to the sex of the subjects, this study revealed males to be predominant for each of the three types of shapes of the sella turcica as shown in Table 2. The difference in frequency of male and female subjects is highly statistically significant ($\chi^2=57.0000$; $df=1$; $P<.001$).

Table 3 shows the different shapes of the floor of the sella turcica. The commonest type of sellar floor in Nigerian subjects studied is concave (Figures 1and2), and the difference in frequency of concave shaped sella floor and that of flat or convex (Figure 3) types is highly statistically significant ($\chi^2=180.0263$; $df=2$; $P<.001$).

Table 4 shows the types of sella turcica floor (concave, flat and convex) in relation to sex of the subjects studied. It shows that male subjects predominated for each type of sella turcica floor. The difference in frequency of male and female subjects is highly statistically significant. ($\chi^2=57.0000$; $df=1$; $P<.001$).

Table 1. The various anatomical shapes of the sella turcica

Shape of the fossa	No.	%
Oval	190*	83
Round	24	11
Flat	14	6
Total	228	100

$\chi^2=257.1579$; $df=2$; $P<.001$.

*Statistically significant in comparison to other values at $P<.001$

Table 2. The various anatomical shapes of the sella turcica in relation to sex

Shape of the fossa	M (%)	F (%)	Total
Oval	145 (84.8)*	45 (78.9)*	190 (83.3)
Round	17 (9.9)	7 (12.3)	24 (10.5)
Flat	9 (5.3)	5 (8.8)	14 (6.1)
Total	171 (100)	57 (100)	228 (100)

$\chi^2=57.0000$; $df=1$; $P<.001$

* Statistically significant in comparison to other values within the same sex at $P<.001$

Table 3. Types of sella turcica floor

Shape of the sella floor	No.	%
Concave	171*	75
Flat	37	16
Convex	20	9
Total	228	100

$\chi^2=180.0263$; $df=2$; $P<.001$.

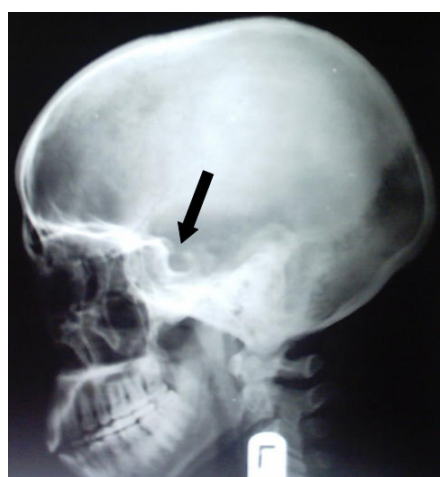
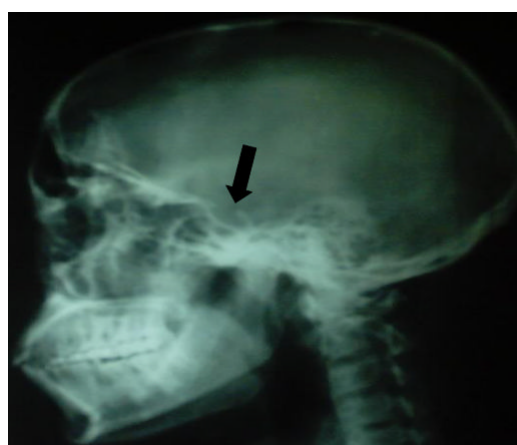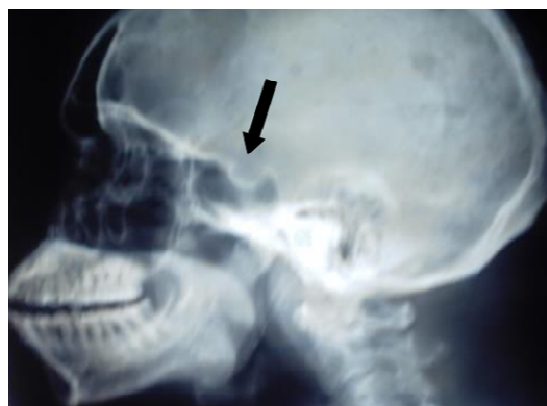* Statistically significant in comparison to other values at $P<.001$

Table 4. Types of sella turcica floor in relation to sex

Shape of the fossa floor	M (%)	F (%)	Total (%)
Concave	135 (78.9)*	36 (63.2)*	171 (75.0)
Flat	21 (12.3)	16 (28.0)	37 (16.2)
Convex	15 (8.8)	5 (8.8)	20 (8.8)
Total	171 (100)	57 (100)	228 (100)

$\chi^2=57.0000$; $df=1$; $P<.001$

* Statistically significant in comparison to other values within the same sex at $P<.001$

Figure 1. Lateral skull radiograph of a 25-year-old man showing oval type of sella turcica with a concave floor**Figure 3.** Lateral skull radiograph of a 34-year-old man showing flat type of sella turcica with a concavo-convex floor anteroposteriorly**Figure 2.** Lateral skull radiograph of a 46-year-old man showing round type of sella turcica with concave floor

Discussion

This study assessed the normal variants of the anatomical shapes of the sella turcica from normal lateral cephalometric radiographs of Nigerian subjects, a means that had also been used previously by Jones et al,⁴ Isadore⁵ and Bruneton et al⁶ in Caucasians.

The three types of shapes of sella turcica (round, oval and flat) reported by Jones et al⁴ have also been observed in this study. Although, Jones et al.⁴ did not report the percentage prevalence of each of the anatomical type of sella turcica, we found the oval type to be the commonest in our study, 83%. This was followed by the round variety, 11%. The flat was the least in occurrence, 6%. However, this study compares favorably with that of Isadore⁵ who

reported 58% oval, 24.4% round and 17.2% flat in adult Caucasians.

The number of subjects (228) used in this study is similar to the number (200) used by Bruneton et al.⁶ The incidence of normal variants of anatomical shapes of the sella turcica floor observed in both series are similar in relative frequency; ie, concave (commonest) followed by flat and then convex, but differ in terms of their prevalence rates. In this study, the prevalence of concave type of sella turcica floor is 75% which is higher than the 58% reported by Bruneton et al.⁶ In both series, flat type of sella turcica floor appeared second, with a prevalence of 32.5% reported by Bruneton et al.⁶ which is higher than in the present study. However, the prevalence rates of the convex type of sella turcica floor (which appeared with the least frequency in both studies) are very similar. Bruneton et al.⁶ reported a prevalence of 9.5% for convex sella floor, similar to our study.

From the foregoing, it follows that the prevalence and the relative frequencies of the normal variants of the anatomical shapes of the sella turcica reported in this study on Nigerian subjects is similar to those reported in Caucasians. Further studies on a larger scale are needed to corroborate our findings.

References

1. Sinnatamby CS (Eds). Last's anatomy: Regional and Applied. Churchill Livingstone, Edinburgh. 2004; 501-504. (provide initials of editor)
2. Helmy ID, Tadros AA, Michael MA. The anatomical basis of medical practice. The human skeleton. Alexandria University Press, Alexandria. 1969; 230-231.
3. Newton TH, Potts DG, eds. Radiology of the skull and brain. The skull (Volume 1, Book 1). Mosby, St. Louis. 1971; 359-405.
4. Jones RM, Faqir A, Millet DT, Mous KF, McHugh S. Bridging and dimensions of sella turcica in subjects treated by surgical orthodontics means or orthodontics only. Angle Orthod. 2004;75:714-718.
5. Meschan I. An atlas of anatomy basic to radiology. W. B. Saunders, Philadelphia. 1976; 343-349.
6. Bruneton JN, Drouillard JP, Sabatier JC, Elie GP, Travenir JF. Normal variants of the sella turcica. Comparison of plain radiographs and tomograms in 200 cases. Radiology. 1979;131:99-104.
7. Romanes GJ, ed. Cunningham's text book of anatomy. Oxford University Press, Oxford. 1981.
8. Oyejide C. Sample size estimation. In: Health research method for developing country scientist. Codat Publication, Ilorin, 1991; 59-63.
9. Bushong SC. Radiologic science for technologists: Physics, biology and protection. Mosby, St. Louis. 1980; 228-256.
1. Sinnatamby CS (Eds). Last's anatomy: Regional