

## Surgical Management of Chronic Suppurative Otitis Media: A 3-year Experience

M. A. Yaor, A. El-Kholy and B. Jafari

Department of Ear, Nose and throat, Trafford General Hospital, Manchester, UK

Reprint requests to: Mr M. A. Yaor, Department of Ear, Nose and Throat, Trafford General Hospital, Moorside Road, Davyhulme, Manchester. M41 5SL, U.K. E-mail: [mosesayaor7@aol.com](mailto:mosesayaor7@aol.com)

### Abstract

**Background/Objective:** To determine the outcome of surgery for chronic suppurative otitis media at our department over 3 years, between 2001 and 2003. The outcome measures were; achievement of dry ear, closure of tympanic membrane perforation and improvement in hearing for patients who had myringoplasty.

**Methods:** A retrospective review of case notes of patients with chronic suppurative otitis media (cholesteatoma and non-cholesteatomatous disease) operated upon by 2 consultant ENT surgeons in our department over a 3 year period. The operations performed were mastoidectomy and type I tympanoplasty or myringoplasty. The results were analysed and presented.

**Results:** Seventy three patients were operated upon for cholesteatoma and non-cholesteatomatous chronic otitis media during this period, there were 41 males and 32 females with a sex ratio of 1:1.3. Age range was 9 to 84 years with the mean age of 37 years. 17 of them were children aged 9 to 15 years (24%). 25 patients (34.2%) had cholesteatoma and 48 (65.8%) had non-cholesteatomatous disease 41 (56.2%) had myringoplasty and 29 (39.7%) had mastoidectomy, and 3 (4.1%) patients had tympanomastoidectomy. 62.5% (n=20) mastoid cavities were dry at 12 months follow up. Perforation closure was achieved in 89% (n=34).

Binaural hearing was achieved in 6 patients and in 4 patients the operated ear became the better hearing ear; air-bone gap was closed completely in 8 patients (19.5%), and in 36.6% (n=15) the gap was closed to within 10dB. There was no deterioration in hearing in the operated ears. One patient presented with House Brachman grade 2 facial palsy pre-operatively which worsened to grade 4 post operatively but improved to pre-operative grade at 12month follow up.

**Conclusion:** Chronic suppurative otitis media is a disease that is still with us, and at our department, the surgery has a high success rate, which is also comparable in adults and children.

**Key words:** Cholesteatoma, non-cholesteatomatous otitis media, tympanoplasty, surgery, outcome

### Résumé

**Fond/Objectif:** Pour déterminer les résultats de la chirurgie pour l'otite moyenne chronique suppurative à notre département pendant une période de 3 ans, entre 2001 et 2003. Les mesures de résultats étaient; accomplissement d'oreille sèche, fermeture de perforation de tympan secondaire et amélioration d'audition pour les malades qui ont eu la myringoplastie.

**Méthodes :** Un examen rétrospectif des notes de cas des malades présentant l'otite moyenne chronique suppurative ( maladie cholestéatome et non-cholestéatome) qui ont été opérés par 2 chirurgiens consultants ORL dans notre département pendant une période de 3 ans. Les opérations étaient la mastoïdectomie et le type I de la tympanoplastie ou de la myringoplastie. Les résultats ont été analysés et présentés.

**Résultats:** Soixante-treize malades ont été opérés pour l'otite moyenne chronique cholestéatome et non cholestéatome pendant cette période. Il y avait 41 mâles et 32 femelles avec un sex ratio de 1:1,3. La chaîne d'âge était de 9 à 84 ans avec l'âge moyen de 37 ans. 17 d'entre eux étaient des enfants âgés 9 à 15 ans (24%). 25 malades (34,2%) ont eu le cholestéatome et 48 (65,8%) ont eu la maladie non-cholestéatome. 41 (56,2%) ont eu la myringoplastie et 29 (39,7%) ont eu la mastoïdectomie, et 3 (4,1%) malades ont eu tympanomastoïdectomie. 62,5% (n=20) cavités du mastoïde étaient sèches à 12 mois continuent. La fermeture de perforation a été réalisée dans 89% (n=34). L'audition binaurale était accomplie dans 6 malades et dans 4 malades, l'oreille opérée est devenue l'oreille de meilleure audition ; l'énergie réserve de l'oreille interne a été comblée complètement dans 8 malades (19,5%), et dans 36,6%

(n=15) l'écart a été réduit au sein de 10dB. Il n'y avait aucune détérioration d'audition dans les oreilles opérées. Un malade a été présenté avec la paralysie du nerf facial de la catégorie 2 de la Chambre Brachman pré-peropératoire qui a empiré à la catégorie 4 post-peropératoire mais a amélioré à la catégorie pré-peropératoire à 12 mois ultérieurs.

**Conclusion:** L'otite moyenne chronique suppurative est une maladie qui est toujours avec nous, et à notre département, la chirurgie a un taux élevé de succès, qui est également comparable dans les adultes et les enfants.

**Mots clés:** Cholestéatome, otite moyenne non-cholestéatome, tympanoplastie, chirurgie, résultats

## Introduction

Chronic suppurative otitis media (CSOM) with or without cholesteatoma is a persistent disease, which can cause severe destruction of the middle ear and mastoid and lead to irreversible sequelae. In the present antibiotic era, the complications are rarely seen.

Surgery plays an important role in its management and the outcome measures are closure of tympanic membrane perforation in myringoplasty, eradication of disease and achievement of a dry and safe ear in mastoidectomy and in some cases, improvement of hearing where ossicular reconstruction or ossiculoplasty is also carried out.

The aim of this retrospective study was to evaluate our results of surgeries performed in patients with CSOM at our hospital over a three year period and a review of literature.

## Materials and Methods

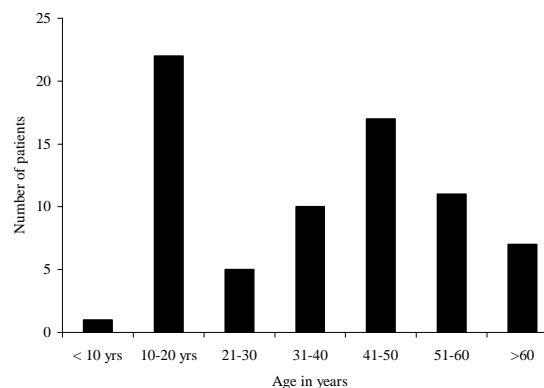
A proforma was designed to retrospectively collect data on 73 patients who had surgery for chronic suppurative otitis media (cholesteatoma and non-cholesteatomatous disease) in the ENT department at Trafford general hospital, Manchester between January 2001 and December 2003.

There were 41 males and 32 females, aged 9 - 84 years (mean 37 years); 17 were children aged 9 to 15 years (Figure 1).

Twenty five patients had cholesteatoma which was limited to the middle ear and mastoid, 48 patients had non-cholesteatomatous, tubo-tympanic mucosal disease.

Forty one primary myringoplasties were performed with 6 revisions, 2 had tympanomastoidectomy. Twenty nine mastoidectomies were carried out and all were canal wall down procedures with meatoplasties; 32 ears were wet at the time of surgery. Computed tomography (CT) scan of the temporal bone (mastoids) was performed for mastoidectomy patients. The commonest incision was the post-auricular, others were enaural and permeal. Facial nerve monitor was used in all the mastoidectomies and patients were covered with prophylactic antibiotics post-operatively. Patients were followed up for up to 18 months.

Figure 1: Age distribution of 73 patients with chronic suppurative otitis media



## Results

Closure of tympanic membrane perforation was achieved in 89% over all and the rate in children 9 - 15 years was 90%. These rates are comparable to those in literature, which varies from 66.6% to 93%. Site and size of the perforations were not assessed in this study, so their effect on the outcome could not be assessed. Three patients had discharging ears at the time of surgery, 2 of them had persistent perforation 6 months after surgery. Two patients with non-cholesteatomatous disease had tympanomastoidectomy and their ears were dry and tympanic membranes were intact at over 6months follow up.

Otorrhoea was reduced from a pre-operative rate of 43% (n=32) over all to 15% (n=11). 29 (90.6%) mastoids were wet at the time of surgery, and post-operatively, 9 (28%) were active, giving a success in achieving a dry ear of 62.5% (n=20).

Forty one patients had myringoplasty, but pre and post-operative audiometric results were available in 37 of them (Table 1). Hearing was improved in all, binaural hearing was achieved in 6 patients and in 4 patients, the operated ear became the better ear. Air-bone gap was closed to within 10dB in 26 (78.3%).

One patient presented with acute mastoiditis with facial nerve palsy, House Brachman grade 2, which got worse after the surgery to grade 4, but improved to grade 2-3 at 9 months follow up. There were no other complications in this study population.

Table 1: Post-operative air-bone gaps in 37 patients undergoing myringotomy

Air-bone gaps (dB)	No. (%)
0	8 (21.6)
5	3 (8.1)
10	15 (40.5)
15	1 (2.7)
20	7 (18.9)
30	3 (8.1)
Total	37 (100)

## Discussion

Chronic suppurative otitis media and cholesteatoma is said to a vanishing disease among western populations, with the incidence of new cases declining, Alho OP, et al (1997).<sup>1</sup> We still continue to see new cases in both adults and children. In this study, of the 29 mastoidectomies, only 6 were revisions and 25 (86.2%) were cholesteatomas, 7 of them were in children 9-15 years of age. The mastoidectomy audit by the Royal college of Surgeons of England<sup>2</sup> reported 320 out of 611 mastoidectomies were primary procedures performed for cholesteatoma in 1991 by 54 consultants and an average number of patients per consultant for one year was 11, the average in this study is 12 which is comparable and could indicate that the burden of chronic otitis media has not changed much over 9-12 years.

Our success rate in closing tympanic membrane perforations was 89%, which is comparable to the rates quoted in literature, which are between 66.6%<sup>3</sup> and 93%.<sup>4</sup> The 17 children in our study were aged 9 – 15 years, 10 had myringoplasty and the success rate in closure of perforation among them was 90%. Umapathy et al<sup>5</sup> reported 90% closure of perforation in 100 consecutive children aged 4-14 years. Our rate is comparable but the study population is smaller and the study design and criteria for success are not similar, therefore, comparison is weak. However, it shows that a success rate in children is high and comparable to that in adults.

The state of the middle ear did influence the outcome of myringoplasty in our study. 3 ears were wet at the time of surgery and 2 failed (66.7%), however there is controversy regarding the outcome of tympanoplasty in operating on wet ears. Vartianem<sup>6</sup> and Baylan<sup>7</sup> say that, the state of the middle ear at the time of surgery does not affect graft take rate while Chan<sup>8</sup> is of the opinion that eradication of disease takes priority and precedes tympanic reconstruction and Gersdorff<sup>9</sup> suggest that it influences the surgical outcome, wet ears having a higher rate of re-perforation and suggests that such ears should have mastoidectomy as well. McGrew<sup>10</sup> in their paper concluded that mastoidectomy impacts the clinical course of the disease in patients by reducing the number of patients requiring future surgery and the disease progression. Mishiro<sup>11</sup> in a retrospective

study of 251 ears with non-cholesteatomatous chronic otitis media operated upon over 11 year period, concluded that mastoidectomy is not helpful in tympanoplasty for non-cholesteatomatous disease, even if the ear is discharging. However, this is a retrospective study and with its inherent drawbacks limits the validity of such a conclusion.

62.5% of the cavities (canal wall down) in this study were dry up to 12 months post-operative follow-up and 28% of were wet. The figures are comparable to those of the mastoidectomy audit by the Royal College of surgeons of England<sup>2</sup> which reported 60% dry and 18% wet cavities at 3 and 15 months post-operatively for open cavity mastoidectomy. It is generally reported that open cavity or canal wall down mastoidectomy has a higher failure rate and poor disease control resulting in a significantly high proportion of wet ears post-operatively. Khalil<sup>12</sup> in a study of the frequency of out patient visits, clinical problems at the visit and the percentage of discharged patients in 101 patients who had canal wall down mastoidectomy, concluded that open cavity carries an intrinsic morbidity resulting in long term attendance in the outpatient.

Hearing results were assessed in the myringoplasty patients only and pre and post-operative audiograms were available in 37 of the 41 patients. Hearing improved in all, air-bone gap was closed to within 10dB in 78.3%, binaural hearing was achieved in 6 patients (16.2%) and in 4 patients (10.8%) the operated ear became the better ear.

Chronic suppurative otitis media with or without cholesteatoma is still present with us and management is still a challenge to Otolaryngologists. Surgery for chronic otitis media in both cholesteatoma and non-cholesteatomatous disease is highly successful in achieving a dry ear, closing the tympanic membrane perforation, preventing recurrence and improving hearing in both adults and children. Though improvement in hearing is not always a priority for patients undergoing tympanoplasty, from this study (though retrospective) and reports in literature, it is reasonable to include and inform patients of this outcome while consenting them for surgery.

## References

1. Alho OP, Jokinen K, Laitakari K, Palokangas J. Chronic suppurative otitis media and cholesteatoma. Vanishing disease among western populations. *Clin Otolaryngol* 1997; 22:358-361
2. Harkness P, Brown S, Fowler H, Grant R, Ryan J. Mastoidectomy audit: results of the Royal College of Surgeons of England comparative audit of ENT surgery. *Clin Otolaryngol* 1995; 20: 89-94
3. Ogisi FO, Adobamen P. Type 1 tympanoplasty in Benin: a 10 year review. *Niger Postgrad Med J* 2004; 11:84-97
4. Hung T, Knight JR, Sankar V. Anteroposterior anchoring myringoplasty technique for anterior

- and subtotal perforations. *Clin Otolaryngol* 2004; 29: 210-214
5. Umapathy N, Dekker PJ. Myringoplasty. Is it worth performing in children? *Arch Otolaryngol Head Neck Surg* 2003; 129: 1053-1055
  6. Vartiainen E, Karja J, Karjalainen S, Harma R. Failures in myringoplasty. *Arch Otorhinolaryngol* 1985;242:27-33
  7. Baylan FR, Celikkanat S, Aslan A, Taibah A, Russo A, Sanna M. Mastoidectomy in non-cholesteatomatous chronic suppurative otitis media: is it necessary? *Otolaryngol head Neck Surg* 1997;117:592-595
  8. Chan SC. Reconstructive middle-ear surgery for chronic otitis media. *Ann Acad Med Singapore* 1980;9:367-373
  9. Gersdorff M, Garin P, Decat M, Juantegui M. Myringoplasty: a long-term result in adults and children. *Am J Otol* 16:532-535
  10. McGrew BM, Jackson CG, Glasscock ME 3rd. Impact of mastoidectomy on simple tympanic membrane perforation repair. *Laryngoscope* 2004; 114:506-511
  11. Mishiro Y, Sakagami M, Takahashi Y, Kitahara T, Kajikawa H, Kubo T. Tympanoplasty with and without mastoidectomy for non-cholesteatomatous chronic otitis media. *Eur Arch Otorhinolaryngol* 2001; 258:13-15
  12. Khalil HS, Windle-Taylor PC. Canal wall down mastoidectomy: a long term commitment to the outpatients? *BMC Ear Nose Throat Disord* 2003; 3:1
-