

Child Neurology: A Case Series of Heterogeneous Neuropsychiatric Symptoms and Outcome in Very Early-Onset Narcolepsy Type 1

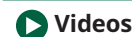Marco Veneruso, MD, Fabio Pizza, MD, PhD, Elena Finotti, MD, PhD, Giulia Amore, MD, Stefano Vandi, Marco Filardi, PhD, Elena Antelmi, MD, PhD, Lino Nobili, MD, PhD, Alessandra Cassio, MD, Andrea Pession, MD, PhD, and Giuseppe Plazzi, MD, PhD

Neurology® 2022;98:984-989. doi:10.1212/WNL.0000000000200666

Correspondence

Dr. Plazzi
giuseppe.plazzi@isnb.it

MORE ONLINE



Videos

Abstract

Narcolepsy type 1 is a central disorder of hypersomnolence characterized by excessive daytime sleepiness, cataplexy (i.e., sudden loss of muscle tone during wakefulness triggered by emotions), and REM sleep-related manifestations that can present with a peculiar phenotype when arising at a pediatric age. Several features of childhood-onset narcolepsy type 1 are also common in neuropsychiatric conditions; discrete neuropsychiatric comorbidity has also been demonstrated. Here, we report on 3 children with very early narcolepsy type 1. All 3 patients had psychiatric features at the time of symptom onset coupled with peculiar motor disturbances. The course of narcolepsy symptoms also paralleled neuropsychiatric symptoms, suggesting a possible intrinsic link between sleep and psychological features. Multidisciplinary management is mandatory for pediatric narcolepsy type 1 since prompt disease management addressing neuropsychiatric symptoms could lead to better clinical outcomes and quality of life.

From the Department of Neurosciences (M.V., L.N.), Rehabilitation, Ophthalmology, Genetics, Maternal and Child Health, University of Genova; IRCCS Istituto Delle Scienze Neurologiche di Bologna (M.V., F.P., D., G.P.); Department of Biomedical and Neuromotor Sciences (F.P., G.A., D.), University of Bologna; Department of Rehabilitation, Child and Adolescent Neuropsychiatry Unit (E.F.), ULSS 6, Vicenza; Department of Basic Medicine (M.F.), Neuroscience and Sense Organs, University Aldo Moro Bari; Center for Neurodegenerative Diseases and the Aging Brain (M.F.), University of Bari Aldo Moro -A.O. Pia Fondazione Cardinale G. Panico, Tricase; Neurology Unit (E.A.), Movement Disorders Division, Department of Neurosciences, Biomedicine and Movement Sciences, University of Verona; Child Neuropsychiatry Unit (L.N.), IRCCS Istituto G. Gaslini, Genova; Department of Medical and Surgical Sciences (A.C., A.P.), University of Bologna; IRCCS S.Orsola-Malpighi Hospital (A.C., A.P.); and Department of Biomedical (G.P.), Metabolic and Neural Sciences, University of Modena and Reggio Emilia, Modena, Italy.

Go to [Neurology.org/N](https://www.neurology.org/N) for full disclosures. Funding information and disclosures deemed relevant by the authors, if any, are provided at the end of the article.

Narcolepsy type 1 (NT1) is a central disorder of hypersomnolence characterized by excessive daytime sleepiness (EDS), cataplexy (i.e., sudden loss of muscle tone triggered by emotions), and additional rapid eye movement (REM) sleep-related manifestations (sleep paralysis, hypnagogic/hypnopompic hallucinations, disrupted nocturnal sleep, and REM sleep behavior disorder).¹ NT1 is linked to cerebrospinal hypocretin-1 (CSF hcrt-1) deficiency, reflecting the loss of hypothalamic neurons that produce hypocretin, likely because of an autoimmune process.² NT1 typically arises during adolescence and young adulthood with age-specific features.³ Childhood NT1 has a peculiar phenotype with EDS manifesting as increased sleep need or hyperactivity with behavioral changes and cataplexy as a complex movement disorder including a gait disorder or a persistent hypotonia typically involving the face (cataplectic facies) intermingled with hyperkinetic features.⁴ In addition, early endocrinologic⁵ and neuropsychiatric³ features can manifest. The peculiar clinical presentation and nonneurologic features may contribute to diagnostic delay and frequent misdiagnosis at the first referral.^{6,7} Here, we report on 3 NT1 children diagnosed at a very early age (<5 years) who displayed different clinical outcomes at follow-up.

Case Reports

Patients were referred to the Bologna Center for Narcolepsy for a second opinion, undergoing a diagnostic workup including neurologic evaluation, actigraphy, in-laboratory cataplexy video documentation, continuous 48-hour video-polysomnography (PSG), multiple sleep latency test (MSLT), brain MRI with contrast, serum testing for human leukocyte antigen (HLA) DQB1*06:02 haplotype, lumbar puncture for CSF analysis (including cytochemical and immunoblot examination, search for autoantibodies responsible for autoimmune encephalitis, virologic examination, and hcrt-1 assay⁸), and endocrinologic evaluation.

Case 1

A 2-year and 9-month-old boy with speech delay was admitted for an acute-onset gait disorder, recurrent falls to the ground, generalized hypotonia, and remarkable sleepiness. To evaluate for a suspected encephalopathy, he underwent brain MRI, EEG, toxicologic analysis, and blood and CSF examination with normal findings. Prolonged daytime (3–4 hours) and nighttime (13 hours) sleep episodes, along with remarkable motor activity during sleep, led to our referral 3 weeks after symptom onset. He presented with EDS, irritability, generalized hypotonia, and recurrent episodes of transient muscular atonia involving the face, limbs and trunk, also leading to falls, apparently triggered by eating and physical tasks (Video 1, Segments 1–3). He also showed intense motor and verbal activities and multiple awakenings during nocturnal sleep (Video 1, Segments 4 and 8). Sleep studies, low CSF hcrt-1, and DQB1*06:02 positivity led to NT1 diagnosis (Table 1). IV immunoglobulin (IVIG) treatment did not modify his symptomatology,⁹ and at 6

month follow-up, he showed a subcontinuous cataplectic state with diffuse hypotonia, wide-based gait, and hyperkinetic movements involving the face (Video 1, Segments 5–6–7). His speech was dramatically compromised (language limited to few words), and he presented with irritability, temper tantrums, motor restlessness, and 9-kg weight gain leading to obesity (BMI 23.1; Z-score 4.1). At 3 years and 5 months of age, treatment with sodium oxybate (SO) up to 2.5 g was started but immediately withdrawn by his parents because of difficulties in administration. At 7 years and 2 months of age, he presented with remarkable sleepiness, subcontinuous cataplexy, severe sociocommunicative difficulties, selective interests, rigidity/resistance to change, and motor stereotypies, consistent with a diagnosis of autism spectrum disorder (Video 1, Segment 9). BMI was 37 kg/m² (Z-score 3.1). We gradually titrated SO up to 8 g. At his last follow-up after 5 months of therapy with SO at 7 years and 7 months of age, he showed remarkable improvement in nocturnal sleep, EDS, and cataplexy with weight loss (BMI 33.6 kg/m²; Z-score 2.9). Moreover, he showed a significant improvement in autistic symptoms with reduced aggressiveness.

Case 2

A 4-year and 10-month-old boy presented with involuntary movements of the face, trunk, and limbs 1 month after a flu-like syndrome. Choreiform movements, hypotonia, dysmetria, and a wide-based gait led us to suspect cerebellitis (Video 2, Segment 1). Brain MRI was normal with the exception of a cystic pineal gland. EEG, toxicologic analysis, and blood and CSF analyses were also unremarkable. We observed the patient 2 months after symptom onset with EDS, nocturnal sleep disruption (motor restlessness and screaming) (Video 3, Segment 5), and severe cataplexy. Indeed, the boy showed cataplectic facies (Video 2, Segment 4), with episodes of sudden atonia in facial muscles, ptosis, and mouth opening, elicited by positive emotional stimuli like watching cartoons. His examination was also notable for choreiform-like movements in his limbs and trunk (Video 2, Segments 2 and 3). A moderate weight gain was reported (BMI 17.8 kg/m²; Z-score 1.5). Sleep studies, low CSF hcrt-1, and DQB1*06:02 positivity led to NT1 diagnosis (Table 1). IVIG treatment did not significantly improve the clinical picture. At 6 months of follow-up (5 years and 4 months of age), he presented with spontaneous EDS amelioration, and pitolisant was started up to 18 mg/d with further improvement of subjective sleepiness. Cataplexy was markedly reduced together with his movement disorder. One year after symptom onset (5 years and 10 months of age), SO (up to 5 g/d) was added on with significant improvement in nocturnal sleep efficiency and daytime sleepiness (Figure 1).

At last follow-up (10 years and 1 month of age), sleepiness and cataplexy were not entirely controlled by pharmacologic (pitolisant 18 mg/d and SO 5 g/d) and behavioral (scheduled nap and regular sport activity) therapy. Of note, he developed a mild mood disorder with social isolation, sadness, and irritability.

Table 1 Laboratory Results, HLA Characterization, Brain MRI, Anthropometric Measures, and Endocrinologic and Psychiatric Aspects

	Case 1	Case 2	Case 3
Sex	Male	Male	Female
Age at onset	2 y 9 m	4 y 10 m	3 y 8 m
First symptom	Gait disorder	Movement disorder	Somnolence
First diagnosis	Encephalitis	Cerebellitis	Psychiatric disorder
Brain MRI	Normal	Cystic pineal gland	Normal
ASO (UI/ml)	338	293	299
Hcrt-1 (pg/mL) (cutoff value <110 pg/mL) ³	30.95 (I), 0 (II)	68.65 (I), 84.90 (II)	49.5 (I)
HLA DQB1*0602	+	+	+
BMI (kg/m ²), Z-score, percentile	17, 0.73, 77° (I)	22.7, 3.94, >99°(II)	20.7, 2.69, >99°(I)
		15.6, 0.18, 57° (II)	27.7, 3.42, >99° (II)
			21.5, 2.54, 99° (II)
Endocrinologic symptoms	Prepubertal stage and obesity	Prepubertal stage	Breast development and obesity
Psychiatric symptoms	Irritability and behavioral disorder	Mild depressive feelings	Irritability and eating disorder
Cataplexy—negative symptoms	++	++	++
Cataplexy—positive symptoms	-	++	-
Cataplexy—facies	-	+	+
EDS	++	+	+
DNS	+	++	+
HH	—	—	+
SP	—	—	—
PSG daytime nap number	3	3	2
PSG daytime total sleep time (min)	274	169	185
PSG daytime SOREMP number	1	2	2
PSG nocturnal sleep latency (min)	5	5	10
PSG nocturnal rem latency (min)	9	2	4
PSG nocturnal total sleep time (min)	506	443	478
PSG nocturnal sleep efficiency (%)	85	89	89
MSLT mean sleep latency (from conventional lights off) (min) (cutoff value <8 min) ³	1.3	9.5	7.24
MSLT mean sleep latency (considering patients collaboration) (min) (cutoff value <8 min) ³		3.2	
MSLT SOREMP number (cutoff value ≥2) ³	5	5	3

MRI: magnetic resonance imaging; ASO antistreptolysin-O; hcrt-1: hypocretin-1; HLA: human leukocyte antigen; BMI: body mass index. (I): first evaluation; (II): second evaluation. EDS: excessive daytime sleepiness; DNS: disrupted nocturnal sleep; HH hypnagogic hallucinations; SP: sleep paralysis; PSG: polysomnography; MSLT: multiple sleep latency test; SOREMP: sleep-onset REM periods.

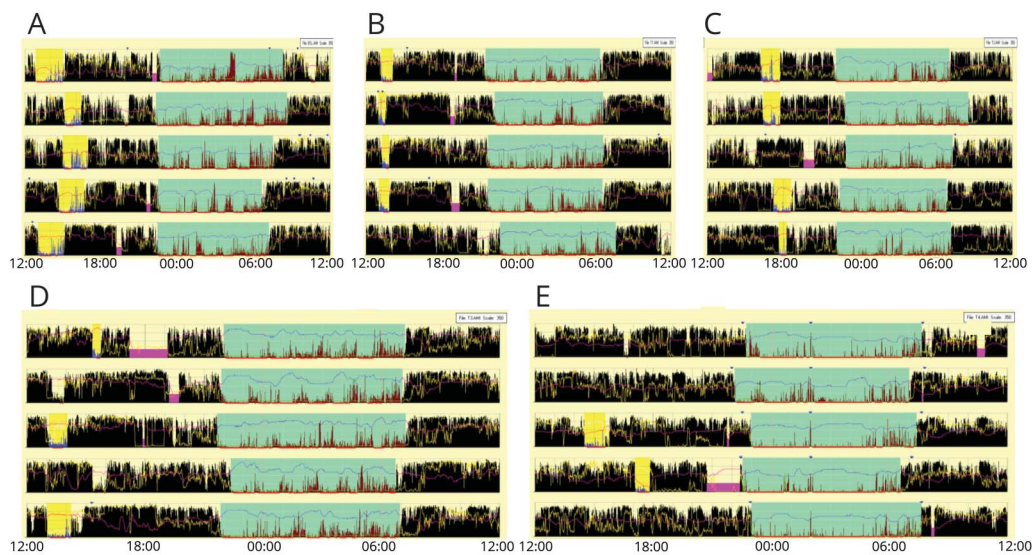
Case 3

A 3-year and 8-month-old girl with an unremarkable history became frankly somnolent after a flu-like episode needing prolonged naps (3 hours) both at school and at home. Her parents reported difficulties falling asleep at night when she

often experienced frightening visual hallucinations, awakenings, sleep talking, and limb movements.

Over the course of 2 weeks, she presented with a droopy face and spontaneous mouth openings, tongue protrusions,

Figure 1 Actigraphic Recordings (Segments) From Case 2 Referred to Long-Lasting Monitoring



Each panel shows a window of five days. Black bars symbolize movement detected by wrist actigraphy; absence of black bars indicates supposed sleeping periods. Horizontal lines represent consecutive 24-hour periods with clock hours indicated on the x-axis. Sky-blue highlight = nocturnal sleep period. Yellow highlight = diurnal sleep episodes. Fuchsia highlight = periods of device removal. Before the diagnosis (A), actigraphy depicts the 24-hour profile typical of NT1 children. At 3- and 6-month follow-up, actigraphy shows progressive and spontaneous reduction of daytime sleep time coupled with a decrease of nocturnal motor activity intensity (B and C). At 9-month follow-up (D, stable treatment with pitolisant 18 mg/d), actigraphy documented a further reduction of diurnal sleep episodes coupled with improvement of subjective sleepiness and cataplexy. At 12-month follow-up, SO was added-on and actigraphy (E) documented a significant improvement in nocturnal sleep efficiency and a shortening of nighttime sleep duration, paralleled by a decrease in afternoon nap frequency.

eyelids closures, and laughter-related falls. She developed irritability and increased appetite, leading to a weight gain of 8 kg in 2 months (BMI 20.5 kg/m²; Z-score 2.6). A psychiatric disorder was alleged because brain MRI, EEG, and blood and CSF analyses were unremarkable. Sleep studies, low CSF hcrt-1, and DQB1*06:02 positivity led to NT1 diagnosis 2 months after symptom onset (Table 1). Early signs of secondary sexual development (breasts and pubic hair) were noted (Tanner stage 2), and hormonal examination indicated a central precocious puberty treated with GnRH agonist therapy. She was initially treated with modafinil 100 mg without benefit. IVIG therapy was then added without significant clinical benefit. At 5 years and 2 months of age, SO was added on up to 8 g, resulting in improved EDS, cataplexy, and weight control.

Video 3 shows the progressive improvement of cataplexy during follow-up at 5 years and 2 months of age (Segment 1) and 6 years and 9 months of age (Segment 2). At the last follow-up (15 years and 2 months of age), narcolepsy symptoms were well controlled.

Discussion

This case series describes 3 patients with early-onset NT1 coupled with different neuropsychiatric features and prominent motor disturbances (cataplectic facies associated with gait disturbance in patient 1 and hyperkinetic movements in patient 2).

Narcolepsy is a rare chronic condition, and disease burden is worsened by diagnostic delay, emphasizing the need to recognize the unusual clinical and neuropsychiatric symptoms associated with NT1.¹⁰ Indeed, all patients in our case series met the diagnostic criteria for NT1 and presented with some peculiar behavioral and motor manifestations that have been included as red flags for early NT1 recognition by a recent consensus.¹¹

Patient 1 showed the worst clinical course, with inadequate therapy response leading to a severe limitation in daily activities. Patient 2 had mild residual symptoms and mood disturbances at long-term follow-up. Patient 3, despite precocious puberty and an initial eating disorder, did not report any residual neuropsychiatric symptoms and showed an excellent response to pharmacologic therapy.

Neuropsychiatric symptoms in these patients co-occurred with sleep disturbances and followed different clinical trajectories significantly affecting disease burden and outcome. These trajectories may be influenced by the severity of the initial psychiatric symptoms; however, it is possible to speculate that greater control over narcolepsy symptoms may also lead to better neuropsychiatric outcomes. Childhood NT1 shares phenomenologic aspects with common neuropsychiatric symptoms such as irritability, hyperactivity, emotional dysregulation, aggressive behavior, impulsiveness, and poor attention. Furthermore, the neuropsychiatric comorbidity that has been demonstrated in NT1 children includes attention deficit hyperactivity disorder (ADHD) (29%), mood disorder

(20%), anxiety disorder (10%), oppositional defiant disorder (ODD) (7%), pervasive developmental disorder not otherwise specified (3%), and eating disorders (3%).^{3,12} Despite few reports, the prevalence of autism among patients with narcolepsy is unknown.¹³ As demonstrated by case 1, there is a complex interplay between narcolepsy-related symptoms that can augment autistic traits and be exacerbated by neuropsychiatric symptoms. It is currently unknown whether hypocretin deficiency and NT1 symptoms affecting very young patients may lead to a neuropsychiatric disorder or be intrinsically part of an underlying neurodevelopmental disorder.¹⁴

Our cases showed different clinical outcomes, pointing to a possible complex relationship between genetic predisposition, neuropsychiatric symptoms, and hypocretin deficiency. Overall, a multidisciplinary approach is mandatory to address neurologic and neuropsychiatric symptoms and improve overall quality of life for pediatric patients with NT1.

Study Funding

No targeted funding reported.

Disclosure

M. Veneruso, F. Pizza, E. Finotti, G. Amore, S. Vand, M. Filardi, E. Antelmi, L. Nobili, A. Cassio, and A. Pession report no disclosures relevant to the manuscript. G. Plazzi is member of the advisory board for Jazz Pharmaceuticals, Takeda, Idorsia, and Bioprojet. Go to Neurology.org/N for full disclosures.

Publication History

Received by *Neurology* August 12, 2021. Accepted in final form March 16, 2022. Submitted and externally peer reviewed. The handling editor was Whitley Aamodt, MD, MPH.

Appendix Authors

Name	Location	Contribution
Marco Veneruso, MD	Department of Neurosciences, Rehabilitation, Ophthalmology, Genetics, Maternal and Child Health, University of Genova; IRCCS Istituto delle Scienze Neurologiche di Bologna, Italy	Drafting/revision of the manuscript for content, including medical writing for content
Fabio Pizza, MD, PhD	IRCCS Istituto delle Scienze Neurologiche di Bologna; Department of Biomedical and Neuromotor Sciences, University of Bologna, Italy	Drafting/revision of the manuscript for content, including medical writing for content
Elena Finotti, MD, PhD	Department of Rehabilitation, Child and Adolescent Neuropsychiatry Unit, ULSS 6, Vicenza, Italy	Drafting/revision of the manuscript for content, including medical writing for content
Giulia Amore, MD	Department of Biomedical and Neuromotor Sciences, University of Bologna, Italy	Drafting/revision of the manuscript for content, including medical writing for content

Appendix (continued)

Name	Location	Contribution
Stefano Vand, MD	IRCCS Istituto delle Scienze Neurologiche di Bologna; Department of Biomedical and Neuromotor Sciences, University of Bologna, Italy	Drafting/revision of the manuscript for content, including medical writing for content
Marco Filardi, PhD	Department of Basic Medicine, Neuroscience and Sense Organs, University Aldo Moro Bari; Center for Neurodegenerative Diseases and the Aging Brain, University of Bari Aldo Moro -A.O. Pia Fondazione Cardinale G. Panico, Tricase, Italy	Drafting/revision of the manuscript for content, including medical writing for content
Elena Antelmi, MD, PhD	Neurology Unit, Movement Disorders Division, Department of Neurosciences, Biomedicine and Movement Sciences, University of Verona, Italy	Drafting/revision of the manuscript for content, including medical writing for content
Lino Nobili, MD, PhD	Department of Neurosciences, Rehabilitation, Ophthalmology, Genetics, Maternal and Child Health, University of Genova; Child Neuropsychiatry Unit, IRCCS Istituto G. Gaslini, Italy	Drafting/revision of the manuscript for content, including medical writing for content
Alessandra Cassio, MD	Department of Medical and Surgical Sciences, University of Bologna; IRCCS S.Orsola-Malpighi Hospital, Bologna, Italy	Drafting/revision of the manuscript for content, including medical writing for content
Andrea Pession, MD, PhD	Department of Medical and Surgical Sciences, University of Bologna; IRCCS S.Orsola-Malpighi Hospital, Bologna, Italy	Drafting/revision of the manuscript for content, including medical writing for content
Giuseppe Plazzi, MD, PhD	IRCCS Istituto delle Scienze Neurologiche di Bologna; Department of Biomedical, Metabolic and Neural Sciences, University of Modena and Reggio Emilia, Modena, Italy	Drafting/revision of the manuscript for content, including medical writing for content

References

- Plazzi G, Clawges HM, Owens JA. Clinical characteristics and burden of illness in pediatric patients with narcolepsy. *Pediatr Neurol*. 2018;85:21-32.
- Latorre D, Kallweit U, Armentani E, et al. T cells in patients with narcolepsy target self-antigens of hypocretin neurons. *Nature*. 2018;562(7725):63-68.
- Postiglione E, Antelmi E, Pizza F, Lecendreux M, Dauvilliers Y, Plazzi G. The clinical spectrum of childhood narcolepsy. *Sleep Med Rev*. 2018;38:70-85.
- Plazzi G, Pizza F, Palaia V, et al. Complex movement disorders at disease onset in childhood narcolepsy with cataplexy. *Brain*. 2011;134:3477-3489.
- Ponziani V, Gennari M, Pizza F, Balsamo A, Bernardi F, Plazzi G. Growing up with type 1 narcolepsy: its anthropometric and endocrine features. *J Clin Sleep Med*. 2016;12(12):1649-1657.
- Maski K, Steinhart E, Williams D, et al. Listening to the patient voice in narcolepsy: diagnostic delay, disease burden, and treatment efficacy. *J Clin Sleep Med*. 2017;13(3):419-425.
- Taddei RN, Werth E, Poryazova R, Baumann CR, Valko PO. Diagnostic delay in narcolepsy type 1: combining the patients' and the doctors' perspectives. *J Sleep Res*. 2016;25:709-715.
- Pizza F, Franceschini C, Peltola H, et al. Clinical and polysomnographic course of childhood narcolepsy with cataplexy. *Brain*. 2013;136(pt 12):3787-3795.
- Lecendreux M, Berthier J, Corny J, Bourdon O, Dossier C, Delclaux C. Intravenous immunoglobulin therapy in pediatric narcolepsy: a nonrandomized,

- open-label, controlled, longitudinal observational study. *J Clin Sleep Med.* 2017; 13(3):441-453.
10. Lividini A, Pizza F, Filardi M, et al. Narcolepsy type 1 features across the life span: age impact on clinical and polysomnographic phenotype. *J Clin Sleep Med.* 2021;17(7):1363-1370.
 11. Vignatelli L, Antelmi E, Ceretelli I, et al. Red Flags for early referral of people with symptoms suggestive of narcolepsy: a report from a national multidisciplinary panel. *Neurol Sci.* 2019;40(3):447-456.
 12. Szakács A, Hallböök T, Tideman P, Darin N, Wentz E. Psychiatric comorbidity and cognitive profile in children with narcolepsy with or without association to the H1N1 influenza vaccination. *Sleep.* 2015;38(4):615-621.
 13. Prihodova I, Dudova I, Mohaplova M, Hrdlicka M, Nevsimalova S. Childhood narcolepsy and autism spectrum disorders: four case reports. *Sleep Med.* 2018;51:167-170.
 14. Pizza F, Magnani M, Indrio C, Plazzi G. The hypocretin system and psychiatric disorders. *Curr Psychiatry Rep.* 2014;16(2):433.
-

Neurology Question of the Day App

Challenge yourself to answer a neurology question each day. Staying up to date and earning CME has never been easier. This app serves up one new multiple-choice question each day on various topics in neurology and provides suggested resources for further study.

Get started today at AAN.com/QODapp.

Announcing...

Child Neurology: A Case-Based Approach Cases From the Neurology® Resident & Fellow Section

This collaboration between the American Academy of Neurology (AAN) and the Child Neurology Society (CNS) represents a collection of reprinted cases from the past 15 years from the Neurology Resident & Fellow Section.

An invaluable resource for both adult and pediatric neurologists and trainees! FREE download: NPub.org/cnbook

Disputes & Debates: Rapid Online Correspondence

The editors encourage comments on recent articles through Disputes & Debates:

Access an article at Neurology.org/N and click on “MAKE COMMENT” beneath the article header.

Before submitting a comment to Disputes & Debates, remember the following:

- Disputes & Debates is restricted to comments about articles published in *Neurology* within 6 months of issue date, but the editors will consider a longer time period for submission if they consider the letter a significant addition to the literature
 - Read previously posted comments; redundant comments will not be posted
 - Your submission must be 200 words or less and have a maximum of 5 references; the first reference must be the article on which you are commenting
 - You can include a maximum of 5 authors (including yourself)
-

Neurology[®]

Child Neurology: A Case Series of Heterogeneous Neuropsychiatric Symptoms and Outcome in Very Early-Onset Narcolepsy Type 1

Marco Veneruso, Fabio Pizza, Elena Finotti, et al.

Neurology 2022;98:984-989 Published Online before print April 6, 2022

DOI 10.1212/WNL.0000000000200666

This information is current as of April 6, 2022

Updated Information & Services	including high resolution figures, can be found at: http://n.neurology.org/content/98/23/984.full
References	This article cites 14 articles, 0 of which you can access for free at: http://n.neurology.org/content/98/23/984.full#ref-list-1
Subspecialty Collections	This article, along with others on similar topics, appears in the following collection(s): All Movement Disorders http://n.neurology.org/cgi/collection/all_movement_disorders Child psychiatry http://n.neurology.org/cgi/collection/child_psychiatry Developmental disorders http://n.neurology.org/cgi/collection/developmental_disorders Narcolepsy http://n.neurology.org/cgi/collection/narcolepsy
Permissions & Licensing	Information about reproducing this article in parts (figures, tables) or in its entirety can be found online at: http://www.neurology.org/about/about_the_journal#permissions
Reprints	Information about ordering reprints can be found online: http://n.neurology.org/subscribers/advertise

Neurology® is the official journal of the American Academy of Neurology. Published continuously since 1951, it is now a weekly with 48 issues per year. Copyright © 2022 American Academy of Neurology. All rights reserved. Print ISSN: 0028-3878. Online ISSN: 1526-632X.

