

Degenerative joint changes of the thoracic spine with respect to sex and age

Cambios degenerativos articulares de la columna torácica con respecto al sexo y la edad

 K. Lauren Bagwell¹ |  Frank L'Engle Williams^{1*}

¹) Department of Anthropology, Georgia State University, Atlanta, USA

Abstract

The thoracic spine manifests degenerative changes from aging, obesity, repetitive strain and occupational stress, although sex differences are poorly understood. In this work we examine whether differences in the expression of thoracic degenerative joint changes can be found in females and males with respect to age. The two age groups included in the study are older adults between 50 and 55 years and elderly individuals between 70-75 years from the William M. Bass osteological collection of the University of Tennessee, Knoxville (USA). The first interval represents the onset of skeletal decline. The second is correlated with reduced mobility and an increase in arthritic pain. The thoracic vertebrae from 99 individuals (52 females and 47 males) were macroscopically examined on superior and inferior centra and zygapophyses for lipping, porosity and eburnation following Buikstra and Ubelaker's (1994) scoring system. Elderly females and males exhibit a higher severity of degenerative changes than older adults, and in males the degree of lipping was extreme. Regarding older adults, males present a greater severity of lipping, extent of lipping, porosity, and extent of porosity than females. However, females show a greater degree of eburnation among older adults, particularly in the lower thoracic vertebrae. When elderly adults are compared, males express a higher degree of lipping, extent of lipping and extent of porosity than females. Like their older adult counterparts, elderly females show evidence of a greater severity in eburnation than males, suggesting hormonal profile disruption associated with reproductive cessation as well as occupational stress, may also cause the deterioration of the intervertebral discs, particularly in the lower thoracic skeleton. Arg An-trop Biol 24(2), 2022. <https://doi.org/10.24215/18536387e054>

Keywords: vertebrae; porosity; lipping; eburnation; osteoarthritis

REVISTA ARGENTINA DE ANTROPOLOGÍA BIOLÓGICA

Volumen 24, Número 2
Julio-Diciembre 2022

There was no financial support received
for this work

*Corresponding author: Frank L'Engle
Williams, Department of Anthropology,
Georgia State University, 33 Gilmer
Street, Atlanta, GA 30303, USA.
E-mail: frankwilliams@gsu.edu

RECIBIDO: 2 Agosto 2021

ACEPTADO: 11 Marzo 2022

<https://doi.org/10.24215/18536387e054>

e-ISSN 1853-6387

<https://revistas.unlp.edu.ar/raab>

Entidad Editora
Asociación de Antropología Biológica
Argentina

Resumen

La columna vertebral torácica manifiesta cambios degenerativos por envejecimiento, obesidad, actividad repetitiva y estrés ocupacional, aunque las diferencias por sexo son poco conocidas. Examinamos si existen diferencias en la expresión de los cambios articulares degenerativos en las vértebras torácicas en mujeres y hombres con respecto a la edad. Los dos grupos de edad incluidos en el análisis corresponden a adultos maduros entre 50 y 55 años y entre 70 y 75 años pertenecientes a la colección osteológica William M. Bass de la Universidad de Tennessee, Knoxville (EEUU). El primer intervalo representa el inicio del declive esquelético, mientras que el segundo está relacionado con una movilidad reducida y un aumento en el dolor articular. Se examinaron macroscópicamente las vértebras torácicas de 99 individuos (52 mujeres y 47 hombres) en las articulaciones superiores e inferiores de los cuerpos y en las zigapófisis, relevando la presencia de osteofitos, porosidad y eburnación según el sistema de puntuación no métrico de Buikstra y Ubelaker (1994). Tanto los individuos femeninos como los masculinos de mayor edad presentan una mayor severidad en los cambios degenerativos que los adultos mayores, y para los hombres el grado de osteofitos fue extremo. Para los adultos mayores, los hombres presentan una mayor severidad de osteofitos, extensión de osteofitos, porosidad y extensión de la porosidad, que las mujeres. Sin embargo, las mujeres presentan un mayor grado de eburnación, particularmente en las vértebras torácicas inferiores. Cuando se comparan los adultos mayores, los hombres expresan un mayor grado de osteofitosis, extensión de osteofitos y extensión de la porosidad, que las mujeres. Al igual que sus contrapartes de mayor edad, las mujeres adultas maduras muestran evidencia de una mayor severidad en eburnación que los hombres, lo que sugiere que la alteración del perfil hormonal asociada con el cese reproductivo de las mujeres, así como el estrés ocupacional, pueden afectar el deterioro de los discos intervertebrales, particularmente en el esqueleto torácico inferior. Arg Antrop Biol 24(2), 2022. <https://doi.org/10.24215/18536387e054>

Palabras Clave: vértebras; porosidad; osteofitosis; eburnación; osteoartritis

Degeneration joint change is a characteristic part of the aging process and occupational stress (Burkhardt & Grupe, 2018; Chen *et al.*, 2017; Listi & Manhein, 2012; López-Barrales *et al.*, 2015; Mays & Dungworth, 2009; Ortner, 2003; Schaffer *et al.*, 2010; Watkins, 2012; Weiss & Jurmain, 2007). In adulthood, and increasingly during the post-reproductive interval, a combination of progressive, deteriorative loss of bony tissue leads to porosity whereas reactive bone formation in the articular surfaces of the joints causes marginal osteophytic lipping (Knüsel *et al.*, 1997; Larsen, 2015; Snodgrass, 2004). Once the joint capsule has suffered collapse and the mating articular pairs establish contact, the subsequent friction between elements results in eburnation (Molnar *et al.*, 2011; Waldron, 2009; Yustos *et al.*, 2021). In addition to age, other factors such as sex, genetics, obesity, genetic predisposition and occupational stress may increase the severity of degenerative joint changes (Chen *et al.*, 2017; Jurmain, 1977; McGonagle *et al.*, 2010; Ortner, 2003; Weiss & Jurmain, 2007). Furthermore, stress suffered earlier in life, such as disease or trauma to the joint can result in severe degenerative changes (Ortner, 2003; Gibbon *et al.*, 2014; Watkins, 2012). Acute stress from vehicular accidents and contact sports such as rugby can rupture the intervertebral joints of the thoracic spine resulting in Schmorl's nodes on the *centrum* surface and other degenerative markers (Ústúndaž, 2009). Degenerative joint changes commonly affect the wrist (Roberts *et al.*, 2006), knees (Plomp *et al.*, 2015), temporomandibular joint (Suby & Giberto, 2019), upper limbs (Palmer *et al.*, 2016), spine (Bridges,

1994; Knüsel *et al.*, 1997; Listi & Manhein, 2012; Quispe & Williams, 2019; Snodgrass, 2004; Ūstūndaġ, 2009; Williamson, 2015), shoulders (Brenneman *et al.*, 2017), hips and elbows (Watkins, 2012; Woo & Sciulli, 2013). As individuals age they will commonly experience pain, inflammation and loss of mobility in the affected areas (Goldring & Goldring, 2006).

While it is accepted that degenerative joint changes manifest in eburnation and osteophyte formation, whether porosity falls under the diagnostic term “osteoarthritis” and is the result of the same processes has been called into question (Austin, 2017; Becker, & Goldstein, 2018; Rothschild, 1997). Two or more of these features has to be present to diagnose osteoarthritis and only eburnation is pathognomonic of this joint disease. It must be borne in mind that porosity in the absence of eburnation and lipping is not necessarily evidence of osteoarthritis (Austin, 2017; Becker & Goldstein, 2018; Gibbon *et al.*, 2014; Molnar *et al.*, 2011; Palmer *et al.*, 2016; Roberts *et al.*, 2006; Rothschild, 1997).

Furthermore, some variability exists in the pathology of the different areas affected. For instance, the elbows and knees tend to exhibit deep grooves coupled with eburnation (Ortner, 2003), whereas other areas primarily present polished surfaces, including the humeral head (Woo & Sciulli, 2013) and the metacarpal articular surfaces (Molnar *et al.*, 2011). Similarly, the vertebral column may present extensive lipping but eburnation is often less extreme with polish and very weak grooves, perhaps from constraints in mobility. In the spine, degenerative joint changes primarily affect the subchondral bone of the intervertebral discs and the apophyseal joints (Maat *et al.*, 1995; Ortner, 2003; Woo & Pak, 2014). Due to a decrease in cellular activity that is essential to the maintenance of disc cartilage, degeneration is considered to begin with the intervertebral disc (Benoist, 2003; Ūstūndaġ, 2009; Zehra *et al.*, 2015). Apophyseal joints act to counter and support the posterior load-bearing muscles of the back and are principally associated with eburnation, porosity, and marginal lipping. The subchondral bone (vertebral body) is characterized primarily by erosion and osteophyte development (Calce *et al.*, 2017; Ortner, 2003). The lower thoracic shows a higher severity than the upper thoracic, whereas the region least affected is the seventh thoracic to the upper thoracic (Larsen, 2015).

Age differences

Most individuals over the age of 50 years across cultures and geographic regions will experience degenerative joint changes associated with osteoarthritis (Felson, 2003; Molnar *et al.*, 2011). Some suggest that over the life course, articular cartilage will be subject to deterioration due to extended periods of mechanical use (Bettié *et al.*, 2009; Loeser, 2009, 2010). During the aging process, progressive change in articular cartilage accumulate in the extracellular matrix (Loeser, 2010). Degenerative changes may rapidly progress in older individuals because of the decreased ability of articular cartilage to withstand the pressures of mechanical loading (Molnar *et al.*, 2011; Ortner, 2003; Waldron, 2009). Outliers who suffered more severely than others, perhaps from a decreased resistance to stress from the accumulation of physical damage, chronic illness or genetic predisposition, increase in number as a function of advancing age (Marklein *et al.*, 2016).

Sex differences

There is much variation existing in the expression of degenerative joint changes in adult females and males. As a result, there are conflicting views on the relationship between sex differences and degeneration during the life course. According to Larsen

(2015) when significant differences can be observed for degenerative joint changes associated with osteoarthritis, males tend to express a higher frequency than females (Molnar *et al.*, 2011). Similarly, Woo & Pak (2014) noted that males showed a greater severity than females. Rogers & Dieppe (2003) argue that while this is true for men before the age of 50 years, after that age women show greater prevalence of degenerative joint changes involved in the expression of osteoarthritis (Nevitt & Felson, 1996; Rogers & Dieppe, 2003). This could possibly be related to declining levels of estrogen that women experience following menopause. Quispe & Williams (2019) found that males present a greater severity of degenerative markers than females for most indicators. However, older adult females, aged 50-55 years, exhibit significantly greater eburnation than their male counterparts, although this was not true of the elderly (Quispe & Williams, 2019). Meanwhile, Snodgrass (2004) found both sexes exhibit the same progression of vertebral degeneration with respect to age, although females are more variable. Srikanth *et al.* (2005) analyzed 34 studies on sex differences and degeneration to determine whether there were an increased severity in males or females. Although only four studies on the spine were investigated, none yielded significant difference between males and females (Srikanth *et al.*, 2005).

Given these disparate results, it is possible that females and males may or may not differ in the degeneration of the thoracic skeleton with respect to age. The two sexes are compared at two post-reproductive age cohorts, separated by twenty years. The twenty-year interval between the two age cohorts conservatively estimates the amount of time needed for significant skeletal degeneration to occur based on the length of the human maturation sequence (Quispe & Williams, 2019). The current study on the thoracic spine serves as a continuation of Quispe & Williams (2019) who focused on the cervical vertebrae. Therefore, the same sample size and composition -both sexes at 50-55 and 70-75 years- and the use of the Buikstra & Ubelaker (1994), scoring system, is replicated in this study.

MATERIALS AND METHODS

To examine whether sex differences in degenerative markers exists with respect to age, thoracic vertebrae were examined from complete skeletons of the William M. Bass collection of the University of Tennessee, Knoxville, where an extensive collection of human remains with recorded sex, age and causes of death is curated (Shirley *et al.*, 2011). The socioeconomic status of 60% of donors can be categorized as low to middle income and 40% were laborers with a high school diploma (Wilson *et al.*, 2007). The donor self-reported parameters included working-class, with a living stature between five-feet two inches and six-feet. Specific stature parameters decreased extrinsic factors that could potentially affect the expression of degenerative markers. Using these selection criteria, 99 individuals from the Bass collection were examined (Table 1). The sample included females and males between the ages of 50-55 years, and females and males between the ages of 70-75 years,

Table 1. Number of individuals included in the study by age category and sex

Category	Age in years	Female	Male	Total
Older adult	50-55	28	25	53
Elderly adult	70-75	24	22	46
Total		52	47	99

replicating the research design of Quispe & Williams (2019). The total sample included 52 females and 47 males, of whom 53 were older adults and 46 were elderly individuals (Table 1). Each thoracic vertebra from T1 to T12 was examined. The superior and inferior surfaces of the body were scored for lipping, porosity, and eburnation.

There are multiple interpretations available for the diagnosis of osteoarthritis. Most acknowledge eburnation as its most severe manifestation and indeed pathognomonic of osteoarthritis, although many researchers also attribute this pathology to joint surfaces that exhibit at least two degenerative changes including porosity, osteophytosis or joint contour modifications (Austin, 2017; Becker & Goldstein, 2018; Gibbon *et al.*, 2014; Molnar *et al.*, 2011; Palmer *et al.*, 2016; Plomp *et al.*, 2015; Roberts *et al.*, 2006; Suby & Giberto, 2019; Ūstŭndaĝ, 2009). Yet there is variation in the way in which these diagnostic principles are applied. Whereas some collapse the categories of eburnation and other degenerative joint changes under osteoarthritis (Austin, 2017; Becker & Goldstein, 2018; Gibbon *et al.*, 2014; Palmer *et al.*, 2016; Ūstŭndaĝ, 2009), others tabulate these markers separately (Henderson *et al.*, 2013; Molnar *et al.*, 2011; Plomp *et al.*, 2015; Roberts *et al.*, 2006; Suby & Giberto, 2019; Watkins, 2012; Woo & Sciulli, 2013; Yustos *et al.*, 2021; Zoęga & Murphy, 2016). Given these conflicting diagnostic criteria, the Standards (Buikstra & Ubelaker, 1994) were chosen to rank degenerative joint changes independently as others have done (Henderson *et al.*, 2013; Watkins, 2012; Williamson, 2015; Woo & Sciulli, 2013; Yustos *et al.*, 2021; Zoęga & Murphy, 2016).

Following Buikstra & Ubelaker (1994) and Quispe & Williams (2019), the degree of lipping was observed macroscopically and scored from 1- 4, 1) barely observable, 2) sharp ridge, often times curled and coupled with spicules, 3) pronounced spicule formation, and 4) ankylosis or fusion (Table 2; Fig. 1). Porosity was ascertained macroscopically using scores from 1-3 and included 1) observable pinpoint perforations, 2) presence of larger coalesced perforations, and 3) both pinpoint and coalesced expressed (Fig. 2) (Buikstra & Ubelaker, 1994; Quispe & Williams, 2019). Eburnation was scored from 1-3 via macroscopic examination and included 1) unobservable or questionably present, 2) polish visible, and 3) polish present coupled with grooves (Fig. 3) (Buikstra & Ubelaker, 1994; Quispe & Williams, 2019). In addition, the extent of lipping, porosity and eburnation were also recorded from 1-3, including 1) 1/3, 2) 1/3 to 2/3, and 3) >2/3 of the surface affected (Table 2) (Buikstra & Ubelaker, 1994; Quispe & Williams, 2019). A scoring error study conducted at Georgia State University yielded no significant difference between scores for eight vertebrae conducted as two scoring attempts separated by two weeks.

Table 2. Description of vertebral osteoarthritic features scored using Buikstra and Ubelaker (1994)

Feature	Score	Extent	Description
Marginal lipping	1	<1/3	Barely observable
	2	1/3-2/3	Sharp ridges, often curled and with some spicules formation
	3	>2/3	Pronounced formation of spicules
	4		Ankylosis or fusion
Porosity	1	<1/3	Observable pinpoint perforations
	2	1/3-2/3	Presence of larger coalesced perforations
	3	>2/3	Both pinpoint and coalesced expressed
Eburnation	1	<1/3	Unobservable or questionably present
	2	1/3-2/3	Polish visible
	3	>2/3	Polish present coupled with grooves

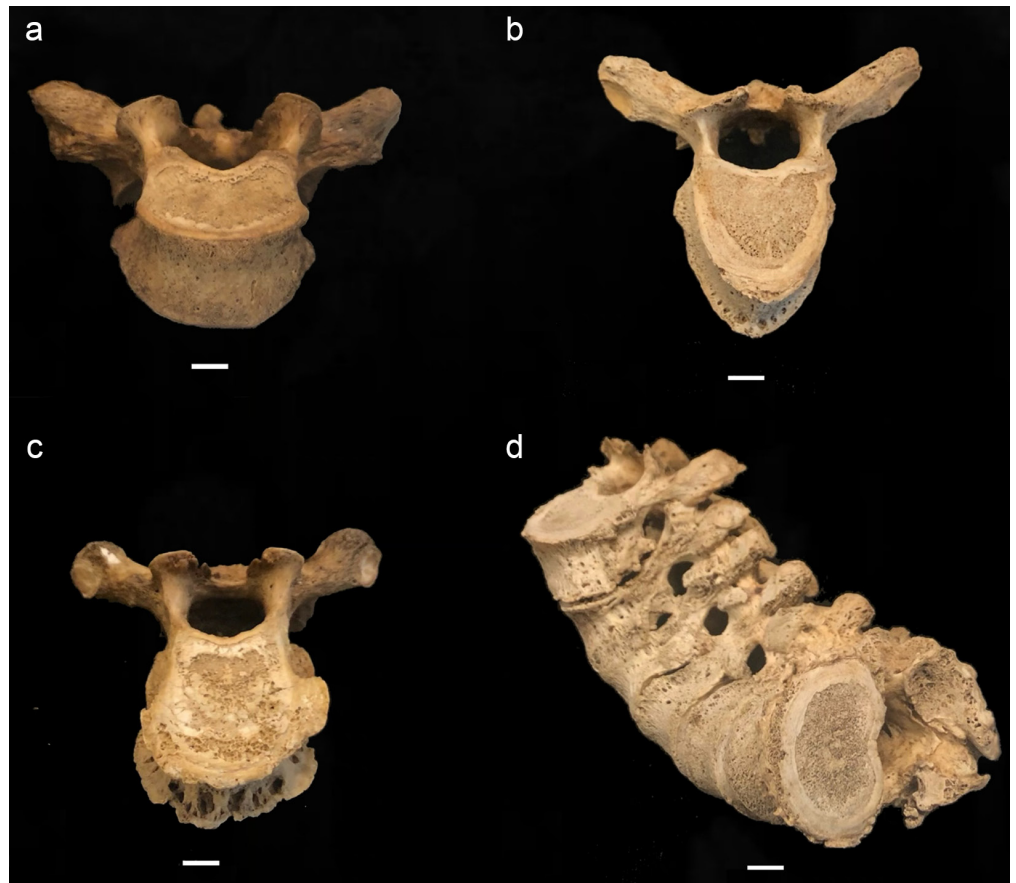


FIGURA 1. Scoring system for lipping; (a) barely observable, (b) sharp ridge, often times curled and coupled with spicules, (c) pronounced spicule formation, and (d) ankylosis or fusion; scale: 1 cm.

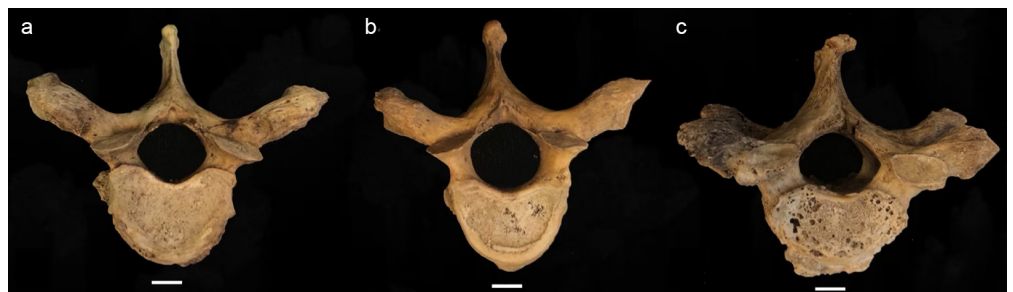


FIGURA 2. Scoring system for surface porosity; (a) observable pinpoint perforations, (b) presence of larger coalesced perforations, and (c) both pinpoint and coalesced expressed; scale: 1 cm.

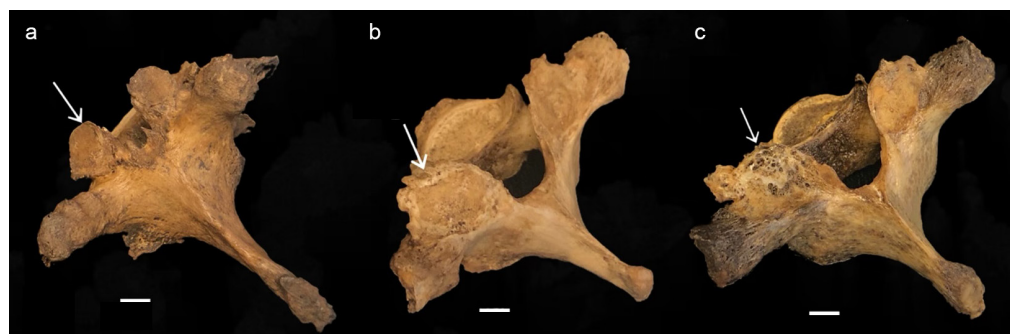

FIGURA 3. Scoring system for eburnation, identified with white arrows; (a) unobservable or questionably present, (b) polish visible, and (c) polish with groove(s); scale: 1 cm.

Lipping, porosity and eburnation signal osteoarthritis but reflect the various responses of the body to the narrowing or obliteration of interior joint spaces (Robson-Brown *et al.*, 2008; Zehra *et al.*, 2015). The scoring system used here preserves the independence of each degenerative marker. Although none of them specifically, such as eburnation, or in combination are used to diagnosis osteoarthritis, all of these degenerative markers are involved in the expression of this pathology.

The Mann-Whitney U statistic was included to test for differences within and across age cohorts. These tests included whether the sexes manifest thoracic degeneration differently by comparing older adults to elderly within each sex. Whether females and males differed as older adults and as elderly individuals was also explored. To compare thoracic degeneration across categories, 95% confidence intervals and mean values for all vertebrae scored for the four age/sex groupings are presented for each degenerative marker.

Ordinal regression was included to address the degree to which eburnation, widely considered to be diagnostic of osteoarthritis, compares to the other degenerative markers (Woo & Pak, 2014). The resulting goodness-of-fit chi-square statistic was examined to evaluate the significance of the relationship between degenerative markers. Ordinal regression allowed for a comparison of all thoracic vertebrae elements pooled together to identify significant associations, or lack thereof, between degenerative markers. Marginal lipping, porosity and eburnation were compared with one another and each of these with their respective extent of degenerative joint changes on the superior and inferior surface.

RESULTS

Older adult males have higher or equal means than their female counterparts for all features excepting eburnation and extent of eburnation where females show greater or equal values (Table 3). Similarly, the means for elderly males are higher than those of elderly females with the exception of porosity, eburnation and extent of eburnation where the converse is present (Table 3). In fact, the means for elderly males surpass those of all other age and sex groups with the exception of porosity, eburnation and extent of eburnation where elderly females are higher (Fig. 4). The means for lipping and extent of lipping are higher than for porosity and eburnation (Fig. 4). The standard deviation is highest for extent of marginal lipping across age and sex categories (Table 3).

Differences with respect to age within each sex

Elderly adult females are significantly distinct from older adults in porosity of the superior and inferior T8, superior T9 and T10 and inferior T6 and T12 (Table 4). Elderly females also show significantly greater severity than older female adults for marginal lipping, where inferior T1 and T8 and superior T9 are significantly distinct between the two groups. The same pattern is apparent for the extent of marginal lipping where inferior T2, T3 and T11 differ, and for eburnation for the superior surfaces of T9, T10 and T12, where elderly females show significantly greater severity (Table 4). In contrast, older adult females are significantly elevated in the severity of the extent of eburnation for T1 inferior ($p=0.031$) compared to elderly female individuals (Table 4).

Elderly males are by far the most distinctive from their older adult counterparts in marginal lipping, where both superior and inferior surfaces of T4, T5 and T6, as well as inferior T3 and T12 are significantly different (Table 4). Elderly males compared to older male adults are also elevated in the severity of porosity where superior T6 and inferior T5,

Table 3. Descriptive statistics for each sex and age category

	N	Female				Male					
		Min	Max	Mean	SD	N	Min	Max	Mean	SD	
Older adults (50-55 years)											
Marginal lipping superior	334	1	4	1.580	0.688	300	1	3	1.670	0.691	
Marginal lipping inferior	336	1	4	1.590	0.685	300	1	3	1.740	0.704	
Extent of marginal lipping superior	336	1	3	1.930	0.878	300	1	3	2.030	0.884	
Extent of marginal lipping inferior	336	1	4	1.920	0.914	300	1	3	1.920	0.873	
Porosity superior	336	1	2	1.020	0.133	300	1	3	1.060	0.244	
Porosity inferior	336	1	2	1.040	0.186	300	1	2	1.060	0.238	
Porosity extent superior	336	1	3	1.610	0.787	300	1	3	1.810	0.844	
Porosity extent inferior	336	1	3	1.580	0.795	300	1	3	1.710	0.817	
Eburnation superior	336	1	3	1.040	0.221	300	1	2	1.040	0.204	
Eburnation inferior	336	1	3	1.040	0.215	300	1	2	1.020	0.140	
Eburnation extent superior	336	1	3	1.070	0.306	300	1	2	1.010	0.100	
Eburnation extent inferior	336	1	3	1.090	0.384	300	1	2	1.020	0.151	
Elderly (70-75 years)											
Marginal lipping superior	285	1	3	1.690	0.636	254	1	4	1.980	0.736	
Marginal lipping inferior	285	1	3	1.770	0.647	255	1	4	2.080	0.740	
Extent of marginal lipping superior	285	1	4	1.930	0.893	254	1	3	2.170	0.880	
Extent of marginal lipping inferior	285	1	3	2.000	0.878	255	1	3	2.230	0.859	
Porosity superior	285	1	3	1.160	0.457	254	1	3	1.140	0.392	
Porosity inferior	285	1	3	1.220	0.500	255	1	3	1.240	0.539	
Porosity extent superior	285	1	3	1.730	0.853	254	1	4	1.790	0.885	
Porosity extent inferior	285	1	3	1.680	0.848	255	1	3	1.680	0.836	
Eburnation superior	285	1	3	1.150	0.402	254	1	3	1.110	0.350	
Eburnation inferior	285	1	3	1.080	0.293	255	1	2	1.050	0.228	
Eburnation extent superior	285	1	3	1.120	0.428	254	1	3	1.100	0.394	
Eburnation extent inferior	285	1	3	1.060	0.297	255	1	3	1.110	0.430	

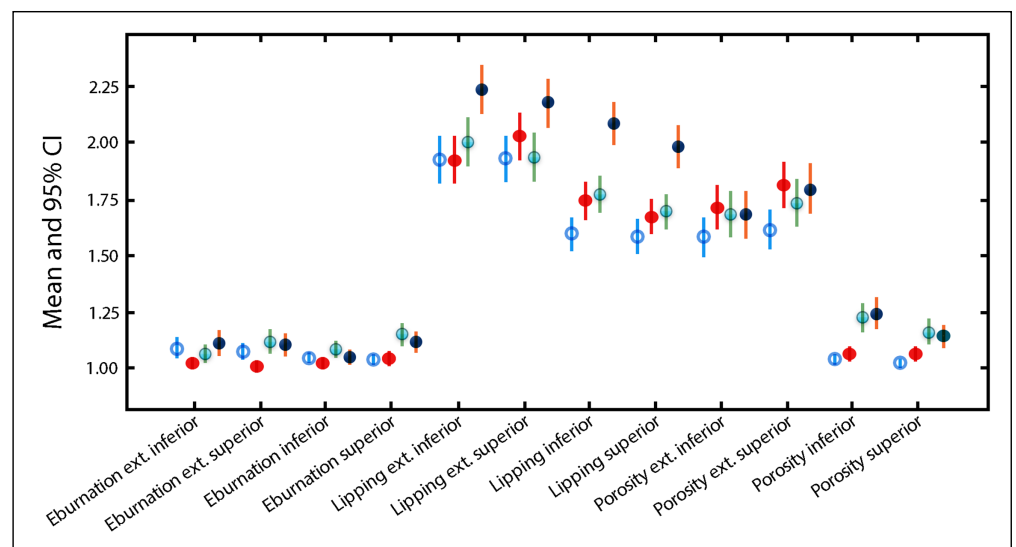


FIGURA 4. Means (circles) and 95% confidence intervals (lines) of all vertebrae scores for each age/sex category; older adult females = unfilled blue circles; older adult males = solid red circles; elderly females = green circles with blue shade; elderly males = solid dark blue circles.

TABLE 4. Results of Mann-Whitney U tests for differences between older adults and the elderly within each sex

Females only	Marginal lipping	Extent of marginal lipping	Porosity	Extent of porosity	Eburnation	Extent of eburnation
T1 inferior	0.026 O<E					0.031 E<O
T2 inferior		0.004 O<E				
T3 superior				0.036 O<E		
T3 inferior		0.040 O<E		0.021 O<E		
T6 inferior			0.024 O<E			
T8 superior			0.011 O<E			
T8 inferior	0.036 O<E		0.001 O<E			
T9 superior	0.030 O<E		0.005 O<E		0.012 O<E	
T10 superior			0.010 O<E		0.051 O<E	
T11 inferior		0.022 E<O				
T12 superior					0.051 O<E	
T12 inferior			0.051 O>E			
<hr/>						
Males only						
T1 inferior		0.003 O<E				
T3 inferior	0.015 O<E					
T4 superior	0.001 O<E					
T4 inferior	0.009 O<E					
T5 superior	0.009 O<E					0.024 O<E
T5 inferior	0.019 O<E		0.011 O<E			
T6 superior	0.004 O<E		0.049 O<E			
T6 inferior	0.003 O<E			0.040 E<O		
T8 inferior			0.020 O<E			
T9 inferior			0.029 E<O			
T12 inferior	0.046 O<E					

T8 and T9 differ significantly. In contrast, older male adults show greater severity of porosity in inferior T9 ($p=0.029$) as well as in the extent of porosity for inferior T6 ($p=0.040$). The elderly differ far more from older adults in the inferior vertebrae surfaces compared to the superior ones for both sexes, although the difference is more pronounced in males.

Sex differences within age categories

Males exhibit significantly greater severity of marginal lipping compared to females for inferior T1, T8 and T10 as well as superior T1 and T3 (Table 5). The same pattern holds for extent of marginal lipping for inferior T2 and T3 as well as for porosity on superior T1, and extent of porosity in superior and inferior T3 (Table 5). In contrast, females show a nearly significantly greater extent of eburnation compared to males for T12 superior ($p=0.052$).

Elderly males exhibit a pronounced severity of marginal lipping compared to females of the same age category for superior T4 and T5 as well as inferior T2, T6, T7, T9 and T11 (Table 5). Superior T1 also differs between elderly males and females for extent of marginal lipping and extent of porosity. In contrast, extension of eburnation for T9 superior is significantly elevated ($p=0.028$) in elderly females compared to males (Table 5). Similar to when age differences are compared within each sex, the inferior surface exhibits greater severity than the inferior surface when females and males are compared within age categories (Table 5).

TABLE 5. Results of Mann-Whitney U tests for differences between females and males within older adults and elderly individuals

Older adults	Marginal lipping	Extent of marginal lipping	Porosity	Extent of porosity	Eburnation	Extent of eburnation
(50-55 years)						
T1 superior	0.029 F<M		0.006 F<M			
T1 inferior	0.028 F<M					
T2 inferior		0.022 F<M				
T3 superior	0.046 F<M			0.003 F<M		
T3 inferior		0.050 F<M		0.003 F<M		
T9 inferior	0.040 F<M					
T10 inferior	0.040 F<M					
T12 superior						0.052 M<F
T12 inferior		0.052 M<F				
Elderly adults (70-75 years)						
T1 superior		0.041 F<M		0.011 F<M		
T2 inferior	0.043 F<M					
T4 superior	0.008 F<M					
T5 superior	0.019 F<M					
T6 inferior	0.022 F<M					
T7 inferior	0.029 F<M					
T9 superior					0.028 M<F	
T9 inferior	0.028 F<M					
T11 inferior	0.029 F<M					

When the 95% confidence intervals are compared across age and sex categories, notable differences include the distinctly higher marginal lipping and extent of marginal lipping scores for elderly males. Older adult males are relatively elevated in extent of porosity for both inferior and superior surfaces compared to other age/sex categories although the elderly of both sexes surpass older adults in porosity. For extent of eburnation inferiorly, older adult females and elderly males are distinct from older adult males, while superiorly, all age/sex categories are elevated compared to older adult males. The elderly, and particularly females, surpass older adults of both sexes in scores for eburnation superiorly (Fig. 4).

Most of the comparisons between degenerative joint changes are not significant. However, the degenerative markers that do demonstrate statistical significance are instructive (Table 6). Marginal lipping versus extent of marginal lipping on the inferior surface is significantly related in older adults ($p=0.013$), elderly individuals ($p=0.014$) and males ($p<0.001$). In addition, porosity and extent of porosity on the superior surface are significantly associated in elderly adults ($p=0.002$) as well as females ($p=0.005$). Additional comparisons demonstrate significance (Table 6). One of these is porosity and extent of porosity on the inferior surface in elderly adults ($p=0.004$) and in males ($p=0.017$). Another is marginal lipping and porosity on the superior surface in older adults ($p=0.017$). Eburnation is not significantly associated with any of the other variables, including extent of eburnation, suggesting an independent expression of this degenerative marker.

TABLE 6. Chi-square results from ordinal regression of degenerative markers for older and elderly adults and the two sexes

	Older adults (n = 636)			Elderly adults (n = 540)			Females (n = 629)			Males (n = 555)		
	X ²	df	p	X ²	df	p	X ²	df	p	X ²	df	p
Lipping vs. extent of lippling inferior	16	6	0.013	12.6	4	0.014				21.7	4	<0.001
Porosity vs. extent of porosity superior				15.1	3	0.002	10.6	2	0.005			
Porosity vs. extent of porosity inferior				11.2	2	0.004				8.1	2	0.017
Lipping vs. porosity superior	8.1	2	0.017									

DISCUSSION

Walking erect places great strain on the thoracic vertebrae and has for millions of years (Cook *et al.*, 1983) as well as more recently in prehistory (Trinkaus, 1985). Given this antiquity of vertebral degenerative markers it should be no surprise that deterioration of the spine is quite common in extant humans by 40 years (Bridges, 1994; Ortner, 2003; Quispe & Williams, 2019), but its expression is minor compared to individuals of more advanced ages (López-Barrales *et al.*, 2015; Mays & Dungworth, 2009; Snodgrass, 2004; Ūstūndağ, 2009; Yustos *et al.*, 2021). Degeneration of the skeleton accelerates after 50 years and virtually everyone has some form of osteoarthritis by 65 years of age (Solomon, 2001).

The thoracic vertebrae are believed to exhibit less extreme degenerative joint changes of the *centrum* than the lumbar and cervical regions because of the restricted movement potential of the thorax (Bridges, 1994; Larsen, 2015). In contrast, the apophyseal joints across the vertebral column are similar in degree of degenerative changes associated with osteoarthritis (Bridges, 1994). In this study, the upper (T1-T3) and lower (T9-T12) thoracic regions appear to be affected by degenerative joint changes more severely than the middle (T4-T8) vertebrae (Tables 4 and 5). This is also the case for prehistoric Amerindians from Alabama where the greatest frequency of osteoarthritis occurred on T7-T10 and T12, with a peak at T9/T10 (Bridges, 1994). Other studies have identified the lower thoracic as particularly vulnerable to degenerative joint changes (Ūstūndağ, 2009; Yustos *et al.*, 2021); however, the upper thoracic is also cited as a location of extensive degenerative joint changes associated with osteoarthritis (Jurmain, 1990). Larsen (2015) suggests the lower thoracic vertebrae bear the greatest degree of mechanical loading. This observation is corroborated by the significant differences within age (Table 4) and sex (Table 5) categories in this region. The greater severity of degenerative joint changes observed in the lower thoracic vertebrae may be due to the amount of weight it must support and a reduced threshold for mechanical loads compared to the mid and upper thoracic regions.

Although there is no specific activity or labor linked to any unambiguous manifestation of degenerative joint changes, there is some degree of correspondence between repetitive strain, particularly involving mechanical loading and severity (Larsen, 2015; Ortner, 2003; Ūstūndağ, 2009), as well as genetic predisposition (Battié *et al.*, 2009). Specific occupational stressors nevertheless appear to operate on the vertebral skeleton over the life course, such as habitual horseback riding or 19th century industrial labor in London (Larsen, 2015), fishing in arctic waters (Zoëga & Murphy, 2016) or labor as an enslaved

person (Watkins, 2012). The individuals in our sample from the University of Tennessee William M. Bass Osteology Collection were donated primarily from laborer occupations and from low and middle income service workers (Wilson *et al.*, 2007). Some of the degenerative features observed could have stemmed directly from manual labor, and in the case of many males, and perhaps some females, probably derived from the transmission of heavy loads from the arms to the lower appendicular skeleton via the thoracic spine. The significant differences between the sexes in both age categories (Table 5) provide evidence that the occupational stress from labor in low- and medium skilled work was at least in part gendered. In contrast, López-Barrales *et al.* (2015) found no statistically significant sex differences in vertebral osteoarthritis in prehistoric Andean peoples from Chile. However, prehistoric Tiwanaku females, in contrast to males, exhibit evidence of gendered repetitive movements in patterns of osteoarthritis (Becker & Goldstein, 2018) whereas males of Iron Age Zambia present greater spinal osteophytosis than do females (Gibbon *et al.*, 2014). It appears the degeneration of the spine is particularly influenced by occupational stress associated with gendered differences in labor profiles.

However, males generally weigh more and have more massive skeletons than females and the greater body weight alone over decades would tend to usher in a mechanical response of the thoracic amphiarthrodial joints from the effects of gravity and daily life. In fact, most studies show a greater prevalence of degenerative joint changes in males compared to females (Molnar *et al.*, 2011), particularly when the sexual division of labor becomes intensified, as for example, after the adoption of agriculture (Larsen, 2015). In this study, males overall presented a greater expression of degenerative markers than females. This was especially observable in margin lipping (Tables 3, 5 and 6; Fig. 4). It is therefore curious as to why older and elderly female adults, with presumably lower body weights, show significantly greater eburnation and extent of eburnation compared to males within each age category, at least for some thoracic vertebrae (Tables 4 and 5). Eburnation arises after the cartilaginous layer between mating pairs of a joint recedes or is dislodged, but the joint continues to operate producing bone-to-bone contact, which polishes and grooves the articulation (Molnar *et al.*, 2011; Ortner, 2003) and may be expressed independent of porosity or marginal lipping (Table 6). Hormonal disruptions associated with menopause may at least partly explain the greater severity of eburnation in females (Larsen, 2015). In addition to the highly eburnated thoracic elements from females noted in this study, eburnation of the cervical vertebrae is also significantly elevated in older adult females compared to males (Quispe & Williams, 2019).

Degenerative changes of the thoracic spine differ from those of the mobile joints of the skeletal system in the presence of ankylosis, which is more common in the vertebral column than in diarthrodial articulations (Larsen, 2015). The smaller inferior surface bears a relatively greater mechanical load compared to the superior articular mate below it, which may increase the growth of osteophytic lipping and eventually ankylosis. The larger number of thoracic vertebrae affected on the inferior compared to the superior surface also could be related to the unique shapes of the vertebral bodies and the placement of the articular facets.

Spinal curvature also may influence degeneration, and in particular, the increasing kyphosis of the mid-thoracic region as a function of age (Toh *et al.*, 2001). Already by age 50 years, substantial kyphosis of the thoracic skeletal has occurred, particularly in males who generally must carry a heavier head, upper arms and torso than females. These differences are merely accentuated with age and lead to extensive lipping and eburnation of the upper and lower thoracic vertebrae. Although a higher degree of degenerative joint changes would be expected to occur where the spinal curvature is the greatest since

these are areas of intense stress compared to the vertebrae aligned more directly in the line of gravity, this is not always the case (Bridges, 1994). However, extensive lipping of the thoracic vertebrae is a risk factor for fractures in males older than 50 years, particularly within the mid-thoracic curvature (Pariente *et al.*, 2017), and may help to counteract thoracic kyphosis (Toh *et al.*, 2001). One might also expect a greater expression of degenerative markers as a function of placement, whereby larger inferior vertebrae withstand more weight than smaller superior ones. Although the lumbar skeleton generally exhibits a greater degree of degenerative change compared to the vertebrae positioned more superiorly, there is no direct order of increasing severity as a function of placement. However, the lower thoracic in this study do seem to exhibit a greater severity of degenerative change than superior elements confirming to some extent that position does influence the degree of expression, although other factors may be present. These include changes in spinal curvature anticipating the lordosis of the lumbar vertebrae that may place unique stresses on the lower thoracic skeleton.

CONCLUSION

One goal of this study was to examine whether older adults differed from the elderly within males and within females. Another was to directly compare the sexes within age categories, corresponding to older adults (50-55 years) and the elderly (70-75 years). Age and sex differences exist for degenerative markers of the thoracic region. When only females are considered, elderly individuals exhibit a higher severity than older adults with the exception of the extent of eburnation in T1 and the extent of lipping in T11 on the inferior surface. For males, a greater expression of osteoarthritis is observed for elderly individuals with the exception of porosity in inferior T9 and extent of porosity in inferior T6. Lipping is particular excessive in elderly males throughout the thoracic skeleton.

When comparing older adults of both sexes, males present a greater severity of lipping, extent of lipping, porosity and extent of porosity while females show a greater extent of eburnation. These significant values are restricted to the upper and lower thoracic regions. Among elderly adults, males express a higher degree of lipping, extent of lipping and extent of porosity, whereas females exhibit a greater degree of eburnation. Contrary to Rogers & Dieppe's (2003) predictions, elderly males exhibit a significantly higher severity of lipping throughout the thoracic region compared to elderly females.

Elderly adults of both sexes manifest a greater severity of degenerative markers than their older adult counterparts. Males also express a greater degree of severity than females, excepting eburnation and extent of eburnation for some vertebrae. These exceptions could be a result of differences in hormone profiles associated with reproductive cessation as well as gendered occupational stress.

ACKNOWLEDGMENTS

We are grateful to Dr. Dawnie Steadman for approving the research design and for allowing the first author access to the William M. Bass collection at the University of Tennessee, Knoxville. We thank the student curatorial staff for their assistance with the osteological material, and two anonymous reviewers whose comments greatly improved the manuscript.

REFERENCES

- Austin, A. E. (2017). The cost of a commute: A multidisciplinary approach to osteoarthritis in New Kingdom Egypt. *International Journal of Osteoarchaeology*, 27, 537-550. <https://doi.org/10.1002/oa.2575>
- Battié, M. C., Videman, T., Kaprio, J., Gibbons, L. E., Gill, K., Manninen, H., Saarela, J. & Peltonen, L. (2009). The twin spine study: Contributions to a changing view of disc degeneration. *Spine Journal*, 9(1), 47-59. <https://doi.org/10.1016/j.spinee.2008.11.011>
- Becker, S. L. & Goldstein, P. S. (2018). Evidence of osteoarthritis in the Tiwanaku colony, Moquegua, Peru (AD 300-1100). *International Journal of Osteoarchaeology*, 28, 54-64. <https://doi.org/10.1002/oa.2634>

- Benoist, M. (2003). Natural history of the aging spine. In: M. Aebi, R. Gunzburg and M. Szpalski (Eds.), *The Aging Spine* (pp. 4-7). Berlin: Springer.
- Brennaman, A. L., Love, K. R., Bethard, J. D. & Pokines, J. T. (2017). A Bayesian approach to age-at-death estimation from osteoarthritis of the shoulder in modern North Americans. *Journal of Forensic Sciences*, 62, 3. <https://doi.org/10.1111/1556-4029.13327>
- Bridges, P. S. (1994). Vertebral arthritis and physical activities in the prehistoric southeastern United States. *American Journal of Physical Anthropology*, 93(1), 83-93. <https://doi.org/10.1002/ajpa.1330930106>
- Buikstra, J. E. & Ubelaker, D. H. (1994). *Standards for Data Collection from Human Skeletal Remains*. Fayetteville, Arkansas: University of Arkansas.
- Burkhardt, A. & Grupe, G. (2018). Hydroxylysine deficiency, conspicuous skeletal lesions and a strange burial practice in a historical German island population. *International Journal of Osteoarchaeology*, 28, 227-236. <https://doi.org/10.1002/oa.2649>
- Calce, S. E., Kurki, H. K., Weston, D. A. & Gould, L. (2017). Principal component analysis in the evaluation of osteoarthritis. *American Journal of Physical Anthropology*, 162(3), 476-490. <https://doi.org/10.1002/ajpa.23130>
- Chen, D., Shen, J., Zhao, W., Wang, T., Han, L., Hamilton, J. L. & Im, H. J. (2017). Osteoarthritis: Toward a comprehensive understanding of pathological mechanism. *Bone Research*, 5(1), 1-13. <https://doi.org/10.1038/boneres.2016.44>
- Cook, D. C., Buikstra, J. E., DeRousseau, C. J. & Johanson, D. C. (1983). Vertebral pathology in the Afar australopithecines. *American Journal of Physical Anthropology*, 60(1), 83-101.
- Felson, D. T. (2003). Epidemiology of osteoarthritis. In K. D. Brandt, M. Doherty and L. S. Lohmander (Eds.), *Osteoarthritis* (pp. 9-16). New York: Oxford University Press.
- Gibbon, V. E., Gallagher, A. & Huffman, T. N. (2014). Bioarchaeological analysis of Iron Age human skeletons from Zambia. *International Journal of Osteoarchaeology*, 24, 100-110. <https://doi.org/10.1002/oa.2231>
- Goldring, S. R. & Goldring, M. B. (2006). Clinical aspects, pathology and pathophysiology of osteoarthritis. *Journal of Musculoskeletal and Neuronal Interactions*, 6(4), 376-378.
- Henderson, C. Y., Craps, D. D., Caffell, A. C., Millard, A. R. & Gowland, R. (2013). Occupational mobility in 19th century rural England: The interpretation of enthesal changes. *International Journal of Osteoarchaeology*, 23, 197-210. <https://doi.org/10.1002/oa.2286>
- Jurmain, R. D. (1977). Stress and the etiology of osteoarthritis. *American Journal of Physical Anthropology*, 46(2), 353-365.
- Jurmain, R. D. (1990). Paleoepidemiology of a central California prehistoric population from Ca-Ala-329. II. Degenerative disease. *American Journal of Physical Anthropology*, 83(1), 83-94.
- Knüsel, C. J., Göggel, S. & Lucy, D. (1997). Comparative degenerative joint disease of the vertebral column in the medieval monastic cemetery of the Gilbertine Priory of St. Andrew, Fishergate, York, England. *American Journal of Physical Anthropology*, 103(4), 481-495.
- Larsen, C. S. (2015). *Bioarchaeology: Interpreting Behavior from the Human Skeleton*. Cambridge: Cambridge University Press.
- Listi, G. A. & Manhein, M. H. (2012). The use of vertebral osteoarthritis and osteophytosis in age estimation. *Journal of Forensic Sciences*, 57(6), 1537-1540. <https://doi.org/10.1111/j.1556-4029.2012.02152.x>
- Loeser, R. F. (2009). Aging and osteoarthritis: The role of chondrocyte sequences and aging changes in the cartilage matrix. *Osteoarthritis and Cartilage*, 17(8), 971-979. <https://doi.org/10.1016/j.joca.2009.03.002>
- Loeser, R. F. (2010). Age-related changes in the musculoskeletal system and the development of osteoarthritis. *Clinics in Geriatric Medicine*, 26(3), 371-386. <https://doi.org/10.1016/j.cger.2010.03.002>

- López-Barrales, R., Hubbe, M., Aspillaga, E., Neves, W. A. & Niemeyer, H. M. (2015). Osteofitosis vertebral en poblaciones prehispánicas de San Pedro de Atacama, norte de Chile. *Estudios Atacameños: Arqueología y Antropología Surandinas*, 50, 177-194. <https://doi.org/10.4067/S0718-10432015000100009>
- Maat, G. J., Mastwijk, R. W. & van der Velde, E. A. (1995). Skeletal distribution of degenerative changes in vertebral osteophytosis, vertebral osteoarthritis and DISH. *International Journal of Osteoarchaeology*, 5(3), 289-298.
- Marklein, K. E., Leahy, R. E., & Crews, D. E. (2016). In sickness and in death: Assessing frailty in human skeletal remains. *American Journal of Physical Anthropology*, 161(2), 208-225. <https://doi.org/10.1002/ajpa.23019>
- Mays, S. A. & Dungworth, D. (2009). Intervertebral chondrocalcinosis: An exercise in differential diagnosis in paleopathology. *International Journal of Osteoarchaeology*, 19, 36-49. <https://doi.org/10.1002/oa.973>
- McGonagle, D., Tan, A. L., Carey, J. & Benjamin, M. (2010). The anatomical basis for a novel classification of osteoarthritis and allied disorders. *Journal of Anatomy*, 216(3), 279-291. <https://doi.org/10.1111/j.1469-7580.2009.01186.x>
- Molnar, P., Ahlstrom, T. P. & Leden, I. (2011). Osteoarthritis and activity—an analysis of the relationship between eburnation, musculoskeletal stress markers (MSM) and age in two Neolithic hunter-gatherer populations from Gotland, Sweden. *International Journal of Osteoarchaeology*, 21, 283-291. <https://doi.org/10.1002/oa>
- Nevitt, M. C. & Felson, D. T. (1996). Sex hormones and the risk of osteoarthritis in women: Epidemiological evidence. *Annals of the Rheumatic Diseases*, 55(9), 673-676.
- Ortner, D. J. (2003). Osteoarthritis and diffuse idiopathic skeletal hyperostosis. In D. J. Ortner (Ed.), *Identification of Pathological Conditions in Human Skeletal Remains* (pp. 545-560). Cambridge: Academic Press.
- Palmer, J. L. A., Hoogland, M. H. L. & Waters-Rist, A. L. (2016). Activity reconstruction of post-medieval Dutch rural villagers from upper limb osteoarthritis and enthesal changes. *International Journal of Osteoarchaeology*, 26, 78-92. <https://doi.org/10.1002/oa.2397>
- Pariente, E., Olmos, J. M., Landeras, R., Nan, D., Gonzalez-Macias, J. & Hernandez, J. L. (2017). Relationship between spinal osteoarthritis and vertebral fractures in men older than 50 years: Data from the Camargo Cohort Study. *Journal of Bone and Mineral Metabolism*, 35(1), 114-121. <https://doi.org/10.1007/s00774-016-0735-1>
- Plomp, K. A., Roberts, C. A. & Strand Vidardottir, U. (2015). Morphological characteristics of healthy and osteoarthritic joint surfaces in archaeological skeletons. *International Journal of Osteoarchaeology*, 25, 515-527. <https://doi.org/10.1002/oa.2319>
- Quispe, B. I. & Williams, F. L. (2019). Cervical arthritis, C3-C7, from an identified osteological collection. *Revista Argentina de Antropología Biológica*, 21(1), 1-13. <https://doi.org/10.17139/raab.2019.0021.01.04>
- Roberts, A. M., Robson-Brown, K., Musgrave, J. H. & Leslie, I. (2006). A case of bilateral scapholunate advanced collapse in a Romano-British skeleton from Ancaster. *International Journal of Osteoarchaeology*, 16, 208-220. <https://doi.org/10.1002/oa.817>
- Robson-Brown, K., Pollintine, P. & Adams, M. A. (2008). Biomechanical implications of degenerative joint disease in the apophyseal joints of human thoracic and lumbar vertebrae. *American Journal of Physical Anthropology*, 136, 318-326. <https://doi.org/10.1002/ajpa.20814>
- Rogers, J. & Dieppe, P. (2003). Paleopathology of osteoarthritis. In K. D. Brandt, M. Doherty and L. S. Lohmander (Eds.), *Osteoarthritis* (pp. 57-65). New York: Oxford University Press.
- Rothschild, B. M. (1997). Porosity: A curiosity without diagnostic significance. *American Journal of Physical Anthropology*, 104(4), 529-533.

- Schaffer, W. C., Carr, R. S., Day, J. S. & Patemen, M. P. (2012). Lucayan-Taino burials from Preacher's Cave, Eleuthera, Bahamas. *International Journal of Osteoarchaeology*, 22, 45-69. <https://doi.org/10.1002/oa.1180>
- Shirley, N. R., Wilson, R. J. & Jantz, L. M. (2011). Cadaver use at the University of Tennessee's Anthropological Research Facility. *Clinical Anatomy* 24(3), 372-380. <https://doi.org/10.1002/ca.21154>
- Snodgrass, J. J. (2004). Sex differences and aging of the vertebral column. *Journal of Forensic Sciences*, 49(3), 458-463.
- Solomon, L. (2001). Clinical features of osteoarthritis. In: S. Ruddy, E. Harris Jr. and C. Sledge (Eds.), *Kelley's Textbook of Rheumatology* (pp. 1409-1418). Philadelphia: Saunders.
- Srikanth, V. K., Fryer, J. L., Zhai, G., Winzenberg, T. M., Hosmer, D. & Jones, G. (2005). A meta-analysis of sex differences prevalence, incidence and severity of osteoarthritis. *Osteoarthritis and Cartilage*, 13(9), 769-781.
- Suby, J. A. & Giberto, D. A. (2019). Temporomandibular joint osteoarthritis in human ancient skeletal remains from Late Holocene in southern Patagonia. *International Journal of Osteoarchaeology*, 29, 14-25. <https://doi.org/10.1002/oa.2709>
- Toh, E., Yerby, S. A., Bay, B. K., McLain, R. F., Benson, D. R. & Mochida, J. (2001). The effects of anterior osteophytes and flexural position on thoracic trabecular strain. *Spine*, 26(1), 22-26.
- Trinkaus, E. (1985). Pathology and posture of the La Chapelle-aux-Saints Neandertal. *American Journal of Physical Anthropology*, 67(1), 19-41.
- Ūstūndaġ, H. (2009). Schmorl's nodes in a post-Medieval skeletal sample from Klostermarienberg, Austria. *International Journal of Osteoarchaeology*, 19, 695-710. <https://doi.org/10.1002/oa.993>
- Waldron, T. (2009). *Paleopathology*. Cambridge: Cambridge University Press.
- Watkins, R. (2012). Variation in health and socioeconomic status within the W. Montague Cobb Skeletal Collection: Degenerative joint disease, trauma and cause of death. *International Journal of Osteoarchaeology*, 22, 22-44. <https://doi.org/10.1002/oa.1178>
- Weiss, E. & Jurmain, R. (2007). Osteoarthritis revisited: A contemporary review of aetiology. *International Journal of Osteoarchaeology*, 17(5), 437-450. <https://doi.org/10.1002/oa.889>
- Williamson, M. A. (2015). A comparison of health between upland and coastal late prehistoric agriculturalists from the southeast USA. *International Journal of Osteoarchaeology*, 25, 890-900. <https://doi.org/10.1002/oa.889> <https://doi.org/10.1002/oa.2372>
- Wilson, R. J., Algee-Hewitt, B. & Meadows Jantz, L. (2007). Demographic trends within the Forensic Anthropology Center's body donation program. *American Journal of Physical Anthropology*, 44, 252. <https://doi.org/10.1002/oa.2250>
- Woo, E. J. & Pak, S. (2014). The relationship between the two types of vertebral degenerative joint disease in a Joseon Dynasty population, Korea. *International Journal of Osteoarchaeology*, 24(6), 675-687. <https://doi.org/10.1002/oa.2250>
- Woo, E. J. & Sciulli, P. W. (2013). Degenerative joint disease and social status in the terminal Late Archaic period (1000-500 B.C.) of Ohio. *International Journal of Osteoarchaeology*, 23, 529-544. <https://doi.org/10.1002/oa.1264>
- Yustos, M., Lozano, M., Morales, J. I., Iglesias-Bexiga, J. & Vergès, J. M. (2021). Degenerative joint disease in the Chalcolithic population of El Mirador cave (Sierra de Atapuerca, Spain): The vertebral column. *International Journal of Osteoarchaeology*, 31, 162-175. <https://doi.org/10.1002/oa.2936>
- Zehra, U., Robson-Brown, K., Adams, M. A. & Dolan, P. (2015). Porosity and thickness of the vertebral endplate depend on the local mechanical loading. *Spine*, 40, 1173-1180. <https://doi.org/10.1097/BRS.0000000000000925>
- Zoëga, G. & Murphy, K. A. (2016). Life on the edge of the Arctic: The bioarchaeology of the Keldudalur cemetery in Skagafiörour, Iceland. *International Journal of Osteoarchaeology*, 26, 574-584. <https://doi.org/10.1002/oa.2446>