

*Case Report*

# Idiopathic Pneumonia Syndrome Refractory to Ruxolitinib after Post-Transplant Cyclophosphamide-based Haploidentical Hematopoietic Stem Cell Transplantation: Lung Pathological Findings from an Autopsy Case

Ken Matsumoto, Keigo Fujishita\*, Masayuki Matsuda, Satoshi Oka,  
Yuka Fujisawa, Toshi Imai, and Takuya Machida

*Department of Hematology and Blood Transfusion, Kochi Health Sciences Center, Kochi 781-8555, Japan*

A 69-year-old Japanese man with acute leukemia received post-transplant cyclophosphamide-based haploidentical stem cell transplantation (PTCY-haplo-SCT) but was readmitted with dyspnea and ground-glass-opacities of the lungs. Bronchoscopy showed inflammatory changes with no signs of infection. He received steroids but required intubation as his condition deteriorated. In addition to antithymocyte globulin and cyclophosphamide, we administered ruxolitinib but failed to save him. Autopsy findings revealed fibrotic nonspecific interstitial pneumonia (NSIP) without evidence of organizing pneumonia or infection. Thus, we diagnosed idiopathic pneumonia syndrome (IPS). As far as our knowledge, this is the first case of IPS with NSIP histology after PTCY-haplo-SCT.

**Key words:** idiopathic pneumonia syndrome, ruxolitinib, post-transplant cyclophosphamide-based haploidentical stem cell transplantation, nonspecific interstitial pneumonia

Idiopathic pneumonia syndrome (IPS) is a rare but fatal complication after allogeneic hematopoietic stem cell transplantation (allo-SCT) [1]. Post-transplant cyclophosphamide-based haploidentical stem cell transplantation (PTCY-haplo-SCT) has been more frequently performed in patients undergoing allo-SCT from alternative donors due to its safety profile with a low incidence of graft-versus-host disease (GVHD). However, little attention has been paid to post-transplant pulmonary complications [2].

Ruxolitinib, a Janus kinase (JAK) inhibitor, has been approved by the U. S. Food and Drug Administration as an agent for steroid-resistant GVHD and it may be effective for non-infectious post-transplant pulmonary

complications accompanied with GVHD [3-5]. Nevertheless, our patient developed refractory IPS even with ruxolitinib treatment after PTCY-haplo-SCT. Here, we report this case to share that such a serious complication could occur even after PTCY-haplo-SCT.

## Case Presentation

A 69-year-old Japanese man with acute myeloid leukemia (AML) who had received allo-SCT three months ago was admitted to our hospital complaining of a dyspnea during a regular visit in July 2020. He had no allergies but had a history of heavy smoking of about 60 pack-years. As his underlying disease was refractory to induction therapy, we decided to proceed to allo-SCT.

We conducted PTCY-haplo-SCT from the patient's daughter as a donor since there were no human leukocyte antigens (HLA)-matched sibling or unrelated donors. At nine days before the transplantation, there was no ground-glass opacity (GGO) on chest computer tomography (CT). The conditioning regimen was a nonmyeloablative regimen consisting of fludarabine, intravenous busulfan for two days, and total body irradiation (TBI). The patient did not receive lung shielding because the dose of TBI was just 4 Grays (Gy). The GVHD prophylaxis consisted of cyclophosphamide (CY) on days 3 and 4 and mycophenolate mofetil (MMF) plus continuous intravenous tacrolimus (TAC) from day 5 respectively. To minimize the risk of CY-induced cardiomyopathy and the risk of relapse, we reduced the dose of CY from 50 mg/kg for two days as first reported by Johns Hopkins University to 40 mg/kg for two days in accord with the JSCT Haplo16 study conducted by the Japan Study Group for Cell Therapy and Transplantation (JSCT) [6, 7]. The donor source was a peripheral blood stem cell.

The patient developed bacterial pneumonia on day 17 after transplantation, but the symptom resolved after engraftment. A bone marrow examination on day 27 confirmed complete remission, but skin erythema and dry cough appeared during the same period. A skin biopsy enabled a diagnosis of acute GVHD, but its severity was mild, classified as grade II based on the world consensus grading [8]. On day 28 and day 39, CT revealed GGOs newly emerging bilaterally (Fig. 1A-D). We suspected that the affected lung lesions were organizing pneumonia (OP) because some of the GGOs migrated. Indeed, the GGOs regressed after we increased the dose of TAC.

Since the skin erythema with acute GVHD and dry cough also resolved, we did not administer steroids, and he was discharged on day 70. Although skin erythema recurred at a regular visit on day 83, the GGOs further regressed on CT (Fig. 1E,F). Nevertheless, he had to be admitted with an acute respiratory impairment only one week later.

The physical examination at admission showed erythema with itching mainly on the face and limbs, and auscultation revealed late inspiratory crackles in the basal dorsal lung lesion bilaterally. A complete blood count showed mild thrombocytopenia and anemia, which was unchanged from a week ago. On the other hand, biochemical examination revealed elevations of

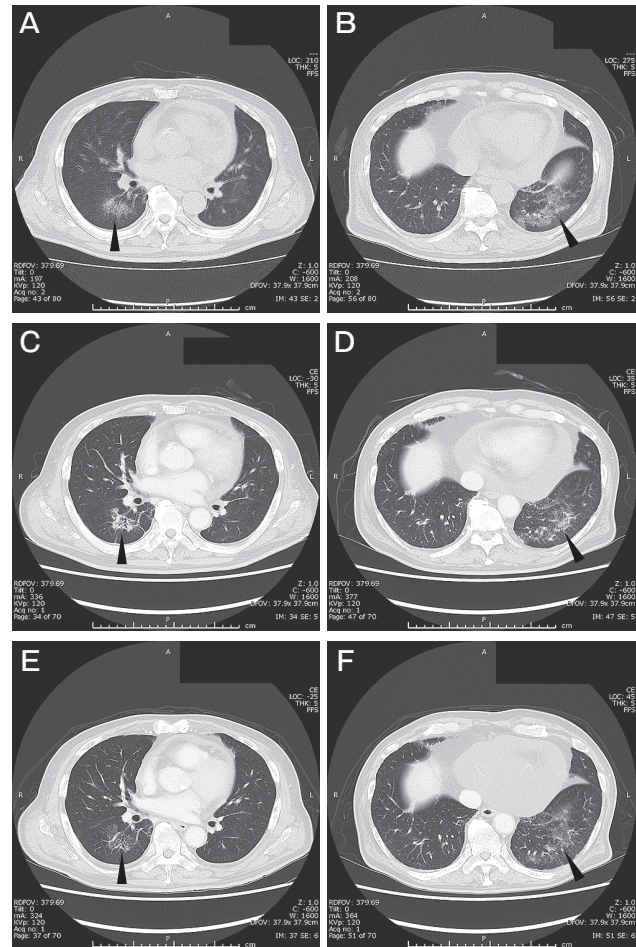


Fig. 1 (A, B): The chest computed tomography (CT) findings on day 28 from post-transplant-cyclophosphamide-based haploidentical stem cell transplantation (PTCY-haplo-SCT), showing ground-glass opacities (GGOs) in both lungs (arrowheads). (C, D): Chest CT findings on day 39, showing enhancement of the GGOs resembling organizing pneumonia (OP) (arrowheads). (E, F): Chest CT findings on day 83, showing regression of GGOs (arrowheads).

lactate dehydrogenase (LDH) and C-reactive protein (CRP) compared to the week ago, suggesting inflammation. In contrast, the cytomegalovirus (CMV) antigen was negative, and a trough level of TAC was 4.2 ng/mL, similar to that observed at the previous week. CT showed re-exacerbation of the GGOs in the lower lungs lobe bilaterally (Fig. 2A, B).

In bronchoscopy, the bronchoalveolar lavage fluid (BAL) with a recovery rate of 48% showed an increased cell number at 510 / $\mu$ L, with an increased lymphocyte ratio of 50%, 84% of which were CD8-positive T cells. On the other hand, a polymerase chain reaction (PCR) test for *Pneumocystis jirovecii* and the galactomannan

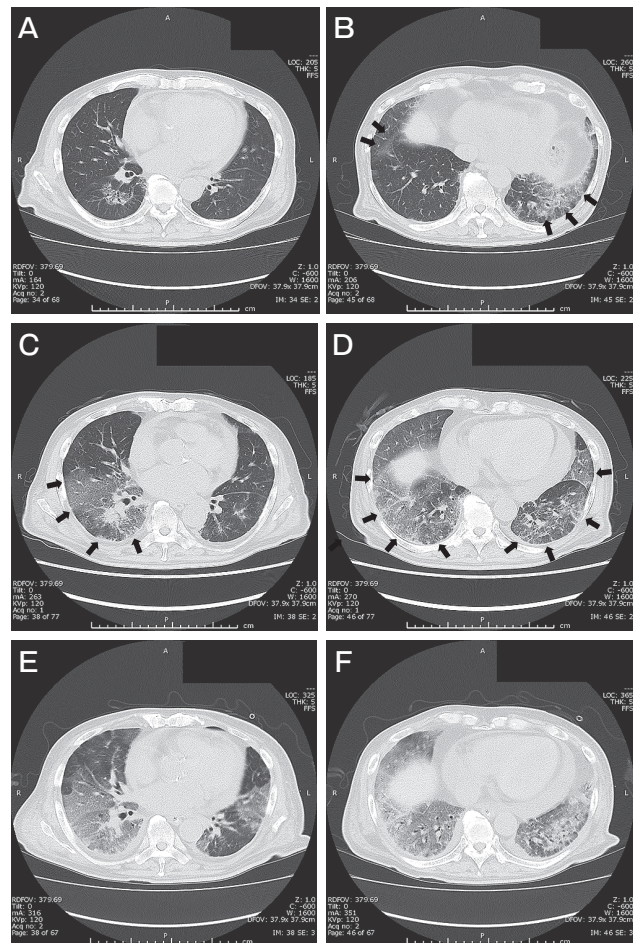
antigen in the BAL were negative.

A transbronchial lung biopsy showed no intraluminal plugs in the alveoli, but edematous hypertrophic alveolar septa and mild lymphocyte infiltration. There were no pathological findings of infection, with negative immunostaining for CMV and Grocott staining. We also performed a loop-mediated isothermal amplification test for severe acute respiratory syndrome coronavirus 2 (SARS-CoV-2), with a negative result.

We diagnosed the re-exacerbation of OP accompanied by acute GVHD because the GGOs had been observed before and re-emerged along with the recurrence of skin erythema. The increased lymphocyte ratio in the BAL also indicated immunological mechanisms. Since the patient was not in respiratory failure yet, we started prednisolone of 30 mg/day on the day after his admission (day 91 after transplantation).

However, he lapsed into rapid respiratory failure in the early morning on the third day of admission (day 92). Laboratory studies showed a further increase in LDH, and CT showed a rapid exacerbation of GGOs (Fig. 2C, D). While there were no signs of heart failure, the value of Krebs von den Lungen-6 (KL-6) had increased to 527 U/mL, suggesting pulmonary fibrosis. We diagnosed refractory OP and performed steroid pulse therapy. We also changed the route of tacrolimus from oral to a continuous intravenous administration. Nevertheless, the patient required intubation as the respiratory distress progressed on the fourth day of admission (day 93).

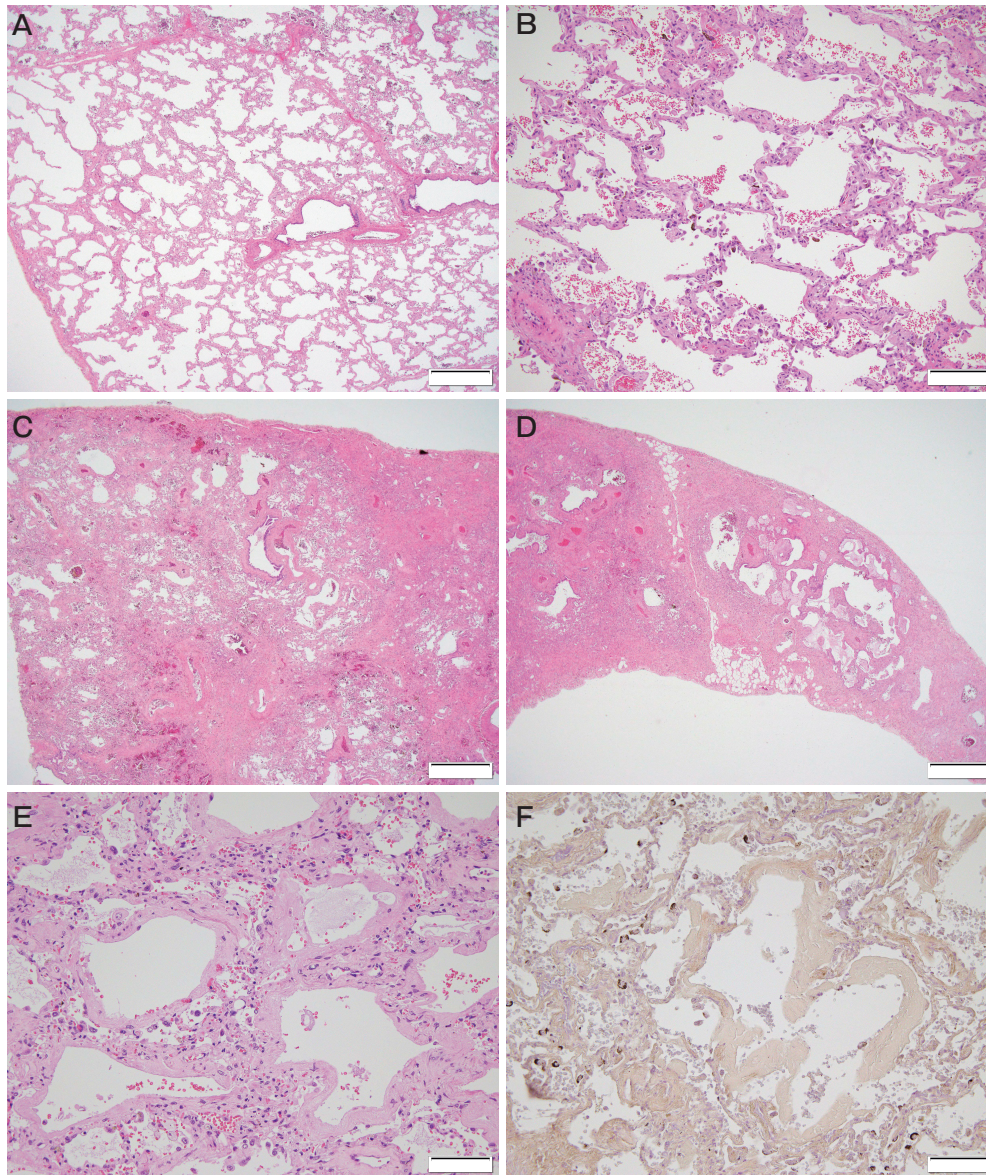
According to the second-line treatment of acute GVHD, we added 1 mg/kg of antithymocyte globulin (ATG), which improved his respiratory condition. We managed to decannulate him as his respiratory condition improved. Nevertheless, oxygen saturation already began to worsen again the day after the decannulation. Since the lymphocytes in the peripheral blood increased as his respiratory condition deteriorated, we considered that suppressing alloreactive T cells was insufficient and re-administered ATG 1 mg/kg and added MMF. However, the CT taken on two days after the re-administration of ATG (day 101) showed further expansion of the GGOs (Fig. 2E, F). As a treatment of acute interstitial pneumonia, we performed pulse therapy with CY, but it had no effect. We considered that refractory acute GVHD participated in the pathogenesis because the patient's respiratory symptoms appeared along with recurrence of the skin erythema. Due to the



**Fig. 2** (A, B): CT on admission, showing re-exacerbation of GGOs in the lower lung lobe bilaterally (arrows). (C, D): Chest CT findings on the third day of admission, showing a further exacerbation of GGOs (arrows). (E, F): Chest CT findings on two days after the re-administration of antithymocyte globulin, showing GGOs spread all over the lungs.

pandemic of COVID-19, mesenchymal stromal cells (MSC) were unavailable. Therefore, we started ruxolitinib 20 mg/day for the GGOs, with the approval of the ethical committee in our institution (No: 203007). Nevertheless, the respiratory condition deteriorated, and we had to re-intubate him. We administered steroid and CY pulse therapy again, but the oxygen saturation declined, and multiorgan failure reared. The patient died on the 33rd day of admission (day 122).

A pathological autopsy of the lungs revealed uniform thickening of alveolar septa throughout the tissue, with little inflammatory cell infiltration. There was a minimal alveolar structural alteration, and those findings were consistent with fibrotic nonspecific interstitial



**Fig. 3** (A, B): Histopathology of the lungs with hematoxylin and eosin (HE) staining, showing uniform thickening of the alveolar septa with minimal structural alteration (magnification). (C, D): Histopathology of the lungs with HE staining, showing heterogeneous fibrosis with alteration of the alveolar structure and a microscopic honeycomb change in the subpleural region. (E, F): Histopathology of the lungs with HE staining and phosphotungstic acid hematoxylin (PTAH) staining, showing diffuse alveolar damage at a predominantly exudative stage with a slight fibrotic stage. Scale bars: A, 1 mm; B, 200  $\mu$ m; C, 1 mm; D, 1 mm; E, 100  $\mu$ m; F, 100  $\mu$ m.

pneumonia (NSIP) (Fig. 3A, B). There were also findings similar to those of usual interstitial pneumonia (UIP) in the subpleural lesion and the margins of the lower lobes, such as spatially heterogeneous fibrosis accompanied by alteration of the alveolar structure and microscopic honeycomb change (Fig. 3C, D). Also, diffuse alveolar damage (DAD) except for the fibrotic stage

was observed in some parts of the lungs (Fig. 3E, F). By contrast, there were no findings suggestive of OP or acute fibrinous OP such as granulomas, Masson body, intraluminal polyps, or fibrin deposition in the alveolar space. Besides, there were no findings of infections.

To summarize, the GGOs that appeared after PTCY-haplo-SCT exacerbated at months after the

engraftment. The histological evaluation revealed mainly NSIP as well as, in some parts, UIP and DAD.

Thus, we diagnosed his non-infectious pulmonary complication as IPS, according to the National Heart, Lung, and Blood Institute consensus definition, rather than OP or peri-engraftment respiratory distress syndrome [1].

## Discussion

IPS is one of the non-infectious post-transplant pulmonary complications, which is defined by the following criteria: (1) widespread alveolar injury, (2) absence of a lower respiratory tract infection, and (3) absence of pulmonary disorder due to cardiac dysfunction, acute renal failure, or iatrogenic overload [1]. IPS typically develops within 100 days, especially within one month after allo-SCT [1,9-11]. Known risk factors of IPS include myeloablative conditioning, TBI, acute GVHD, older age, and primary diseases such as AML and myelodysplastic syndrome [1,9,11].

The above-mentioned clinical features suggest that not only direct pulmonary damage from conditioning such as TBI, but also immune-mediated damage including GVHD, could lead to the onset of IPS. In animal models, researchers demonstrated that several humoral factors including tumor necrosis factor- $\alpha$  (TNF- $\alpha$ ), lipopolysaccharides (LPS), chemokines, and oxidative stress can affect donor-derived T cells and antigen-presenting cells, causing IPS [1].

In our patient's case, we speculate that bacterial pneumonia after the allo-SCT could have caused a high amount of LPS and chemokines release, which could have raised the risk of IPS. Besides, the use of TBI without lung shielding might have contributed to the development of IPS, as lung shielding during irradiation is reported to lower the IPS risk [11].

So far, all IPS that received histological evaluation are cases with non-PTCY-haplo-SCT, and DAD dominates most of the pathological findings, including 2 cases in Japan. [12-16]. We could not find a similar report in PubMed using the key phrases "idiopathic pneumonia syndrome", "nonspecific interstitial pneumonia", and "hematopoietic transplantation".

Meanwhile, PTCY-haplo-SCT generally suppresses alloreactive immune reactions while preserving normal hematopoiesis since activated alloreactive T cells are generally fragile to CY due to having little aldehyde

dehydrogenase (ALDH), which converts aldophosphamide, an active metabolite of CY, into an inactive metabolite carboxycyclophosphamide, whereas regulatory T cells (Tregs) and hematopoietic stem cells are resistant to CY because they are rich in ALDH [2]. In one clinical trial in Japan, the incidence of grade III-IV acute GVHD was only 5% after PTCY-haploidentical peripheral blood stem cell transplantation with a reduced-intensity conditioning regimen [17]. A meta-analysis also showed that PTCY-haplo-SCT was associated with a lower rate of GVHD compared with SCT from unrelated donors [18].

Thus, the most interesting point of this case is that severe IPS with rare histology developed after PTCY-haplo-SCT, without severe GVHD.

There are two theoretical reasons to consider regarding this patient's development of IPS.

First, alloreactive T cells targeting pulmonary tissues had not might not have been depleted sufficiently since we reduced the dose of CY and used peripheral blood stem cell as a donor source.

A prospective study with a low-dose PTCY (25 mg/kg for one day) demonstrated that no less than 33% of the patients developed grade III-IV GVHD [19]. Furthermore, a meta-analysis reported an increase in immune-related complications such as GVHD when peripheral blood stem cells, with a large number of activated lymphocytes, were used as a donor source compared to bone marrow [20]. Hence, CY 40 mg/kg for two days with peripheral blood stem cell in our case was enough to prevent severe acute GVHD but was possibly insufficient to deplete alloreactive T cells causing the IPS.

Second, Tregs restraining pulmonary inflammation might have been specifically depleted, after the PTCY-haplo-SCT.

C-C motif chemokine ligand 2 (CCL2), also called monocyte chemoattractant protein 1 (MCP1), is a chemokine that is released from lung tissue with inflammation [1]. CCL2 had been thought to develop pulmonary injury by recruiting T cells expressing C-C motif chemokine receptor 2 (CCR2) [1,21]. Meanwhile, recent studies have shown that CD4+ Forkhead box P3 (FoxP3)+Tregs expressing CCR2 strongly suppress inflammation and fibrosis in the lungs [22,23]. Furthermore, these Tregs expressing CCR2 are highly sensitive to CY [24].

Therefore, we infer that, in our case, Tregs express-

ing CCR2 were selectively depleted by PTCY, whereas bacterial pneumonia after allo-SCT drove CCL2 expression in lung tissue, which resulted in alloreactive T cells recruitment to lung tissue without suppression by the Tregs to develop fatal IPS. Since the expression of CCL2 of the lungs is enhanced in patients with NSIP or UIP, our patient's lung histology supports the above-mentioned hypothesis [25, 26].

There is also room for improvement in the treatment of IPS. The efficacy of steroids as an initial treatment for IPS is limited, and the mortality of IPS after one month is around 70% [1]. TNF- $\alpha$  inhibitors were expected as a second-line treatment, but a randomized controlled trial evaluating a TNF- $\alpha$  inhibitor for the treatment of IPS within 180 days after allo-SCT has failed to prove a statistically significant efficacy [27].

In our case, we administered ruxolitinib because the GGOs occurred along with skin GVHD. We presumed ruxolitinib to be effective against the lung lesions because ruxolitinib not only inhibits several inflammatory cytokines, including TNF- $\alpha$ , but also increases the number of Tregs [28].

There are some reports of ruxolitinib usage for non-infectious pulmonary complications after allo-SCT, especially obstructive bronchiolitis, which described some effects such as an improvement of respiratory function or a reduction of systemic steroids [29, 30]. However, we saw little pharmaceutical benefit in our patient.

Ruxolitinib could not restrain lung fibrosis sufficiently, partly because ruxolitinib mainly inhibits tracheal epithelial cells from releasing inflammatory cytokines, whereas it has a minor inhibitory effect on fibroblasts in lung tissue from proliferation and activation [31]. Additionally, ruxolitinib is known to down-regulate the CCR2 expression on cells from patients with primary myelofibrosis [32]. Ruxolitinib increases the number of Tregs but may simultaneously suppress the expression of CCR2, which might have made it difficult for Tregs to migrate into the lung tissue in our case.

However, of the two cases of IPS after PTCY-haplo-SCT, one patient with IPS was effectively treated with ruxolitinib [33, 34]. One reason for the difference in clinical course between our case and the previous report is that the dose of PTCY was not reduced in the previous report, which could deplete allogeneic reactive T cells to some extent. In addition, the previous patient

did not be contracted bacterial pneumonia before the IPS, and the amount of CCL2 in the lung could be smaller. Furthermore, concurrent administration of CY and ruxolitinib as a treatment for our patient's IPS might lead to further depletion of CCR2-positive Tregs and make the poorer prognosis.

Therefore, when clinicians are obliged to add treatment for refractory IPS after PTCY-haplo-SCT in addition to steroids and ruxolitinib, the use of MSC that increase CCR2-positive Tregs may be preferred over CY [23].

In conclusion, we encountered a patient with fatal IPS with rare histology of NSIP, which was refractory to ruxolitinib after PTCY-haplo-SCT.

Agents only to increase the number of Tregs, such as ruxolitinib, are not necessarily effective to IPS after PTCY-haplo-SCT, and we also need an approach to immigrate Tregs to the lung.

## References

1. Panoskaltsis-Mortari A, Griese M, Madtes DK, Belperio JA, Haddad IY, Folz RJ and Cooke KR: An Official American Thoracic Society Research Statement: Noninfectious Lung Injury after Hematopoietic Stem Cell Transplantation: Idiopathic Pneumonia Syndrome. *Am J Respir Crit Care Med* (2011) 183: 1262–1279.
2. Al-Homsi AS, Roy TS, Cole K, Feng Y and Duffner U: Post-transplant high-dose cyclophosphamide for the prevention of graft-versus-host disease. *Biol Blood Marrow Transplant* (2015) 21: 604–611.
3. Zeiser R, von Bubnoff N, Butler J, Mohty M, Niederwieser D, Or R, Szer J, Wagner EM, Uckerman T, Mahuzier B, Xu J, Wilke C, Gandhi KK, Socié G and REACH2 Trial Group: Ruxolitinib for Glucocorticoid-Refractory Acute Graft-versus-Host Disease. *N Engl J Med* (2020) 382: 1800–1810.
4. Zeiser R, Polverelli N, Ram R, Hashmi SK, Chakraverty R, Middeke JM, Musso M, Giebel S, Uzay A, Langmuir P, Hollaender N, Gowda M, Stefanelli T, Lee SJ, Teshima T, Locatelli F and REACH3 Investigators: Ruxolitinib for Glucocorticoid-Refractory Chronic Graft-versus-Host Disease. *N Engl J Med* (2021) 385: 228–238.
5. Streiler C, Shaikh F, Davis C, Abhyankar S and Brownback KR: Ruxolitinib is an effective steroid sparing agent in bronchiolitis obliterans due to chronic graft-versus-host-disease. *Bone Marrow Transplant* (2020) 55: 1194–1196.
6. Luznik L, O'Donnell PV, Symons HJ, Chen AR, Leffell MS, Zahurak M, Gooley TA, Piantadosi S, Kaup M, Ambinder RF, Huff CA, Matsui W, Bolaños-Meade J, Borrello I, Powell JD, Harrington E, Warnock S, Flowers M, Brodsky RA, Sandmaier BM, Storb RF, Jones RJ and Fuchs EJ: HLA-haploidentical bone marrow transplantation for hematologic malignancies using nonmyeloablative conditioning and high-dose, post-transplantation cyclophosphamide. *Biol Blood Marrow Transplant* (2008) 14: 641–650.
7. Sugita J, Ota S, Kamimura T, Omoto E, Kuroha T, Matsuo K, Akashi K, Taniguchi S, Harada M and Teshima T: The Impact of Reduced Dose of Posttransplant Cyclophosphamide in HLA-Haploidentical Peripheral Blood Stem Cell Transplantation. *Biol Blood Marrow Transplant* (2019) 25: S57–S58.
8. Przepiorka D, Weisdorf D, Martin P, Klingemann HG, Beatty P, Hows J, and Thomas ED: 1994 Consensus Conference on Acute GVHD Grading.

- Bone Marrow Transplant (1995) 15: 825–828.
9. Haider S, Durairajan N and Soubani AO: Noninfectious pulmonary complications of haematopoietic stem cell transplantation. *Eur Respir Rev* (2020) 29: 190119.
  10. Wenger DS, Triplette M, Crothers K, Cheng G, Hill JA, Milano F, Shahrir S, Schoch G, and Vusse LKV: Incidence, Risk Factors, and Outcomes of Idiopathic Pneumonia Syndrome after Allogeneic Hematopoietic Cell Transplantation. *Biol Blood Marrow* (2020) Transplant 26: 413–420.
  11. Vogel J, Hui S, Hua C, Dusenbery K, Rassiah P, Kalapurakal J, Constine L and Esiashvili N: Pulmonary Toxicity After Total Body Irradiation - Critical Review of the Literature and Recommendations for Toxicity Reporting. *Front Oncol* (2021) 11: 708906.
  12. Yousem SA: The histological spectrum of pulmonary graft-versus-host disease in bone marrow transplant recipients. *Hum Pathol* (1995) 26: 668–675.
  13. Yadav H, Nolan ME, Bohman JK, Cartin-Ceba R, Peters SG, Hogan WJ, Gajic O, and Kor DJ: Epidemiology of Acute Respiratory Distress Syndrome Following Hematopoietic Stem Cell Transplantation. *Crit Care Med* (2016) 44: 1082–1090.
  14. Ahya YN: Noninfectious Acute Lung Injury Syndromes Early After Hematopoietic Stem Cell Transplantation. *Clin Chest Med* (2017) 38: 595–606.
  15. Nakamura Y, Mitani N, Ishii A, Hayashi S, Yujiri T, Ikeda E and Tanizawa Y: Idiopathic pneumonia syndrome with thrombotic microangiopathy-related changes after allogeneic hematopoietic stem cell transplantation. *Int J Hematol* (2013) 98: 496–498.
  16. Koinuma T, Nunomiya S, Wada M, Koyama K and Suzuki T: Concurrent treatment with a tumor necrosis factor-alpha inhibitor and veno-venous extracorporeal membrane oxygenation in a post-hematopoietic stem cell transplant patient with idiopathic pneumonia syndrome: a case report. *J Intensive Care* (2014) 2: 48.
  17. Sugita J, Kagaya Y, Miyamoto T, Shibasaki Y, Nagafuji K, Ota S, Furukawa T, Nara M, Akashi K, Taniguchi S, Harada M, Matsuo K, Teshima T and Japan Study Group for Cell Therapy and Transplantation (JSCT): Bone Marrow Transplant (2019) 54: 432–441.
  18. Arcuri LJ, Aguiar MTM, Ribeiro AAF and Pacheco AGF: Haploidentical Transplantation with Post-Transplant Cyclophosphamide versus Unrelated Donor Hematopoietic Stem Cell Transplantation: A Systematic Review and Meta-Analysis. *Biol Blood Marrow Transplant* (2019) 25: 2422–2430.
  19. Nakamae H, Koh H, Katayama T, Nishimoto M, Hayashi Y, Nakashima Y, Nakane T, Nakamae M, Hirose A and Hino M: HLA haploidentical peripheral blood stem cell transplantation using reduced dose of post-transplantation cyclophosphamide for poor-prognosis or refractory leukemia and myelodysplastic syndrome. *Exp Hematol* (2015) 43: 921–929.
  20. Arcuri LJ, Hamerschlag N, Rocha V, Bonfim C and Kerbauy MN: Outcomes after Haploidentical Hematopoietic Cell Transplantation with Post-Transplantation Cyclophosphamide: A Systematic Review and Meta-Analysis Comparing Myeloablative with Reduced-Intensity Conditioning Regimens and Bone Marrow with Peripheral Blood Stem Cell Grafts. *Transplant Cell Ther* (2021) 27: 782.e1–782.e7.
  21. Fowler KA, Jania CM, Tilley SL, Panoskaltis-Mortari A, Baldwin AS, Serody JS and Coghill JM: Targeting the Canonical Nuclear Factor- $\kappa$ B Pathway with a High-Potency IKK2 Inhibitor Improves Outcomes in a Mouse Model of Idiopathic Pneumonia Syndrome. *Biol Blood Marrow Transplant* (2017) 23: 569–580.
  22. Milger K, Yu Yingyan, Brudy E, Irmiler M, Skapenko A, Mayinger M, Lehmann M, Beckers J, Reichenberger F, Behr J, Eickelberg O, Königshoff M, and Krauss-Etschmann S: Pulmonary CCR2+CD4+T cells are immune regulatory and attenuate lung fibrosis development. *Thorax* (2017) 72: 1007–1020.
  23. Cao M, Liu H, Dong Y, Liu W, Yu Zhengyu, Wang Q, Wang Q, Liang Z, Li Y and Ren H: Mesenchymal stem cells alleviate idiopathic pneumonia syndrome by modulating T cell function through CCR2-CCL2 axis. *Stem Cell Res Ther* (2021) 12: 378.
  24. Loyher P, Rochefort J, Baudesson de Charville C, Hamon P, Lescaillie G, Bertolus C, Guillot-Delost M, Krummel MF, Lemoine FM, Combadière C and Boissonnas A: CCR2 Influences T Regulatory Cell Migration to Tumors and Serves as a Biomarker of Cyclophosphamide Sensitivity. *Cancer Res* (2016) 76: 6483–6494.
  25. Yoshioka S, Mukae H, Sugiyama K, Kakugawa T, Sakamoto N, Nakayama S, Abe K, Fujii T, Kadota J and Kohno S: High-BAL fluid concentrations of RANTES in nonspecific interstitial pneumonia compared with usual interstitial pneumonia. *Respir Med* (2004) 98: 945–951.
  26. Greiffo FR, Viteri-Alvarez V, Frankenberger M, Dietel D, Ortega-Gomez A, Lee JS, Hilgendorff A, Behr J, Soehnlein O, Eickelberg O and Fernandez IE: CX3CR1-fractalkine axis drives kinetic changes of monocytes in fibrotic interstitial lung diseases. *Eur Respir J* (2020) 55: 1900460.
  27. Yanik GA, Horowitz MM, Weisdorf DJ, Logan BR, Ho VT, Soiffer RJ, Carter SL, Wu J, Wingard JR, Difronzo NL, Ferrara JL, Giralt S, Madtes DK, Drexler R, White ES and Cooke KR: Randomized, double-blind, placebo-controlled trial of soluble tumor necrosis factor receptor: etanercept for the treatment of idiopathic pneumonia syndrome after allogeneic stem cell transplantation: blood and marrow transplant clinical trials network protocol. *Biol Blood Marrow Transplant* (2014) 20: 858–864.
  28. Silvia S, Nimitha RM, Michael B, Schmitt-Graeff A, Chen S, Mueller T, Verbeek M, Fischer J, Otten V, Schmickl M, Maas-Bauer K, Finke J, Peschel C, Duyster J, Poeck H, Zeiser R and von Bubnoff N: Activity of therapeutic JAK 1/2 blockade in graft-versus-host disease. *Blood* (2014) 123: 3832–3842.
  29. Zhao Y, OuYang G, Shi J, Luo Y, Tan Y, Yu J, Fu H, Lai X, Liu L and Huang H: Salvage Therapy With Low-Dose Ruxolitinib Leads to a Significant Improvement in Bronchiolitis Obliterans Syndrome in Patients With cGVHD After Allogeneic Hematopoietic Stem Cell Transplantation. *Front Pharmacol* (2021) 12: 668825.
  30. Schoettler M, Duncan C, Lehmann L, Furutani E, Subramaniam M and Margossian S: Ruxolitinib is an effective steroid sparing agent in children with steroid refractory/dependent bronchiolitis obliterans syndrome after allogeneic hematopoietic cell transplantation. *Bone Marrow Transplant* (2019) 54: 1158–1160.
  31. Singer JW, Al-Fayoumi S, Taylor J, Velichko S and O'Mahony A: Comparative phenotypic profiling of the JAK2 inhibitors ruxolitinib, fedratinib, momelotinib, and pacritinib reveals distinct mechanistic signatures. *PLoS One* (2019) 14: e0222944.
  32. Masselli E, Carubbi C, Pozzi G, Percepe A, Campanelli R, Villani L, Gobbi G, Bonomini S, Roti G, Rosti V, Massa M, Barosi G and Vitale M: Impact of the rs1024611 Polymorphism of CCL2 on the Pathophysiology and Outcome of Primary Myelofibrosis. *Cancers (Basel)* (2021) 13: 2552.
  33. Tomomasa D, Isoda T, Mitsuiki N, Yamashita M, Morishita A, Tomoda T, Okano T, Endo A, Kamiya T, Yanagimachi M, Imai K, Kanegane H, Takagi M and Morio T: Successful ruxolitinib administration for a patient with steroid-refractory idiopathic pneumonia syndrome following hematopoietic stem cell transplantation: A case report and literature review. *Clin Case Rep* (2021) 9: e05242.
  34. Liu W, Chen W, Fang L and Chen R: Idiopathic Pneumonia Syndrome and Thrombotic Microangiopathy Following Nonmyeloablative Haploidentical Peripheral Blood Stem Cell Transplantation and Posttransplant Cyclophosphamide: A Case Report. *Medicine (Baltimore)* (2015) 94: e1200.