

C3 Glomerulonephritis associated with Anti-complement Factor H Autoantibodies in an Adolescent Male: A Case Report

HyeSun Hyun, M.D.^{1*}
Hee Gyung Kang, M.D., Ph.D.^{2,4}
UiJu Cho, M.D., Ph.D.³
Il-Soo Ha, M.D., Ph.D.^{2,4}
Hae Il Cheong, M.D., Ph.D.^{2,4*}

¹Department of Pediatrics, St. Vincent's Hospital, The Catholic University of Korea, Suwon, Korea;

²Department of Pediatrics, Seoul National University Children's Hospital, Seoul, Korea; ³Department of Pathology, St. Vincent's Hospital, The Catholic University of Korea, Suwon, Korea; ⁴Research Coordination Center for Rare Diseases, Seoul National University Hospital, Seoul, Korea

*Both authors contributed equally to the work.

Corresponding author: Hae Il Cheong, M.D., Ph.D.

Department of Pediatrics Seoul National University Children's Hospital 101 Daehak-ro, Jongno-gu, Seoul 03080, Korea

Tel: +82-2-2072-2810

Fax: +82-2-2072-2810

E-mail: Cheonghi@snu.ac.kr

Corresponding author: HyeSun Hyun, MD
Department of Pediatrics St. Vincent's Hospital, The Catholic University of Korea, Seoul, 93 Jungbu-daero, Paladal-gu, Suwon, gyeonggi-do 16247

Tel: +82-31-249-7320

Fax: +82-31-257-9111

E-mail: inthy@naver.com

Received: 31 December 2020

Revised: 19 February 2021

Accepted: 19 March 2021

This is an open-access article distributed under the terms of the Creative Commons Attribution Non-Commercial License (<http://creativecommons.org/licenses/by-nc/4.0/>) which permits unrestricted non-commercial use, distribution, and reproduction in any medium, provided the original work is properly cited.

Copyright © 2021 The Korean Society of Pediatric Nephrology

C3 glomerulonephritis (C3GN), a rare condition associated with dysregulation of the alternative pathway of the complement system, is histopathologically characterized by isolated or dominant C3 deposition in the renal glomeruli. We report a case of C3GN associated with anti-complement factor H (CFH) autoantibodies and CHF-related protein deficiency in an adolescent male. A 16-year-old adolescent male was admitted to a hospital with a 1-month history of generalized edema prior to presentation. Persistent microscopic hematuria and low serum C3 levels were incidentally detected at 7 and 10 years of age, respectively. Laboratory test results revealed hypoalbuminemia, nephrotic-range proteinuria, microscopic hematuria, and normal serum creatinine levels. The serum C3 and C4 levels were 17 mg/dL (normal 80–150 mg/dL) and 22 mg/mL (17–40 mg/mL), respectively. Renal biopsy showed typical features of C3GN. Further investigations revealed positive results on plasma anti-CFH autoantibody testing and a homozygous deletion of *CFHR1* and *CFHR3*, which encode CFH-related proteins 1 and 3, respectively. Proteinuria persisted despite treatment with intravenous methylprednisolone, mycophenolate mofetil, and angiotensin-receptor blocker; however, his renal function remained stable. In conclusion, anti-CFH autoantibodies serve as important contributors to C3GN. This is the first case report that describes C3GN in an adolescent Korean male with anti-CFH autoantibodies and homozygous *CFHR1* and *CFHR3* deletion.

Key words: C3 glomerulonephritis, Hypocomplementemia, Anti-complement factor H autoantibodies, Complement factor H related proteins

Introduction

Dysregulation of the alternative pathway of the complement system causes various kidney diseases; C3 glomerulopathy (C3G) and atypical hemolytic uremic syndrome (aHUS) represent such complement-driven glomerular diseases¹.

C3G, a relatively new diagnostic category, is characterized by isolated or predominant glomerular C3 deposition^{1,2}. C3G affects both children and adults who typically show persistent hematuria with or without proteinuria and progressive renal failure. C3G may present with a wide spectrum of clinical manifestations. Based on renal biopsy findings, C3G is categorized into dense deposit disease (DDD) and C3 glomerulonephritis (C3GN). DDD,

formerly referred to as membranoproliferative glomerulonephritis (MPGN) type II, is characterized by dense osmophilic intramembranous glomerular deposits, and C3GN is characterized by predominantly C3 deposits in the mesangial, subendothelial, and subepithelial glomerular areas².

Several inherited and acquired abnormalities cause C3G. Genetic causes include pathogenetic mutations in complement-related genes, such as *C3*, *CFB*, *CFH*, *CFI*, and *CFHR 5*, which encode C3, complement factor B (CFB), complement factor H (CFH), complement factor I, and CFH-related protein 5, respectively. Acquired abnormalities are associated with development of autoantibodies against complement proteins and complexes; for example, C3 nephritic factor (C3NeF) that targets C3 convertase, C5NeF that targets C5 convertase, anti-CFH autoantibodies, and anti-CFB autoantibodies³.

CFH is the main plasma regulatory protein of the alternative pathway of the complement system, and a significant percentage of patients with aHUS, particularly children develop anti-CFH autoantibodies, which were first implicated as contributors to aHUS in 2005^{4,5}. Anti-CFH autoantibodies mainly develop secondary to a homozygous deletion of *CFHR1* and *CFHR3* encoding *CFHR1* and *CFHR3*, respectively^{6,7}. Anti-CFH autoantibodies also occur in a few patients with C3G. However, unlike patients with aHUS, those with C3G and anti-CFH autoantibodies do not show *CFHR1* and *CFHR3* deficiency⁸.

Anti-CFH-associated C3G is rare; Durey et al.⁹ reported 23 cases, including 6 pediatric cases in 2016. We report a case of C3GN associated with anti-CFH autoantibodies and homozygous *CFHR1/CFHR3* deletion together with a literature review.

Case report

A 16-year-old adolescent male without a family history of renal disease presented to a local hospital with a 1-month history of generalized edema. Asymptomatic microscopic hematuria was first detected at 7 years of age. At 10 years of age, he developed cervical lymphadenitis with fever; however, serum creatinine level was normal (0.6 mg/dL), and the C3 level was 31 mg/dL (normal range 80–150 mg/dL). His serum hemoglobin level was 12 g/dL, platelet count was $241 \times 10^9/L$. Urinalysis showed 4+ proteinuria and microscopic hematuria. His fever defervesced, and proteinuria decreased to 1+ with symptomatic treatment, on the second day of hospitalization. Following symptomatic improvement, he was discharged on the fourth day of admission and experienced no subjective symptoms post-discharge; however, low serum C3 levels and proteinuria with microscopic hematuria persisted over 3 years. Unfortunately, the patient was lost to follow-up for 4 years.

At 16 years of age, the patient noticed generalized edema with 3-kg weight gain over a month. His blood pressure was 120/80 mmHg, and body temperature was 36.8°C. He was 170 cm tall and weighed 58 kg. Laboratory test results showed white blood cells 9,580/ μ L, platelets $387 \times 10^9/L$, serum hemoglobin level 14 g/dL, serum proteins 3.9 g/dL, albumin 1.9 g/dL, creatinine 0.6 mg/dL, C3 was 17 mg/dL, and C4 was 22 mg/mL (normal range 17–40 mg/mL). Serum immunoglobulin (Ig) G, A, and M levels were normal. Urinalysis showed 4+ proteinuria, microscopic hematuria, and 24-hour urinary protein excretion of 3.7 g/day. Renal ultrasonography revealed increased renal parenchymal echogenicity bilaterally. Renal biopsy was performed (Fig. 1); light microscopy examination of the biopsy

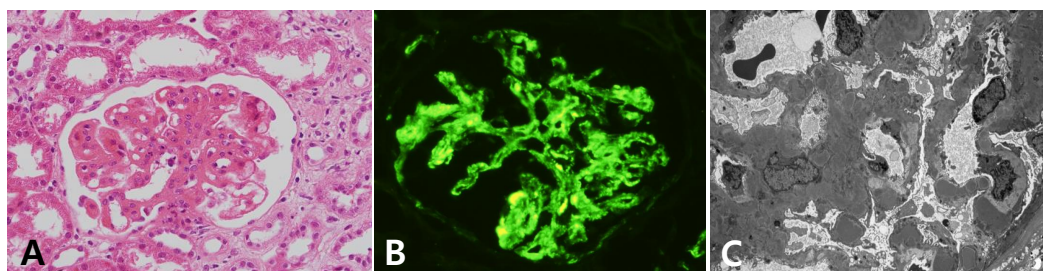


Fig. 1. Kidney biopsy findings of the patient. Light microscopy examination (A) of the renal biopsy specimen revealed lobular accentuation of the glomerulus, mesangial matrix expansion, and focal tram track appearance of the glomerular capillary walls. Immunofluorescence microscopy (B) showed predominant deposition of C3 in the mesangium and peripheral capillary walls. Electron microscopy (C) revealed electron-dense deposits in subendothelial and mesangial areas.

specimen revealed lobular accentuation of the glomeruli, mesangial matrix expansion, and a tram-track appearance of the glomerular capillary walls. The glomerular sclerosis were noted in 4 of the 30 glomeruli. Thrombus or fragmented red blood cells within glomeruli, in subendothelial areas, and in the mesangium and endothelial swelling or denudation were not seen. Immunofluorescence microscopy revealed C3 (4+) and IgM (1+) deposits in the mesangium and the capillary walls. Electron microscopy revealed subendothelial and mesangial electron-dense deposits. These histopathological findings were consistent with those observed in C3GN, and the patient received intravenous methylprednisolone, followed by oral prednisolone, mycophenolate, and an angiotensin-receptor blocker. Proteinuria persisted despite treatment; however, renal function remained stable throughout follow-up (Table 1).

Western blot analysis performed at 18 years of age revealed normal CFH levels with complete lack of plasma *CFHR1* (Fig. 2). Multiplex ligation-dependent probe amplification assay using a commercial kit (SALSA MLPA Probemix P236-A3 ARMD mix-1, MRC-Holland, Amsterdam, The Netherlands) confirmed homozygous *CFHR1* and *CFHR3* deletion. Plasma anti-CFH IgG testing using a commercially available ELISA kit (CFH IgG ELISA kit, Abnova, Heidelberg, Germany) revealed a titer higher than that observed in healthy subjects. However, the titer was lower than that in patients with anti-CFH-associated aHUS, which may be attributed to decreased anti-CFH autoantibody production secondary to chronic immunosuppression (Table 2).

Table 1. Serial laboratory findings of the patient

Assay	Age of the patient (years)						
	10*	11	12	16 [†]	17	18	19
Hemoglobin (g/dL)	12	n.a.	13.6	14	14.1	15.8	14.4
Platelet ($\times 10^9/L$)	241	n.a.	260	387	179	343	328
Albumin (g/dL)	3.2	n.a.	3.9	1.9	3.5	2.7	2.8
Creatinine (mg/dL)	0.6	0.6	0.6	0.6	0.7	0.6	0.7
C3 (mg/dL) [‡]	31	11	12.4	17	12	17	n.a.
Urine protein	4+	1+	2+	3+	4+	4+	4+
Urine RBC (/HPF)	many	10–29	10–29	many	many	10–29	10–29
Spot urine protein/creatinine (mg/mg)	n.a.	n.a.	n.a.	3.4	3	3.4	2.3

*When the patient had cervical lymphadenitis; [†]When the patient had glomerulonephritis; [‡]Reference range 80–150 mg/dL. n.a., not available.

The patient was diagnosed with C3GN associated with anti-CFH autoantibodies and homozygous *CFHR1/CFHR3* deletion.

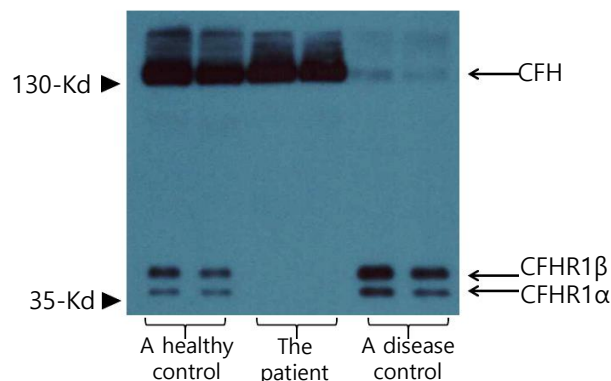


Fig. 2. Western blot analysis using a commercial polyclonal anti-human complement factor H (CFH) antibody shows three bands in the plasma of a normal control, an upper thick band of CFH and two lower bands of CFH-related proteins 1 α (CFHR1 α) and 1 β (CFHR1 β). While the concentration of CFH in the patient's plasma was normal, the lower two bands were completely missing, which suggests a total deficiency of CFHR1 protein. The disease control was a patient with biallelic mutations in CFH and a near-total deficiency of plasma CFH protein.

Table 2. Titers of plasma anti-CFH autoantibodies by ELISA

	Arbitrary unit
Healthy control 1	-980
Healthy control 2	-291
The patient	1,640
Disease control 1*	17,800
Disease control 2*	17,709

*Patients with atypical hemolytic uremic syndrome in association with anti-CFH autoantibodies and homozygous deletions of *CFHR1* and *CFHR3*

Discussion

MPGN was previously classified into types I, II, and III based on histopathological and ultrastructural findings. MPGN types I and II (also known as DDD) are characterized by subendothelial as well as mesangial deposits and highly osmophilic electron-dense intramembranous deposits, respectively. MPGN type III is typically associated with both subendothelial and subepithelial deposits¹⁰. A consensus meeting of renal pathologists and nephrologists held in 2015 to establish an etiology/pathogenesis-based system for classification and diagnosis of GN, recommended a new classification of GN into the following pathogenetic types: immune-complex GN, pauci-immune GN, antiglomerular basement membrane GN, monoclonal immunoglobulin GN, and C3G¹¹. Accordingly, MPGN is reclassified into immune complex-mediated MPGN (characterized by immunoglobulin and C3 deposition associated with abnormal activation of the classical complement pathway), and complement-mediated MPGN (defined as C3G characterized by isolated or predominant C3 deposition associated with abnormal activation of the alternative complement pathway)¹⁰. C3G includes DDD and C3GN.

Dysregulation of the alternative complement pathway may occur secondary to genetic mutations in complement-related genes or as an acquired abnormality. Development of autoantibodies, including C3NeF, C5NeF, anti-CFH autoantibodies, and anti-CFB autoantibodies constitutes the most frequent acquired abnormality³. C3NeF, the first described and most commonly observed autoantibody, primarily occurs in patients with DDD but less frequently in patients with C3GN^{10,12}. Anti-CFH autoantibodies, first described in patients with aHUS in 2005, occur in a significant percentage of children with aHUS^{5,6,11} but in only a few patients with C3G^{8,9}. Two large cohort studies of C3G, the Columbia University and the Mayo Clinic cohort have described these autoantibodies^{13,14}.

In the Columbia University cohort study¹³, the prevalence of C3NeF and anti-CFH autoantibodies was 31.0% and 7.1%, respectively among 42 patients with C3GN. Similarly, the Mayo Clinic cohort study¹⁴ reported that the prevalence of C3NeF and other autoantibodies (C5NeF, C4NeF, anti-CFH autoantibodies, and anti-CFB autoantibodies) was 37.8% and 16.7%, respectively among patients

with C3GN who showed negative results for monoclonal gammopathy (which commonly causes C3G in adults). The Columbia University cohort included children (31.5%) and adults,¹⁵ whereas the Mayo Clinic cohort included mainly adults¹⁴.

CFH, the key regulator of the alternative pathway of the complement system, controls complement levels in both the fluid phase and on cell surfaces¹⁵. The C-terminal region of CFH is associated with surface recognition, whereas the N-terminal region promotes cofactor and decay-accelerating activity. C3G is associated with defective fluid phase C3 regulation with genetic mutations in the N-terminal region of CFH, and autoantibodies show N-terminal specificity. In contrast, aHUS is associated with uncontrolled complement activation on endothelial cells, and mutations and autoantibodies affect the C-terminal region of CFH¹⁵. Moreover, anti-CFH autoantibodies in patients with aHUS are primarily associated with homozygous *CFHR1* and *CFHR3* deletion, although the mechanism by which *CFHR1/CFHR3* deficiency promotes anti-CFH antibody production is unknown^{6,7,9}.

In contrast to patients with aHUS, those with C3G and anti-CFH autoantibodies do not show *CFHR1* and *CFHR3* deficiencies⁸. Our case report is the first to describe C3GN associated with anti-CFH autoantibodies and homozygous *CFHR1/CFHR3* deletion. In this patient, the *CFHR1/CFHR3* deletion led to develop anti-CFH antibody that has different properties from those develop in patients with aHUS. Further studies are needed on the association of anti-CFH autoantibodies and *CFHR1/CFHR3* deletion in C3G patients

A French study⁸ reported that the mean anti-CFH autoantibody titer in patients with C3G was comparable with that in patients with aHUS. Despite similar titers, the avidity of anti-CFH autoantibodies in C3G patients was lower than those of aHUS patients. Lower avidity of antibody binding to CFH in patients with anti-CFH-associated C3G than in patients with anti-CFH-associated aHUS may contribute to lower immune-complex generation rates^{8,9}. In our patient, anti-CFH autoantibodies were not measured during the acute stage of the illness but only 2 years after disease onset. Therefore, the relatively lower titer of anti-CFH autoantibodies in our patient may reflect decreased anti-CFH antibody production secondary to steroid and

immunosuppressant administration.

Although C3G can present at all ages, it most commonly occurs during late adolescence and early adulthood³. Notably, DDD manifests earlier than C3GN, and C3G shows no sex predilection. Renal manifestations of C3GN include hematuria, hypertension, and commonly nephrotic-range proteinuria. Low C3 levels are observed in approximately 66% of patients, and kidney biopsy is essential for definitive diagnosis. Progression to kidney failure is common, with high recurrence rates after renal transplantation^{3,10}. Our patient had persistent low C3 level since age 10. Our speculation is that the patient already had C3 dysregulation at the age of 10 years when low serum C3 level was first detected. The patient probably had C3 dysregulation before age 10, and cervical lymphadenitis at the age of 10 exacerbated it. It is well-known that nonspecific infections can induce complement activation.

Current treatment recommendations for C3G (based on data from case series and observational studies), include administration of corticosteroids, antiproliferative drugs (cyclophosphamide, mycophenolate mofetil), and monoclonal antibodies (rituximab), which inhibit factors that trigger complement pathway activation. Although eculizumab therapy is deemed useful, few reports have discussed its efficacy in patients with C3G. Owing to limited research in this field, information regarding optimal treatment and prognosis of patients with anti-CFH-mediated C3G is unavailable. In addition to corticosteroids and immunosuppressants, plasma exchanges and B-cell inhibitor administration are considered feasible therapeutic strategies for C3G associated with autoantibodies, including anti-CFH autoantibodies and C3Nef^{4,9}.

In conclusion, we report the first case of C3GN associated with anti-CFH autoantibodies and homozygous *CFHR1/CFHR3* deletion in an adolescent Korean male. This rare case highlights the importance of genetic testing and complement factor assay in patients with persistently low C3 levels.

Acknowledgement

This research was supported by a grant of the Korea Health Technology Research & Development Project

through the Korea Health Industry Development Institute, funded by the Ministry of Health & Welfare, Republic of Korea (grant number: HI18C0013).

Conflicts of interest

No potential conflict of interest relevant to this article was reported.

ORCID iDs

HyeSun Hyun <http://orcid.org/0000-0001-8525-1471>

Hee Gyung Kang <http://orcid.org/0000-0001-8323-5320>

UiJu Cho <http://orcid.org/0000-0002-6229-8418>

Il-Soo Ha <http://orcid.org/0000-0001-5428-6209>

Hae Il Cheong <http://orcid.org/0000-0001-7556-1265>

References

1. Caravaca-Fontán F, Lucientes L, Cavero T, Praga M. Update on C3 glomerulopathy: a complement-mediated disease. *Nephron* 2020;144:272-80.
2. Cook HT, Pickering MC. Histopathology of MPGN and C3 glomerulopathies. *Nat Rev Nephrol* 2015;11:14-22.
3. Ahmad SB, Bomback AS. C3 glomerulopathy: pathogenesis and treatment. *Adv Chronic Kidney Dis* 2020;27:104-10.
4. Dragon-Durey MA, Loirat C, Cloarec S, Macher MA, Blouin J, Nivet H, et al. Anti-factor H autoantibodies associated with atypical hemolytic uremic syndrome. *J Am Soc Nephrol* 2005;16:555-3.
5. Dragon-Durey MA, Sethi SK, Bagga A, Blanc C, Blouin J, Ranchin B, André JL, et al. Clinical features of anti-factor H autoantibody-associated hemolytic uremic syndrome. *J Am Soc Nephrol* 2010; 21:2180-7.
6. Lee BH, Kwak SH, Shin JI, Lee SH, Choi HJ, Kang HG, et al. Atypical hemolytic uremic syndrome associated with complement factor H autoantibodies and *CFHR1/CFHR3* deficiency. *Pediatr Res* 2009;66:336-40.
7. Lee JM, Park YS, Lee JH, Park SJ, Shin JI, Park YH, et al. Atypical hemolytic uremic syndrome: Korean pediatric series. *Pediatr Int* 2015;57:431-8.
8. Blanc C, Togarsimalemath SK, Chauvet S, Le Quintrec M, Moulin B, Buchler M, et al. Anti-factor H autoantibodies in C3 glomerulopathies and in atypical hemolytic uremic syndrome: one target, two diseases. *J Immunol* 2015;194:5129-38.

9. Durey MA, Sinha A, Togarsimalemath SK, Bagga A. Anti-complement-factor H-associated glomerulopathies. *Nat Rev Nephrol* 2016;12:563-78.
10. Salvadori M, Rosso G. Reclassification of membranoproliferative glomerulonephritis: identification of a new GN: C3GN. *World J Nephrol* 2016;5:308-20.
11. Sethi S, Haas M, Markowitz GS, D'Agati VD, Rennke HG, Jennette JC, et al. Mayo Clinic/Renal Pathology Society Consensus Report on Pathologic Classification, Diagnosis, and Reporting of GN. *J Am Soc Nephrol* 2016;27:1278-87.
12. Servais A, Noël LH, Roumenina LT, Le Quintrec M, Ngo S, Dragon-Durey MA, et al. Acquired and genetic complement abnormalities play a critical role in dense deposit disease and other C3 glomerulopathies. *Kidney Int* 2012; 82:454-64.
13. Bomback AS, Santoriello D, Avasare RS, Regunathan-Shenk R, Canetta PA, Ahn W, et al. C3 glomerulonephritis and dense deposit disease share a similar disease course in a large United States cohort of patients with C3 glomerulopathy. *Kidney Int* 2018;93:977-85.
14. Ravindran A, Fervenza FC, Smith RJH, De Vriese AS, Sethi S. C3 glomerulopathy: ten years' experience at Mayo Clinic. *Mayo Clin Proc* 2018;93:991-1008.
15. Riedl M, Thorner P, Licht C. C3 glomerulopathy. *Pediatr Nephrol* 2017;32:43-57.